BOSTON
MEDICAL LIBRARY
8 THE FENWAY

Digitized by the Internet Archive
in 2011 with funding from
Open Knowledge Commons and Harvard Medical School

http://www.archive.org/details/textbookofoperat01koch

TEXT-BOOK

OF

OPERATIVE SURGERY

TEXT-BOOK

OF

OPERATIVE SURGERY

BY

DR. THEODOR KOCHER

PROFESSOR OF SURGERY AND DIRECTOR OF THE SURGICAL CLINIC
IN THE UNIVERSITY OF BERN

THIRD ENGLISH EDITION

AUTHORISED TRANSLATION FROM THE FIFTH GERMAN EDITION

BY

HAROLD J. STILES, M.B., F.R.C.S. EDIN.

SURGEON TO THE CHALMERS HOSPITAL, EDINBURGH
SURGEON TO THE ROYAL EDINBURGH HOSPITAL FOR SICK CHILDREN
LECTURER ON APPLIED ANATOMY, UNIVERSITY OF EDINBURGH

AND

C. BALFOUR PAUL, M.B., F.R.C.S. EDIN.

ASSISTANT SURGEON, ROYAL EDINBURGH HOSPITAL FOR SICK CHILDREN

WITH 415 ILLUSTRATIONS

IN TWO VOLS.

VOL. I

NEW YORK
THE MACMILLAN COMPANY
LONDON: ADAM AND CHARLES BLACK
1911

23.d.50

First English Edition (*translated from the Second German Edition*) *published in* 1895.
Second English Edition (*translated from the Fourth German Edition*) *published in* 1903.
Third English Edition published in 1911.

TRANSLATORS' PREFACE

No apology is needed for the endeavour to render more accessible to the profession in this country a work on operative surgery by so eminent an authority as Professor Kocher.

The book is essentially a record of the author's personal experience and of his own methods of operation. To avoid an appearance of egotism he has written in the first person plural, and this plan has been followed in the translation.

The first English edition, which appeared in 1895, was translated from the second German edition, while the second English edition, which was twice the size of its predecessor, was translated from the fourth German edition. The present volume is a translation of the fifth and latest German edition.

The amount of new material that has been added, the rearrangement and revision of the text, and the great number of new illustrations introduced have been responsible for an increase of 300 pages. The work now covers the whole field of operative surgery. In the first of the five parts into which the volume is divided, the preparation of the patient, the disinfection of the surgeon and his assistants, the methods of sterilisation, surgical technique, treatment of wounds and anæsthesia have been greatly amplified, local and regional anæsthesia being dealt with at length.

In the second part the surgery of the vascular system has been systematically considered, no less than 106 operations on the arteries being described, while the suture of veins receives full attention.

The third part, dealing with the surgery of the nervous system, has been rearranged as well as largely amplified. The portion devoted to the operations on the brain and cranial nerves has been practically rewritten, and full acknowledgment is given to the work of the present-day neurologists, especially in connection with the removal of tumours and of the Gasserian ganglion. Operations on the peripheral nerves are also described

in a systematic manner, and emphasis is laid on their topography in relation to conduction anæsthesia.

In the fourth part Professor Kocher writes with authority on the surgery of the extremities. Fresh material has been introduced in connection with the operative treatment of paralysis and deformities, while his well-known descriptions of arthrotomies, resections, and amputations have been revised and enlarged. As excision of the wrist-joint has been unaccountably omitted in the German, we have thought it desirable to insert it in the form of an appendix at the end of the book.

The fifth part, which forms the second half of the volume, is devoted to the surgery of the head and trunk. The section on the surgery of the thorax has been practically rewritten, and the recent advances in the treatment of the thoracic viscera receive full attention.

As regards the section of the abdomen, special mention should be made of the chapters on the liver and bile ducts, which have been rewritten and occupy nearly thirty pages of the text. The operations on the intestines, including the rectum, as well as those on the kidney and ureters, have also been dealt with much more fully than in the former editions.

For the time and labour expended in the translation the writers derive no inconsiderable reward from the consciousness that the teaching and methods of so great a master as Professor Kocher will be welcomed not only by senior students and practitioners, but also by all who are actively engaged in the teaching and practice of surgery.

We have much pleasure in expressing our indebtedness to Mr. W. J. Stuart, F.R.C.S. Edin., for kindly assisting us with the translation of some of the more difficult passages, and we again desire to thank Mr. George Stronach, M.A., for the literary care with which he has read the proofs. To Miss A. C. Hutcheson, M.A., we would express our thanks not only for compiling the index, but for much general assistance.

HAROLD J. STILES.
C. BALFOUR PAUL.

EDINBURGH, *February* 1911.

AUTHOR'S PREFACE TO THE FIFTH EDITION

In the prefaces to the former editions of this work on operative surgery I have specially emphasised the fact that the more surgery has become the common property of medical men, the more it is incumbent on any one who intends to devote himself to practical surgery to take every opportunity of improving his technique. This is essential, because any general practitioner of repute may be suddenly called upon to take charge of a surgical department in a country hospital. The responsibility of such a position must weigh heavily upon the conscientious practitioner if he has not had a thorough training as a clinical assistant in a hospital, as he may be required at any moment to decide instantly on a course of action on which may depend not only the future health but even the life of the patient. Unless he wishes to be classed among those who resort to exploratory incisions on all occasions regardless of risk, he must learn how to make an exact diagnosis and to establish precise indications for treatment. This necessitates the stern discipline of a long clinical assistantship. The requisite dexterity in operating is acquired in a shorter apprenticeship to a good practical surgeon.

The possession of these requisites would destroy the favourite arguments of those physicians who are inclined to disparage surgery and belittle its successes. They maintain that the cases are innumerable in which unnecessary and even injurious operations are performed, and they are apt to hold the whole profession responsible for such unwarranted operations undertaken by men of little experience.

Just as the physician is not permitted to write prescriptions without a knowledge of the action and effects of drugs, so the surgeon should not be allowed to perform operations unless he is capable of first making an exact diagnosis and prognosis.

Even if we admit that the surgeon is responsible for the results of his operations, it must never be forgotten that omissions and blunders in the

previous treatment on the part of the public and the physician respectively account for an infinitely larger number of victims than do the errors of the surgeon. The surgeon's task is hard enough, and his difficulties ought to be lessened as much as possible—indeed, we consider it justifiable to raise the question: What particular considerations are due to the surgeon from physicians and from the public? I wish to call special attention to these in the interest of the patients.

1. In every case where there is any question of operation the surgeon ought to be summoned in the first instance for the purposes of examination and consultation. Surely the time will come when cases of ileus will receive operative treatment at once, and will not be left until gangrene of the intestine and perforation make it impossible to deal successfully with the cause of the condition. Every ileus ought to be examined at the beginning by both the physician and the surgeon. If two consultants are unnecessary, it is the surgeon who is indispensable.

A case of acute appendicitis can be easily and entirely cured by an operation on the first day, but without an operation the life of the patient may be very seriously endangered by the rapid supervention of perforative peritonitis. The relations of the patient should therefore be informed at once of the possibility of a cure by operation: it is unwarrantable to omit to call in the surgeon until peritonitis has become advanced. In cases in which carcinoma is suspected, a succession of specialists should not allow the best time for a radical cure to slip away by wasting weeks and months in establishing a diagnosis. The statistics which we shall produce in this book clearly prove that if patients suffering from malignant mischief receive operative treatment at an earlier stage of the disease, an important addition to the number of permanent cures would certainly be obtained.

If suspicious symptoms appear in a case of brain-tumour the general health of the patient should not be reduced by preparations of mercury for several months on the assumption that syphilis exists: it is no use handing the patient over to the surgeon when the operative treatment is certain to fail.

These are all experiences I have had, and I could easily add to them.

2. The choice of where the operation is to be done, as well as the manner of its performance, should be left entirely to the surgeon.

It is no easy matter to arrange all the preparations for an operation so as to ensure complete asepsis. We have made such strides since the days when sepsis prevailed, that when a patient inquires if the operation is serious, we can assure him there is no danger. In the days of sepsis such an assertion would not have been strictly true, even with small operations.

A surgeon cannot guarantee the satisfactory progress of his patient after an operation unless it be done in a place where he can make all his own arrangements, where he can thoroughly depend on his staff, and where he has entire control of all details, such as the previous treatment of the patient, the preparation of ligatures and sutures, of bandages, of instruments, and of everything which comes in contact with the wound; and lastly, he must be sure of the cleanliness of the assistants' hands.

How often does the doctor write to say that he has prepared everything most punctiliously and that there is no necessity to bring instruments, ligatures, sutures, or bandages. Accordingly, the trusting surgeon arrives and finds that some very necessary instruments are wanting, that there are no drainage tubes, and that the well-sterilised dressings have been handled in such a way that they are no longer sterile.

It has frequently been my lot to see doctors disinfect their hands before an operation almost to the extent of injuring their skin, while the theatre-nurse, after disinfecting her hands, quietly helps the patient to take off his dirty clothes and to place him properly on the operating table. She often wears a regulation dress which quite prohibits a purification in the surgical sense of the word, and when the well-sterilised thread is handed to her, she lets it trail over all manner of towels and articles of clothing.

The surgeon can only guarantee a successful issue in its full sense, *i.e.* aseptic healing, when the patient is brought to his own hospital where he has thorough confidence in the staff and the appliances, and, moreover, where he has authority.

Many times I have bitterly repented having embarked upon a serious operation under conditions over which I had no control, in consequence of having undertaken a distant journey to the patient because his doctors and relations could not make up their minds to let him be moved. If the patient cannot be moved, the surgeon should be allowed to bring his own staff and appliances. I cannot admire those itinerant surgeons who place themselves at the service of general practitioners and offer to operate on their patients on the spot.

3. I have already shown that it is absurd to call in the surgeon when a patient has become moribund, according to the custom expressed in the well-known words of the physician—"The patient is lost at any rate, now we can hand him over to the surgical clinique." And it is equally unwarrantable to call in the surgeon to perform merely secondary operations.

A small carcinoma of the skin will often be excised, perhaps even a small recurrent nodule removed, but directly the growth has spread and deepened the case is thrust upon the hospital surgeon. Or a primary

carcinoma is removed and subsequently the adjacent glands become enlarged; the patient is then handed over at this late stage to a surgeon who has to perform an operation which was plainly indicated at the beginning.

How frequently a tuberculous abscess is merely incised, with the result that mixed infection from staphylo- and streptococci arises. The prognosis is now fundamentally altered and only at this late period is the surgeon called upon to remove the disease from its foundation.

In order to participate fully in the benefits of surgical therapy, doctors and surgeons must regard the smallest operation as an important matter, and must give it the most careful consideration. There is no objection to a general practitioner performing an operation himself, but if he is not quite clear as to the possible results his conscience ought to lead him to consult any experienced surgeon in order to gain a clear idea of the indications, dangers, and technique of the operation. Young general practitioners who are fresh from the examination room undertake cheerfully quite big operations simply because in the clinic, they have seen the largest wounds heal uninterruptedly under aseptic treatment, and because they have observed how regularly a simple abdominal or appendix case, or even one of goitre, can be dismissed after eight days. They have had too little opportunity of realising that such an uninterrupted recovery is dependent on certain definite rules which must on no account be broken.

It is the aim of this work on operative surgery to bring these fundamental principles to the knowledge of the medical profession: physicians and surgeons must, however, co-operate if the best results are to be obtained. In our opinion, the doctor is most to be commended who establishes a correct diagnosis at once, and, regardless of other considerations, sends his patients for early operation to the place where there is the best prospect of a permanently successful result; he can then consider that he has been the chief cause of the success, and he is certainly much more to be congratulated than the man who cannot resist the temptation of trying to prove his ability as an operator under conditions where the requisites for success are unattainable.

CONTENTS

INTRODUCTION 1

SECTION I

General Considerations

A. PREPARATION FOR OPERATION 3

(*a*) *Preparation of the Patient* 3
1. In the Ward . . . . . 3 2. By the Medical Attendant . . 4
(*b*) *Preparation of the Operating Room* 7
(*c*) *Preparation by the Assisting Staff of the Materials required* . . . 7

B. THE BEGINNING OF THE OPERATION 9

(*d*) *Position of the Patient* 9
(*e*) *Asepsis of the Patient and Operators—Final Cleansing* 11
(*f*) *Anæsthesia* 12
1. General . . . . . 12 3. Conduction 18
2. Local . . . . . 16 4. Spinal 29

C. OPERATIVE TECHNIQUE 30

(*g*) *Direction of Skin Incisions* 30
(*h*) *Division of Deep Tissues* 33
(*i*) *Arrest of Hæmorrhage* 33
(*k*) *Closure of the Wound* 34

D. AFTER-TREATMENT OF THE PATIENT 35

E. DETAILS WITH REGARD TO ANÆSTHESIA 37

(*l*) *Further Remarks on Local Anæsthesia* 37
1. Lennander's Investigations 37
(*m*) *Appendix to Medullary Anæsthesia* 41
(*n*) *Epidural Injection into the Spinal Canal* 45
(*o*) *Further Details on General Anæsthesia* 46

F. TREATMENT OF WOUNDS 63

(*p*) *Sterilisation of Dressings, Instruments, and Lotions* 63
(*q*) *Disinfection of the Skin* 65
(*r*) *Prevention of Air-Infection* 72
(*s*) *Implantation-Infection, and the Question of Ligatures* 73
(*t*) *The Significance of Necrotic Tissue in regard to Infection—Prevention of Necrosis* . 75
(*u*) *Treatment of Infected Wounds* 79

SECTION II

Surgery of the Vascular System

A. SURGERY OF THE HEART AND PERICARDIUM 82

1. Exposure and Suture of the Heart 82
2. Puncture, Incision, and Drainage of the Pericardium . . 89
3. Cardiolysis 91

B. SURGERY OF THE LARGE ARTERIES 92

1. Ligature of the Abdominal Aorta 92
2. Ligature of the Innominate Artery 93
3. Ligature of the Common Carotid Artery 93

(*a*) *Branches of Common Carotid Artery* 95

4. Ligature of the Internal Carotid Artery 95
5. Ligature of the External Carotid Artery 96

(*b*) *Branches of External Carotid Artery* 97

6. Ligature of the Superior Thyroid Artery 97
7. Ligature of the Lingual Artery . 99
8. Ligature of the External Maxillary Artery (Facial) 101
9. Ligature of the Sterno-mastoid Artery 102
10. Ligature of the Occipital Artery . 102
11. Ligature of the Posterior Auricular Artery 103
12. Ligature of the Ascending Pharyngeal Artery 103
13. Ligature of the Ascending Palatine Artery 103
14. Ligature of the Internal Maxillary Artery 104
15. Ligature of the Superficial Temporal Artery . . . 104

(*c*) *Branches of Internal Carotid Artery* 105

16. Ligature of the Ophthalmic Artery and its Branches, the Supraorbital and Frontal Arteries 105

(*d*) *Subclavian Artery and its Branches* 105

17. Ligature of the Subclavian Artery 105
18. Ligature of the Vertebral Artery 106
19. Ligature of the Internal Mammary Artery 107
20. Ligature of the Superior Intercostal Artery 108
21. Ligature of the Inferior Thyroid Artery 108
22. Ligature of the Transversalis Colli Artery 110
23. Ligature of the Posterior Scapular Artery 110

(*e*) *Axillary Artery and Arteries of the Arm* 110

24. Ligature of the Axillary Artery . 110
25. Ligature of the Superior Thoracic Artery 115
26. Ligature of the Acromio-thoracic Artery 115
27. Ligature of the Long Thoracic Artery 115
28. Ligature of the Anterior Circumflex Artery 115
29. Ligature of the Posterior Circumflex Artery 117
30. Ligature of the Subscapular Artery and Branches 120

(*f*) *Brachial Artery and its Branches* 120

31. Ligature of the Brachial Artery . 120
32. Ligature of the Arteria Collateralis Radialis Superior . . 120
33. Ligature of the Superior Profunda Artery 120
34. Ligature of the Arteria Collateralis Media 121
35. Ligature of the Arteria Collateralis Radialis Inferior . . 121
36. Ligature of the Inferior Profunda Artery 121
37. Ligature of the Anastomotica Magna Artery 121

(*g*) *Arteries of the Forearm and Hand* 123

38. Ligature of the Radial Artery . 123
39. Ligature of the Ulnar Artery . 123
40. Ligature of the Common Interosseous Artery 125
41. Ligature of the Superficial Palmar Arch 125
42. Ligature of the Deep Palmar Arch 127
43. Ligature of the Digital Arteries in the Palm, Collateral Digital Arteries 127

(*h*) *Branches of the Thoracic Aorta* 127

44. Ligature of the Intercostal Arteries 127

(*i*) *Branches of the Abdominal Aorta* 129

45. Ligature of the Parietal Branches 129
46. Ligature of the Cœliac Axis . 130
47. Ligature of the Coronary Artery 130
48. Ligature of the Splenic Artery . 130
49. Provisional and Permanent Ligature of the Arteries of the Stomach, Pancreas, and Duodenum 130
50. Ligature of the Superior Mesenteric Artery 131
51. Ligature of the Inferior Mesenteric Artery 131
52. Ligature of the Renal Artery . 131
53. Ligature of the Internal Spermatic Arteries 132

(*k*) *Common Iliac Artery and its Branches* 132

54. Ligature of the Common Iliac Artery 132

(*l*) *Hypogastric Artery and its Branches* 134

55. Ligature of the Internal Iliac Artery 134
56. Ligature of the Superior Vesical Artery 134
57. Ligature of the Ilio-lumbar Artery 134
58. Ligature of the Obturator Artery 134
59. Ligature of the Lateral Sacral Artery 136
60. Ligature of the Gluteal Artery . 136
61. Ligature of the Sciatic Artery . 136
62. Ligature of the Inferior Vesical Artery 136
63. Ligature of the Artery to the Vas Deferens 136
64. Ligature of the Middle Hæmorrhoidal Artery . . . 136
65. Ligature of the Uterine Artery . 137
66. Ligature of the Internal Pudic Artery 139

(*m*) *External Iliac Artery and its Branches* 139

67. Ligature of the External Iliac Artery 139
68. Ligature of the Deep Epigastric Artery 139
69. Ligature of the Deep Circumflex Iliac Artery 141
70. Ligature of the Femoral Artery . 143
71. Ligature of the Internal Circumflex Artery 146
72. Ligature of the Profunda Femoris Artery 146
73. Ligature of the External Circumflex Artery 146
74. Ligature of the Perforating Arteries 148
75. Ligature of the Anastomotica Magna Artery 148

(*n*) *Popliteal Artery and its Branches* 148

76. Ligature of the Popliteal Artery 148
77. Ligature of the Anterior Tibial Artery 148
78. Ligature of the Posterior Tibial Artery 151
79. Ligature of the Peroneal Artery . 155

(*o*) *Arteries of the Foot* 155

80. Ligature of the Dorsalis Pedis Artery 155
81. Ligature of the Plantar Arteries 155

C. SURGERY OF THE VENOUS SYSTEM 159

(*a*) *General Indications for the Exposure and Ligature of the Larger Veins* . . . 159

(*b*) *Exposure, Suture, and Ligature of Individual Veins* 161
82. Exposure of the Superior Vena Cava 161
83. Ligature and Suture of the Inferior Vena Cava . . . 162
84. Ligature and Suture of the Innominate Veins . . . 164
Tributaries of the Innominate Veins 165
85. Ligature of the Thyroidea Ima Vein 165
86. Ligature of the Common Jugular Vein 166
Tributaries of the Common Jugular Vein 166
87. Ligature of the Superior Longitudinal Sinus 166
88. Ligature of the Lateral Sinus . 166
89. Ligature of the Occipital Sinus . 167
90. Ligature of the Spheno-parietal Sinus 167
91. Ligature of the Diploic Veins . 167
92. Ligature of the Superior and Inferior Ophthalmic Veins . 167
93. Ligature of the Internal Jugular Vein 167
94. Ligature of the External Jugular Vein 167
95. Ligature of the Anterior Jugular Vein 168
96. Ligature of the Subclavian Vein 168
97. Ligature of the Axillary Vein . 168
98. Ligature of the Veins of the Arm 168
Tributaries of the Inferior Vena Cava 168
99. Ligature and Suture of the Common Iliac Vein . . . 168
100. Ligature of the Internal Iliac Vein 168
101. Ligature of the Common Femoral Vein 168
102. Ligature of the Tributaries of the Femoral and Internal Iliac Veins 169
103. Ligature of the Long Saphenous Vein 169
104. Ligature of the Short Saphenous Vein 170
105. Ligature in the Portal Area . 170
106. Ligature of the Superior Mesenteric Vein 170

SECTION III

Surgery of the Nervous System

INTRODUCTION 171
A. METHODS OF EXPLORATION, AND RELIEF OF CEREBRAL TENSION . 172
1. Puncture of the Skull and Brain 172
(*a*) General Remarks . . . 172
(*b*) Special Indications for and Technique of Puncture of the Brain 173
2. Trephining for Exploration and Decompression . . . 175
(*a*) Arrest of Hæmorrhage during Trephining 176
(*b*) Partial Circumscribed Craniectomy 178
(*c*) Extensive Resection of the Skull 179
B. OSTEOPLASTIC TREPHINING 182
3. Osteoplastic Resection of Skull . 182
4. Circular Craniotomy . . . 184
5. Craniotomy for the covering in of Osseous Defects in the Skull . 185
C. SPECIAL INDICATIONS FOR TREPHINING 186
6. Trephining over the Sinuses of the Dura Mater . . . 186
(*a*) Trephining over the Superior Longitudinal Sinus . . . 186
(*b*) Trephining over the Occipital Sinus 187
(*c*) Trephining over the Lateral Sinus 188
7. Trephining for Intracranial Hæmorrhage 189
(*a*) Trephining for Intracerebral and Subdural Hæmorrhage . . 189
(*b*) Trephining for Supradural Hæmorrhage 191
8. Trephining for Abscess of the Brain 193
9. Trephining for Cerebral Tumours . 194
(*a*) For Cerebral Tumour . . 194
(*b*) For Cerebellar Tumour . . 195

D. CRANIO-CEREBRAL TOPOGRAPHY 198

E. SURGERY OF THE SPINAL CORD AND ITS COVERINGS 202

(*a*) Puncture of the Subarachnoid Space 202
(*b*) Extensive Exposure of the Spinal Cord 202
10. Technique of Laminectomy . 204

F. SURGERY OF NERVE-ROOTS 206

(*a*) Intracranial and Intraspinal Nerves 206
11. Extirpation of the Gasserian Ganglion, division of its Root and Intracranial Branches . 207
(*a*) Extirpation of the Gasserian Ganglion 207
12. Summary of technique which we regard as best 210
(*b*) Division of the Root of the Gasserian Ganglion . . . 213
(*c*) Intracranial Section of the Divisions of the Trigeminal . 213
13. Division of the posterior roots in the spinal canal . . . 214

G. SURGERY OF INDIVIDUAL PERIPHERAL NERVES 214

(*a*) *General Remarks on Surgery of Nerves* 214

(*b*) *Cranial Nerves* 215

14. Optic Nerve 215
Trigeminal Nerve (Extracranial) 217
(*a*) First Division—
1. Frontal 219
2. Nasal 219
(*b*) Second Division—
1. Exposure of Superior Maxillary Nerve at the Base of the Skull . . 219
2. Exposure of Zygomatic Nerve 222
3. Exposure of Spheno-palatine Nerves 222
4. Exposure of Superior Dental Nerves 222
5. Exposure of Infraorbital Nerve 222
6. Exposure of Palatine Nerves . 223
(*c*) Third Division—
1. Buccinator Nerve . . . 227
2. Auriculo-temporal Nerve . 228
3. Inferior Dental Nerve . . 228
4. Mental Branch of Inferior Dental Nerve . . . 229
5. Mylo-hyoid Nerve . . 229
6. Lingual Nerve . . . 229
15. Facial Nerve 229
16. Aconstic Nerve 232
17. Vagus Nerve 232
(*a*) Superior Laryngeal Nerve . 232
(*b*) Inferior Laryngeal Nerve . 232
18. Spinal Accessory Nerve . . 233
19. Hypoglossal Nerve . . . 236

H. SPINAL NERVES 236

(*a*) *The Upper Four Cervical Nerves* 236

20. Great Occipital Nerve . . 238
21. Small Occipital Nerve (Great Auricular and Superficial Cervical Nerves) . . . 239
22. Fourth Cervical Nerve (Supraclavicular and Phrenic Nerve) 239

(*b*) *The Lower Four Cervical Nerves (Brachial Plexus)* 240

23. Anterior Thoracic Nerves . . 243
24. Short and Long Subscapular Nerves 243
25. Long Thoracic Nerve . . 243
26. Circumflex Nerve . . . 243
27. Suprascapular Nerve . . . 243
28. Nerve to the Rhomboids . . 243
29. Lesser Internal Cutaneous Nerve 243
30. Internal Cutaneous Nerve . . 243
31. Musculo-cutaneous Nerve . . 243
32. Median Nerve and Branches . 245

(*c*) *Common Palmar Digital Branches* 248

(*d*) *Anterior Interosseous Nerve* 248

(*e*) *Palmar Cutaneous Branch* 248

(*f*) *Palmar Digital Branches* 248

33. Ulnar Nerve and Branches . 248
(*a*) Palmar Cutaneous Branch . 249
(*b*) Dorsal Cutaneous Branch . 249
(*c*) Palmar Branch . . . 249

34. Musculo-spiral Nerve . . 250
(a) Upper External Cutaneous Branch 250
(b) Lower External Cutaneous Branch 250
(c) Posterior Interosseous Nerve . 250
(d) Radial Nerve . . . 252

(g) *Thoracic Nerves* 252

35. Intercostal Nerves . . . 252

(h) *Lumbar Plexus* 252

36. Ilio-inguinal 252
37. Ilio-hypogastric . . . 252
38. External Cutaneous Nerve. . 255
39. Genito-crural Nerve . . . 255
40. Anterior Crural Nerve and Branches. 255
(a) Anterior Cutaneous Nerves . 255
(b) Long Saphenous Nerve . . 255
41. Obturator Nerve . . . 257

(i) *Sacral Plexus* 257

42. Superior Gluteal Nerve . . 257
43. Inferior Gluteal Nerve . . 257
44. Small Sciatic Nerve . . . 257
45. Great Sciatic Nerve and Branches 257
(a) Internal Popliteal (posterior Tibial). 259
(a) Ramus Communicans Tibialis 259
(β) Internal Plantar Nerve . 260
(γ) External Plantar Nerve . 264
(b) External Popliteal. . . 264
(a) Ramus Communicans Fibularis 264
(β) Anterior Tibial . . . 264
(γ) Musculo-cutaneous . . 267

(j) *Pudendal Plexus* 267

(a) Pudic Nerve 267

(k) *Coccygeal Plexus* 268

46. Ano-Coccygeal Nerves . . 268

(l) *Sympathetic Cord* 268

47. Division of the Cervical Sympathetic above the Superior Cervical Ganglion . . 268

SECTION IV

Surgery of the Extremities

(a) *General* 270
(b) *Nerve-Anastomosis, Nerve-Transplantation, Nerve-Grafting* 271
(c) *Surgery of Muscles* 271
(d) *Surgery of Tendons* 272
(e) *Surgery of Articular Ligaments* 275
(f) *Surgery of Bones* 275

A. ARTHROTOMY, OSTEOTOMY, AND RESECTION 276
(a) *Technique*. 276
(b) *Indications and Contraindications* 278
(c) *After-Treatment* 279
(d) *Operations on the Foot* 281
1. Resection of the Phalanges and Metatarsal bones . . . 281
2. Resection for Hallux Valgus . 281

3. Osteoarthrectomy at the Tarso-Metatarsal Joint and Anterior Tarsectomy 281
4. Osteoarthrectomy at the Mid-tarsal Joint 282
5. Excision of the Scaphoid . . 283
6. Arthrotomy at Chopart's Joint . 283
7. Excision of the Astragalus. . 283
8. Excision of the Os Calcis . . 285
9. Astragalo-Calcanean Arthrectomy and Posterior Tarsectomy 286
10. Arthrotomy and Resection of Ankle 286
11. Total Tarsectomy . . . 289

(*e*) *Operations on the Leg* 290

12. Supramalleolar Osteotomy. . 290
13. Resection of the Lower Third of the Leg 290
14. Osteotomy of the Tibia . . 290
15. Resection of the Tibia . . 291
16. Resection of the Fibula . . 292

(*f*) *Operations on the Knee* 292

17. Arthrotomy, Arthrectomy and Resection at the Knee-joint . 292
18. Meniscotomy 299
19. Arthrotomy for Habitual Dislocation of the Patella . . 300
20. Excision of the Patella . . 300

(*g*) *Operations on the Thigh* 300

21. Supracondylar Osteotomy of the Femur 300
22. Osteotomy and Resection of the Femur 301
23. Osteotomy and Subtrochanteric Cuneiform Resection of the Femur 301

(*h*) *Operations at the Hip and Pelvis* 303

24. Arthrotomy and Resection of the Hip 303
25. Arthrotomy in Congenital Dislocation of the Hip . . . 307
26. Osteotomy of the Pelvis . . 307
27. Resection of Half the Pelvis . 308
28. Resection of the Sacrum . . 309

(*i*) *Operations on the Fingers and Hand* 309

(*a*) Preliminary Remarks on Operations on the Fingers . 309
(*b*) Preliminary Remarks on Operations on the Hand . 310
29. Excision of Phalanges and Metacarpal Bones, of Interphalangeal and Metacarpo-phalangeal Joints . . . 311

(*k*) *Operations on the Forearm* 312

30. Osteotomy and Resection of the Ulna 313
31. Osteotomy and Resection of the Radius 313

(*l*) *Operations at the Elbow* 313

32. Arthrotomy, Arthrectomy, and Resection of the Elbow . . 314

(*m*) *Operations on the Upper Arm* 318

33. Osteotomy and Resection of the Diaphysis of the Humerus . 319

(*n*) *Operations at the Shoulder* 319

34. Arthrotomy, Arthrectomy, and Resection of the Shoulder-joint 320
35. Resection of the Clavicle, of the Sterno-Clavicular and Acromio-clavicular Articulations . . 327
36. Resection and Total Excision of the Scapula 327

B. AMPUTATIONS AND DISARTICULATIONS 329

(*a*) *Introduction* 329

(*b*) *Evolution of the Methods of Amputation* 330

(c) *Performance of the different Methods* 332

(d) *Methods of obtaining useful Stumps* 335

(e) *Amputations of the Foot* 342

37. Removal of the Toes and Individual Metatarsal Bones . 342
38. Disarticulation of all the Toes (Metatarso-phalangeal Disarticulation) 342
39. Amputation through the Metatarsus 343
40. Disarticulation at the Tarso-metatarsal Joints (Lisfranc) . 343
41. Anterior Intertarsal Disarticulation 344
42. Posterior Intertarsal Disarticulation (Chopart) . . . 345
43. Intertarsal Amputation . . 346
44. Subastragaloid Disarticulation . 346
45. Subastragaloid Osteoplastic Amputation 346
46. Disarticulation at the Ankle-joint (Syme) 347
47. Osteoplastic Amputation of the Foot (Pirogoff) . . . 348

(f) *Amputations of the Leg* 350

48. Amputations of the Leg . . 350

(h) *Amputations at the Knee* 355

49. Disarticulation at the Knee . 356

(i) *Amputations through the Thigh* 357

50. Amputation of the Femur through the Condyles (Carden and Buchanan) 359
51. Osteoplastic Amputation of the Femur through the Condyles (Ssabanejeff) 360
52. Supracondyloid Amputation . 361
53. Osteoplastic Supracondyloid Amputation of the Thigh (Gritti) 361
54. Amputation through the Middle of the Thigh . . 362
55. High Amputation of the Thigh 363
56. Disarticulation at the Hip . 363
57. Amputation of the Pelvis and Interilio-abdominal Disarticulation 367

(k) *Amputation of the Hand and Fingers* 371

58. Amputation and Disarticulation of the Fingers . . . 371
59. Disarticulation at the Wrist-joint 373

(l) *Amputation of the Arm* 373

60. Amputation of the Forearm . 373
61. Disarticulation at the Elbow-joint 373
62. Amputation through the Upper Arm 374
63. Disarticulation at the Shoulder. 376
64. Interscapulo-thoracic Amputation 379

ILLUSTRATIONS

SECTION I

General Considerations

FIG.		PAGE
1.	Arrangement of Sterilised Sheets for Operation on Goitre	8
2.	Stand for Lotions used in Author's Clinic	12
3.	Braun's Apparatus for the Administration of Chloroform and Ether	15
4.	Conduction Anæsthesia (Braun) of Front of Upper Arm (after Spalteholz)	19
5.	Conduction Anæsthesia (Braun) of Back of Upper Arm (after Spalteholz)	20
6.	Conduction Anæsthesia (Braun) of Front of Forearm (after Spalteholz)	21
7.	Conduction Anæsthesia (Braun) of Back of Hand (after Spalteholz)	22
8.	Conduction Anæsthesia (Braun) of Finger (after Spalteholz)	22
9.	Conduction Anæsthesia (Braun) of Anterior Surface of Thigh (after Spalteholz)	23
10.	Conduction Anæsthesia (Braun) of Front of Leg (after Spalteholz)	24
11.	Conduction Anæsthesia (Braun) of Back of Leg (after Spalteholz)	25
12.	Conduction Anæsthesia of Median and Ulnar Nerves (after Spalteholz)	26
13.	Dissection of Right Side of Neck (Spalteholz) to illustrate Conduction Anæsthesia (Braun)	27
14.	Dissection of Perineum (Spalteholz) to illustrate Conduction Anæsthesia (Braun)	28
15-16*a*.	Normal Incisions illustrated on Langer's Figures	31, 32
17.	Kocher's Artery Forceps	33
18.	Point of Introduction of Needle in the Production of Medullary Anæsthesia	42
19, 20.	Skiagrams of the Lumbar Vertebræ (Klien)	43
21, 22.	Cathelin's Method of Epidural Injection of Sacral Canal	45
23.	Chloroform Mask	48

SECTION II

Surgery of the Vascular System

24.	Incision for Exposure of Heart	83
25, 26.	Exposure of Heart	84, 86
27.	Outline of Heart, Lungs and Pleuræ (Spalteholz-Merkel)	88
27*a*.	Transverse Section of Thorax showing Effusion in the Pericardium	89
28.	Ligature of Lingual, Common Carotid, Innominate, first part of the Axillary, and Internal Mammary Arteries	94
29.	Ligature of External Carotid and Subclavian Arteries	96
30.	Ligature of Superior Thyroid Artery	98
31.	Ligature of Lingual, Common Carotid, Innominate, first part of the Axillary, and Internal Mammary Arteries	100

FIG. PAGE
32. Ligature of Facial, Inferior Thyroid, and Vertebral Arteries 101
33. Ligature of Occipital Artery 102
34. Ligature of Facial and Temporal Arteries. Trephining the Jaw to expose the Inferior Dental Nerve 103
35. Ligature of Supraorbital Artery. Exposure of Supraorbital Nerve and Infraorbital Nerve. Opening of Frontal Sinus 104
36. Ligature of External Carotid and Subclavian Arteries 106
37. Ligature of Facial, Inferior Thyroid, and Vertebral Arteries 107
38. Ligature of Suprascapular Artery 108
39. Exposure of 10th Rib and 10th Intercostal Artery and Nerve. Ligature of Posterior Scapular Artery 109
40, 41. Author's "Normal Incisions" 111, 112
42. Ligature of Lingual, Common Carotid, Innominate, first part of Axillary and Internal Mammary Arteries 113
43. Ligature of Axillary Artery, above or immediately below the Pectoralis Minor . 114
44. Exposure of Axillary, Brachial, Superior Profunda and Subscapular Arteries and Median, Subscapular, Musculo-spiral, and Circumflex Nerves . . . 116
45. Ligature of Anterior Circumflex Artery. Exposure of Musculo-cutaneous Nerve . 117
46. Ligature of Posterior Circumflex and Superior Profunda Arteries and Exposure of Circumflex and Musculo-spiral Nerves 118
47. Ligature of Axillary, Brachial, Superior Profunda, and Subscapular Arteries; Exposure of Median, Subscapular, Musculo-spiral, and Circumflex Nerves . . 119
48. Ligature of Brachial and Radial and Ulnar Arteries 122
49. Ligature of Radial Artery on Back of Wrist. Exposure of Radial Nerve . . 124
50. Ligature of Interosseous Artery; Exposure of Median and Anterior Interosseous Nerves 126
51. Ligature of Superficial and Deep Palmar Arches 128
52. Exposure of 10th Rib and 10th Intercostal Artery and Nerve. Ligature of Posterior Scapular Artery 129
53. Ligature of Common Iliac Artery 133
54. Ligature of Profunda Femoris, External Circumflex, Obturator Arteries . . 135
55. Nephrotomy. Ligature of Sciatic, Internal Pudic, and Gluteal Arteries. Exposure of Great and Small Sciatic, Internal Pudic, and Superior Gluteal Nerves . . 137
56. Ligature of Internal Pudic Artery at the Ischial Tuberosity 138
57. Cholecystotomy. Ligature of Deep Circumflex Iliac, Common Iliac, and Common Femoral Arteries 140
57*a*. Ligature of Deep Epigastric Artery 141
58. Cholecystotomy. Ligature of Deep Circumflex, Common Iliac, and Common Femoral Arteries 142
59. Ligature of Common Femoral, Femoral Arteries. Exposure of External Cutaneous Nerves 144
60. Ligature of Internal Circumflex Artery 145
61. Ligature of Profunda Femoris, External Circumflex, and Obturator Arteries . . 147
62. Ligature of Popliteal Artery 149
63. Ligature of Anterior Tibial Artery. Exposure of Anterior Tibial Nerve . . 150
64. Ligature of Posterior Tibial Artery above the Origin of the Peroneal . . . 152
65. Ligature of the Posterior Tibial Artery. Exposure of the Internal Saphenous and Posterior Tibial Nerves 153
66. Ligature of Peroneal Artery 154
67. Ligature of Dorsalis Pedis Artery. Exposure of Anterior Tibial and Musculo-cutaneous Nerves 156
68. Ligature of Plantar Arteries at their Origin from the Posterior Tibial Artery. Exposure of Posterior Tibial Nerve 157
69. Ligature of Plantar Arch and External Plantar Artery. Exposure of Plantar Nerve . 158
70. Technique of End-to-End Arterial Suture (Carrel) 160
71. Technique of End-to-Side Arterial Anastomosis (Cushing) 160
72, 73, 74. Osteoplastic Resection of the Manubrium Sterni 162, 163, 164
75. Ligature of the Long Saphenous Vein, below where it opens into the Femoral Vein . 169

SECTION III

Surgery of the Nervous System

FIG. PAGE

76, 77. Doyen's Burrs 174
78. Application of Elastic Band round Skull in Craniectomy 177
79. Lane's Forceps 179
80. Cushing's Temporal Operation of Trephining for Decompression . . . 180
81, 82. Cryer-Sudeck Burrs 181
83. Cushing's Cerebellar Operation of Trephining for Decompression . . . 182
84, 85. Doyen's Burrs 183, 184
86. Post-auricular Incision for opening the Mastoid Antrum, the Lateral Sinus, and the Descending Cornu of the Lateral Ventricle 187
87. Opening the Mastoid Antrum and the Lateral Sinus. Exposure of the Temporo-sphenoidal Lobe and Puncture of the Descending Horn of the Lateral Ventricle . 188
88. Ligature of the Middle Meningeal Artery 192
89. Exposure of both Cerebellar Lobes 196
90. Unilateral Exposure of the Cerebellum for the Removal of a Tumour in the Region of the Cerebello-pontine Angle 196
91. Cortical Areas of the Brain 197
92. Position of the Motor Areas in the Brain of Man (Krause) 198
93. Centres upon the Inner Cerebral Hemisphere (Horsley) 199
94. Author's Craniometer 200
95. Determination of the Chief Centres and Convolutions on the Skull by Author's Craniometer 201
96, 97. Osteoplastic Laminectomy 204, 205
98. Patient after Extirpation of Gasserian Ganglion 208
99. Exposure of the Gasserian Ganglion by the Temporo-sphenoidal Route . . 209
100. Excision of Gasserian Ganglion through an Angular Incision 211
101. Osteoplastic Exposure of the Orbit 216
102. Ramifications of the Facial Nerve (Bockenheimer) to illustrate Proper Direction of Incisions on Face 217
103. Ligature of the Supraorbital Artery. Exposure of Supraorbital and Infraorbital Nerves. Opening of the Frontal Sinus 218
104. Resection of the Second (Superior Maxillary) Division of the Trigeminal Nerve . 220
105. Exposure of the Second (Superior Maxillary) Division of the Trigeminal Nerve at the Foramen Ovale 221
106. Exposure of the second (Superior Maxillary) Division of the Trigeminal Nerve at the Foramen Ovale 223
107. Ligature of the Supraorbital Artery. Exposure of the Supraorbital and Infraorbital Nerves. Opening of the Frontal Sinus 224
108. Exposure of the Third (Inferior Maxillary) Division of the Trigeminal Nerve at the Foramen Ovale 225
109. Incision for resecting the Third (Inferior Maxillary) Division of the Trigeminal Nerve at the Foramen Ovale. Exposure of the Facial Nerve 226
110. Ligature of the Facial and Temporal Arteries. Trephining the Ascending Ramus of the Jaw to expose the Inferior Dental Nerve 228
111. Facio-hypoglossal Anastomosis (Frazier) 231
112. Ligature of the External Carotid with the Origins of the Lingual, Facial, and Occipital Arteries. Ligature of the Subclavian Artery 233
113. Exposure of the Spinal Accessory Nerve in the Middle of the Neck 234
114. Ligature of the Lingual, Common Carotid, Innominate, and first part of Axillary and Internal Mammary Arteries 235
115. Exposure of the Upper Three Cervical Nerves 237
116. Ligature of the Occipital Artery. Exposure of Great and Small Occipital Nerves . 238
117. Ligature of the External Carotid and Subclavian Arteries 240
118. Ligature of the Axillary, Brachial, Superior Profunda, and Subscapular Arteries. Exposure of Median, Subscapular, Musculo-spiral, and Circumflex Nerves . 241

FIG. PAGE
119. Ligature of Posterior Circumflex and Superior Profunda Arteries. Exposure of Circumflex and Musculo-spiral Nerves 242
120. Ligature of the Brachial, Radial, and Ulnar Arteries 244
121. Ligature of Interosseous Artery. Exposure of Median and Anterior Interosseous Nerves 246
122. Ligature of Superficial and Deep Palmar Arch with two Branches of Median Nerve . 247
123. Conduction Anæsthesia (Braun) of Finger (Spaltcholz) 248
124. Exposure of Ulnar Nerve at the Internal Epicondyle 249
125. Ligature of Posterior Circumflex and Superior Profunda Arteries. Exposure of Circumflex and Musculo-spiral Nerves 251
126. Exposure of Posterior Interosseous Nerve below Head of Radius and Dorsal Branch of Ulnar Nerve at Wrist 253
127. Ligature of Posterior Scapular Artery. Exposure of the 10th Rib and 10th Intercostal Artery and Nerve 254
128. Ligature of Common Femoral and Femoral Arteries. Exposure of External Cutaneous Nerves 256
129. Exposure of Great Sciatic and External and Musculo-cutaneous Nerves . . 258
130. Ligature of Popliteal Artery 260
131. Ligature of Posterior Tibial Artery. Exposure of Internal Saphenous Nerve . 261
132. Ligature of Plantar Arch, Internal and External Plantar Artery. Exposure of Internal and External Plantar Nerve 262
133. Ligature of Anterior Tibial Artery and Exposure of Anterior Tibial Nerve . . 263
134. Ligature of Peroneal Artery. Exposure of External Saphenous, Posterior Tibial, and Musculo-cutaneous Nerves 265
135. Ligature of the Dorsalis Pedis Artery. Exposure of Anterior Tibial and Musculo-cutaneous Nerves 266

SECTION IV

Surgery of the Extremities

136. Method of dividing Tendons 273
137. Method of suturing divided Tendons (Wilms-Siever Stitch) 273
138. Method of shortening a Tendon 273
139. Tenoplasty 274
140. Osteotomy for Hallux Valgus 281
141. Excision of the Anterior Tarsus 281
142. Incision for Excision of the Mid-Tarsus and Cuneiform Excision in Club-foot . 283
143-144. Excision of an Osseous Wedge in Club-foot 284
145. Excision of the Astragalus 285
146. Coronal Section through the Ankle-joint (Henle) 285
147. Excision of Os Calcis 285
148. Resection of the Posterior Tarsus 286
149. Incision for Arthrotomy of Ankle on Right Side 287
150, 151. Excision of Ankle 288
152. Resection of the Entire Tarsus (Wladimiroff, Mikulicz) 289
153. Result after Complete Resection of the Tarsus 289
154. Resection of Lower Third Leg (Brodnitz) 291
155. Resection of Lower Third of Leg 292
156. Osteotomy of the Femur. Cuneiform Osteotomy of the Tibia . . . 292
157. Incision for Arthrotomy of Knee 293
158, 159, 160, 161. Arthrotomy of the Knee 294-297
162, 163. Excision of the Patella 300
164. Osteotomy of the Femur. Cuneiform Osteotomy of the Tibia . . . 301
165, 166. Subtrochanteric Osteotomy of Femur 302
167. Incision for Arthotomy of Hip 303
168, 169. Arthrotomy of the Hip 304, 305

FIG. PAGE
170,171. Scoop for Reposition of Head of Femur in Open Operation for Congenital Dislocation of the Hip 306
172. Sprengel's Incision for Osteotomy of the Pelvis 307
173. Result after Excision of Hip and Innominate Bone for a Tumour of the Pelvis . 308
174. Excision of the Phalanges and First Metacarpal Bone 311
175. Excision of the Phalanges and Metacarpal Bones. (Coronal Section of the Wrist, after Henle) 311
176. Incision for Arthrotomy of the Elbow and Wrist 314
177, 178. Arthrotomy of the Elbow 315, 316
179. Excision of Elbow, showing Method of obtaining Rounded Ends of the Bones . 317
180, 181. Excision of the Head of the Humerus by the Anterior Oblique Incision . 320, 321
182-185. Arthrotomy of the Shoulder by Posterior Curved Incision . . . 322-325
186. Result after Excision of Shoulder for Tubercular Disease 326
187. Excision of the Scapula 328
188-192. Schemes showing the Evolution of the Different Methods of Amputation . 330, 331
193. Position of the Line of Suture by the Transverse Circular Incision . . . 332
194. Position of the Line of Suture by the Oblique Incision 332
195, 196. Method of performing the Transverse Circular Incision 333
197-199. Method of performing the Oblique Incision 333
200. The Lynn-Thomas Forceps 334
201-206. Skiagrams of Stumps after Amputation 336-340
207. Disarticulation of the Great Toe at the Metatarso-phalangeal Joint, and of the 2nd Toe along with its Metacarpal Bone; Amputation through the 3rd Toe, and through the 5th Metatarsal Bone 342
208. Disarticulation of all the Toes at the Metatarso-phalangeal Joints . . . 342
209. Disarticulation at the Tarso-metatarsal Joints 342
210. Lisfranc's Amputation (Dorsal View) 343
211. Lisfranc's Amputation (Plantar View) 343
212. Anterior Intertarsal Amputation (Jäger). Horizontal Section of Foot (after Heitzmann). 344
214. Posterior Intertarsal Disarticulation 345
215. Subastragaloid Disarticulation (Malgaigne, Textor) 346
216. Disarticulation at the Ankle-joint (Syme's Amputation modified) . . . 347
217. Guyon's Wave-cut for Disarticulation at the Ankle 347
218. Coronal Section through Ankle-joint (Henle) 347
219, 220. Disarticulation at the Ankle-joint by an Internal Flap 348, 349
221. Osteoplastic Disarticulation of the Foot (Pirogoff) 350
222. Amputation through the Malleoli 351
223. Amputations through the Leg 351
224-226. Osteoplastic Amputations of the Leg 352-354
227. Transverse Section through the Leg above its Middle 355
228. Disarticulation at the Knee-joint 356
229. Section through the Knee-joint at the Level of the Condyles of the Femur . . 357
230, 231. Amputations through the Thigh 358
232. Transverse Section through the Thigh 358
233. Amputation of Thigh through the Condyles (Carden) 359
234. Osteoplastic Amputation through the Condyles of the Femur (Ssabanejeff) . . 360
235. Osteoplastic Supracondyloid Amputation (Gritti) 361
236. Osteoplastic Supracondyloid Amputation (Gritti) by an Oval Incision . . 362
237. Disarticulation at the Hip, the disease affecting the Soft Parts in Front . . 364
238. Coronal Section of the Hip and Knee-joints (after Henle) 366
239. Disarticulation at the Hip-joint 366
240, 241. Lines of Section of Pelvis in Keen and Freeman's Cases of Amputation of Pelvis 369
242. Interilio-abdominal Disarticulation 370
243. Longitudinal Section through the Flexed Finger 372
244. Disarticulation of Fingers 372
245. Disarticulation of Middle Finger, Hand at Wrist-joint, and Amputation through Forearm 373

FIG. PAGE
246. Transverse Section through Upper Third of Forearm 374
247. Disarticulation at the Elbow-joint by a Circular Incision 375
248. Ligaments of the Elbow-joint 376
249. Disarticulation at the Elbow-joint. Longitudinal Section through the Elbow-joint (after Braune) 376
250. Amputation through the Upper Arm 377
251. Disarticulation at the Shoulder-joint 377
252. Disarticulation at Shoulder by Racket Incision 378
253, 254. Removal of the Upper Extremity together with the Shoulder Girdle . . 379, 380

GENERAL CONSIDERATIONS

INTRODUCTION

Compared with that of former times, the practice of operations on the cadaver has become a less important factor in the education of the surgeon in operative technique. Such practice must be supplemented by a thorough knowledge of operations on the living subject. But even that is not invariably sufficient, as a practitioner during an operation cannot satisfactorily discuss all the features of a case and the sometimes intricate details of the technique in an ordinary or even difficult emergency.

This want can be supplied by text-books. A text-book on operative surgery should include all that can be gathered from practice on the cadaver, and all that can be observed during operation on the living subject. It should, in addition, discuss the indications which point to the necessity of this or that operation, decide the choice of method, and, finally, explain the conditions which tend to secure a good result from operative interference.

We do not altogether share the opinion that operative training on the cadaver can be neglected by the clinical surgeon and relegated to a tutor with but little experience in operating. The performance of operations on the cadaver affords an excellent method of revising topographical anatomy, and is specially valuable to the student when supervised by an operator who is also an experienced clinician.

Some anatomists deserve the credit of having lost no opportunity of inculcating surgical anatomy in their text-books; but one feels that the pure anatomist may go too far in this direction and attempt to take up points which can only be dealt with by one possessing a practical experience of surgery. The interest of anatomists in surgical matters would meet with greater appreciation if they would enter into anatomical detail more fully than has hitherto been the practice.

Surgeons nowadays require a more accurate description of the course of the vessels and nerves than is contained in the majority of anatomical handbooks. At the present time we are called upon to do more than simply expose an artery at the seat of election for the purpose of ligaturing it. The veins, too, have to be ligatured, sutured, or excised. It is necessary also to possess an accurate knowledge of the course of even the smaller nerves, of the layers in which they lie, and of the regions in which they are distributed, as it is by injection into the nerves that local anæsthesia (conduction) is obtained.

The position, relations, and attachments of the organs are far too superficially studied by anatomists for us to content ourselves with descriptions from that source. It is, for example, still an undecided question how the normal kidney is held in position. This is surely a subject of inquiry for anatomy to decide first of all.

The surgeon must fall back on his own resources in determining the incisions which will produce least harm in opening into joints or in exposing some deeply-situated structure. Anatomical text-books give us little or no help in this matter, a manifest reason why there is still such a multiplicity of methods in use, all of them aiming at the same object. There is surely only one method that can be the best, namely, that founded on anatomical and physiological grounds. In this

work we shall restrict ourselves to describing certain operations as typical. We do not intend to compare all the alternative methods, merely because they have a famous man as sponsor. A young surgeon who has mastered the anatomical and physiological principles on which operative surgery is based, can readily draw his own conclusions as to the merits of different methods authorised or preferred by experienced surgeons, if he watches them operating on the living subject.

It is a very serious matter for patients if a junior surgeon disregards the necessity for method in operating. In operations on the face we have seen incisions used which damaged the facial nerve and inflicted on the patient an unnecessary lifelong disfigurement.

As we pointed out in the preface, it is even more reprehensible to undertake an operation without having established definite indications and instructions for its performance. Apart from giving an accurate description of individual operations, supplemented by intelligible illustrations, we consider it one of the chief requirements ot a text-book of operative surgery to afford full information on this point. Young practitioners often come straight from a course of operative surgery on the cadaver—generally a cram-course before an examination—without the slightest knowledge of the conditions which call for the performance of an operation.

SECTION I

GENERAL RULES

A. PREPARATION FOR OPERATION

(a) The Preparation of the Patient

It is evidently not the practice everywhere to prepare patients before operation, but it is certainly not always advisable to operate on the patient the day after admission. We were once consulted by a lady who informed us that ovariotomy had been performed on her twice, and that on each occasion she had made a very rapid recovery. She was suffering from an abdominal swelling of recent development. When we pointed out that it would be necessary to make a careful examination of her, and that she would have to be properly prepared for the operation, she became so impatient that she consulted another surgical authority, who next day performed a laparotomy. Within twenty-four hours we were present at the autopsy. It was found that she had been suffering from cirrhosis of the liver with ascites, and that there were extensive intestinal adhesions as a result of the previous "ovariotomies." The bowel had been incised. Both ovaries were found to be intact! She had thus been three times subjected to exploratory operations. This is an example of what may result from undue haste in operating on an importunate patient.

1. Preparation to be carried out in the Ward. Our ward staff are provided with printed instructions regarding the preparation of patients for special operations; and general instructions insure that every patient is properly prepared for the administration of anæsthetics, the prevention of accidents, and the conduct of an aseptic operation.

(1) Every patient should be made to take a bath, and submit to a thorough wash with soap and warm water. The head should not be omitted from the cleansing process, and the skin in the region of the operation should also be shaved.

There is no reason why every patient should not have the benefit of a vigorous cleansing from head to foot in the surgical sense of the term. If he is accustomed to pay attention to the skin in the British manner, he will be interested to know that his habits are in accordance with the methods of aseptic surgery. On the other hand, those who have always regarded washing as superfluous will find themselves quite rejuvenated after the unusual experience of a bath.

When the whole body has been surgically cleansed, there should be no trace of dirt about the scalp, nails, mouth, throat, or genitals. This washing process, which is carried out in a warm bathroom on the day before the operation, is to be preferred to the practice of some surgeons who apply antiseptic poultices to the skin at the site of operation. We regard the latter treatment as not devoid of danger, as poultices may give rise to skin-irritation and eczema. It is sufficient to wash the infected part

with soap and water, then with ether and alcohol to remove the fats, as an aseptic dressing has to be subsequently applied.

Antiseptic treatment of the skin is to be brought into operation when the skin is the seat of an eczema or other form of skin eruption. In these circumstances it is obvious that the wound cannot be treated on aseptic lines, and antiseptic treatment must be resorted to throughout. It is impossible to make an unhealthy skin aseptic in a short space of time.

Special care must be taken in cleansing parts of the body covered with hair, as shaving and scrubbing with a brush are indispensable aids.

(2) All accessible mucous membranes must be subjected to a process of direct cleansing similar to that applied to the skin.

Mechanical cleansing is of primary importance. Special attention must be given to the buccal and nasal cavities. All sordes and tartar must first of all be removed from the teeth, as otherwise it is impossible to keep the mouth clean. This performance may be undertaken by a dentist. The repeated use of a tooth-brush with soap and warm water is sufficient to cleanse the teeth, and prevent fur from accumulating on the tongue and gums. If an antiseptic must be used, salol or a weak solution of carbolic constitutes a suitable wash for the nose, mouth, and throat. Stronger solutions, by inducing excessive secretion, may do more harm than good. Crusts in the nostrils and deposits on the tonsils must be removed and the parts painted with iodine.

The disinfection of the mouth is a matter of so much importance in the prevention of pneumonia from aspiration during anæsthesia that it should never be neglected.

Besides the upper air and alimentary passages, the vulva, vagina, and rectum must have attention paid to them. All discharges should be removed by washing with soap and water, or alternatively by swabbing with a weak solution of lysol. Subsequent soiling can be prevented by repeated irrigation with warm water previously boiled, or with a weak aqueous solution of lysol.

There should be no difficulty in making the patient understand that the cleansing must not be made illusory by inoculating the prepared region with possibly infected hands.

No patient should come to an operation with a full bladder or rectum. On the morning of the operation a warm soap and water enema should be administered: the patient should empty his bladder, and when necessary a catheter should be employed.

(3) The intestinal canal must be emptied. The bowels, however, should not act more than twice in the twenty-four hours previous to the operation.

Many surgeons dispense entirely with preliminary purgation. The reason for this is quite intelligible. The worst condition of all is when the patient is suffering from an artificial diarrhœa at the time of operation. It has been shown that when an aperient is given the number of bacteria increase as the intestinal contents become more liquid, while they only diminish in a material degree with the abatement of the diarrhœa. It is important, therefore, that the action of the purgative should have ceased by the day of the operation. Soiling of the body will thus be avoided.

Two days before the operation the patient is given either 1 to 2 tablespoonfuls of castor oil or a dessertspoonful of natural Karlsbad salts in a glass of warm water. The nature of the subsequent diet is important: it should consist of meat rather than eggs. Fluids may be freely taken. Vegetables and carbohydrates (with the exception of sugar) are to be avoided. In adults we allow practically no milk, as it produces copious stools. In operations on the alimentary canal, it is safer for some time previously to limit the diet to artificial foods such as tropon, or fluid somatose.

When the intestine has been emptied as far as possible, an intestinal antiseptic should be given to limit decomposition and gas formation. We prefer subnitrate of bismuth (6 gr. six times daily). This imparts a black colour to the motions, and removes the offensive smell in a remarkable manner.

2. Preparation by the Medical Attendant. (4) A thorough examination must be made of the respiratory organs, and special attention should be given to the treatment of any existing bronchitis.

The lungs, if already the seat of bronchitis, are only too liable to develop broncho-pneumonia. The aspiration of solid substances and bacteria during anæsthesia, the influence of the ferments of hæmorrhage, small emboli, or finally impairment by the anæsthetic of the epithelium of the lung, individually or collectively, tend to the production of this condition—broncho-pneumonia,—which not infrequently proves fatal. If the operation cannot be postponed till the bronchitis is cured, it is advisable to administer creosotal. Our former assistant, Dr. Rollier, who has carefully investigated the action of this drug for some years, has shown that it prevents complications and acts beneficially on the course of a pneumonia.

We do not hesitate to give large doses of creosotal when necessary. $2\frac{1}{2}$ dr. may be administered night and morning in the form of an enema with milk. The dose has occasionally to be increased to one ounce at the onset of pneumonia, followed by a stimulant such as camphor-benzoate.

Sluggishness of the pulmonary circulation, which does not yield to treatment, is one of the worst complications as regards the anæsthetic and adds considerably to the risk of an operation. It is dealt with in the following summary :—

(5) Preparation as regards the circulatory system. The importance of the condition of the heart with regard to the administration of an anæsthetic is known to every surgeon ; but there is considerable diversity of opinion as to the application of the anæsthetic. Many practitioners do not hesitate to anæsthetise a patient who is the subject of heart disease, because they have found such patients inhale the anæsthetic innocuously ; and it is a matter of common occurrence to find that patients affected with valvular disease of the heart and irregular cardiac action can undergo an operation with as satisfactory results as those who are physically more fitted for the ordeal. Everything depends, however, on the extent to which the heart is competent to cope with any increased demands which may be made on it, additional to that exerted by the action of the anæsthetic and possibly that of the antiseptics. A cardiac examination to ascertain if the increased strain is able to be met is of no little importance.

When a heart lesion is fully compensated, and a moderate amount of exertion fails to excite any untoward symptoms, operative interference can be safely undertaken under a general anæsthetic. Marked venous congestion, even without any discoverable cardiac lesion, indicates a much more serious condition. We have not infrequently seen cases, for example, of obstruction caused by enlargement of the mediastinal glands producing signs of œdema of the lung by interference with the pulmonary and general circulation.

Katzenstein [1] has described an effective method of testing the function of the heart prior to operation. He puts a considerable force of resistance in the course of the circulation and observes the resultant effect on the action of the heart. In a normal heart, the functional activity is maintained without any increase, usually with a decrease, in the heart's contraction. Insufficiency, on the other hand, is shown by an increase in the pulse-rate with a fall, instead of a rise, of blood-pressure after compressing both external iliac arteries at Poupart's ligament for a space of from $2\frac{1}{2}$ to 3 minutes.

We had once an interesting case of atheroma of the coronary arteries in a woman who suffered great distress after sudden movements, and died suddenly a week after she had been submitted to examination. Here the insufficiency of the heart muscle was indicated by a marked diminution in the pulse-rate whenever the patient raised herself in bed on several occasions. In Basedow's disease it is a frequent and noteworthy symptom to find a considerable increase in the pulse-rate when greater demands are made on the heart.

Considerable alteration in the frequency of the heart's contractions under increased strain affords a valuable means of forming an opinion on the efficiency of the action of the heart, in cases of dilatation, in cases with toxic changes in the heart muscle, in Basedow's disease, and in infective diseases, in cases with atheromatous changes in the coronary arteries and their results, and especially in cases distinguished

[1] *Deutsche med. Wochenschrift*, 1904, 22.

by the presence of fatty heart. A practitioner not infrequently sees death occur with unaccountable rapidity in connection with somewhat prolonged anæsthesia and severe operations in stout people, chiefly as the result of impairment of the heart muscle by poisons and ferments both during and after the operation.

The Riva-Rocci apparatus is an indispensable means of estimating the blood-pressure. When it is applied during rest as well as after exertion, an even better indication is obtained of the efficient action of the heart. By the simultaneous use of the Riva-Rocci apparatus and the sphymograph we find the average pressure in robust individuals corresponds to 150 mm. Boari [1] puts it at 120 to 140 mm. In any case a blood-pressure over 160 mm. is to be regarded as high, and one below 110 mm. as the reverse.

The use of the Riva-Rocci instrument not only gives us valuable information regarding the strength and resistance of the heart but also indicates the state of the vasomotor centre. We have twice seen patients with slight manifestations of Addison's disease die suddenly, where a preliminary estimation of the blood-pressure might have induced the surgeon to pause in his endeavour to bring the operation to a successful issue.

The condition of the veins must also be examined before an operation is undertaken, so that sudden accidents from this source may be prevented. Careful attention must be paid to varices and thromboses in the lower extremities, as the production of thromboses and emboli is assisted by the action of the anæsthetic, the fixation of the patient during the operation, and the position subsequently assumed, as well as by the action of blood ferment and other poisons.

Lennander has emphasised the necessity of elevating the legs in the cases we have instanced. It is even more important to see that constriction of the lower extremities by straps is avoided and that the legs are not allowed to be left in suspense during the operation. The legs must be massaged while the patient is in bed, and completely swathed in firm flannel bandages before a foot is allowed to be put on the ground.

(6) Preparation with reference to the function of the urinary organs. We have already alluded to the necessity of the nurse observing that every patient's bladder is emptied before operation.

The efficient action of the kidneys must also be estimated by cryoscopy of the blood and urine. Since Koranyi's important discovery, this is recognised as an essential item in surgical operations.

The kidneys play so important a part in the elimination of all poisons present in the blood during or after operation, even if they are only due to the anæsthetic or derived from the absorption of effused blood in a purely aseptic case, that the assurance of the patient's progress to recovery can only be certified when the kidneys are found to be acting efficiently. A thorough examination of the urine must always be undertaken by the assistant before every operation.

It is advisable to stimulate the kidneys by administrating fluids by the mouth, and by subcutaneous or rectal injections of normal saline, in order to ensure a rapid excretion of the toxic products that have been set free in the tissues as the result of the operation or the matter administered.

(7) Lastly, there are a few general conditions which must be regarded as contraindications to operative interference.

Besides such pathological conditions of the blood as pernicious anæmia and leucæmia, diabetes, Addison's disease, the status thymicus and lymphaticus are some of the most frequent causes of sudden accidents after operative interference. In these cases the operation can only be safely undertaken after the patient has undergone prolonged treatment specially adapted to the condition, *e.g.* the treatment which has been carefully studied and described by Kausch for diabetes (pushing sodium carbonate till the reaction of the urine is alkaline) which, *mutatis mutandis*, is no less indicated in certain anæmias, Addison's disease, Basedow's disease, and status lymphaticus.

[1] *Gazz. d. osped.*, 1902.

(b) Preparation of the Operating Room

The surgeon will be saved every difficulty if he follows our advice and operates only in well-appointed rooms. It is, however, advisable to consider what should be done when one has to operate in a room which is used for other purposes.

(1) The room must be completely cleared of all pieces of furniture (including the chandeliers and curtains) which are not required for the operation. All articles that cannot be removed, *e.g.* stoves, fireplaces, etc., must be covered with large damp cloths. The floor and walls are to be washed with soap and hot water and the ceiling is to be whitewashed. After satisfactory ventilation and purification have been ensured, the room should be closed till the performance of the operation.

The disinfection of a room preparatory to operation may have far-reaching results. No one would ever select a room in which there had been a case of infectious disease. Disinfection of the walls with sublimate, carbolic, or formol necessarily gives rise to vapours which must act injuriously on the patient during a long operation.

We were once asked to operate in a room which had been so thoroughly disinfected with formol that it was almost impossible to breathe in it even after a thorough course of ventilation. The effect of such an atmosphere on the lungs of an anæsthetised patient can be well imagined.

Mechanical cleansing is all that is required, but it must be of a thorough nature. For an ordinary room, scrubbing with soap and hot water, or with bread (Esmarch), is more effective than disinfecting with corrosive sublimate. The chief matter for attention is that no dust should be left which can be disturbed and fall on the operating table or dressings. It is therefore sufficient if the tables and chairs which are to be used are washed with soap and hot water. Disinfection by means of antiseptics is only harmful. Before any piece of furniture is brought into use it must be completely covered with sterilised towels.

One thing must be understood, and it is this—the room is to be emptied, thoroughly washed from corner to corner, including all cornices, ledges, etc., and must be then closed.

(c) Preparation by the Assisting Staff of the Materials required for Operation

The knowledge that all infective germs can be destroyed by sufficient boiling, and that all materials which have been effectively boiled are rendered sterile for surgical purposes, has enormously simplified the preparations for an operation.

The nurse who is entrusted with the preparations has to be informed that all the materials which are to be used in an operation are to be previously boiled for a time ranging from ten minutes to two hours, or, as an alternative, are to be placed in a current of steam.

(1) In the first place a large number of sterilised cotton sheets are necessary, a number sufficient to cover completely all the furniture in the operating chamber.[1]

If one is not sure that, in spite of washing, dirt will not be forced through, "impermeable" washed in lukewarm water must be placed under the cloths.[2]

Similarly the clothing both of the patient and of all those taking part in the operation must be cased in sterile coverings so that only those parts—such as arms, hands, and face, which can be thoroughly washed, are left uncovered. In operations about the head and face, the scalp and beard must be shaved, so that no hair can come in contact either with the instruments or the wound. The scalp should be covered with a boiled rubber cap over which a sterile bandage should be applied, to prevent any hair from appearing round the edges.

[1] Our large cotton cloths and cloaks, when not sterilised by steam, are boiled for an hour and a half in water which has already been boiled for half an hour. After use they can be immediately washed out in tepid water, then in soap and water, and then in soap and soda lye, and boiled in this for half an hour, washed out with hot water, then with cold water, and afterwards dried.

[2] "Impermeable" does not withstand the action of hot water.

The patient's face must be concealed by means of a screen (Fig. 1), *i.e.* a cloth suspended from a nickel-plated hoop such as we first introduced for use in goitre operations. "Drop" infection (Flugge) is thereby prevented should the patient vomit, cough, or sneeze. The most effective screen is composed of cloth, lined with wadding, so that no deleterious matter can obtain an entrance. This is as important a precaution as enveloping the head and face of the surgeon in a mask like that of a Turkish woman. An operative mask is only effective when the mouth is covered with a layer of wadding (Mendes de Leon [1]). If the surgeon is suffering from a cold, he should protect his nose and mouth effectively with wadding (Leon's helmet).

We have often been interested in watching an operation where the surgeon was covered up to the eyes, while his assistants, who were charged with the supervision of instruments, swabs, and ligatures, and for whom surely masks were still more necessary, were unprovided with so important a paraphernalia. In such a case it is

Fig. 1.

plain that the risk of infecting the wound by speaking or coughing has not been properly appreciated.

(2) All compresses, swabs, and bandages which come in contact with the patient, as well as the gloves of the operator and his assistants, must be boiled for an hour and a half, or sterilised by steam, previous to the operation. They should be boiled in small separate bundles, only to be opened immediately before use. Swabs and muslin compresses should be boiled in ·75 per cent physiological salt solution.

The operation sister should be trained to pack the bundles so that, by simply unfolding the wrappings immediately before the operation, the contents can be spread out at once in proper order on an aseptic surface. The sheet for spreading on the tables should be packed on the outside of the bundle, which contains separate packets of large and small gauze dressings, swabs, gloves, drainage-tubes, threaded needles, and instruments.

[1] Langenbeck's *Archiv*, Bd. 72.

(3) The necessary instruments are sterilised in a separate compartment of a Schimmelbusch or other steriliser (Braatz, Skirving), and previous to use are laid out on the sterilised cloths, with the basins at hand. The knife is wrapped up so as not to blunt the edge.

When one has no special apparatus, the instruments are wrapped in gauze and packed like the dressings, so that they may be properly laid out when the coverings are undone. The instruments, which should be kept entirely free from dust, are best boiled in a 2 per cent soda solution or in 2 per cent solution of borax, the latter treatment, however, causing a white deposit to appear on them. If they cannot be removed from the steriliser immediately before the operation, the instruments should be left wrapped in the gauze in which they were boiled, or the outer wrapping should be further covered with sterile gauze. After an operation the instruments must be washed in soda and water, afterwards in hot water, and finally dried.

The knives, which ought to be made perfectly smooth, may be simply immersed in strong lysol, washed in absolute alcohol, and dried with sterile gauze.

(4) Sutures, after having the fats removed by soaking for twelve hours in ether and twelve hours in alcohol, are boiled for five minutes in a 1 per cent solution of perchloride of mercury, loosely wound on spools with clean hands protected by sterilized towels, and placed in fresh perchloride in which they are again boiled for ten minutes before use. Glass is cleansed with absolute alcohol. The sutures are best left in the solution in the glass vessel in which they were boiled. To avoid the trouble of threading needles at the operation, they may be threaded beforehand, arranged in order, and wrapped up in one or two layers of sterile gauze. They are again boiled for a minute in perchloride, and are then laid on the table still wrapped in the gauze in which they were boiled. The operator himself unrolls the gauze and takes the threaded needles one after another as they are required. Ligatures may be dealt with in a similar manner.

Every theatre nurse must be taught that she may only handle sutures with perfectly clean hands and sterilised gloves. It is difficult to thread needles with rubber gloves.

The surgeon and his assistants must exercise equal care, and never handle the sutures without putting on gloves; boiled rubber gloves with cotton gloves over them are the most serviceable.

(5) Drainage-tubes, like the sutures, are boiled for ten minutes in 1-1000 perchloride, in which solution they are retained and from which they are lifted direct previous to use. When this is not practicable, they should be wrapped in gauze before the operation and boiled or steamed for one minute. The surgeon himself then unrolls the gauze and lays it on the sterilised sheet covering the table.

(6) Preparation of sterile physiological salt solution. A ·75 per cent salt solution is prepared beforehand by boiling for an hour in a kettle with an overhanging lid. If there is no suitable vessel at hand for preparing large quantities of solution, the apparatus in which the saline has been boiled must be rendered dustproof by an immediate covering of boiled cloths. Part of the saline should be prepared some time beforehand and allowed to cool, so that the lotion may be used at a proper temperature.

If no suitable apparatus fitted with a stop-cock is available, a ladle with which to serve the lotion must be boiled and kept immersed up to the handle.

B. THE BEGINNING OF THE OPERATION

(d) The Position of the Patient

All well-appointed clinics and hospitals are now furnished with operating tables the segments of which can be raised or lowered so as to alter the position of the body. Many tables, however, do not always fulfil the equally necessary condition of placing the patient in a comfortable position.

To attain this end, it should be possible quickly and easily to secure the legs above the knees, to place the arms and hands close to the body and fasten them securely without hurting the patient. This position of the hands and arms is specially advocated by Rothe of Breslau in order to prevent anæsthetic paresis, and we agree with him that it is advisable that the arms should not be fixed above the head.

In addition, the Trendelenburg position must be readily available, for in many laparotomies it is necessary to displace the intestines upwards towards the diaphragm. This is the chief value of the Trendelenburg position, but there are other important points in its favour.

During anæsthesia, when laryngeal reflex is abolished, it is of importance to prevent saliva, blood, and other extraneous matter from being conveyed into the lungs. All fluids should gravitate to the pharynx and mouth, from which they can readily escape or be removed. Elevation of the pelvis is therefore of special value in preventing aspiration pneumonia in operations in the region of the mouth, pharynx, nose, and larynx.

The Trendelenburg position has the additional advantage of preventing cerebral anæmia when the blood-pressure has been reduced either from severe loss of blood or by the use of an anæsthetic such as chloroform. Its advantages are so evident that the Trendelenburg position has frequently been overdone, especially by gynæcologists.

One occasionally sees the position adopted in operations with the patient suspended almost vertically. Kraske has drawn attention to the dangers of so exaggerated a Trendelenburg position. That a man cannot be expected to stand on his head for half an hour to an hour without his circulation being seriously affected is obvious to any one who has a knowledge of the mechanics of the circulation, and who has witnessed the copious venous hæmorrhage associated with a dependent position of the head, as in Rose's operation.

Kraske instances two cases of death occurring from strain thrown on a heart already weakened as the result of myocarditis, without the use of chloroform. Eiselsberg and Duhrssen have also observed apoplexy result from the employment of the high pelvis position. An operator must therefore be careful not to elevate the hips without due consideration in patients who are obese, or who have disease of the heart or vessels (arteriosclerosis). Such patients, apart from those under operation, can often obtain sleep without respiratory embarrassment only when the head and shoulders are elevated.

Further, in obese persons, Kraske has pointed out that the fat-laden omentum may slip upwards, and by interfering with the portal circulation give rise to hæmorrhage into the stomach. It may also be responsible for intestinal obstruction by dragging on the colon, of which he has seen one fatal case. The omentum should always be replaced after a laparotomy even when the patient has been occupying the ordinary position during operation.

The position in which the shoulders are raised and the feet lowered is of less frequent necessity. We regularly employ this position in operations on the thyroid, while Horsley recommends it for operations on the skull and brain, its object being to diminish the hæmorrhage from the veins in the head and neck.

Elevation of special parts of the body is frequently of great assistance during operations, especially those on the gall-bladder, stomach, and pancreas, when the epigastric region is raised, and in kidney operations, when the loin is elevated.

Proper precautions must always be taken to keep the patient's body warm, for which purpose we use a table heated by hot water. Krönig conveys heat directly to the patient by means of sixteen electric lamps placed under the operating table. Henle has shown experimentally the prejudicial effect produced by cooling of the body during an operation.

To avoid this loss of heat by overheating the scene of operation as was formerly done cannot be recommended, because there is too great a variation in the temperatures of the operating room, the corridor, and the bedroom. It is also inadvisable for the surgeon and his assistants to operate in an atmosphere charged with moist heat like that of a Turkish bath.

An operating table must satisfy the following conditions:—To warm the patient directly; to change rapidly the position of the whole or of special parts of the body; to prevent the constriction of any part of the body, especially of the lower extremities; and lastly to give comfort to the patient.

The position of the patient after operation will be considered in the chapter on after-treatment.

(e) Asepsis of the Patient and Operators. The Final Cleansing

The following recommendations apply only to those who enter the operating room as scrupulously clean as if they were entering a drawing-room. The patient is prepared the day before the operation as we have described. The surgeon and his assistants have already bathed and washed and guarded themselves from all possible sources of infection. Everything necessary for disinfection must be carried out previous to the operation. The operator and his assistants must disinfect their hands immediately after contact with infective matter, such as fæces, mucous secretions, saliva, etc., which should be effected before the hands become dry by immersing them in an antiseptic, and afterwards washing them thoroughly with soap and water.

This is the explanation of our dictum that gloves should be worn in the intervals between operations and should be removed before an operation, by which means contact with infective matter will be prevented. But when such matter has touched the skin, it must be removed immediately and thoroughly.

With these precautions, the final cleansing is initiated by washing all parts of the body that are left exposed, especially the face, eyebrows, beard, and hair. The teeth must be brushed with soap and water, and the mouth, pharynx, and nose syringed with sterile water or a weak antiseptic ($\frac{1}{4}$ per cent carbolic). The hands and arms are again washed with soap and water, and then scrubbed under a somewhat warmer stream of water, without the soap.

The chief fault at this stage is that sufficient care is not ensured that the assistants, nurses, and the patient are as thoroughly purified as the surgeon himself. It is not sufficient to purify the patient's skin only in the area of the operation: every part that is not entirely covered must be as carefully cleansed. Further, it is remarkable how many people at the present day refuse to be convinced that dirt can be really and readily removed by means of simple running water.

In conclusion, the reprehensible practice of using nail-cleaners must be abandoned. The nails can only be thoroughly cleaned when they are cut so short that there is no recess between them and the pulp of the finger. It is then as easy to clean them with a nail-brush and soap as it is to wash the rest of the hand.

When the hands have been thoroughly scrubbed with a nail-brush and soap under a stream of warm water, they are afterwards washed and scrubbed in warm sterile saline solution, and finally cleansed with alcohol, which removes fat, and which, as K. Fett[1] has shown, has a more penetrating action than watery solutions. By the drawing of a swab soaked in ether over the skin, even after it has been thoroughly washed with soap and water, a stain will always be found on the gauze. It is more advisable, therefore, to cleanse the patient's skin with ether after it has been washed with soap and before alcohol has been applied. The surgeon's hands should be thoroughly scrubbed with a brush in 85 per cent alcohol (Ahlfeld uses 96 per cent, while Leedham Green recommends 70 per cent as the most useful strength), after which they should be dried with sterile gauze. The hands should not be washed in sterile water after the ether and alcohol have been used, as the process interferes with the action of the alcohol. Fig. 2 illustrates the stand we have used for many years, which enables us to do our necessary ablutions under a stream of alcohol and sterile water. We would direct attention to the small rubber caps attached to the upper jars, which are slipped over the stop-cocks when they are

[1] *Zeitschrift f. Geburtshilfe*, Bd. 47.

opened and shut. The brushes, like the rubber caps, are kept immersed in 5 per cent carbolic solution in one of the three basins.

Antiseptics do not come under survey in an aseptic operation. They are no more effective than the method of cleansing we have described, and they are often responsible for their toxic effects and causation of eczema. Soaking the skin of the patient and of the operating staff in corrosive sublimate, carbolic, or iodine is only to be adopted when previous preparation has been omitted, or when the disinfection is considered to have been incomplete. This will be discussed in a later chapter.



FIG. 2.—One of the glass vessels contains five litres of warm sterile saline solution, the other is filled with 85 per cent alcohol. Each has an empty basin under it. The third basin contains the nail-brushes in 1-20 carbolic solution. In the small dish, the rubber caps, which are fitted over the glass vessels, are kept in 1-20 carbolic when not in use.

During the course of the operation the hands should be frequently dipped in warm sterile water to remove any blood, and washed in 50 per cent alcohol. If the latter solution is too strong and affects the skin, 25 per cent alcohol, as proposed by Schlaffer, may be used instead, the hands being afterwards dried with sterile gauze.

It is necessary to use corrosive sublimate, carbolic, or lysol only in case of the hands becoming infected with pus, the contents of viscera (fæces), or secretion from a mucous membrane. Then, the employment of an antiseptic is necessary, but it must always be afterwards removed from the hands with sterile water. As it is impossible to foresee such cases of infection, it is advisable to protect the hands with rubber gloves, which can be dipped in an antiseptic from time to time and then rinsed in sterile water.

Whenever a ligature has to be applied, it must only be handled with sterilised gloves. Cotton gloves are useful for this purpose, and are much more pleasant to work with than those made of rubber, especially when the fingers have to be utilised for inserting the needle. The gloves should be donned after the bleeding has been arrested and the hands have been cleaned. By this means the ligature is prevented from coming in direct contact with the skin of the surgeon or that of his assistants.

(f) Anæsthesia

1. *General Anæsthesia.* It is assumed that a thorough examination of the patient has been made prior to the administration of a general anæsthetic. If there are any contraindications to a general anæsthetic, local anæsthesia must be employed, or if the former has to be administered, the attendant risks must be carefully considered. All conditions in which the circulation or respiration is seriously affected are to be regarded as contraindications.

Mikulicz[1] has given an admirable account of these conditions. His views and ours are in complete correspondence. General anæsthesia is dangerous in all cases of heart disease where the efficiency of the cardiac muscle is seriously impaired. Cardiac

[1] *Deutsche Klinik*, 1901, von Leyden und Klemperer.

lesions that are fully compensated, and functional disorders are not so dangerous as a fatty degeneration of the heart with myocarditis and a weak irregular pulse.

We would lay more stress, however, than Mikulicz does, on the dangers of those conditions of the heart and lungs which are associated with chronic venous congestion, accompanied by œdema and cyanosis. Included in these are certain cases of dilatation of the heart, especially of the right side, marked emphysema, narrowing of the thoracic cavity by tumours, effusions, and notably empyema. Further, a general anæsthetic is dangerous in all conditions in which the blood pressure is seriously reduced, *e.g.* in Addison's disease, severe anæmia, and an advanced stage of Basedow's disease.

Auto-intoxications and general disturbances of nutrition are contra-indications to the introduction of a new poison in the form of the anæsthetic. Sepsis, by producing fatty changes in important organs, must receive particular consideration in this respect. Diabetes, Basedow's disease, the status thymicus and lymphaticus, as well as all renal conditions characterised by a diminished excretion of urinary solids, are cases in which a general anæsthetic involves a certain amount of risk.

In short, a general anæsthetic should not be administered if the patient is suffering from any serious impairment of the circulation or respiration, or from a toxaemia, either of an acute or chronic nature.

If attention be paid to the above contraindications, and care be taken to see that the stomach is empty,[1] and the patient's body kept warm, anæsthesia with ether (if we assume it is properly administered) presents no risk of an accident. The result may be otherwise with chloroform, however. Not long ago we were asked to operate by one of our colleagues, an able and busy practitioner, who, in spite of our objection, insisted on giving the patient chloroform, because in all his long experience he had never had a death resulting from its administration. The patient, however, died before the commencement of the operation.

Yet in many places chloroform is almost exclusively employed. In a small town where we had a recent operation, the use of chloroform had to be resorted to, as there was no practitioner at hand who had any knowledge of ether administration.

Inexperienced anæsthetists are inclined to give too much ether, while debarring the admission of a necessary amount of air. We hold with Mikulicz, Hofmann, Sudeck, Koblank, and others, that the suffocation method of giving ether should be abandoned in favour of administering it in small doses with free access of air. The disadvantages accompanying the administration of ether, such as excitement, cough, and severe salivation, will then disappear.

Given according to Hofmann's drop method, *i.e.* where it is dropped on a mask simply covered with gauze (with no waterproof material), the administration of ether becomes as easy as that of chloroform. Sudeck has shown that ether intoxication [2] is by this means rapidly produced, and that during this period of analgesia, which appears before the stage of excitement and previous to the complete loss of consciousness, a minor operation can readily be performed. Sudeck recommends the use of Czerny's mask, which consists of a cylinder open at both ends with several layers of flannel stretched across it, into which are poured 1 to $1\frac{1}{2}$ ounces of ether. The patient is requested to make deep inspirations, and the mask, to which a pneumatic face-piece has been attached, is placed over the nose and mouth, when after a few inspirations the intoxication stage occurs. By this method, however, a very small quantity of air is at first admitted, so that the question arises as to whether asphyxia, to some extent, is not produced. When the stage of excitement appears, the mask should be at once removed, at which stage Kronecker takes the mask away and begins the operation.

[1] It is absolutely necessary to empty the stomach before an anæsthetic is administered. We recently saw a patient die of suffocation when this precaution had been omitted, a sudden attack of vomiting of a large quantity of the contents of the stomach leading to "aspiration."

[2] Joteyko and Stefanowska (*Dissociations des phénomènes de sensibilité, etc.*, Acad. royale de méd. de Belgique, 1902) have shown that analgesia commences much earlier than the loss of any other sensation and continues for a longer period.

This method, though entirely unattended by danger, has the disadvantage of not inducing sufficiently-deep anæsthesia in many patients, especially in males and others of an excitable temperament. It cannot be maintained that "ether-intoxication" produces anæsthesia when the patient is only enjoying pleasant dreams and when he makes vigorous ejaculations. Witzel and other surgeons who favour the drop-method employ, as a matter of fact, a mixed anæsthesia.

Witzel and Hofmann administer an injection of morphia ($\frac{1}{6}$ to $\frac{1}{2}$ grain) one hour previous to the operation, and a larger dose if the patient has become inured to the drug. Witzel's uniformly-good results have to be attributed to the addition of the morphia. Kuttner [1] also, who is accustomed with success to operate under simple ether-intoxication (in Braun's clinic), regards "the combination of ether and morphia" as essential. As Witzel very properly remarks, Nussbaum's method of producing morphia-chloroform anæsthesia does not correspond with his own method since he (Witzel) gives the morphia one hour previous to operation, as recommended by Riedel and practised by Juillard.

A mixture of chloroform and ether can also be employed. Whenever it is evident that the necessary degree of anæsthesia cannot be obtained by means of ether alone chloroform should be administered in drops. Kionka [2] refers to the experiments of Honigmann and Kochmann, which show that the anæsthetic properties are materially raised when the two anæsthetics—chloroform and ether—are combined. Willy Meyer,[3] on Weidig's authority, asserts that when ether and chloroform are mixed, a new chemical compound is produced which has a special molecular weight of its own. The addition of 20 to 30 drops of chloroform is sufficient to induce sleep during the administration of the ether. After a single experience of the method, we cannot recommend it as entirely free from danger. The only fatality attributable to administration of the anæsthetic which we have had in the course of private practice during thirty-five years occurred when chloroform was used because the anæsthesia produced by ether was not sufficiently deep.

When the combination of chloroform and ether is to be employed, it is necessary to follow Braun's advice and use either his own or the Roth-Dräger oxygen apparatus (Fig. 3), which prevents the administration of the anæsthetic in too concentrated a form. In a review of Dumont's handbook on anæsthesia,[4] Rose declares that the introduction of Junker's apparatus is the most important advance that has been made in the matter of anæsthetics.

On the authority of Honigmann's preliminary work, Braun emphasises the fact that dilute ether vapour does not produce cyanosis or stimulate the secretion of saliva or mucus. The latter results only occur when concentrated ether is used. With his apparatus, which is adapted for the alternate or simultaneous administration of ether and chloroform, Braun estimates that on every occasion on which the bag (which holds 500 c.cm. of air) is emptied on inspiration the air the patient breathes contains 1·7 per cent of chloroform or 6 per cent of ether.

A great advantage of Braun's apparatus (Fig. 3) is, that by the addition of a catheter it can be used at once in all operations connected with the nose, mouth, jaw, and pharynx. Both Rose and the author (with Arnd's apparatus) drew attention to this fact so far back as 1878.

Finally, there is another anæsthetic of a mixed nature to be considered, viz. that in which ethyl bromide is used as a preliminary to the administration of ether. We are well aware that deaths have occurred from the use of ethyl bromide, but they scarcely outnumber the fatalities for which ether is responsible. Witzel has described in full detail a fatal case which occurred in the practice of one of his colleagues. It is a significant fact, however, that we have never had a single accident in the thousands of cases in which ethyl bromide was used to induce the anæsthesia. We will certainly never dispense with its use, and we regard it as a less dangerous

[1] "Operation in Ätherintoxication," *Beitr. z. klin. Chir.* Bd. 35.
[2] *Deutsche Klinik*, v. Leyden und Klemperer, 1903.
[3] *Journal of the American Med. Association*, Feb. 1903.
[4] "On Mixed Anæsthesia with Ether and Chloroform," *Munch. med. Wochenschr.* Bd. 20, 1901.

method than that of administering chloroform in unmeasured quantities. A recent death in the Canton of Bern was attributed to the use of ethyl bromide in the case of a child affected with status thymicus.

The use of ethyl bromide calls for a closer attention to contraindications than does that of ether alone, but the same demand applies to the use of every mixed anæsthetic, such as morphia, but more especially chloroform. It is satisfactory to note that it is unnecessary to administer a mixture instead of pure ether when dealing with children or feeble anæmic patients, who can be readily brought under the influence of the latter anæsthetic. It is only in cases where the action of pure ether is not efficient, when administered to powerful men or excitable persons with a high blood-pressure, that ethyl bromide provides an excellent means of inducing rapid and quiet anæsthesia.

Many years ago we recommended, and for a long time made it our practice, that the anæsthesia should commence with chloroform and be continued with ether, in order to bring on sound sleep rapidly in strong and resistant patients, who constitute a large number of those who come under operation; for—as Braun has proved—once anæsthesia is obtained, the majority of patients can be kept under its influence by merely giving small but repeated administrations of ether. We are now convinced that it is safer to induce the anæsthesia with ethyl bromide than with chloroform.

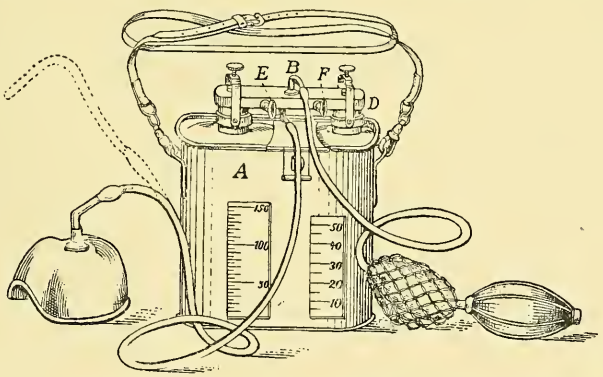

FIG. 3.—Braun's apparatus for the administration of chloroform and ether.

It may be mentioned that one of the last deaths we had under chloroform occurred in an old woman who had previously received an injection of morphia. In this case the aggregation of the poisons seemed to be responsible for the fatal effect of a minimal dose of chloroform administered in drops.

Witzel, in whose method morphia is the chief agent, has adopted and even exaggerated our practice of giving stimulants before operations. One or two hours before operation he gives a rectal injection of strong tea with red wine and brandy, one ounce of each with five to six drops of opium, or about a quarter of a wineglass of brandy to the same quantity of tea and wine. For many years it has been our practice to give a small cup of tea with brandy half an hour or an hour before the administration of the anæsthetic. With the same object Lennander gives a hypodermic injection of 1 mg. ($\frac{1}{64}$ gr.) strychnine nitr. and 2 g. (35 drops) of camphorated oil (1 : 4) half an hour before the operation. Poncet also gives a subcutaneous injection of brandy (with one-third to two-thirds of water) during the operation; while Kümmel gives large doses of brandy.

The anæsthetic should be administered with attention to the following conditions: The patient, if he has been properly prepared—if his stomach is empty, and the mouth and pharynx have been disinfected—is placed upon the table, care being taken to see that cooling of the body is prevented and that respiration is quite unimpeded. About three quarters of an hour before the operation he is given half

a cup of tea, with two tablespoonfuls of red wine or brandy, which, in the case of alcoholic subjects, is perhaps best administered by the rectum, after Witzel's method. It is only in the case of powerful adults that we give a hypodermic injection of morphia ($\frac{1}{6}$ to $\frac{1}{2}$ gr.) half an hour before operation.

The anæsthesia is induced with ethyl bromide dropped on a special mask, 5 c.c. being used for women, 20 to 30 c.c. for robust men. Narcosis is obtained in from 60 to 90 seconds, after which it is maintained with ether administered by the drop method, or with Braun's apparatus. In children and weakly subjects, ether alone should be used from the commencement of the operation. In the latter case, if the mixture of ether and air fails to produce sufficiently-deep anæsthesia, diluted chloroform vapour may be given for a short time with a regulating apparatus, such as that of Braun or Roth-Dräger.

When there is any reason for anxiety it is an excellent practice to combine the influence of a local anæsthetic by means of an injection of cocain when the patient is under ethyl bromide, or in the stage of analgesia which, according to Sudeck, follows the early administration of ether. The pain of incising the skin can thus be prevented, while sensation in the deeper portions of the wound is destroyed by infiltration (Schleich), or by endoneural injections into the exposed nerves (Cushing).

Lennander generally combines local anæsthesia with repeated administrations of ether or chloroform in cases where sensitive tissues like the parietal peritoneum have to be divided or torn, and again when the wound has to be closed.

In maintaining the anæsthesia it is of advantage to adhere to the minimum dose. Young and inexperienced anæsthetists are inclined to over-administration; and, if the truth were told (v. Mikulicz's interesting statistics), it is chiefly from this overstepping of the permissible dose that deaths under anæsthesia occur.[1] The chief advantage of an apparatus such as Braun's (and the earlier ones of Geppert, Kionka, Wohlgemuth, and the present Roth-Dräger apparatus) is that it makes it impossible for an inexperienced practitioner or an unqualified man to exceed the anæsthetic limit. The drop method possesses a similar advantage, but it not infrequently becomes a "pouring method," as a result of inexperience or youthful zeal.

Insensibility to pain is the test of sufficient anæsthesia. The large majority of anæsthetists consider it their duty to take observations of the expansion and contraction of the pupil of the eye, the disappearance of the corneal reflex, the variation of the pulse, and the relaxation of the muscles, very interesting experiments in the anæsthetising of animals, but not advisable in the case of operations on the human subject. The production of analgesia is the only object in view in the latter case, although it is a matter of some difficulty to convey this instruction to the mind of a young and impulsive practitioner.

2. *Local Anæsthesia.* Before depriving a patient of the benefits of a general anæsthetic, a surgeon must decide under what conditions general anæsthesia can be dispensed with. The first request made by the generality of patients is that they may be able to "sleep" during the operation. Not only do they wish to be free from pain, but they want to be spared the excitement usually entailed by an operation. The analgesic effects of the early stage of ether narcosis will often prove sufficient. We agree with Mikulicz (*loc. cit.*) and Küttner that on sensitive people the psychic effects of the excitement associated with local anæsthesia may have results more dangerous than those of a general anæsthetic.

Local anæsthesia has invariably to be carefully considered where there are conditions present which render the administration of a general anæsthetic dangerous, as in cases of advanced disease in internal organs, blood changes, low blood-pressure, intoxications, diabetes, Addison's disease, advanced Basedow's disease, sepsis, status lymphaticus, and diseases of the cardiac muscle, liver, both kidneys, etc. When an operation cannot be performed by means of local anæsthesia, the means may be combined with narcosis, as we have already described.

The question further arises — To what extent should general anæsthesia be

[1] It is not by chance that we have had only one fatality in thirty-five years in private practice, where for most of the time we have employed the same anæsthetist.

restricted (provided of course it is effected by a safe method) when there are no contraindications to its employment? Schleich, who has won many adherents to the use of local anæsthesia (after Koller had enriched the world in 1881 with the discovery of cocain), has evidently far overshot the mark in regard to the indications for its use.

Minor operations may certainly be undertaken under local anæsthesia. It is, however, just these so-called minor operations that make patients fight shy of further surgical measures which may be deemed necessary. The local anæsthesia process is not always so painless as its description would lead us to believe, and even Schleich candidly admits that he occasionally has to have recourse to the use of the chloroform mask. If a patient has suffered pain, for instance, from the excision of a small primary cancerous tumour, he is almost certain to refuse to allow the removal of the glands to be undertaken subsequently, at the proper time.

Further, there is the risk that, in removing a small malignant primary tumour with local anæsthesia, the operation may not be sufficiently thorough. Schleich, in a monograph on the subject, mentions 75 cases where malignant growths were removed by means of a local anæsthetic without recurrence of the malady, but one looks in vain for the exact details of the operations, which ought surely to be produced in dealing with results of so marvellous a description.

If the thoroughness and accuracy of a surgical undertaking are at all prejudiced by the use of a local anæsthetic, general anæsthesia must be substituted, provided its use is not contraindicated. This point must be plainly understood by the physician whose attitude in regard to early operation at the beginning of the disease so often influences the ultimate fate of the unfortunate sufferer from cancer.

The full significance of the words "local anæsthesia" is, in our opinion, most clearly demonstrated when the analgesia is produced at the site where the anæsthetic is injected. In this form local anæsthesia was first exclusively developed, and was brought into most extensive use by Reclus and others. It is still the principal method of rendering the skin insensitive prior to incision.

At the present time this method is extensively employed, especially in the majority of our operations on the thyroid. It consists in infiltrating the skin and subcutaneous tissues along the line of incision, which is marked on the skin by a fine scratch with the point of the knife, so that the cocain can be injected with accuracy. An angled canula is used, and 1 to 6 grammes (20 to 100 min.) or more of a 1 per cent solution of cocain in normal saline are injected, the solution being sterilised by boiling once. It must be remembered that cocain loses a considerable part of its anæsthetic effect when heated to boiling point.

The needle is inserted immediately under the skin, and the injection is made while the needle is gradually withdrawn, the point, at the same time, being kept in contact with the skin. In a minute the incision can be made without pain, and without any risk of poisoning, as there is not sufficient time for absorption into the blood stream.

The infiltration anæsthesia of Schleich [1] is quite distinct from this process, as he does not regard his method as a cocainization of the tissues in the same sense as in the older method. According to Schleich, the ·2 per cent saline solution he uses produces analgesia by purely physical means, the cocain being added only to make the process of infiltration painless. It is the flooding of the tissues with a heterotonic fluid (·2 per cent instead of the normal ·75 or ·8 per cent) that causes loss of sensation.[2]

Schleich's injection consists of a solution of cocain (1 to 1000) in saline (2 to 1000), with morphia ($\frac{1}{4}$ to 1000). A quantity not exceeding 50 g. ($1\frac{3}{4}$ ounces) of this solution may be injected without harm, till an œdema similar to that in acute Bright's disease is produced. When required, the solution may be strengthened by the addition of a trace of tropococain, or diluted to a tenth with saline lotion, when

[1] *Deutsche Klinik*, v. Leyden und Klemperer, 1901.

[2] Gans (*New York Med. Record*, 1904) uses only sterile water to produce anæsthesia in operations about the rectum. 1 to 15 c.cm. are injected.

a very extensive œdema is desired. Schleich admits that he has often seen "the early stages of cocain intoxication" produced by these means.

It is only in exceptional cases that we employ Schleich's method. Like Braun, we consider that so marked an œdema, as well as the injection of heterotonic fluid, in what Braun calls "Quellungsanæsthesie," cannot fail to impair the tissue vitality and may retard the healing process. It is true that in Schleich's solution the irritative effects of the heterotonic solution, so far as pain is concerned, are masked by the addition of cocain. Nevertheless the irritative effects are there. C. Ritter,[1] in discussing the method by which nature relieves pain, has shown that inflammatory exudates, on account of their high concentration (with a freezing point of 0·76 compared with 0·56 of normal serum), induce a reaction with hyperæmia and œdema till the difference in concentration is equalised.

In our opinion the older method of producing local anæsthesia is sufficiently effective, because the deeper tissues and organs are mainly insensitive. Lennander[2] deserves great credit for his excellent work on the sensitiveness of the viscera and tissues, in which he shows that a large number of deeply-situated organs can be dealt with without any form of anæsthesia. We shall refer to this point more fully in a later chapter.

A second reason why infiltration anæsthesia should not be carried to extremes is to be found in the increasing importance and practical value of "conduction" anæsthesia.

3. "*Conduction*" *Anæsthesia.* To H. Braun[3] of Leipzig belongs the credit of having, as a result of careful researches, brought this method of producing analgesia into more general notice.[4]

If "conduction" anæsthesia has not been sufficiently adopted by the profession, it is because a more accurate knowledge of anatomy is required for its practice than for that of the infiltration method. No one, however, should operate by either method without considerable anatomical experience. Braun makes use of Spalteholz's excellent illustrations of the course of the nerves, more especially those of the extremities of which the majority of anatomical atlases are singularly neglectful.

"Conduction" anæsthesia is produced by a perineural or—after the nerve trunk has been exposed—by an endoneural injection of an isotonic saline solution of cocain. It is therefore essential that the operator must have a capable anatomical knowledge of the course of the nerves. Following Braun's example, we have introduced illustrations to show the points where the nerves will be encountered.

The method is almost identical with that described by Oberst in 1888, in which constriction was brought into use. Krogius utilised the method without constriction (v. History). Braun, however, was the first to demonstrate in the clearest manner that "conduction" anæsthesia is really produced by influencing the nerve trunk, and is not a variety of infiltration anæsthesia, while he further proved the advantages of simultaneous constriction, a point which had already been alluded to by Kummer.

For "conduction" anæsthesia less concentrated solutions of cocain are required, and the anæsthesia is produced more rapidly if the limb is constricted before making the injection. The constricting agent need not be firmly applied, for obstruction to the venous return is all that is necessary. A rubber band is placed round the root of the finger, into which, in the position of the four nerves there, 2 c.c. (30 minims) of a 1 per cent cocain solution are injected. Complete peripheral anæsthesia of all the tissues is produced within the space of five minutes. The addition of 1 to 3 drops of a 1 to 1000 solution of adrenalin acts in the same way as constriction by aiding and prolonging the action of the cocain.

The method of "conduction" anæsthesia may be employed in three different ways :—

[1] C. Ritter, *Arch. f. klin. Chir.* Bd. 69.
[2] *Grenzgebiete*, Bd. 10, and *Deutsche Zeitschrift f. Chir.* Bd. 10.
[3] *Arch. f. klin. Chir.* Bd. 71.
[4] We refer to his new handbook *Die locale Anästhesie*, Leipzig, 1905.

(*a*) In portions of the body, like the hand and foot, where the peripheral nerves occupy a superficial position, anæsthesia can be produced by a circular (Hackenbruch) or semicircular injection of cocain (Braun).

An injection transversely across the back of the hand produces insensibility in the

FIG. 4.—Conduction anæsthesia (Braun), front of upper arm (after Spalteholz).

dorsal surface of the fingers and hand. A circular injection round the elbow joint renders the skin of the forearm insensitive, and a similar injection round the limb below the knee-joint has the same effect on the skin of the leg. The toes and the anterior part of the foot are made insensitive by an injection at the bases of the

metatarsal bones. If no cutaneous nerve has become superficial by piercing the deep fascia in the area to be anæsthetised, this area may simply be encircled by a

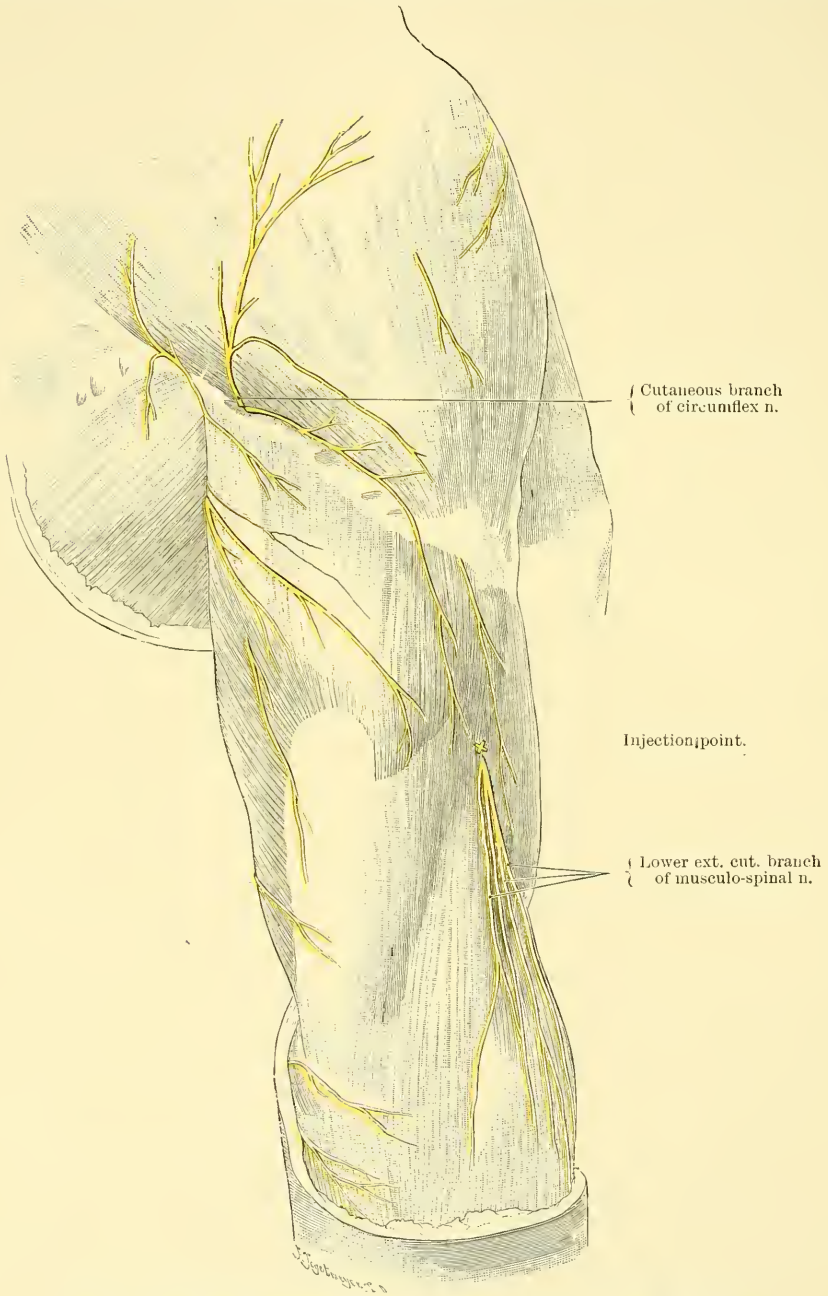

FIG. 5.—Conduction anæsthesia (Braun) of back of upper arm (after Spalteholz).

ring of cocain injections (Hackenbruch). The accompanying figures after Spalteholz indicate the site at which the cutaneous nerves can be treated with injections after they have pierced the deep fascia (Figs. 4-11).

(*b*) Perineural Injection. In order to anæsthetise portions of the body where the nerves have not yet become superficial, an operator must be thoroughly acquainted with the course of the nerve trunks. Braun has made careful experi-

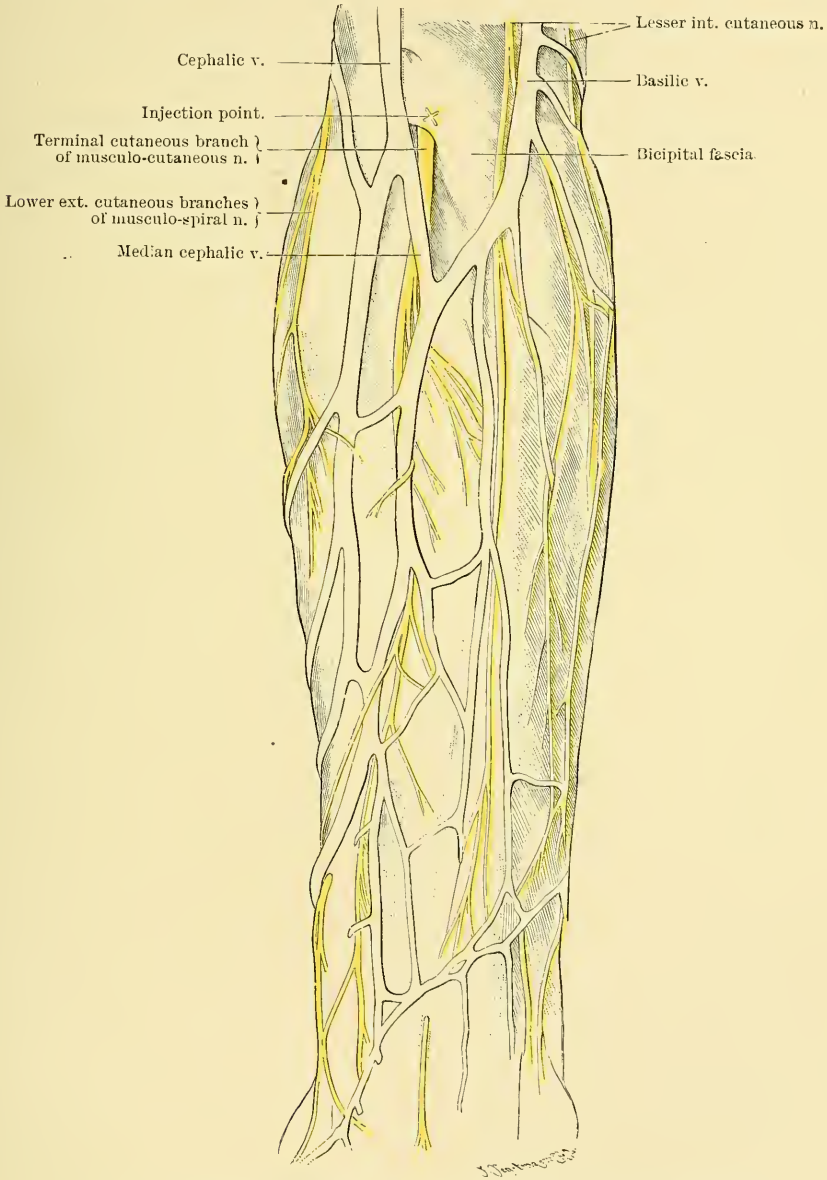

FIG. 6.—Conduction anæsthesia (Braun) for part of fore-arm (after Spalteholz).

ments to show what nerve trunks can be reached with accuracy through the skin for the purpose of perineural injection.

The median nerve above the wrist is reached by introducing the needle from the ulnar side under the palmaris longus tendon; the ulnar nerve at the wrist by passing the needle from the ulnar side under the tendon of the flexor carpi ulnaris.

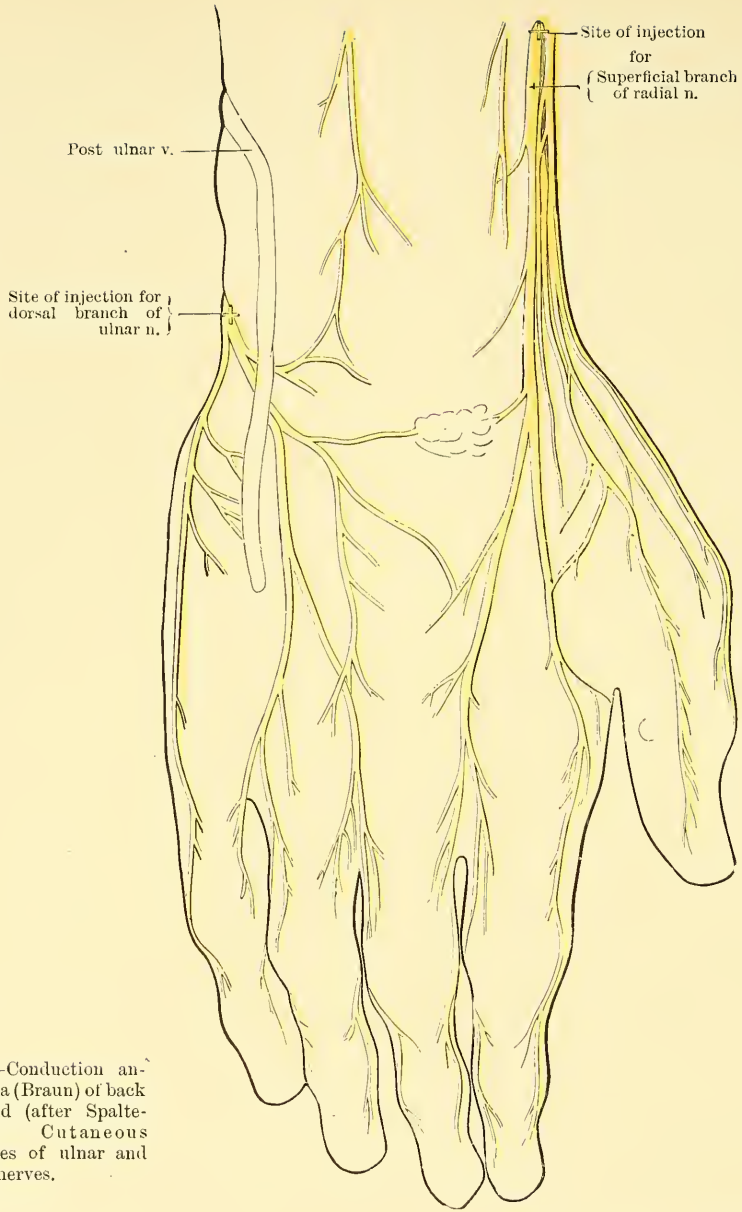

FIG. 7.—Conduction anæsthesia (Braun) of back of hand (after Spalteholz). Cutaneous branches of ulnar and radial nerves.

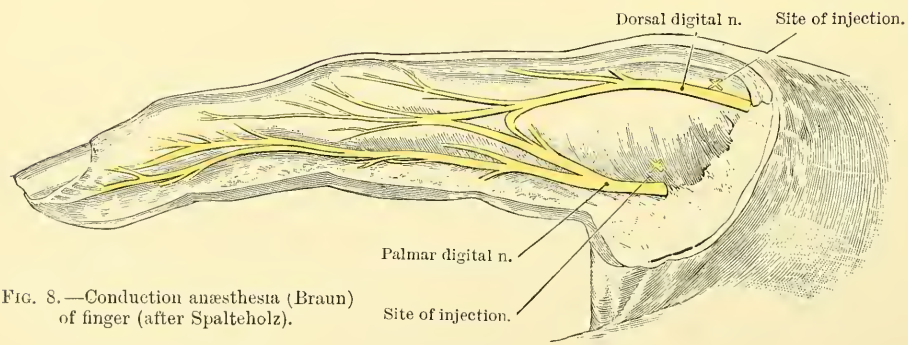

FIG. 8.—Conduction anæsthesia (Braun) of finger (after Spalteholz).

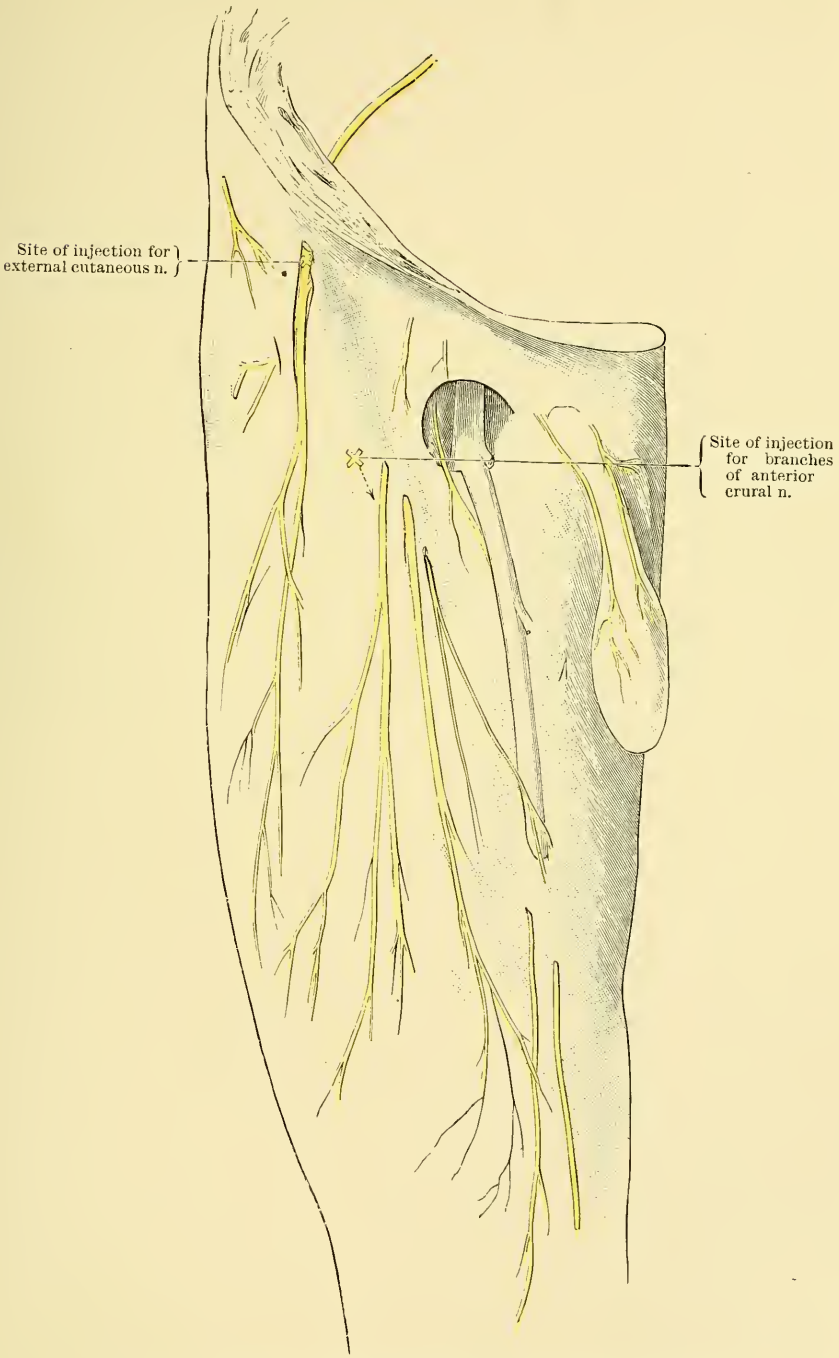

FIG. 9.—Conduction anæsthesia (Braun) of anterior surface of thigh (after Spalteholz).

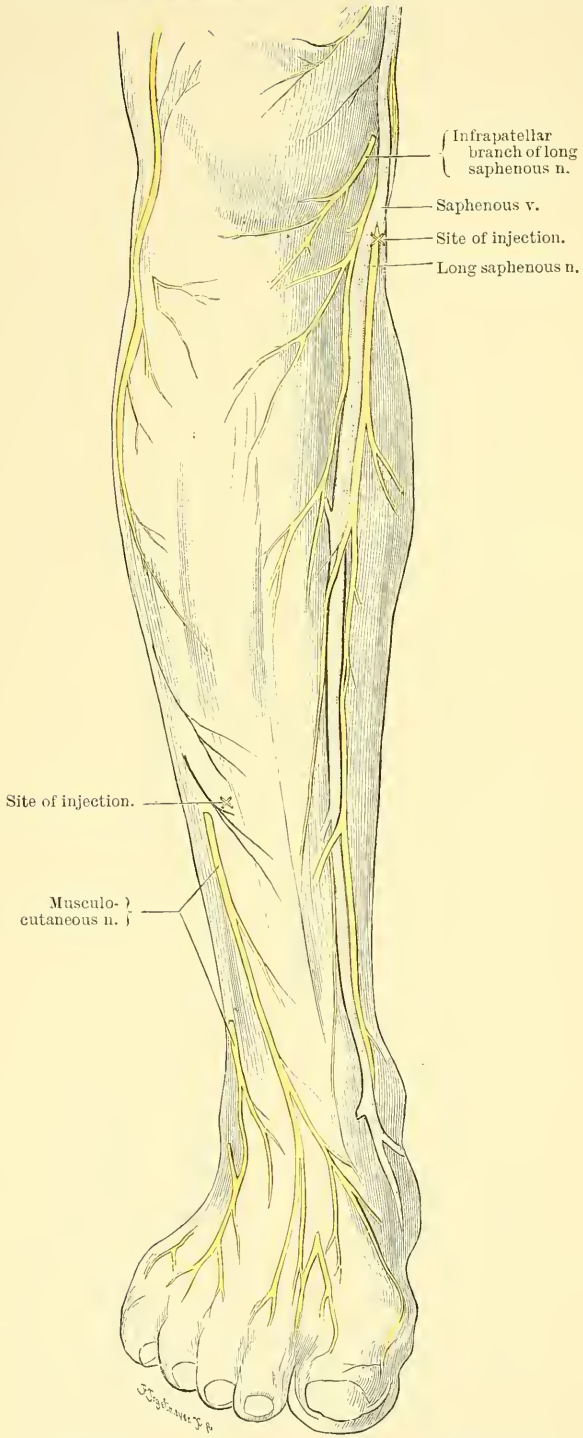

FIG. 10.—Conduction anæsthesia (Braun) of front of leg (after Spalteholz).

The latter nerve can also be reached by puncturing the deep fascia immediately behind the internal condyle of the humerus (Fig. 12).

The posterior tibial nerve can be encountered behind the internal malleolus by inserting the needle close to the tendo-Achillis and directing it forwards towards the bone so that the vessels occupy the inner side. The external popliteal nerve is found at the inner side of the biceps in the popliteal space, a puncture being made under the fascia from behind; while it can also be encountered behind the head of the fibula. The long saphenous nerve is reached by injecting directly backwards immediately below the internal tuberosity of the tibia. The musculo-cutaneous and short saphenous nerves are reached by injecting transversely half round the leg along a line a handbreadth above the external malleolus.

Nyström and Lennander inject the external cutaneous nerve just below the anterior superior spine of the ilium for the purpose of obtaining skin in Thiersch grafting.

A transverse injection above the eyebrow renders insensitive that part of the scalp which is supplied by the frontal branches of the trigeminal. Similarly the branches of the auriculo-temporal, which pass in front of the ear close to the neck of the jaw, are encountered by a transverse injection on the temple, while a similar injection on the occiput will strike the great and small occipital nerves. The great occipital can be reached with accuracy immediately after it has pierced the trapezius.

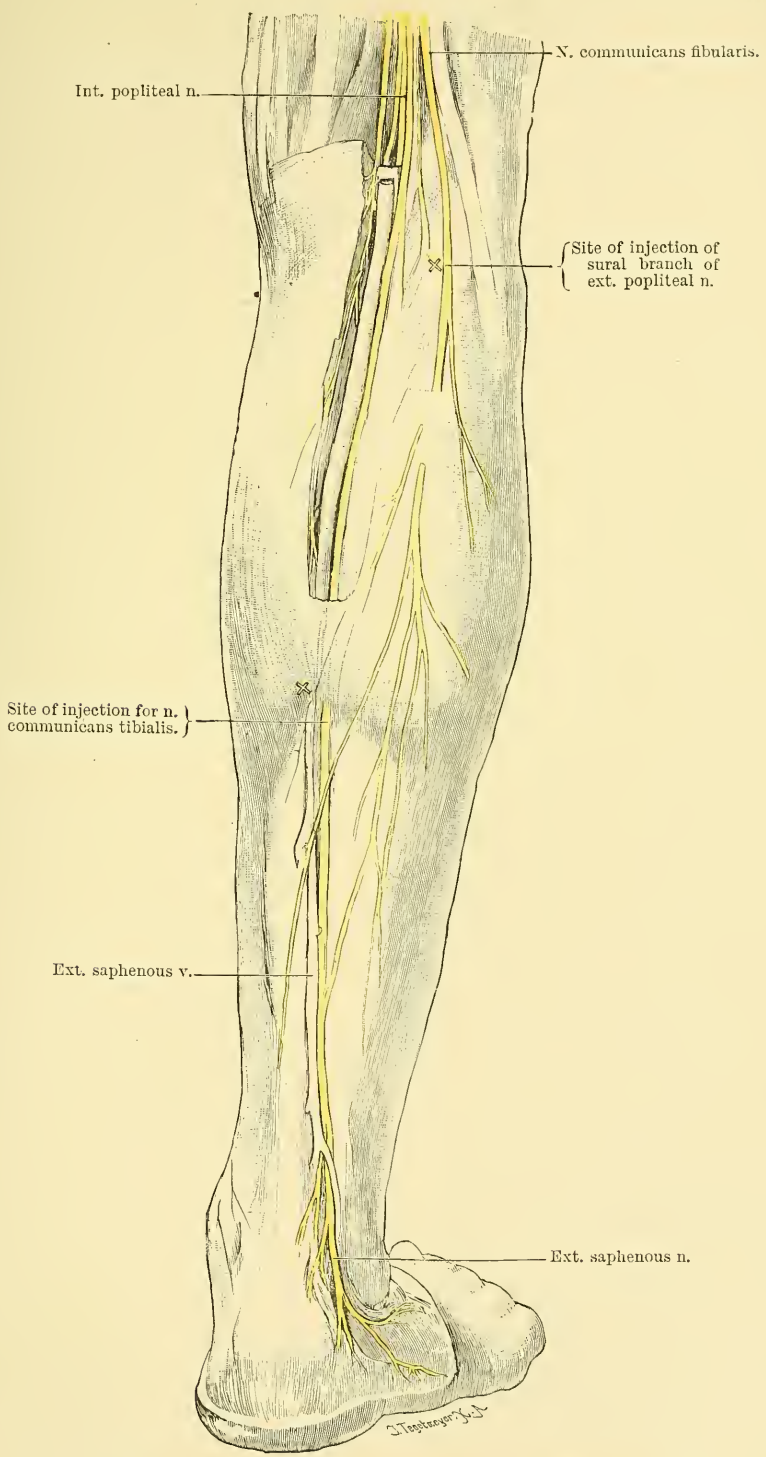

FIG. 11.—Conduction anæsthesia (Braun) for back of leg (after Spalteholz).

We agree with Halsted and Schleich that the lingual nerve can be rendered insensitive by a submucous injection at the point where the anterior pillar of the fauces joins the floor of the mouth. The point where the inferior dental nerve enters the bone is accurately indicated by the lingula on the inner surface of the ramus of the jaw. For the extraction of teeth, the small branches of the nerves to the pulp can be saturated by simple infiltration through the bone by injecting a 1 per cent cocain solution into the gum on either side of the tooth. An interval of from six to ten minutes should elapse before the extraction is performed (Braun).

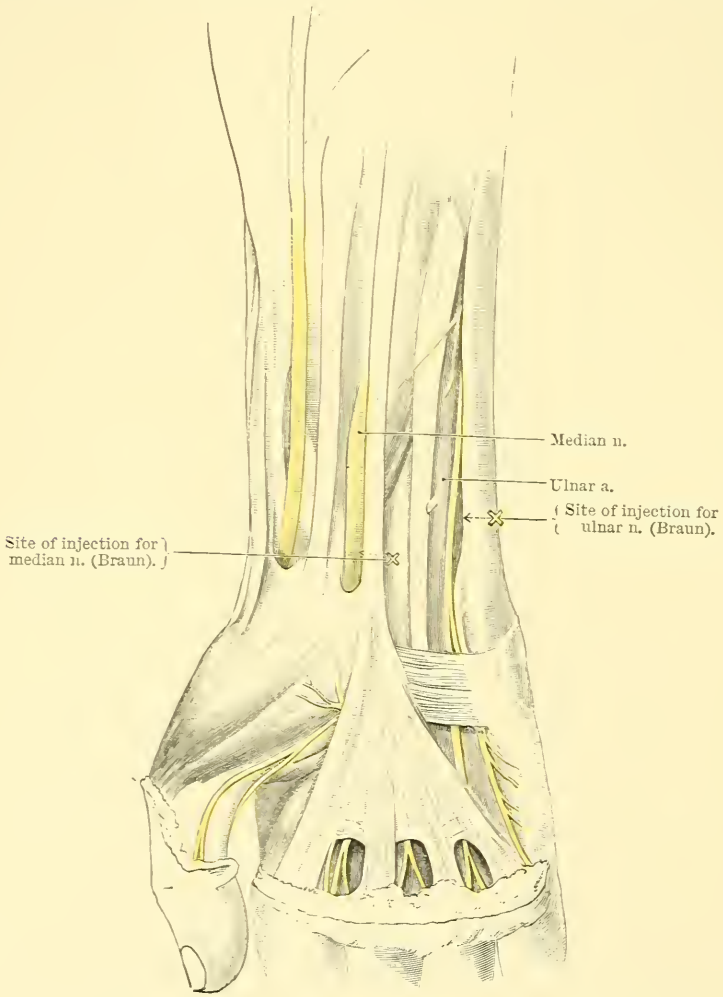

Fig. 12.—To illustrate conduction anæsthesia of the median and ulnar nerves (after Spalteholz).

One side of the neck and the region of the ear can be made insensitive by an injection along the middle third of the posterior border of the sternomastoid. This involves the small occipital, great auricular, and superficial cervical nerves. The region immediately below this, in continuation with the upper part of the thorax anteriorly, can be rendered insensitive by injecting the descending supraclavicular branches of the cervical nerves (Fig. 13).

Anæsthesia of the larynx is obtained by perineural cocainisation of the superior

laryngeal nerve, the injection being made immediately below the posterior end of the cornu of the hyoid bone down to the thyrohyoid membrane.

According to Lennander, the penis is made insensitive by injecting both dorsal nerves close to the symphysis, by a transverse injection into the subcutaneous tissue on the under surface 2 cm. behind the frenum, and by a similar injection into the corpus spongiosum at the posterior border of the frenulum.

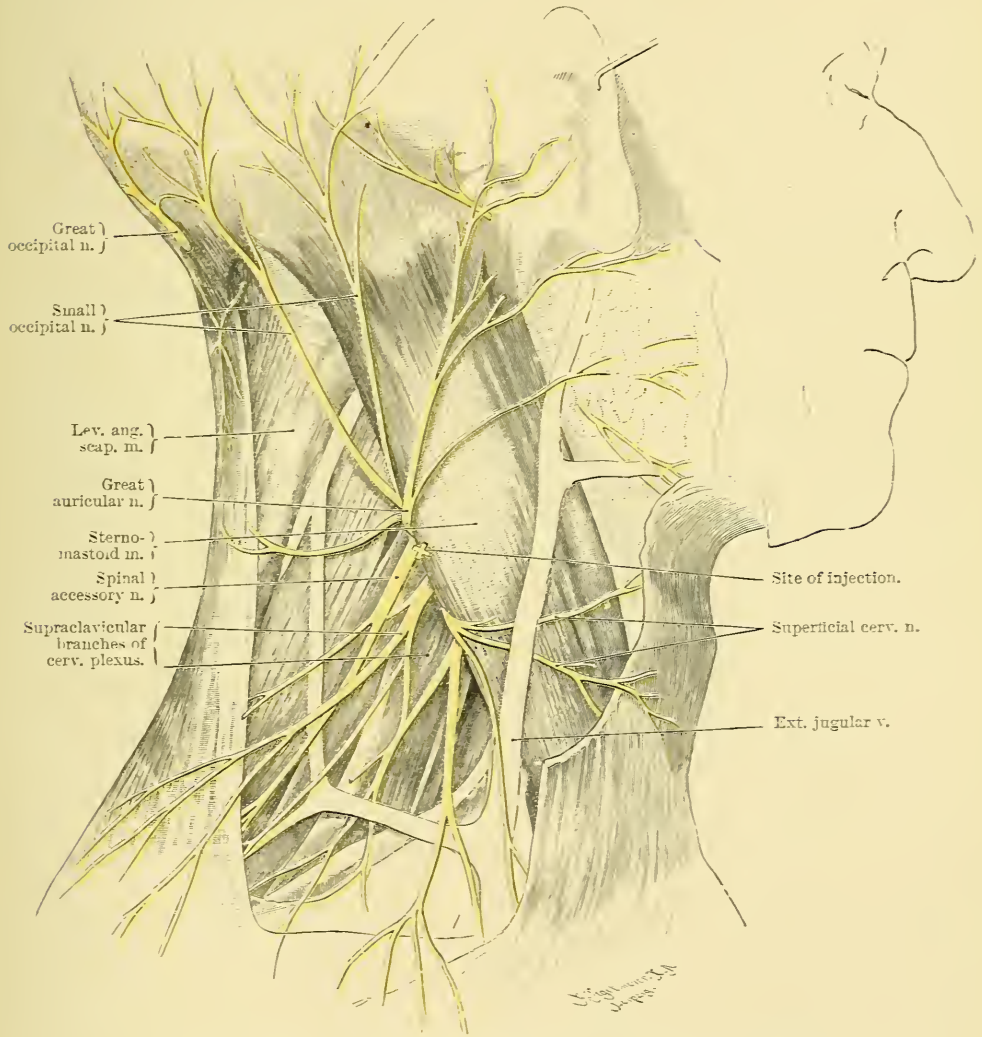

FIG. 13.—Dissection of the right side of the neck (Spalteholz) to illustrate conduction anæsthesia (Braun).

The testicle is rendered insensitive by perineural injection of the nerves in the spermatic cord, and also by infiltration of the connective tissue behind the epididymis.

The rectum may be incised or cauterised by infiltrating the surrounding connective tissue and muscles. This, of course, applies only to the part in the area of the "conduction" anæsthesia in the narrower sense (Fig. 14).

Braun always prepares the cocain solution fresh from a 10 per cent solution of the hydrochloride in absolute alcohol ($\frac{1}{2}$ c.c. = $\frac{3}{4}$ gr. cocain). He obtains a $\frac{1}{2}$ per cent solution by placing $\frac{1}{2}$ c.c. of the above in a watch glass and setting it on fire, the

residue being dissolved in 10 c.c. of physiological saline. Immediately before use 1 to 3 drops of a 1 to 1000 solution of adrenalin are added. The injection should, as a rule, be given fully half an hour before operation.

(*c*) "Conduction" anæsthesia by endoneural injection is an important substitute for general anæsthesia when the latter is contraindicated in an extensive operation. A knowledge of the exposure of the nerve is assumed. We have on three recent occasions performed a high amputation of the thigh by this method. One was a case of severe sepsis following fracture of the femur with tearing of the femoral artery. The second was a case of gangrene of the leg in a patient with advanced myocarditis;

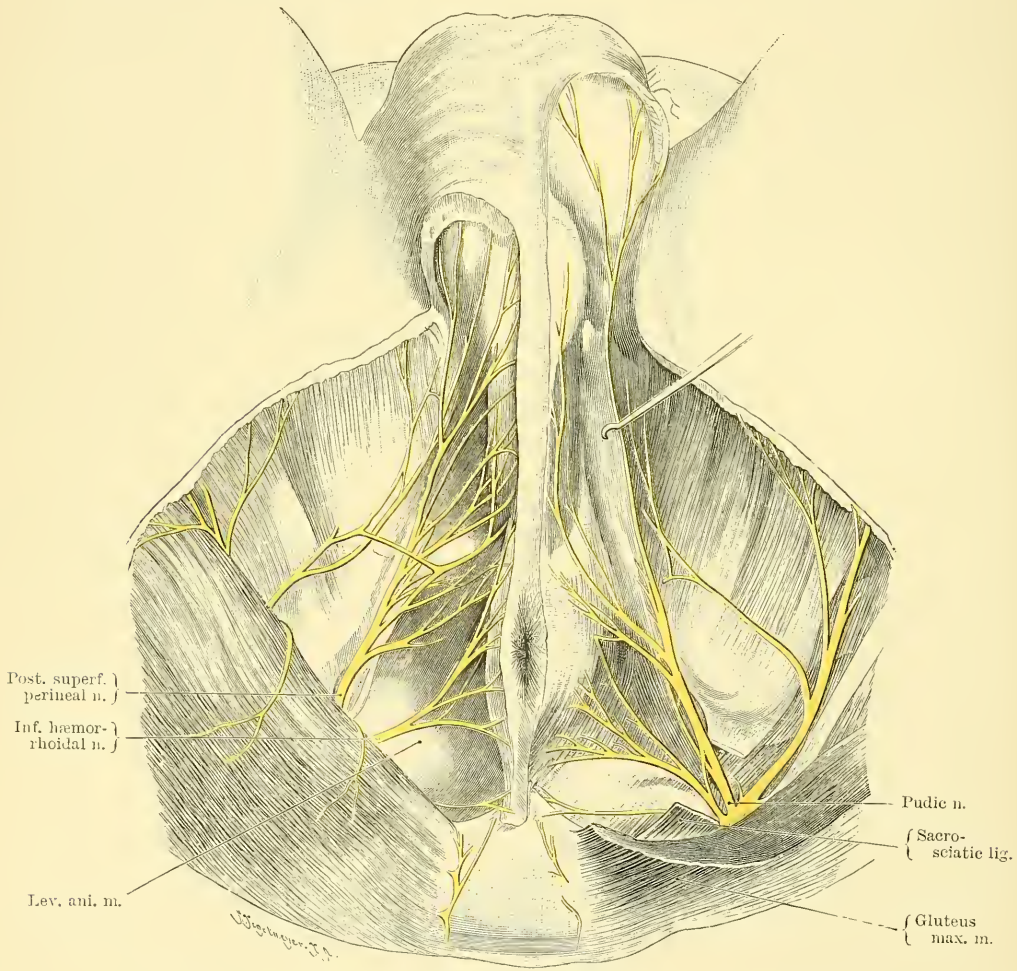

FIG. 14.—Dissection of perineum (Spalteholz) to illustrate conduction anæsthesia (Braun).

while the third was for suppuration in the knee-joint in a patient with advanced pulmonary tuberculosis. The anterior crural nerve was exposed without difficulty in the groin, as was also the great sciatic nerve in the buttock, and a 1 per cent cocain solution (without adrenalin) was injected into the nerve trunks. In the first two cases anæsthesia was immediate and complete. In the last case (where perhaps the cocain had been over-boiled) severe burning pain was complained of during the operation. In a similar manner the brachial plexus can be exposed above the clavicle and injected.

Crile and Matas were the first to adopt "conduction" anæsthesia for the amputation of a limb (arm and leg). Crile has shown that a 1 per cent cocain solution is required, the action of which is almost immediate in distinction to the perineural injection. Its effects last, at most, half an hour, but it may be prolonged by the addition of adrenalin.

Crile and Cushing have demonstrated that the injection prevents shock, which otherwise manifests itself by a sudden fall in the blood-pressure whenever the nerves are divided.

(*d*) There is still another method of employing "conduction" anæsthesia, viz. that used by Cushing where endoneural injections are made during the course of an operation performed under local anæsthesia.

Cushing has shown that during an operation for hernia, the exposed trunks of the ilio-hypogastric and ilio-inguinal nerves can be anæsthetised by endoneural injection, a complete absence of pain resulting. We agree with Braun that this method is of great practical importance, as it suggests the advisability of an operator being prepared to anæsthetise, by perineural or endoneural injection, every exposed nerve, which will subject the patient to some amount of pain if cut transversely, or which supplies part of the area of operation.

4. *Spinal Anæsthesia* (*Rachicocainisation*). Since Bier, who introduced spinal cocainisation, has warned us of the dangers to which it is liable, there are few surgeons who practise this method to any great extent.

Tuffier performs practically all his operations on the pelvis and the lower extremities (including cases of hernia) with stovain anæsthesia, and assures us that after several years' experience he would rather leave the performance of a stovain injection to his assistants than he would the administration of a general anæsthetic.

Cernezzi also speaks in eulogistic terms of the value of stovain in "conduction" anæsthesia. It is poisonous to animals in doses of (approximately 1 gr. per pound) 18 cg. per kilo, proving that it possesses only one-third of the toxic power of cocain. Cernezzi uses it along with adrenalin, as otherwise it has the effect of causing dilatation of the vessels. He injects up to 2 c.cm. (30 drops) of a $\frac{1}{2}$ per cent solution in saline, to which one drop of a 1 to 1000 solution of adrenalin has been added (Parke Davis). Stovain can be boiled without harm. The limit of a dose is 50 cg. ($7\frac{3}{4}$ gr.) of stovain and 1 mg. ($\frac{1}{64}$ gr.) of adrenalin, thus up to 100 c.cm. ($3\frac{1}{2}$ oz.) of his solution with 16 drops of adrenalin could be used. Cernezzi has also performed laparotomy under this anæsthetic.

So-called "spinal" anæsthesia comes practically under the classification of "conduction" anæsthesia. Braun points out that Eden's experiments on cats show that the nerve-roots in the spinal canal (which have no medullary sheath) are peculiarly sensitive to infiltration. An injection of water and of 0·2 per cent salt solution produced anæsthesia which continued for a considerable time. A solution of cocain would therefore prove more efficient were it not that there is the same risk here as in local anæsthesia, namely, of reabsorption in the blood, a risk which we attempted to abolish in the latter form of anæsthesia by means of constriction and the addition of adrenalin.

The injection of a fluid into the subarachnoid space acts almost as powerfully as if it had been made directly into the blood. That stovain can be more readily borne by a patient, as Tuffier seems inclined to assume, because it produces local coagulation is a point that remains undecided.

Cernezzi states that stovain is precipitated in the presence of alkaline solutions, for which reason no alkali must be used when boiling or cleaning the syringe. Klapp has shown experimentally that intradural injections of milk sugar are absorbed much more rapidly than when the injection is administered subcutaneously. He also produced complete anæsthesia of the entire body in dogs without any symptoms of poisoning, by injections of oily or concentrated solutions of gelatine. Donitz, under Bier's directions, has shown that in man the addition of adrenalin to a large extent retards the process of absorption. Notwithstanding this, the danger of uncontrollable absorption remains a great drawback in spinal injection,

a method of producing anæsthesia otherwise so convenient, for its technique is very simple, and all the nerves below the conus medullaris which have not yet left the canal are reached at a point where they are close together.

M. Mori has maintained in a very interesting work that the injection of cocain into the spinal canal presents another serious danger, namely, that it produces a fall of blood-pressure. According to Crile, who was the first to establish convincing proof of this fact, a considerable fall in the blood-pressure takes place after injections in the region of the medulla, but even after injections have been made lower down, a vasomotor paralysis of the abdominal vessels is produced through the nerves traversing the arachnoid space (Tuffier and Hallion).

In connection with "conduction" anæsthesia, Braun has observed that an impairment of the vasomotor nerves corresponds with a rise of temperature in the part affected, but in the extremities this has no serious consequences such as severe bleeding.

At the present time, spinal cocainisation as a method of producing anæsthesia cannot stand reasonable comparison with proper ether anæsthesia or with local and "conduction" anæsthesia.

C. OPERATIVE TECHNIQUE

(g) The Direction of the Skin Incisions

As we pointed out in our previous editions, the appearance of operation scars is greatly improved if the incision is made in the direction of Langer's lines of cleavage of the skin. This is especially applicable to all incisions about the face or neck. The tension of the surrounding tissues does not draw apart the edges of the skin, and the scar, after cicatrisation is complete, often becomes invisible even to a critical eye. We have abundant opportunity of observing the differences in the appearance of the scar in connection with operations on the thyroid as some of our own colleagues employ very different methods.

Since the adoption of aseptic principles, one can afford to make free skin incisions, as the resulting scar, even in exposed parts, is always of the slightest description. Certain operators, more especially younger men, in their anxiety to avoid disfigurement, employ incisions which are much too small. This is a great mistake, for malignant tumours of the face, nose, jaw, and mouth have often recurred from this cause, while in the removal of glands in the neck and other regions the use of a small incision often adds considerably to the difficulty of the operation.

All incisions should therefore be made of sufficient length and should follow the lines of cleavage of the skin. We regard these as normal incisions.

It is further possible to avoid making an incision directly over a diseased focus or organ when the skin covering the latter does not lend itself to aseptic treatment. This applies particularly to the scrotum, where, owing to the wrinkled character of the skin, disinfection is not only a difficult but often a painful process. Our inguinal incision is specially adapted for the majority of these cases, and enables the displacement of the testicle upwards. It has incidentally the further advantage that it allows one to inject the nerves to the testicle at Cushing's point.

In the earlier editions we illustrated by means of figures the results of small incisions in the body such as are employed as special openings for drainage tubes. While these are of value in showing how proper incisions come together naturally and improper ones tend to gape, we think it will be simpler to indicate merely on Langer's figures the normal incisions for a few operations, and consider the other incisions in the chapter dealing with the special part (Figs. 15 and 16). Although the median incision is not depicted, its use should always be preferred on account of the small amount of damage it involves.

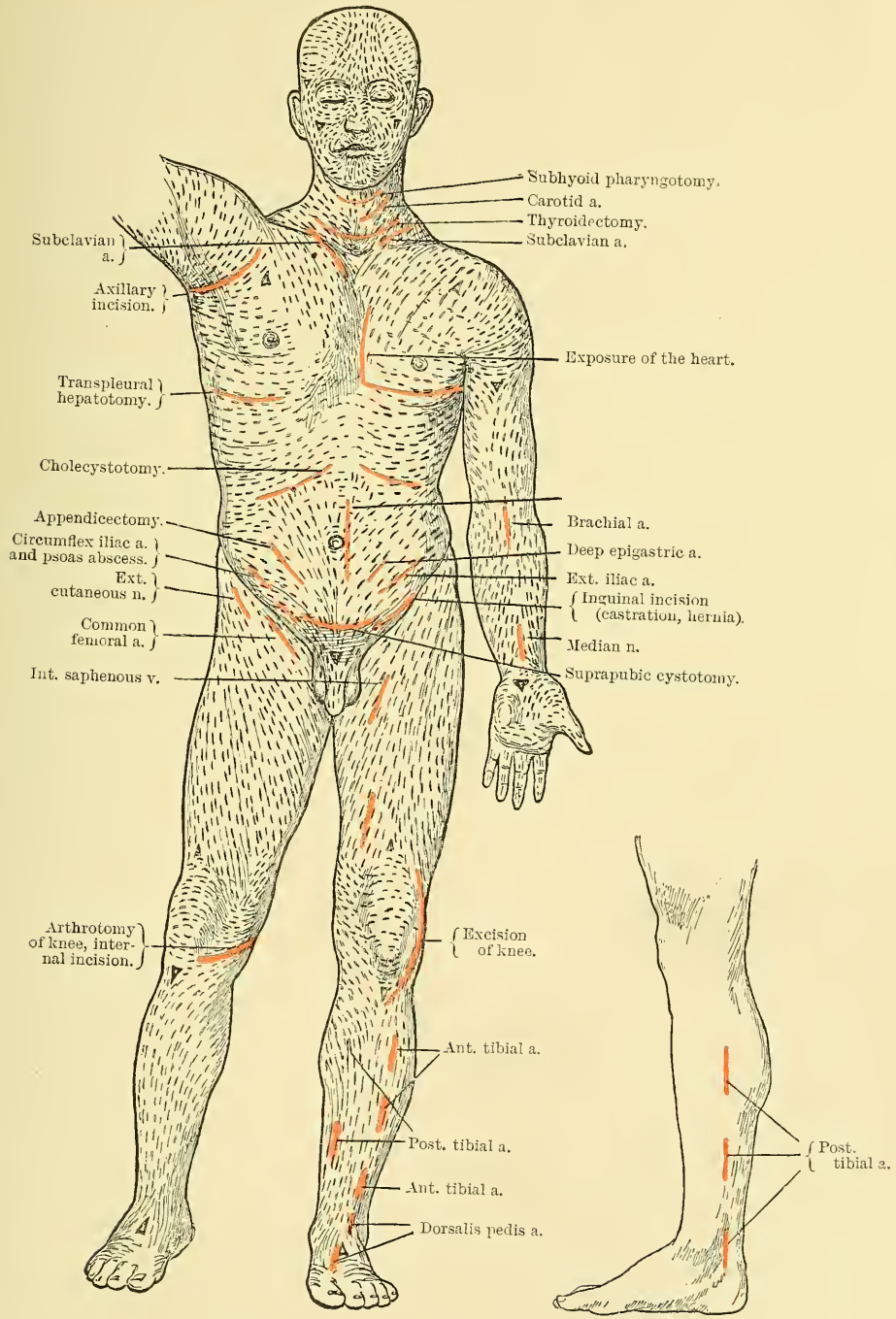

FIG. 15.

FIG. 15*a*.

FIGS. 15 and 15*a*.—A few normal incisions illustrated on Langer's figures.

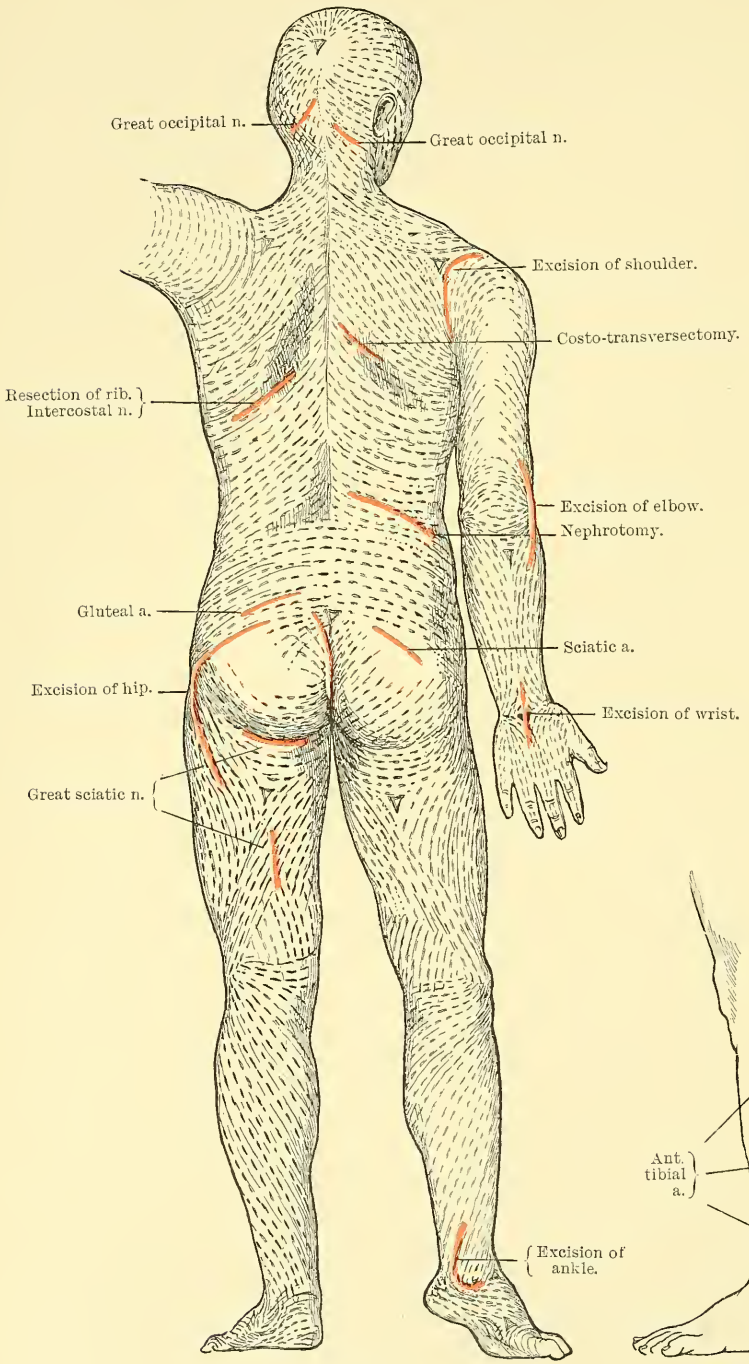

FIG. 16.

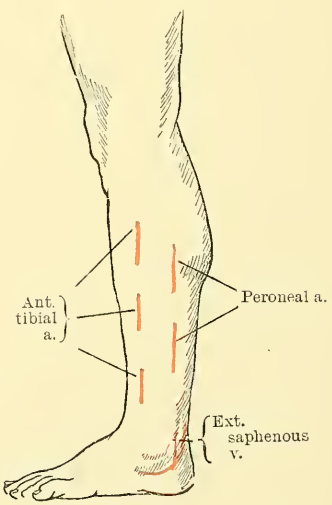

FIG. 16*a*.

FIGS. 16 and 16*a*.—A few normal incisions illustrated on Langer's figures.

(h) Division of Deep Tissues

It is not enough to divide the skin only in the proper line : the deeper tissues must also be divided in such a way that no unnecessary injury is inflicted. In our earlier editions we considered this matter under the head of segmental incisions.

It is obvious that an incision which divides large arteries and veins unnecessarily is to be avoided. In most cases, however, the preservation of nerves is of greater importance, for the results of nerve division (paralysis) are, as a rule, much more serious than those following ligature of a vessel : yet these are the simple points which are so often neglected.

Consider, for instance, the unsightly appearance of the neck after an operation on the thyroid which has resulted in paralysis of the sterno-laryngeal muscles. The deep hollows that are produced are very repulsive to people of refinement. It is far more important to avoid injuring the nerve supplying a muscle than the muscle itself, for with proper care the latter can be divided and subsequently sutured without any damage to its function being sustained. At the most, a tendinous inscription is formed such as normally exists in muscles which have a segmental nerve-supply (rectus abdominis). In operations connected with the thyroid, we therefore divide the muscles high up and subsequently unite them with sutures. There is no resulting harm, because there is no interference with their nerve-supply.

As a general rule, however, even the segmental division of muscles is not necessary. A muscle may be simply separated in the direction of its fibres by blunt dissection. Its sheath alone is divided, and is afterwards sutured. This procedure may be designated interfibrillar muscular division. The same principle is also adopted in the operation which was recommended by Roux and called by us the permuscular method, an operation usually performed for perityphlitis. By separating the muscle fibres, preferably with a blunt dissector, and holding the edges apart with blunt hooks, a wide interval is gradually obtained, without any harmful results. When the edges of the muscles are released, they come together again naturally (*vide* Fig. 382 under perityphlitis).

Once the skin, fascia, and muscles have been divided, the edges of the wound must be protected while the deeper tissues are being dissected. This can be attained either by covering them with sterilised towels, or by pulling out and fixing to the skin with our artery forceps a layer of deep fascia or serous membrane (especially peritoneum).



Fig. 17.—Kocher's artery forceps.

(i) Arrest of Hæmorrhage

Every bleeding point, no matter how small, should be secured in the line of the incision so that the wound may not become infiltrated with blood. This is an important consideration and one which is often disregarded. A wound that is infiltrated with blood is more difficult to heal.

The bleeding points, however, should not be immediately ligatured, for it is dangerous to expose ligature material to the risk of contamination during the whole course of an operation. The newer pattern of artery forceps has the advantage that even when a large number are necessary they are conveniently hung out of the way and do not interfere with the surgeon's movements. The variety

we use (Fig. 17) is very light, is easily applied, and takes a firm grip even in the case of dense tissues.

The ligatures should only be applied at the end of an operation—if they are then found to be necessary. Small vessels should merely be twisted. In simple operations like the radical cure of a hernia we do not employ ligatures. In the neck, however, every vessel should be tied, for in the act of coughing or vomiting even the smaller veins suffer considerable distension. Antiseptic silk should be used as the ligature material. A substitute for silk is only necessary in the absence of asepsis.

(k) Closure of the Wound

Before a wound is closed all bleeding should have ceased. A collection of blood in a wound predisposes to infection and, next to tissue necrosis, is the most important factor in retarding healing. It is mainly due to the care we bestow on the arrest of hæmorrhage that our operation wounds, *e.g.* hernia, goitre, or perityphlitis, are healed in the course of a week, when the patients are, as a rule, able to leave their beds and return home. The avoidance of excessive tissue necrosis is equally important. It was on account of the cervical portion of the uterus being ligatured *en masse* that the results of supravaginal hysterectomy were for many years unsatisfactory. In this case, as in certain others, ligature *en masse* is to be avoided.

In modern practice, an aseptic wound is no longer regarded as strictly sterile, for there is no wound entirely free from the presence of bacteria at the end of an operation. Staphylococci grow in the fluids pressed from a glove after it has been worn. All that micro-organisms require for their development is a nidus of blood-clot or dead tissue at the body temperature. So-called dead spaces are of no importance so long as they are empty. Tissue necrosis and effusions of blood are the real sources of danger.

Primary union by complete closure of the wound must therefore only be expected when neither effused blood nor necrotic tissue has been left in the wound. If there is any chance of blood collecting in the wound, free escape must be provided by inserting a drainage tube, which we invariably use when we are not absolutely certain that subsequent hæmorrhage will not occur. If one is satisfied that sufficient escape has been provided for blood and serum, the rest of the wound may be closed.

For many years it has been our practice to suture our wounds completely and bring out the drainage tube through a special opening in the skin. In this way the least observable scars are obtained. The drainage tube may, however, be simply brought out between the stitches. Burkhardt[1] has observed that tissue necrosis is always associated with an exudation of leucocytes, which sometimes amounts to suppuration. Absorption of the necrotic tissue can only occur in spite of the exudation provided that no bacteria are admitted. According to Burkhardt the process of absorption begins on the sixth day, while a couple of months are required for the absorption of a piece of tissue the size of a bean.

When one cannot prevent the necrosis of a large piece of tissue, no closing sutures must be used. For in such a case it is not sufficient merely to provide for drainage of the wound secretions as in the case of a blood-clot. Bacteria grow in dead tissue, and must be sucked out, as it were, and immediately rendered harmless. When, therefore, necrotic tissue is left in a wound, it must be prevented from undergoing decomposition by keeping the wound open by antiseptic packing. Surgeons who are not particular in their method of arresting hæmorrhage, who are not careful to avoid bruising the tissues, and who employ ligature *en masse*, do well to make it a rule to pack their wounds tightly with iodoform gauze, a practice which is still observed in certain clinics. Irrigation is only required for washing blood from a wound or when a wound has been soiled with some discharge. Normal saline solution at the

[1] Langenbeck's *Archiv*, Bd. 74.

body temperature should be used for irrigation. Tavel's solution causes a superficial cauterisation and produces a whitish discoloration of the wound. This, of course, may have an antiseptic action similar to that of bismuth or zincoxide paste. In clean wounds (*i.e.* those which are not directly soiled by bile, fæces, saliva, etc.) this is rather a disadvantage than otherwise.

When there is nothing to contraindicate closure of a wound, each layer of tissue should be sutured separately. A continuous suture of antiseptic silk is the best and simplest, and will secure the certainty of asepsis.

A layer of collodion is all that need be placed over the wound to protect it from contact with the clothes. If it does not hold well, bismuth paste may be smeared over the wound from time to time (*e.g.* in the region of the nose, mouth, vagina, or rectum). The bismuth keeps the line of suture and the ends of the stitches dry.

When drainage or packing is adopted, the exposed end of the tube or gauze must be thoroughly covered over with antiseptic gauze (iodoform, xeroform, or vioform gauze), and the dressings renewed every time the discharge makes its way through.

It is only by carefully distinguishing between wounds which may safely be closed at once, wounds in which an accumulation of blood may occur, and wounds in which a large amount of dead tissue has to be absorbed, and by adopting treatment suitable to each, that dangerous disturbances in the course of healing can be avoided.

D. AFTER-TREATMENT OF THE PATIENT

When a patient has undergone the nervous strain of an operation, and in addition has had no food for some hours previously; when he has been kept under an anæsthetic for some time, and when he has become chilled, partly from the effect of the anæsthetic, and partly from exposure of the skin; when he has lain on the table with his hands and feet tied, and when in addition there has been much loss of blood, which, of course, can and should be prevented, his condition is one calling for immediate steps being taken to restore the functions of the vital organs, especially by improving the action of the heart.

Many years ago, as a result of observations we made with pulse tracings, we advised, as a prophylactic measure, the administration before operation of tea and sugar, with an admixture of alcohol in the form of brandy or warm wine. As already mentioned, Witzel's plan of giving strong enemata is also to be recommended.

Similar treatment is also advisable after operation, when the circulation is weak. The blood-pressure can be raised by the use of stimulants, *e.g.* tea or coffee with sugar, with or without the addition of alcohol. If vomiting is present, the stimulant should be given in the form of an enema. The administration of warm fluids by the mouth, rectum, or subcutaneously, has a beneficial action. The use of subcutaneous saline infusions should never be omitted after a prolonged or serious operation.

It is very important to maintain the body heat by means of hot bottles and blankets, measures which must be persisted in till the patient is warm, or is noticed to be in a state of gentle perspiration.

Witzel is a strenuous advocate of respiratory gymnastics, *i.e.* deep inspiration and forced expiration, methods to be recommended for all patients who are confined to bed. After an operation they are even more effective, as they accelerate the elimination of the ethyl bromide and ether from the lungs. Further, forcible expiration is of value in expelling mucus from the upper air passages.

Vomiting is best arrested by washing out the stomach, for in this way the anæsthetic which has been swallowed with the saliva is removed, and acute paralytic distension of the stomach, which is occasionally observed after abdominal operations, is prevented. It is of advantage also to rinse out the mouth and nose after as well as before operation. So far as it is due to the action of the anæsthetic on the nervous system, vomiting is benefited by saline infusions and enemata, the latter treatment effectively flushing out the system (Sahli).

Every patient does not require all these remedies. Robust subjects, especially those whose pulse after operation is found to be strong and who sleep quietly, need only be placed in a well-ventilated room and covered up warmly in bed.

The position in which the patient lies after operation is a matter of great importance. Quincke[1] gives general directions in regard to the position patients should be made to adopt in bed for rest and sleep. But in the case of a patient who has just been operated on it is well to be more precise. If there is marked anæmia, shock, or collapse, and the pulse is weak, the head must be maintained at a low level in a position which is not necessarily uncomfortable, and is most conveniently obtained by raising the foot of the bed.

The same position should also be adopted when it is desired to prevent the gravitation of saliva and mucus into the trachea, either when the patient remains unconscious, or when there is impairment of deglutition or loss of the laryngeal reflex.

When, on the other hand, it is important to avoid congestion of the vessels of the head and neck, especially of the veins, the patient must be placed with his pelvis low. This is most conveniently secured by elevating the head by means of pillows. It is curious to observe the frequency with which pillows are simply placed behind the head and shoulders of a patient, with the result that within a quarter of an hour he has slipped off the inclined plane. In addition to the pillows being placed under the head, the patient should also have the additional support of a flat bolster pushed transversely under the mattress below the upper part of the thighs.

As Lennander has pointed out, a dependent position of the legs may give rise to thrombosis of the veins, especially if varix is present. In these cases, therefore, the pelvis alone must be kept low, while the legs should be raised and maintained at a higher level than the buttocks.

Witzel has emphasised the importance to be attached to the position in which the patient is carried after operation, for if attention to this is neglected when the patient is still unconscious, aspiration may take place of the fluids in the mouth and result in post-operative pneumonia, a by no means infrequent complication after laparotomy.

Apart from the danger of thrombosis, there are two conditions which must be carefully watched for shortly after operation, namely, the onset of pneumonia and paresis of the bowel.

According to Kionka, the rapidity with which the anæsthetic vapour is removed by the lungs once its administration has ceased depends on its insolubility in water. Its local effect on the air passages continues for a somewhat longer time; and even if the alleged powerful action of ether in increasing secretion does not prove so real, still the diminished resistance of the epithelial cells to the attack of bacteria is to be taken into consideration. Existing bronchitis aggravates this. We have already referred to the prophylactic treatment with large doses of creosotal in the enema.

The activity of the intestines after abdominal operations may be greatly impaired even to the extent of producing paralytic ileus. The passage of a rectal tube and the introduction of glycerine suppositories to stimulate contractions, and also the administration of saline purges (magnesium sulphate, and Karlsbad salts), may be urgently indicated, and must be resorted to without delay. In an intestine which is securely stitched, the sutures hold so securely that even in the first day or two movements of the bowel have no prejudicial effect.

The most important consideration to attend to, however, is to see that the stomach and intestine are empty before operation, and, if necessary, to have them emptied during the operation, *e.g.* in obstruction of the bowels. Further, intestinal decomposition should be restricted by giving beforehand frequent small doses of bismuth, which prevent putrefaction and the formation of gas (*vide* Preparation of the Patient). Physostigmin is a very powerful remedy, but it must be used with caution. Even 1 mg. ($\frac{1}{60}$ gr.) is very active, so that it is advisable to begin with $\frac{1}{600}$ gr. (a decimilligram).

With regard to the treatment of a patient whose stomach will retain nothing in

[1] *Die Krankenpflege*, Bd. 1, 1901.

the shape of nourishment, or in whom feeding by the mouth is not permissible, the introduction of fluid is of the greatest importance. Patients may be kept for days on subcutaneous injections of saline lotion.

When rectal feeding is employed, an enema of warm milk will be found to produce the least amount of decomposition and to be retained longest. The addition of an egg aids decomposition, while nutritive powders such as tropon and somatose do so still more.

When rectal feeding cannot be resorted to, sugar and fats, or albumin in some non-coagulating and non-poisonous form, may be administered subcutaneously. As an alternative for subcutaneous injections of sterilised olive oil (20 to 100 gr. with 3·58 per cent grape sugar in solution), Friedrich recommends the injection of Siegfried's pepsin-fibrin-peptone (up to 20 g. (300 gr.) at a time), the caloric value of which is reckoned as about 100, the daily requirement of man being 4200 calories.

E. DETAILS WITH REGARD TO ANÆSTHESIA

The preceding chapters A to D have been made as short and practical as possible, and everything tending to cause confusion has been omitted. Argument has been abridged, and points that did not seem to us to have a practical bearing on the subject have been avoided. The directions we have given are identical with those summarised for the benefit of our assistants and staff, in order that the best results may be obtained by a combined system of administration.

For this reason anæsthesia has been briefly considered merely as an adjunct to ether narcosis. There are, however, numerous topics of interest connected with anæsthesia and wound-treatment which require further elucidation. In the next two chapters additional questions will be discussed which are of more theoretical importance.

(1) Further Remarks on Local Anæsthesia

As we observed in our former editions, the majority of the deep tissues possess no great degree of sensitiveness. This has been clearly proved by the fact that our thyroid operations are conducted without either a general anæsthetic or tissue infiltration, in this way testifying to a noteworthy advancement in the practice of local anæsthesia.

Only a few tissues are sensitive, and if they are carelessly torn, pulled, or crushed, instead of being cut, any operative procedure has a painful result. With careful methods of operation, even children have admitted that they felt absolutely no pain during an operation for goitre.

To Lennander is due the credit of having systematically investigated the sensibility of the organs and tissues in the human body. A brief summary of his results is of great interest.

1. Lennander's Investigations.[1] Lennander in his work acknowledges the value of the experiments of Bloch, Byron Robinson, and Max Buch, and calls attention to the diversity of opinions on the sensibility of the organs and tissues, at the same time giving a full account of the literature on the subject. The first facts he established were in connection with the abdomen.[2]

Lennander's investigations are singularly brilliant owing to the simplicity of their results. He finds that in the abdomen the only sensitive tissues are the peritoneum covering the diaphragm and the peritoneum of the abdominal walls. The peritoneum included between the sympathetic cords in front of the 4th and 5th lumbar vertebræ, and probably also in front of the sacrum, where sensory nerves are not found anatomically, is non-sensitive.

The parietal peritoneum is sensitive only to pain, not to touch, heat, or cold. Further, according to Lennander, normal or inflamed peritoneum is

[1] *Deutsche Zeitschr. f. Chir.* Bd. 73. [2] *Grenzgebiete d. Med. u. Chir.* Bd. 10, 1902.

equally sensitive, but earlier investigators have considered the latter condition more keenly alive to sensation, of which all the abdominal viscera which he examined were shown to be entirely devoid.

The conclusion can therefore be drawn that only the intercostal lumbar and sacral nerves (possibly also the phrenic nerve), which are distributed in the subserous tissues, are concerned in the conduction of pain, as all the organs supplied by the vagus and sympathetic are entirely non-sensitive.

According to Lennander, inflammation of an abdominal organ entails severe pain when the parietal peritoneum becomes involved by the spread of the toxins and the inflammatory process along the subserous lymphatics into the lymphatic glands in the posterior abdominal wall. Pains of a colicky nature in hollow muscular viscera such as the stomach, intestines, gall-bladder, bile duct, and ureter, are the result of muscular contractions exerting traction on the cerebro-spinal nerves of the abdominal wall.

Unless the parietal peritoneum is involved, there is no pain. The visceral peritoneum, mesentery, and omentum are devoid of sensation even when they are hyperæmic and inflamed. A peritonitis limited to the appendix is not necessarily provocative of pain.

Adhesions between the viscera and the parietal peritoneum produce pain by tension, but adhesions between viscera alone are free from this result.

The reason why pain is frequently felt at a distance from the seat of the actual disease is that in this situation the chemical, bacterial, or mechanical irritation first affects the abdominal wall. Thus, in appendicitis the pain may be referred to the umbilicus or the region of the stomach, while in a strangulated hernia it is referred to the urethra or other organ. According to Kronecker, Weber has proved that the common sensation is fully developed in the abdominal organs, and that internal organs, though they have no sense of touch, are sensitive to pain. Nerves, muscles, and the brain are insensitive to touch but are sensitive to pain. Nothnagel explains colic, for instance, by the action of "adequal" stimuli.

The nausea and vomiting that are so frequently produced when traction is made on an abdominal organ, *e.g.* the omentum, are simply due to irritation of the cerebro-spinal nerves in the adominal wall.

The mucous membrane even of the rectum is insensitive as far down as its junction with the skin. Distension of the rectum merely creates a desire to go to stool and only becomes painful when the rectal contractions, which are really the underlying cause of the pain, stimulate the sensory nerves of the periproctal connective tissue by traction. The vagina and uterus are insensitive to pain as long as traction is not made on the abdominal wall.

The testicle and epididymis, which are supplied by the sympathetic nerves in the spermatic cord, are insensitive to pain: they only give rise to a sensation as if pressure was being put upon the abdomen. The only pain-conducting nerves are derived from branches of the lumbar plexus which enter the spermatic cord and are distributed in the coverings and the parietal layer of the tunica vaginalis, in the same way as the scrotal branches of the internal pudic nerve give sensation to the connective tissue on the posterior surface of the epididymis. The penis is supplied with sensation through its two dorsal nerves as well as by the deeper terminal branches of the internal pudic nerve.

Like the thyroid gland, the trachea, lungs, and visceral layer of the pleura are all insensitive. The parietal pleura, on the contrary, is particularly sensitive.

Lennander regards bone and bone-marrow as insensitive, the periosteum alone proving sensitive to pain, while he also considers granulation tissue devoid of sensation.

It is clear, therefore, that the observations of Lennander and his associates must have an important effect on the technique of local anæsthesia. There is no occasion for infiltrating tissues with cocain, according to Schleich's method, when they are already insensitive. Further, as cerebro-spinal nerves alone transmit painful sensations, it follows that the conduction method is the one which really goes to the root of the matter. We know the course of the cerebro-spinal nerves, and only require

more accurate anatomical detail to be able to obtain the effects of conduction anæsthesia in any part of the body.

Lennander, and more especially Braun, have led the way in this direction, but there is much still to be learned about the subject. The conduction method has the great advantage that the injection can be made sometime before and at a distance from the site of operation, whereas in Schleich's method the actual tissues to be cut have to be rendered œdematous by forcible infiltration.

Until we can accurately locate for the majority of operations all the points at which peri- or endo-neural injections can be made, Cushing's modification of Schleich's infiltration method may still be adopted with advantage for the deeper tissues. Schleich, who was the first to demonstrate the practical value of dilute solutions of cocain, deserves the credit for raising local anæsthesia to the position it now holds. It will be no disadvantage, however, were the method he adopts, in which "the tissues when incised appear glazed and jelly-like and drip like an over-ripe melon," to be discarded. The directions Schleich gives for the removal of a rib, which consist in forcing the injection through the periosteum into the bony canals and marrow so as to produce saturation of the posterior periosteal surface round the edge of the ribs, and many similar injunctions are, from Lennander's observations, entirely unnecessary.

If the nerve which supplies the area of the operation is known and is accessible, the injection should be made previous to operating. But when this is impossible, the skin in the line of incision may be rendered insensitive by the injection of a 1 per cent solution of cocain (with adrenalin).

When injecting the cocain we always keep the point of the needle in contact with the deep surface of the skin, and endeavour to avoid raising wheals in the skin itself, which, apart from the pain they entail, interfere with the vitality of the skin after suturing. We have never found "endermatic" injection a necessary measure. Braun states that a subcutaneous injection of cocain, combined with the simultaneous application of the ethyl chloride spray for one to two minutes, produces satisfactory anæsthesia, as the action of the ethyl chloride on the sensory nerves intensifies the effect of the cocain. Once an incision is made in the skin (or fascia), the nerve twigs supplying the area of operation can frequently be observed; if not, their approximate position can easily be ascertained. Direct perineural or endoneural injections (Cushing) can then be administered. Cushing described his method as specially effective in herniotomy, but it is also well adapted for the intercostal and other nerves. If these nerves fail to be exposed in the incision, sensitive areas may be infiltrated with a 1 to 1000 isotonic solution of cocain (Braun). Infiltration is, however, specially indicated before incising the sheath of a muscle preparatory to dividing it, as, for example, in operations on the thyroid, where no harm results, as it is followed by incision into the infiltrated layers.

Previous to division of the muscles the injections should be made. Here, again, infiltration is not harmful, as the fibres are simply separated (as described in the operative technique) and no subsequent suturing is necessary.

Finally, organs like the thyroid or kidney, which have a fibrous capsule, may be decorticated without pain by injecting the cocain underneath the capsule. The same process is applicable to the periosteum.

It may often be possible to render a large surface of mucous membrane completely anæsthetic by simply sprinkling it with a rubber spray containing either a cocain, B. eucain, or tropococain solution. As Schleich observes, the latter substance in the solid state acts effectively and is harmless, while B. eucain has the advantage of being less poisonous, is more stable, and is not affected by boiling, an injection of 1 part in 1000 normal saline solution producing anæsthesia which lasts from ten minutes to an hour (Braun). Anæsthesin (Ritsert) (3-1000 solution) is equally serviceable. Spindler strongly recommends akoin (Trolldenier) 1-1000 solution in physiological saline. It can be depended upon to produce an anæsthesia which is maintained for three-quarters of an hour. Braun's method of using cocain in the form of a spray affords excellent results when employed in combination with ethyl chloride, the effect of which is increased by freezing.

When the capsule has been separated, the insensitive substance of the organ or the bone, as the case may be, is encountered. Lennander has shown that in the case of organs which have a pedicle, *e.g.* the testicle (we would include the thyroid), a more effective anæsthesia is obtained by a simple injection into the pedicle rather than by the production of a diffuse œdema. During excision of the thyroid gland, the resulting pain is more severe when the superior thyroid vessels are ligatured or pulled upon. It is at this stage that the excruciating "radiating" pains occur, *e.g.* the earache and toothache referred to elsewhere.

Our observations have hitherto been almost entirely restricted to the consideration of cocain and its administration, as we agree with Braun that it is more advantageous to possess a thorough knowledge of the use of so well known a local anæsthetic as cocain hydrochloride, than to be continually testing the anæsthetic properties of substances which are new.

The anæsthetic effects of cocain can easily be increased, and at the same time may be more readily obtained, by combining it with other substances in the same way as chloroform is used to augment the narcotic effects of ether. As we have already mentioned, Schleich occasionally adopts solid tropococain for this purpose, especially with regard to the surface of the peritoneum. To scrape or cauterise a large ulcer of skin, Braun employs extensive infiltration with a $\frac{1}{2}$ per cent solution of tropococain (up to more than 50 c.cm.) accompanied by freezing. Schleich also frequently combines the ethyl chloride spray with infiltration in opening certain collections of pus, Lennander making use of anestil for the same purpose. In hypersensitive patients the insertion of the needle may be rendered painless by previously freezing the skin. Braun has shown that local cooling increases in a marked degree the action of cocain by delaying the process of absorption and by lowering the vitality of the tissues (*vide infra*). The combination of a local anæsthetic with freezing has been found very satisfactory in operations on inflamed tissues, which cannot be easily cocainised, *e.g.* in cases of furuncle, whitlow, and dental abscess.

A preliminary injection of morphia ($\frac{1}{6}$ to $\frac{1}{3}$ gr.) half an hour before the operation—although the necessity is seldom indicated—is also an aid to local as well as general anæsthesia. More importance is attached to the necessity of increasing the local action by diminishing the circulation or by reducing the vitality of the tissues (Braun).[1] Cocain is, to a certain extent, a vaso-constrictor, but its anæsthetic qualities are not dependent on this property to the extent that Eversbusch, Laborde, and Maurel declared them to be. Kionka agrees with Schleich in attributing the production of anæsthesia to the fact that the tissues are infiltrated under high pressure, *i.e.* the infiltration produces ischæmia by mechanical compression of the nerve elements.

Ether, ethylchloride, or methylchloride in the form of a spray, act directly on the vitality of the skin by causing a considerable local removal of heat and in this way assist the action of the local anæsthetic. (Ethylchloride, which has a low boiling-point (12·5 C.), is particularly effective.)

Cocain, on the other hand, is a protoplasm poison and acts in virtue of its combination with the protoplasm of nerve tissue. According to Kionka, Hans Meyer maintains that certain anæsthetics act chiefly on the lecithin bodies and cholesterin fats contained in red blood corpuscles and in the cells of nerve ganglia, acting locally as well as when they are taken up in the blood corpuscles and conveyed to the brain. The property of dissolving fat is, for example, an important factor in the explanation of the narcotic action of chloroform.

To explain the specific and elective actions of narcotics, a special affinity for the albumins of the cells must be assumed. This assumption also applies to the adminstration of cocain, as in cases of cocain poisoning only a small quantity of the drug is excreted. The combination is certainly a loose one, and the nerve protoplasm recovers with great rapidity.

By reducing the vitality of the tissues, the local action of an anæsthetic can be strengthened. Further, a similar effect is produced if the tissues are rendered

[1] *Arch. f. Klin. Chir.* Bd. 69.

anæmic, for by this process absorption is retarded. This is the explanation why such artifices as local constriction, cooling (per ethylchloride spray), and the addition of adrenalin, materially increase and prolong the action of a local anæsthetic. Corning[1] was the first to demonstrate the importance of constriction. Similarly Custer's experiments have proved that dilute solutions of cocain diminish the risk of toxæmia due to the delayed absorption on account of the large quantity of the solutions made use of. By intensifying the local effects, the general effects, and in particular the symptoms of poisoning, are obviated not only for the time during which the circulation is interrupted (*e.g.* by constriction), but subsequently when they either fail to appear in any form, or appear only in a slight degree, as the cocain has then entered into harmless combinations which can be readily eliminated from the system.

Adrenalin, which is a local vaso-constrictor (Biedl), is now regarded as the best adjuvant to local anæsthesia. It was first adopted in ophthalmic surgery by Dor and Darus,[2] and in naso-laryngeal surgery by Swain, Bode, and Bukofzer, Braun initiating its use in general surgery. The intensity of its action must, however, be remembered, for even $\frac{1}{10000}$ mg. per kilo is sufficient to raise the blood-pressure in animals.

A 1-2000 to 1-5000 solution of adrenalin produces anæmia of mucous surfaces. Braun found that the injection of a 1-1000 solution into the skin of the forearm produced in five minutes complete blanching for an area with a diameter of 1 to 2 ins., the effect of which lasted for an hour, and was not followed by hyperæmia. According to Braun, $\frac{1}{2}$ mg. of adrenalin in very weak solution produces no general symptoms, while he has never observed any local tissue disturbance caused by adding 3 drops of a 1-1000 solution of adrenalin to 1 c.c. of a 1 per cent or 10 c.c. of a 1-1000 solution of cocain. The addition of adrenalin undoubtedly prolongs anæsthesia for hours, and therefore the injection may be given half an hour before the operation, so as to avoid unnecessary delay in its commencement.

Braun noticed that $\frac{1}{2}$ mg. adrenalin, administered on himself, produced both circulatory and respiratory disturbances; while Schäfer observed that intravenous injections were followed by increasing respiration and muscular efficiency, stimulation of the vagus, with slowing of the pulse and more powerful contractions of the auricles and ventricles, with a rise of the blood-pressure due to contraction of the peripheral vessels. The vessels of the brain also contract under the action of adrenalin.[3]

(m) Appendix to Medullary Anæsthesia

Corning's ingenious suggestion of anæsthetising nerve roots or even the spinal cord itself, by injection into the lumbar region of the subarachnoid space, was first put into practice by Bier. Unfortunately, even though it had been taken up with enthusiasm on all sides, Bier himself had very shortly afterwards to publish a warning against the use of this procedure.

The technique is comparatively easy. With the patient sitting[4] (or lying on the side, if the former position is not possible), a line is drawn joining the highest points of the iliac crests. This crosses the fifth lumbar spine (Tuffier). At a point on this line, 1 cm. from the middle line, a fine hollow needle is thrust directly forwards for a distance of 5, 6, or 7 cm. between the fourth and fifth lumbar spines,

[1] *New York Med. Jour.*, 1885.

[2] Braun recommends Parke Davis' adrenalin solution, which contains adrenalin chloride with salt, some free hydrochloric acid, and aceton chloroform. The suprarenin of the Hochster factory has proved equally good: suprarenin 1 g. to 9 g. common salt in 2 c.cm. of a 10 per cent solution of hydrochloric acid and water to 1000 g.

[3] On one occasion we observed the sudden onset of œdema of the lungs with severe dyspnœa and cyanosis, which lasted half an hour, occur from the inadvertent mixture of 6 per cent adrenalin (Parke) with a 1 per cent cocain solution. 5 c.cm. of the solution were injected.

[4] Fig. 18 (Tuffier) gives an excellent idea of the point where the needle enters between the fourth and fifth lumbar vertebræ.

through the soft tissues and the tough ligamentum subflavum between the laminæ down to the dura and arachnoid. The escape of a few drops of clear cerebro-spinal fluid shows that the point of the needle has reached the right place. Fifteen minims of a $\frac{1}{2}$ to 2 per cent solution of cocaine are then injected. If no fluid escapes it is useless to inject, for there is no proof that the subarachnoid space has been reached. The same may be said if blood escapes, a result due to the wounding of the extradural plexus of veins.

Klien (Grenzgebiete, Jena, 1903) utilised the X-rays in order to determine through

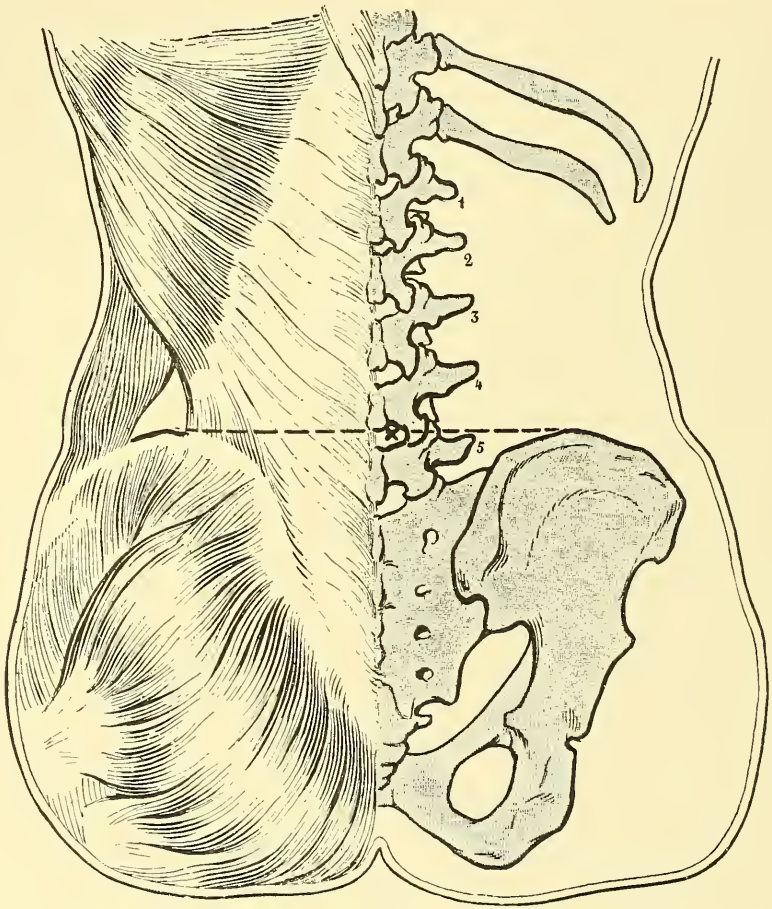

Fig. 18.

which intervertebral space the spinal canal can be most easily reached by puncture. He found, however, that there were very great individual differences. As a rule, the puncture is most easily made in the interval between the third and fourth lumbar vertebræ.

Klien's skiagrams demonstrate the importance of forcibly flexing the trunk so that the intervertebral spaces may be made wider. He recommends the insertion of the needle immediately below the spinous process in a slightly upward direction. If there is any difficulty the puncture may be made some millimetres to one side, the operator at the same time directing the needle towards the middle line.

When the injection has been accomplished, complete anæsthesia of the parts of the

body below the level of the injection is obtained in the space of ten to fifteen minutes, the anæsthetic proving effective on the parts supplied from the lumbar and sacral regions, and in exceptional cases on the areas supplied by the dorsal and lower cervical spinal nerves. This anæsthesia lasts from one to three hours, so that even extensive operations can be performed without sensation on the part of the patient.

There is no doubt something very attractive about this procedure. In the first case in which we employed this method we did not let our students into the secret of the injection, and performed an excision of the ankle, which was very much inflamed,

Fig 19.

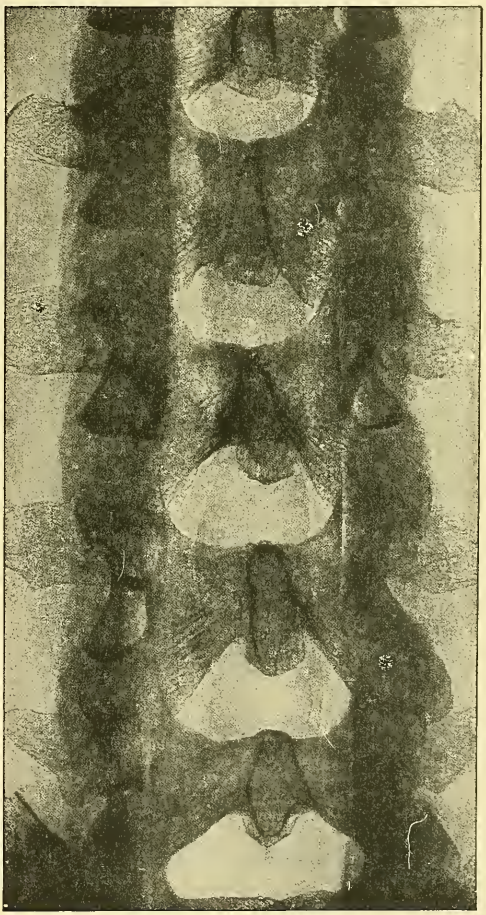

Fig. 20.

Figs. 19 and 20.—Skiagraphs of the lumbar vertebræ (with Prof. Klien's kind permission).

in a child much addicted to screaming. During the operation the patient was engaged in eating and in talking unconcernedly with an assistant behind a curtain which hid from him his diseased foot.

Unfortunately, the anæsthesia is not always so complete, as symptoms appear in a few hours which far exceed in unpleasantness the sequelæ of general anæsthesia. The principal resultant is severe headache, often lasting for several days, frequently accompanied by vomiting, with almost invariably a rise of temperature (to 104° F.), which is particularly liable to cause an erroneous impression of the state of the wound. The temperature generally falls the next day.

Stumme[1] has reported the results of medullary anæsthesia in Mikulicz's clinic. In 21 out of 40 cases anæsthesia was incomplete or absent, while nausea, vomiting, sweating, oppression, tremor, headache, and collapse (2 cases) were noted. As a rule these symptoms were of short duration, but the vomiting occasionally continued for days, while headache was the subject of complaint for as long a period as two months. In addition, pain in the back, exhaustion, and fever were also observed.

In isolated cases more severe after-effects have been noted, which take the form of delirium, with violent excitement, extreme anxiety, breathlessness (respirations 42), very rapid pulse, dilated pupils, and cramps or exaggerated sensibility of the lower extremities. Fever and rapid respiration and pulse continued in one case till the third day, while in a few cases transitory motor paralysis was observed.

Two serious results of this form of anæsthesia still require to be taken notice of. The first may seem questionable to many, but we have observed in cases where the anæsthetic worked particularly well that the wound ran a markedly unfavourable course. This observation was confirmed by Dr. Cushing, to whom the subject had been mentioned. A still more serious result is death following the injection. We have seen one such case, in which the fever and headache failed to subside, and tuberculous meningitis developed. Dr. Dumont has also published a case where death occurred. We cannot with certainty exclude the possibility of deleterious effects produced by cocain on the central nervous system, and especially on its coverings, and which show themselves in headache and other irritative phenomena, giving the necessary impulse to the production of peculiar inflammation in predisposed persons. In consideration of the above facts there can be no question, at least until further research has been carried out, of the general disadvantages of medullary anæsthesia as compared with the much less dangerous and more pleasant form of general anæsthesia.

Every practitioner is not so fortunate as Bier to be able, in his first experiments with a new procedure, to draw attention to its disadvantages. The possibility of preventing the serious after-effects of medullary anæsthesia by choice of suitable media has not been worked out. Bier himself entertains hope of improvement in this direction, and K. Schwarz had no evil results from the use of tropa-cocain ($\frac{3}{4}$ gr.) instead of cocain.

Neugebauer[2] also recommends tropa-cocain in $\frac{3}{4}$ gr. doses. It should be freshly prepared and boiled. He states that anæsthesia appeared in the perineum in the course of a minute, and gradually spread to the genitals, posterior surface of the thighs, the feet, legs, groin, and abdomen. Following Bier's suggestion, Dönitz injected adrenalin along with the cocain. He first injected half a c.cm. of a 1 to 1000 solution of adrenalin diluted with an equal amount of water, followed by an injection of $\frac{1}{8}$ to $\frac{1}{4}$ gr. ($\frac{3}{4}$-1$\frac{1}{2}$ cg.) of cocain. Entirely satisfactory anæsthesia was obtained in this way in animals, and prejudicial after-effects were absent.

As we have already indicated, spinal anæsthesia received a new impulse after the introduction of stovain by Fourneau in 1904. Reclus, who is a staunch supporter of local anæsthesia, declares that stovain is as powerful an analgesic as cocain, and has the advantage of proving less dangerous. Poenaru Caplescu of Jonnesco's clinic regards it as a valuable local anæsthetic in doses of from $\frac{1}{2}$ to 1 gr. (3-7 cg.). Gemuseus, working under Dumont, uses $\frac{1}{2}$ to 1 drachm of a 4 per cent solution for tooth extraction. Foisy considers that stovain is less active than cocain, and that in combination with adrenalin it is apt to cause tissue necroses.

It is chiefly employed in the production of spinal anæsthesia, and we have called attention to the extensive use made of it by Tuffier, while it is highly recommended by Jonnesco. Czerny finds it serviceable in doses of 1-1$\frac{1}{2}$ gr. (6-10 cg.) and Sonnenburg has reported 57 operations under stovain. In eleven of these it failed, but in the other 46 cases the anæsthesia lasted from one-half to three-quarters of an hour, and was attended by no bad after-effects.

Sonnenburg uses the preparation that is sold in sterile tubes. He dilutes it in the syringe with spinal fluid and injects 1 to 1$\frac{1}{2}$ gr. (5-7 cg.). After an average

[1] *Beitr. z. klin. Chirurgie*, Bd. 35. [2] Wien, *Klin. Wochenschr.*, 1901.

interval of five and a half minutes the anæsthesia reaches the upper part of the abdomen, including the abdominal organs.

Lastly, at the Berlin Surgical Congress in 1905, Bier and Dönitz communicated their experiences of stovain in combination with paranephrin. They employed a 4 per cent solution instead of the 10 per cent solution that is sold ready for use. It is easily sterilised. They consider that the injection should be made at a higher level than is customary, namely, between the first and second lumbar vertebræ. We should refrain from injection above the interval between the second and third on account of the close proximity of the conus medullaris. The needle is introduced in the middle line. On several occasions Bier and Dönitz found that only unilateral anæsthesia was produced — a satisfactory proof of localised infiltration of the nerve-roots. Bier specially recommends spinal anæsthesia by stovain, combined with paranephrin in elderly feeble people with disease of the pelvic organs

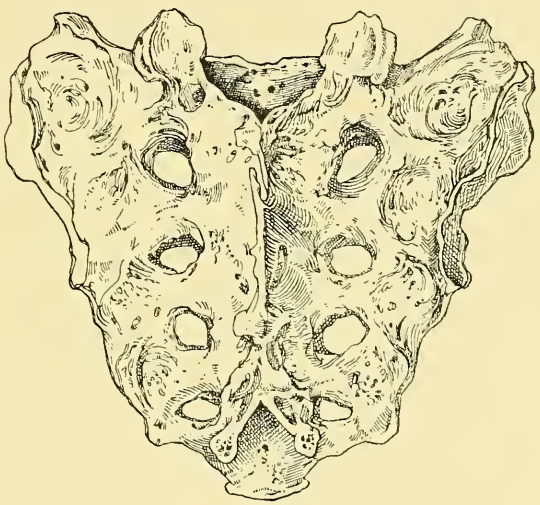

FIG. 21.

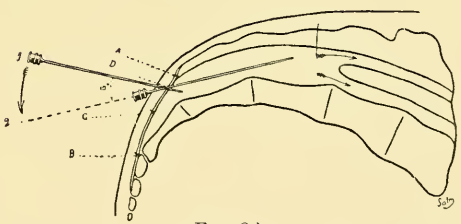

FIG. 22.

FIGS. 21 and 22.—To illustrate Cathelin's method of injecting into sacral canal. Note the alteration in the direction of the needle.

(n) Epidural Injection into the Spinal Canal

Before leaving the subject of spinal anæsthesia we must make allusion to epidural injection. After Tuffier and Hallion's observations had shown that medullary injection acts only on the nerve-roots, Cathelin[1] attempted infiltration of the nerve-roots outside the dura, *i.e.* between the dura and the bony wall of the spinal canal, by puncture of the sacral canal. The veins in the dorsal plexus carry the injection as high as the dorsal region of the cord, owing to their free intercommunication and the narrow outlet from the spinal canal.

The puncture is not easily accomplished, and we have performed it with the patient in the lateral position. A needle, $2\frac{1}{2}$ inches long, is inserted below the last sacral spine between the two prominent posterior sacral tubercles. It is then pushed forwards in the triangular space between these tubercles till it has sufficiently penetrated the thick membrane which closes the space. The needle is then directed upwards towards the sacral canal for a depth of 1 to 2 inches, exactly in the middle line, when the injection is given.

Cathelin explains that the injection acts by the entrance of the anæsthetic into the rich venous plexus between the dura and the wall of the spinal canal. It has also, however, a local action, as he has found the injection produce very satisfactory results in neuralgia of the lower extremities, lumbago, in the radiating pain of tabes and also in cases of enuresis. Cathelin injects 1 drachm (4 g.) of a $\frac{1}{2}$ per cent

[1] *Bull. de la Soc. de Chir.*, 1901, *et Soc. Biol.*

solution of cocain. In dogs he was able to produce complete anæsthesia of the whole body. The two conditions in which Cathelin's method are chiefly indicated are incontinence of urine and pain in the lower half of the body.

(o) Further Details on General Anæsthesia

Rose has stated that no one can avoid an occasional fatality under anæsthesia, as a patient may die suddenly from the nature of his disease, quite apart from the use of the anæsthetic. The truth of this cannot be denied. Death may occur very suddenly from the status thymicus and status lymphaticus, and also from certain circulatory disturbances, *e.g.* atheroma of the coronary arteries. Patients who have a high blood-pressure are liable to apoplexy, and in this connection death has taken place suddenly from an increased blood-pressure in the vessels of the brain. In diseased conditions of nutrition, such as diabetes and Addison's and Basedow's disease, death may occur rapidly under anæsthesia if the disease is far advanced.

All this, however, is no excuse for the frequency with which deaths occur under anæsthesia, because, as we have already observed, general anæsthesia is clearly contra-indicated in these diseases, and if these conditions are not observed, no anæsthetic is free from danger. If a careful examination of the patient is invariably undertaken previous to the operation, one can make practically sure of preventing a fatality as the result of administering the anæsthetic.

We agree with Mikulicz that till the present time ether and chloroform are the only anæsthetics which are sufficiently understood, and which can be safely used for a prolonged severe operation. Among the anæsthetics for minor operations, ethyl-bromide comes first. As we have already stated, it is more advantageous to make oneself familiar with the method of administering a well-known anæsthetic than ever to be striving after new agents for the sake of novelty. The use of laughing gas, which was first discovered by Horace Wells in 1844 (according to Rose), has now been abandoned.

According to Gurlt's statistics (*Deutsch. Gesellschaft f. Chir.*), the mortality from chloroform is 1 in 2075, and from ether 1 in 5112, although countless deaths from chloroform are never published. These figures, as well as personal experience, have induced a large number of surgeons to adopt ether. Certain schools, notably those of Lyons and Boston, have always held firm by ether, and surgeons, who, like Juillard, have used ether exclusively for many years, are most enthusiastic in its favour. Witzel, in recent years, has become one of its staunchest advocates.

Ether was first administered by inhalation by Collins Warren in 1805. Long utilised it for small operations in 1842, but it was not till 1846 that it was regularly adopted by Morton.[1] In 1847 came Simpson's discovery of chloroform. Why is it that in spite of the enthusiasm with which ether has been adopted from the time Morton first made use of it (*vide* earlier editions, and Kappeler's great text-book on Anæsthetics) there are still so many hospital surgeons and practitioners who give their adherence to the use of chloroform? The reason is simply this, that with chloroform one can be certain of producing complete anæsthesia in a brief space of time, whereas with ether this result is impossible. It is, moreover, significant that George W. Gray,[2] a surgeon educated in the Harvard School at Boston, even now finds it necessary to draw particular attention to the cases in which chloroform is preferable to ether, *i.e.* cases in which there is any respiratory impairment.

Further, San Martin[3] makes the assertion that only one fatality from chloroform occurred in Spain during last century, and that in twenty-four years he has only had one death—a result which he attributes to the rarity of alcoholism in Spain, and also to the fact that the anæsthetic is always administered by a specialist. Apart from the latter consideration, we consider that the use of bellows apparatus for giving the

[1] According to Tinker (*Johns Hopkins Hosp. Reports*, Sept. 1902), the credit for introducing ether is really due to Dr. Morton.

[2] *Boston Med. and Surg. Journal*, Oct. 1895. [3] *Revista de med. de Madrid*, 1905, No. 865.

anæsthetic is important, while Martin lays stress on the use of a small nozzle through which the chloroform vapour is blown into the nose.

Chloroform is a much more intense poison than ether. All experiments[1] (Hyderabad Commission) intended to prove that chloroform always causes first an arrest of respiration, and through this an arrest of the action of the heart, are contrary to the experience of surgeons, even in the case of persons in whom after examination no defect of the heart or respiratory system has been demonstrable. This fact is now supported by Embley's experiments (*vide infra*). It may happen that suddenly during chloroform narcosis the face turns pale, the pupils become dilated and immobile, the pulse disappears and the heart stops, while respiration continues regularly or irregularly for a time. Certain observers would refer the early as well as the late syncope to trigeminal reflex with irritation of the cardio-inhibitory centre in the medulla, since often a few drops will determine death (Zoege Manteuffel), but the experiments of Gaskell and Shore on cross circulation in dogs prove with certainty that constant lowering of the blood-pressure and consequent danger of collapse may ensue even if the influence of the brain be excluded, and Winogradoff and Schmidt, under Kronecker, have referred this result to disease of the heart ganglia. Numerous other experiments (English Chloroform Committee, Wood and Hare, Schmey, Kronecker, and others) have proved that chloroform can cause death as a pure cardiac poison. Kronecker and his fellow-workers have shown that the co-ordination centre of the heart is paralysed, and that in dogs it fails to make recovery.

Embley[2] has recently undertaken a large number of experiments with chloroform anæsthesia. Sudden arrest of the heart is due to stimulation of the vagus. Inhalation of air containing more than 2 per cent of chloroform causes weakening of the heart's action and a fall of the blood-pressure; a still higher percentage produces paralysis of the heart. Cardiac paralysis does not occur if the vagi are previously divided, and can be prevented by section of the vagi. On the other hand, stimulation of the vagi, if the heart is already weakened by more than 2 per cent of chloroform, causes cardiac arrest. The fall in blood-pressure is the result of paralysis of the musculature of the heart and the small arteries. The cardiac paralysis comes on without stimulation or sudden alteration in the pulse rate, and the heart dilates. The arrest of respiration either occurring before or after arrest of the heart is due to the fall of blood-pressure, and does not occur without it. Respiration is restored on raising the blood-pressure.

Nevertheless, all these experiments, which appear to disprove the possibility of cardiac paralysis of medullary origin, do not preclude the contingency of cardiac failure from paralysis of the vasomotor centre in the brain, although Gaskell and Shore only observed excitement of the same.

We can, fortunately, avoid these cardiac dangers by administering to the patient *only the dose* he can sustain. The administration of chloroform not sufficiently diluted with air is the cause of the bad effects, and the latter may be referred primarily to reflex influences through trigeminal and vagus twigs in the nose, larynx, and lungs on the cardiac and respiratory centres, and also to the direct influence of the poisoned blood on the heart. Holmgren has shown that the reflex respiratory and cardiac arrest caused by the use of non-concentrated chloroform disappears spontaneously, along with the diminished sensibility which accompanies the further administration of the chloroform as long as the access of fresh air is allowed. According to Cushing, also, death from cardiac arrest is avoided by administering chloroform in proper dilution. Only then it endangers life through paralysis of the respiratory centre of the medulla when narcosis is very prolonged. The volumetric proportion of chloroform and air in which animals can live the longest and with the least damage to themselves has been definitely estimated (5 c.c. to 100 litres air, according to Kronecker). The dangers, therefore, may be avoided by inducing narcosis with a minimum dose, and not increasing the degree and duration of the anæsthesia beyond a certain point.

[1] Cf. Kappeler's excellent article on Narcosis for more exact details in *German Surgery*.

[2] *Brit. Med. Journ.*, April 1902.

The dictum of Sedillot, "pure chloroform properly administered never kills," is therefore justified, and the astonishment of some authors at our earlier method of giving first chloroform and then following up with ether, causes no surprise to those who are properly versed in the use of chloroform. Without the help of an apparatus, or such precautions as will prevent the overstepping of a certain degree of concentration, inexperienced operators should never be allowed to induce chloroform anæsthesia.

Junker's and particularly Kappeler's apparatus, constructed on the basis of Snow's experiments, give the greatest protection in this respect, as they can be regulated so as to obtain a definite percentage of air and chloroform. Dumont recommends Krohne and Sesemann's apparatus.[1] Braun's apparatus is amongst the best.

Although an apparatus by which an admixture by volume of chloroform and air can be supplied possesses undoubted advantages, yet Esmarch's simple mask is still in most common use. The mask depicted here, while preserving the shape of Esmarch's and of Gerard's, leaves a sufficiently wide gap all round to render it impossible to respire too concentrated chloroform, and it has the advantage that narcosis may be induced with minimal doses at first, if the drop method be adopted. This method, which was recommended by us a year before the publication of Zuckerkandl's paper in the *Correspondenzblatt für Schweizerärzte*, in ignorance of Léon Labbé's publication, is now, by the employment of Kappeler's apparatus, the method in general practice. It permits of such a dose being administered to any patient as will induce narcosis without risk.

In the hands, however, of inexperienced or careless anæsthetists a mask does not

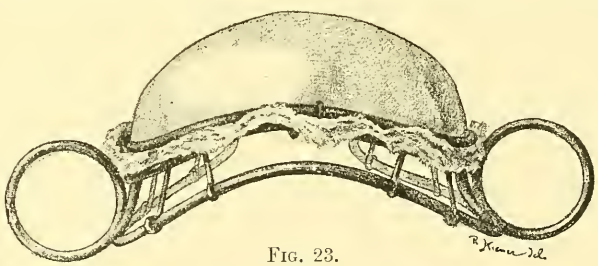

Fig. 23.

give assurance against the worst accident, viz. sudden death at the beginning of the narcosis in comparatively healthy individuals. That these deaths may surely be avoided with proper foresight, every surgeon who has seen thousands of chloroform cases without one such accident will affirm. Bardeleben, after 30,000 cases, had his first experience of such a death. But, it must be admitted that this danger is more difficult to avoid with the use of chloroform than it is with that of ether, because chloroform produces its toxic action in much smaller doses, and therefore Bert's safe interval ("zone maniable") is a much narrower one.

Even careful surgeons are still confronted with the great difficulty of maintaining the right degree of narcosis during a prolonged operation, because by it the blood-pressure becomes markedly reduced, and such complications as loss of blood add still further to the danger.

However, it is not possible to avoid the more intense toxic action which finds its expression on certain organs in the after action of the drug, when narcosis has ceased, since, when anæsthesia has been prolonged, degenerative processes are developed in the vital organs. These changes appear in certain subjects with chronic constitutional or nutritional disturbances, and generally pass off without permanent effect within

[1] Ratimoff, working under Kronecker, found that paralysis of the respiratory centre and death from cardiac paralysis occurred in one hour with 20 cm. of chloroform to 100 litres of air. With 5 c.c. a satisfactory narcosis was maintained for several hours, and for a longer period this required an increase to 7 cm. if the body temperature was kept up. Kappeler found that for satisfactory narcosis 9½ grams of chloroform to 100 litres of air were necessary as an initial dose, but that men required 50 c.cm. According to P. Bert the two extremes are 10 grams per 100 litres for rapid anæsthesia, and 20 grams for sudden death.

a few hours or days, but may in exceptional cases lead to a fatal termination. The latter cases have drawn attention to the fact that certain sequelæ, which were accepted as the more or less necessary accompaniments of the narcotic effect of the anæsthetic, such as vomiting, etc., may have a very palpable causal foundation in certain organic diseases. These special sequelæ of chloroform narcosis do not always even now receive the attention they deserve. Since Fischer and Thiem drew attention to them from their experience of an unfortunate case, a number of observers have furnished experimental proof of their causation.

Nothnagel was the first to furnish experimentally the anatomical basis for the clinical phenomena. Unger, Strassmann, Casper, Fränkel, Schellmann and Ostertag, Bandler and Bastianelli have contributed to a more definite knowledge of the changes. These consist in fatty degeneration of the muscles, especially (but not invariably) of the heart muscle, of the kidneys, stomach, and mucous membranes generally, and of a coincident fatty infiltration of the liver. Ostertag, from the presence of the pigment in the urine, deduces destruction of the red blood corpuscles. Ajello finds hyaline degeneration of the vessels, and deposits of the products of degeneration in the spleen. Fatty degeneration is associated with necrosis of the renal epithelium (Fränkel) and of the lobules of the liver. Marthen found that the changes in the kidneys were especially well-marked. Pohl showed that the largest amount of chloroform was found combined in those organs which contained the greatest proportion of constituents soluble in chloroform—that is to say, in the brain and the red blood corpuscles. Overtoun observed that the different narcotics act by combining with the lecithin and cholesterin-holding constituents of the cells, whereby they induce a change in the physical condition of these cerebral fatty matters, even the loss of the function. Kionka has certainly pointed out that the solubility of fat does not constitute the essential point, but that a specific action must be assumed.

Stiles and M'Donald[1] have sought for the explanation of the deposit of fat in the property of chloroform as a protoplasm poison. They find a similarity between delayed chloroform poisoning and other auto-intoxications, and have observed an increase of acetone in the urine as a result of the fatty degeneration. Offergeld[2] holds with Neudörffer that the deficient oxidation and fatty degeneration are due to the distinctive action of chloroform on the hæmoglobin. He finds parenchymatous nephritis with fatty degeneration the most constant danger. The latter is prevented by ligature of the renal artery, but is increased by ligature of the vein or the ureter. If there is a coexisting nephritis (bacterial or toxic) the epithelial degeneration is increased by the chloroform. Regeneration takes place as the fat disappears and is stored up in the liver. There is less fatty degeneration when chloroform-oxygen narcosis is induced.

Kast and Mester have shown that there is destruction of albumen in chloroform narcosis as proved by the increased excretion of nitrogen, and by the increased proportion of neutral sulphates in the urine. According to Battier and Soulier, chloroform diminishes the amount of glycogen in the liver, and since the latter acts as a destroyer of the poison, the proportion of poison in the urine is increased, and gives rise to vomiting, which may be counteracted by naphthol, washing out of the stomach, and by the administration of glycogen. According to Thiem and Fischer, the safety of repeated chloroform administration may be ascertained by the isonitril reaction upon chloroform in the urine. The urine should no longer reduce Fehling solution. This is important, for, as Schenk has demonstrated, the frequently repeated administration of chloroform at short intervals is followed by a well-marked degeneration.

To be able to definitely ascribe the degenerative changes in the organs to chloroform, other toxic, and especially septic, influences must be excluded. This point has not always been carefully enough noted, as wound infection and its more severe results are especially apt to assert themselves after general anæsthesia. The greater risk of poisoning with other toxic agents, whether they be antiseptic or bacterial, is indeed one of the unfavourable results of general anæsthesia. Galeazzi and Grillo found

[1] *Scot. Med. and Surg. Journal*, 1904.

[2] Langenbeck's *Archiv*, Bd. 75.

that after chloroform narcosis rabbits were killed by a dose of diphtheria toxin, which was not fatal to a non-narcotised rabbit, because its elimination suffered in consequence of damaged kidneys, just as, according to Battier's views, the destruction of the poison in the liver was diminished.

As previously mentioned, the direct action of the anæsthetic on the epithelium of the lung is to be regarded as diminishing the bactericidal power of the lungs. According to Snels'[1] experiments it predisposes to severe infections of the lungs after prolonged anæsthesia.

That individuals with fatty liver, kidney disorders, digestive disturbances, chronic poisonings, such as Basedow's disease, etc., should be specially liable to the dangerous sequelæ of general anæsthesia can be readily understood.

Bandler and Leppmann have shown that, in animals, degenerative changes are far less frequent and extensive with ether than with chloroform narcosis. In fatal cases the symptoms from the after-effects of chloroform are mainly those of impaired function of the kidneys and liver, giving rise to vomiting, icterus, diminution in the quantity of urine, and the presence of albumen and casts, and, as Heintz describes, marked acceleration of pulse, and collapse. In Bandler's case (Wölfler's clinic), which ran its course like an acute yellow atrophy, there occurred, in addition to the above symptoms, pains over the liver, headache, delirium, blood in the motions, unconsciousness, and petechial hæmorrhages, while, towards the end, leucin and tyrosin appeared in the urine. Bandler asserts that it is the fat in fatty liver which combines with chloroform, and so induces a complete degeneration resembling that of acute yellow atrophy. These pathological changes are the results of an overdose of chloroform, since they are found only after operations of long duration. And as it is of great importance, in the administration of chloroform, to guard against the occurrence of syncope, it is equally important not to expose the patient's life to the risks of these after-effects when the operation to be performed is likely to be prolonged. It should also be noted that in anæmic and cachectic individuals, and in operations in which a serious loss of blood is entailed, all the above conditions will be exaggerated.

The contraindications to the use of chloroform are numerous—as already described. It is suitable for persons of strong constitution, for children and adolescents. Hagenbach, a very careful observer, has used it almost exclusively for twenty-five years in the Sick Children's Hospital at Basle without a single mishap, using an apparatus devised by himself, which allows of the administration of air along with the chloroform. In time of war, chloroform is the anæsthetic most commonly adopted, because one has to deal with young and healthy subjects, in operations undertaken for recent injuries to soldiers. In unhealthy individuals, *e.g.* in septic cases, the contraindications hold good.

In the author's private clinic, where for twenty years chloroform has been used almost exclusively, only one death has occurred. The case was one in which, during a long operation, begun under ether, chloroform had afterwards to be administered. This is a method we consider objectionable, but one to which we were driven on this occasion, because the patient's struggles rendered it impossible to complete the operation. In our private clinic we have always had the services of the same anæsthetist—a very careful and conscientious man, and a layman.

The dangers of chloroform can therefore be avoided, but experience, and a thorough examination of each individual case before its administration, are imperative. For this reason it is far more convenient to have at our disposal an anæsthetic whose range of safety is less limited, and where want of foresight in its use is not forthwith punished by death of the patient. Such an anæsthetic we have in ether.

That ether narcosis may prove fatal is shown by statistics, but it has this advantage over chloroform, that its action on the heart is insignificant as compared with its action on respiration, and also that the poisonous after-effects involve the other organs to a far less extent. The contraindications to the use of ether can be more precisely formulated, and are in practice more easily determined than are those

[1] *Nederl. Tijdschr. voor Geneeskunde*, 1902.

of chloroform. Respiratory disturbances and pathological changes in the respiratory organs with dyspnœa are the contraindications of prime importance, as ether causes more severe and more lasting damage to the respiratory organs than can be attributed to chloroform.[1]

But we here repeat that these contraindications really apply when the ether is incorrectly administered, not when administered according to the methods described in the earlier section on anæsthesia. Chapman[2] found in rats that the repeated administration of ether produced ecchymoses on the surface of the lung, with alveolar and peribronchial exudation. Pneumonia was readily produced in animals which were made to inhale cultures of the diplococcus after repeated administrations of ether, while it did not occur when they were not etherised.

A deleterious action on the kidneys has also been attributed to ether, but experiments and clinical observation by Roux and Wunderlich, as well as by Fueter and Lerber (under Dumont's direction), show that in this respect ether is certainly not more dangerous than chloroform. Yet Thomson, Colemann, and Kemp, by direct measurements, have shown that ether causes a greater diminution in the amount of blood contained in the kidney, and in the amount of urine secreted by it, than does chloroform. Out of ninety deaths in the Roosevelt Hospital, five were due to renal affection following ether narcosis. Brown has described a considerable decrease in the solids excreted in the urine after etherisation.

Casts and albumen are certainly met with just as frequently after the use of chloroform (Niebergall), and, according to Eisendraht, Zachrisson (Lennander), Lerber, Barbacci and Bebi, Luther and Rindskopf, even more frequently, while Stockvis and Doyer maintain, on the contrary, that kidney affections are decidedly more common after ether.

The peculiar effects of ether on pre-existing congestive, hyperæmic, and inflammatory conditions of the larynx, bronchi, and lungs are well known. Such deaths as we have observed following the administration of ether occurred after operations on cases with marked tracheal stenosis, diseases of the lungs, or empyema.

In cases dying shortly after the operation, with steadily increasing dyspnœa, it was remarkable to observe how great was the hyperæmia of the tracheal and bronchial mucous membranes of even the finest tubes. In all these cases, however, pure ether was given without morphia, and was freely poured on a mask covered with waterproof sheeting.

It is worth while inquiring into the causation of the damage to the respiratory organs, which may end in œdema of the lung, severe bronchitis, hepatisation, and pneumonia. For the elucidation of this point the interesting work of Gottstein is deserving of notice.

If ether, even more than chloroform, be credited with producing a tendency to pneumonia, then, as Gottstein argues, these pneumonias should cease to occur when local anæsthesia is employed. But Gottstein (Mikulicz's clinic) has observed that of 74 non-abdominal operations under cocain, only 1 was followed by pneumonia, whereas in 114 abdominal cases pneumonia occurred in 27—*i.e.* after deducting the cases of pneumonia caused by lymphatic infection following peritonitis, and the cases succeeding vomiting, he still found 14·8 per cent as against only 5·8 per cent in chloroform anæsthesia.

Gottstein accounts for these figures by the fact that the abdominal operations under cocain were performed on old people, and were of a serious nature. Mikulicz considers that there is a danger of pneumonia in all abdominal operations, and for this reason he does not perform the radical cure of hernia unless there are symptoms of incarceration.

He accepts the Gussenbauer-Pietrozowski theory, viz. that pneumonia in these cases results from emboli, which reach the lungs either through the liver, or through direct

[1] Bruns has called attention to the fact that the after-effects of ether result from its impurity. Professor Drechsel informs us that even with the purest ether oxone is generated if it be exposed to the light.

[2] *Annals of Surgery*, 1904.

communication between the portal vein and twigs of the inferior vena cava, and he considers that the infarcts so formed in the lungs may, without being primarily infected, become secondarily infected from the air passages.

These deductions of Gottstein's prove, therefore, that pneumonia following ether narcosis is not to be considered an ether pneumonia as a matter of course. According to some statistics, those of Schultz, for example, pneumonia is more common after chloroform—a fact in accordance with many clinical observations. What is chiefly of importance, however, is the fact that the bad effects of ether on the lungs are in large part avoidable since they are caused by faulty administration of the anæsthetic.

Hölscher[1] (Esmarch's clinic) states that most authors refer bronchitis and pneumonia following ether narcosis to direct irritation of the ether, or to some impurity in the ether (Bruns) acting on the mucous membranes. Nauwerck deserves the credit of having called attention to a new and important source of infection, viz. that owing to the paralysis of the soft palate, the root of the tongue, and the epiglottis, the saliva and mucus, which are both greatly increased, are apt to be drawn back during inspiration, carrying with them organisms from the buccal cavity.

Grossmann considers that the "rattle" consequent on the back-flow of mucus and saliva is the result of bad technique, which he blames as the true cause of the lung affections.[2]

Hölscher, prior to inducing anæsthesia, coloured the fluid of the mouth with a watery solution of gentian violet, according to Lehrwald's procedure. He has ascertained that with the patient in a horizontal position, and with a plentiful accumulation of fluid at the back of the throat, the act of respiration is sufficient to carry the colouring agent to the finest bronchi, and even to immediately under the pleura. Where respiration is obstructed this is proportionately increased in one or other lung, according to the position of the patient, and if the head be propped up this overflow into the lung is much more marked.

But with the head dependent no aspiration occurs, except in cases of tracheal stenosis, and then only as far as the trachea itself. So long as the head is horizontal and is inclined to one side, the mucus and saliva, which are copiously secreted in ether narcosis, are prevented from accumulating at the orifice of the larynx, and are allowed to flow out at the corner of the mouth.

In the surgical clinic at Kiel the headpiece of the operation table is lowered so that the head is dependent, while Witzel operates with the head forcibly thrown backwards.

Hölscher does not believe that a hypersecretion of mucus is demonstrable. At an autopsy performed shortly after death he found no collection of mucus and no hyperæmia. He has also observed, that however marked salivation may be, no mucus is secreted.

In cats, however, which, like human beings, and unlike dogs, are supplied with a great number of mucous glands in the trachea, he found distinct increase in the secretion, as well as mucus in the chalice cells, and also constantly on the general surface of the membrane, but considered that the amount was so small as to be easily removed by the ciliary movements, which, contrary to Bernard and Engelmann's statements, are not paralysed by ether and chloroform.

Hölscher could never satisfy himself of the presence of hyperæmia or inflammation of the trachea or bronchi. For this reason he considers that the tracheal and bronchial mucous membranes are less affected than are those of the mouth, nose, and pharynx, but he thinks that this may be explained on teleological grounds, since the trachea and bronchi cannot exercise this faculty, as they are protected by the mouth and nose.

He finds that salivation occurs with pure ether, even although administered through the trachea; but he admits that a part of the action may be a local irritative one on the termination of the lingual nerve, a view held by Claude Bernard.

He attributes bronchitis and pneumonia partly to the cooling effect of chloroform

[1] Hölscher, "Experiment. Untersuchungen," etc., *Langenb. Arch.* Bd. lvii. 1898, S. 175.

[2] Grossmann, on this account, entirely rejects the mask introduced by Juillard, and recommends his own modification of Wanscher's mask.

and ether (does he make an exception in the case of cocain?), but for the most part he considers them the result of aspiration of infected material, and of this he adduces ample proofs. Before the Surgical Congress in Berlin, 1901, Henle communicated some very interesting contributions on the subject of the influence of cooling in the causation of pneumonia, and we agree with him that, for protracted operations, a heated operating table, such as we have used for the last twenty-five years, should be universally employed.

Another important cause of cerebral anæmia is marked cooling of the body. This is all the more important from the fact that, in every prolonged anæsthesia, whether from chloroform or ether, not only does the body temperature fall but the blood-pressure is considerably lowered.

One must conclude from Hölscher's experiments that, with healthy respiratory organs, the bad effects of ether may be guarded against, but at the same time there is no proof that the same holds good when the organs are diseased. Just as we consider it certain that heart disease and weakness are the contraindications to the use of chloroform, so are diseases of the respiratory organs and extensive narrowing of the respiratory passages contraindications to the use of ether.

At the German Surgical Congress held at Berlin in 1905, Kelling and Lenhartz, who had made a special study of post-operative pneumonia, regarded aspiration as the chief factor in its prevention. Embolism and extension from the lymphatics were considered as merely secondary considerations. According to Henke, infarcts are not found *post mortem* sufficiently often to attach much importance to an embolic origin.

Lenhartz laid special emphasis on the fact that in abdominal operations the interference with diaphragmatic breathing causes deficient æration in the lower parts of the lung. That interference with respiration plays an important part in the production of pneumonia has been proved by Schloffer (Wölfler's clinic), who recorded 29 cases of pneumonia out of 107 cases of excision of the thyroid under anæsthesia. But since the introduction of scopolamin and morphia narcosis, Kümmel has observed a significant decrease in the frequency of pneumonia. Still in these cases the severity of the injury is not without its influence on the results. Schloffer observed more cases of pneumonia after Bassini's operation for the radical cure of hernia than after any of the other methods. When using ether, therefore, our chief care should be to reduce this tendency to cause damage to the respiratory passages to a minimum by following the rules laid down by Nauwerck, Grossmann, and Hölscher, viz. to adopt a suitable position of the patient, with the head dependent and turned to one side, to allow the saliva to flow away as it is secreted according to the statements of Hofmann, Witzel, and others. But still more important than position is the dilution of the ether vapour with air.

Schmidt (Kronecker) has observed how well animals, which otherwise suffer from severe catarrhal affections of the air passages, bear ether administered by Kronecker's apparatus, the ether mixed with moist air being blown down the nostrils. But there is still another factor which must be kept carefully in mind. When ether (on account of its weakness as compared with chloroform, and of the larger dose required) is administered by the "asphyxiation method," which is effected by pouring a large quantity of ether into a mask and excluding the air, hyperæmia of the lungs and marked salivary secretion always result, evils which may be prevented by diluting the ether with air.

Dreser has formulated the same rule for ether as for chloroform, viz. that a definite proportion of air should be used with it. He starts with 2 c.c. and rises to 4 c.c. of ether in 10 litres. In this way he guards against the sensation of choking, and against irritation of the bronchi. Cushny (Kronecker) has experimented with carefully measured mixtures of chloroform and of ether, which he introduced through tubes into the nose by means of water pressure, and he proved that narcosis could be induced by means of 15 to 20 per cent of chloroform vapour, and that it could be maintained with 5 to 7½ per cent, while a 20 to 30 per cent ether mixture did not always cause anæsthesia, and, to maintain narcosis, ether required a higher percentage than chloroform (20 to 25 per cent). As will be shown later, Braun, of

Leipzig, has arrived at the conclusion that, in proper dilution (6 to 7 per cent by volume), ether has no bad effects on the respiratory organs, but that in this form it is not always powerful enough to induce complete anæsthesia. Hofmann and Witzel dilute the ether with air by dropping the ether from some height on to an open mask. In cases where the diluted mixture is not strong enough to produce complete narcosis, we endeavour to avoid the evils of more concentrated ether vapour by inducing anæsthesia with a small dose of a rapidly acting anæsthetic, such as bromethyl, which for healthy adults is harmless in small doses. Bromethyl has now quite superseded chloroform for this purpose, though Lennander, following Zachrisson, obtained very good results with the latter.

Recommended by Nunneley in 1849, bromethyl has found a strong advocate in Haffter of Frauenfeld. We have made use of it in accordance with Haffter's methods and writings, and can fully confirm his experiences.

Narcosis may be induced in adults by 20 to 30 g. of bromethyl, the whole dose being put into a mask, covered with impermeable tissue, and inhaled for 30 to 60 seconds. There is then no need for the large doses of ether with exclusion of air, and satisfactory anæsthesia can be maintained for a long time without the cyanosis from impediment to the breathing, and without the rattle consequent on the backward flow of the saliva. Bromethyl is quite unnecessary for children or weakly and delicate individuals. We have never seen anything to cause us anxiety when using Haffter's doses; but we use only one small dose, and never repeat it, as it is only by prolonging the bromethyl narcosis that we feel any danger is incurred. It should not be administered for any prolonged operation.

Regli has described a deleterious action on the kidneys and lungs after the use of bromethyl alone, and, in the case of alcoholics, he has entirely failed to induce narcosis sufficiently deep as to ensure muscular relaxation. Abonig and Baracz give similar experiences. The latter author rightly points out that induction of chloroform narcosis with bromethyl is dangerous, although, since introduced by Ebermann, this method (the Poitou-Düplessy method) has attained great popularity in France (Dumont), and although, according to Dastre, the toxic properties of the two substances are antagonistic, both, however, act deleteriously on the heart (Löhrs) and blood-pressure, and whereas ether at once counteracts the passing depression caused by bromethyl, chloroform rather accentuates it.

The results of bromethyl-chloroform narcosis recorded by Rein in Diakonow's clinic are not in favour of this combined procedure. In 167 cases asphyxia resulted 12 times, the pulse stopped in 8, and no fewer than 7 deaths occurred in 2260 cases anæsthetised.

Whether the drop-method of administering bromethyl or the administration by Braun's apparatus prior to ether should remove the last objection to this procedure, if the maximum dose is never exceeded has still to be proved. We do not consider it adapted to all cases. Partsch's experiences (Larisch) are very much in favour of the drop-method. The method above described of administering bromethyl prior to ether so facilitates the induction of anæsthesia (both for the doctor and the patient, on account of the rapidity and ease with which it is induced in strong individuals) that we should no longer neglect such an excellent expedient. For all cases where there are no definite contraindications to a general anæsthetic, it is immeasurably superior to medullary anæsthesia.

A period of excitement with screaming, struggling, and clonic and tonic contractions of the muscles, accompanied by difficulty in respiration and cyanosis, reflex action on the heart and respiration, spasmodic respiration, or arrest of both heart and respiration, we have never seen occur in bromethyl anæsthesia. How these untoward accidents can be avoided with pure ether anæsthesia we have already fully discussed in an earlier chapter on Anæsthesia.

In a certain number of diseases there are absolute contraindications to the use of ether as well as chloroform, as one or other could only be administered at a risk to the patient's life.

Amongst those contraindications are included all those conditions with which are

associated advanced degeneration of the cardiac muscle, of the liver, of the kidneys, or of the lymphatic system—that is to say, in a number of conditions implying disturbances of general nutrition, such as Addison's and Basedow's diseases, "cachexia thyreopriva," severe forms of anæmia, marked degrees of fatty degeneration and alcoholism, conditions of inanition, sepsis, severe poisoning, diabetes (Becker has collected twelve cases of death from diabetic coma following anæsthesia), and particularly the status thymicus and status lymphaticus.

According to Mikulicz and Stein, chronic inflammation of the cervical glands increases the risk of anæsthesia. Death may occur after operation in patients who are of a "lymphatic diathesis" (Doyer),[1] even without enlargement of the thymus.

The number of deaths under an anæsthetic (ether as well as chloroform) in subjects with enlarged thymus and enlargement of the lymphatic apparatus is proportionately high, and is all the more striking from the fact that the victim is usually in the early decades of life, when, as a rule, the administration of a general anæsthetic presents the fewest dangers. Friedjung, in his review of the literature relating to the status lymphaticus, has found only one death under ether, as opposed to numerous deaths under chloroform. Dr. Hedinger reported to us a case of death following the administration of ethylbromide. Here also the status lymphaticus was present. In our own practice, one death under ether (in a boy aged sixteen years), which occurred, in 1896, during an operation on a fistulous empyema, depended on the status lymphaticus. In these cases death occurs from cardiac paralysis *during* the administration of the anæsthetic, but it occasionally occurs *after* the administration of the anæsthetic. In goitre, and especially in cases of Basedow's disease,[2] fatalities are particularly frequent.

Dr. Hedinger has stated that the *post mortem* examinations held in the Pathological Institute at Berne (Langhans) showed that the status lymphaticus or a persistence of the thymus was present in all the cases of death under chloroform. This is in accordance with Kundrat's statements. The same conditions were also found in a case of Basedow's disease, where the patient died suddenly after "struma extirpation." The explanation may be found either in mechanical influence on the heart or its nerves, a hyperthymisation or an autointoxication, from inefficiency of the lymph glands in removing the products of assimilation, or in a hypoplasia of the chromafin apparatus.

Friedjung attributes the fatal issue in part to mechanical causes resulting from the position of the trachea between the thymus and the innominate artery. But Paltauf and Kundrat very properly do not consider it as positively proved that the cause is mechanical. Schlömischer points out that, in subjects affected with the status lymphaticus, death does not depend on the nature of the anæsthetic, but occurs as frequently with ether as with chloroform. It is, therefore, desirable to percuss out the sternal region, to palpate the supra-sternal fossa, to examine the throat for tonsillar hypertrophy, and to investigate the spleen, since by neglect of these precautions the patient's life may be exposed to extreme danger. If it should then be deemed necessary, a preparatory course of thymus extract may be adopted, as suggested by Escherich.

The opinion we hold and the procedure we favour in regard to anæsthesia have been already stated in the chapter dealing with the regulations for the beginning of the operation.

In the absence of the conditions mentioned previously as contraindications, ether administered in the way already described is the best anæsthetic.

(1) If the state of ether-intoxication (Sudeck) is desired, the ether is administered on Czerny's mask, which is firmly applied to the face, a form equally useful for either short or interrupted anæsthesia (*e.g.* combined with local anæsthesia).

(2) It may be administered by means of the drop-method (Hofmann and Witzel)

[1] *Annals of Surgery*, 1904.

[2] In these subjects a combination with the status lymphaticus is, according to Mobius, Spencer, and Schnitzler, of frequent occurrence.

where the pelvis is lowered and, if necessary, the head is thrown back, or as an equivalent, Braun's bellows may be brought into operation.

(3) It may be administered in combination with other drugs if the operator finds the individual resistant to the action of the anæsthetic. Morphia may be previously injected (Riedel, Kümmel, Witzel, and others) or the anæsthetic may be induced with a single dose of ethylbromide. Stimulants should always be given half an hour before operation.

In all cases where there is no hindrance to the breathing and no affection of the respiratory organs, ether must be regarded as the most suitable anæsthetic. The best method of procedure is to induce narcosis with a single dose of bromethyl, and to maintain it with ether in measured doses. The drop-method is not sufficient, but success is generally ensured by pouring on measured quantities of ether, according to the effect produced on the patient.

In this way, as proved by statistics collected from our clinic by Dr. Oppikofer, quiet anæsthesia is obtained, on an average, in 6·41 minutes, the patient's sensation and respiration requiring careful observation.

The condition of the pupil is a valuable indication of the degree of anæsthesia. According to Kappeler, as sensibility disappears the pupil becomes small, whereas in the excitable stage it may be dilated. The behaviour of the pupil is, however, much less constant with ether than with chloroform. In prolonged ether narcosis the pupils should be watched, and this is still more important when there is a special necessity for inducing anæsthesia with chloroform. In a patient under the influence of chloroform, whenever slowing of the pulse is apparent enough has been given. Further administration is to court danger, while slowing of the breathing is also a sign to be cautious in continuing the chloroform.

Stertorous breathing, athetosis of the finger (Koblank), complete muscular relaxation, and irregular pulse indicate that the full permissible dose has been exceeded. It is frequently difficult to obtain quiet and complete narcosis in alcoholic subjects. The difficulty is best overcome by a previous injection of $\frac{1}{2}$ grain morphia. We restrict the use of morphia, fearing, like Kümmel, the production of respiratory disturbances. Moreover, by giving alcohol in large doses, we can much more efficiently facilitate the induction of anæsthesia. Franck also protests against the use of morphia on account of its depressing action on respiration. The addition of $\frac{1}{60}$ grain atropin, as suggested by Dastre, would appear to guard against dangerous reflexes (*e.g.* cardiac arrest) acting through the vagus. It certainly acts effectively by preventing the secretion of saliva, but Franck asserts that it cannot be given in sufficiently large doses to be of any service.

Chloroform should supplant ether in all cases where, in the absence of a definite contraindication, disease of the respiratory organs is found to be present. It should invariably be given by an apparatus which allows of an admixture of air, at first in minimum doses, and its administration should be regulated by the condition of the pulse and the state of the pupils.

Prolonged anæsthesia with chloroform should always be avoided, and in any case it is only to be employed with an apparatus which ensures accurate measurement of the dose. According to Wohlgemuth[1] Neudörffer was the first to conduct investigations with chloroform and oxygen. Kreutzmann improved the method of using it, while Hillischer recommends gas and oxygen anæsthesia, and Krönig still commences his oxygen-ether-chloroform anæsthesia with laughing gas.

In 1901 Wohlgemuth adopted a practical method of administering chloroform and oxygen, in which oxygen from a steel cylinder was passed through a U-shaped tube over a wad soaked with chloroform. The Roth-Dräger drop-apparatus for chloroform, ether, and ethyl bromide is an improved and simplified form of Wohlgemuth's apparatus. By its means the quantity of chloroform mixed with the oxygen can be accurately measured, and any alteration can at once be made by simply moving an indicator.

Wohlgemuth states as the advantages of oxygen-chloroform anæsthesia:—The

[1] *Arch. f. klin. Chir.* Bd. 64.

face retains a good colour, the pulse is slower, the breathing regular and quiet, and the pupils are contracted and do not react, while the stage of excitement is absent or short, and there is no salivation.

The Roth-Dräger apparatus admits of the administration of 3 litres of oxygen per minute. If the indicator points to 25 drops, the mixture contains $\frac{1}{2}$ gr. (5 min.) of chloroform; and as a rule it is sufficient to have the indicator at 35 drops, while in alcoholics it has to be placed at 65 drops. Wohlgemuth found 0·1 of chloroform in 1 litre of oxygen was necessary for satisfactory anæsthesia.

Oxygen-chloroform anæsthesia should replace ether, when the latter is contra-indicated by dyspnœa or disease of the lungs.

The best forms of apparatus are built on Braun's principle, *i.e.* it is possible to administer different anæsthetics simultaneously, or alternately, by simply turning a stopcock. According to calculations made by Kionka for Krönig, the Roth-Dräger apparatus is unsatisfactory when the anæsthetic is begun with ether, for only 5·7 per cent of ether vapour by volume is produced instead of 7 volumes.

Krönig begins by placing 45 drops of chloroform and 180 drops of ether in the apparatus, and continues the anæsthesia with 5 drops of chloroform and 120 of ether per minute. As a rule, however, he induces the anæsthesia with laughing gas (Bennet's inhaler) just as we use ethylbromide.

By following the instructions we have already given, the risk of suffocation and fainting with which we had formerly to contend need no longer be faced. Suffocation may follow incautious administration and depends on closure of the glottis owing to the so-called "swallowing of the tongue" (really falling back of the epiglottis), or on spasm, or on blood, mucus, or food getting into the glottis. Syncope is dependent on cerebral anæmia.

Suffocation by too intense stimulation of the terminations of the fifth nerve (also of the laryngeal nerves, and of the vagus terminations in the upper air passages) is due to the sudden contact of concentrated vapours. This is the cause of the reflex spasm of the glottis and of the involuntary muscles of respiration, and also of cardiac arrest. Rosenberg prevents these reflex effects by spraying the mucous membrane of the nose with a 10 per cent solution of cocain, and François Frank also recommends this method.

"Swallowing the tongue" is a consequence of the paralysis of the muscles of the tongue and pharynx, the flaccid epiglottis falling back and occluding the entrance to the larynx during inspiration. In a patient in whom we had to resect the lower lip along with the chin and the central part of the jaw, we were easily able to convince ourselves that such is really the mechanism.

This complication is avoided by the Heiberg-Esmarch grip, by placing the four fingers behind the angle of the jaw and pushing it forwards. The effect of this, as we were able to demonstrate in the above case, depends not merely on the pushing forward of the tongue—how frequently we see that pulling out the tongue with forceps has no effect—but on its being lifted up, thus putting the glosso-epiglottidean ligaments and the epiglottis on the stretch. Our mask is constructed with two rings (Fig. 23) for the thumbs, the fingers being kept in such a position that they are ready to grip the jaw. Witzel prevents its occurrence by having the head bent backwards so that the muscles from the jaw to the tongue and larynx are put on the stretch.

Obstruction from blood, saliva, or mucus is avoided by inclining the body with the head downwards.

Food may be prevented from entering the larynx by keeping the stomach empty, either by a fast for three to five hours previous to the operation, or, where this is impossible, owing either to the exhausted condition of the patient or to the pressing necessity for immediate operation, by emptying the stomach by means of the syphon. This should never be forgotten. Vomiting of itself is of no consequence, except in so far as it brings up food-stuffs. It seldom occurs, however, if the stomach be empty. A special precaution to be taken to heart by young anæsthetists is not to keep the jaw forward when vomiting sets in, as by lifting up the epiglottis stomach contents

gain access to the larynx.[1] Attacks of syncope are far graver than the danger of suffocation. The best means of preventing the cerebral anæmia, which is responsible for sudden syncope, is by placing the patient on an incline, with the head more dependent than the trunk and legs. The introduction of the Trendelenburg position has made it very easy to carry this out, and experience goes to prove that syncope need not be feared with the patient in this position. This gives the Trendelenburg position the advantage over that of Rose, in which the operation is performed with the head hanging over the end of the table.

Further, cerebral anæmia is to be expected when there is extreme loss of blood, and, when this is unavoidable, the anæsthesia should be immediately stopped. The best means of avoiding the danger consequent upon the loss of blood is immediate intravenous transfusion of a ·75 per cent salt solution at 38° to 41° C. The administration of the anæsthetic should be stopped also in cases where anæmia of the brain is produced, *e.g.* in ligature of the carotid.

Another important cause of cerebral anæmia is marked cooling of the body. This is all the more important from the fact that, in every prolonged anæsthesia, whether from chloroform or ether, not only does the body temperature fall but the blood-pressure is considerably lowered. It is to be avoided by keeping the patient warm.[2]

Fear and anxiety perceptibly increase the tendency to syncope. In such circumstances a dose of morphia may be ungrudgingly given before operation, but an appropriate dose of alcohol, or, better still, of tea with some brandy in it, is perhaps more effective. According to Feilchenfeld, the addition of five or six drops of tincture of strophanthus is sufficient to ensure complete composure if given on the morning of, and for two nights before, the operation. The subcutaneous injection of morphia before beginning the operation would seem to be a very doubtful proceeding, because in certain persons morphia rapidly produces a sensation of uneasiness with accompanying attacks of syncope.

In one of our last cases of death under chloroform, in which all precautions had been taken, we are inclined to ascribe death, which took place at the very commencement of the operation, to this idiosyncrasy. The patient had had an injection of $\frac{1}{6}$ grain of morphia immediately before the operation, instead of half an hour beforehand, as had been ordered. The patient, a woman of eighty years of age, suffering from trigeminal neuralgia, collapsed at the first incision, the pulse disappeared, respiration stopped, and the face assumed a bluish tint.

Finally, cerebral anæmia from shock consequent upon too early commencement of the operation must be guarded against. If the sensibility is not entirely suspended, a sudden intense pain in certain sensitive nerve areas may result in severe shock, as Crile has quite recently shown. Cushing has also noticed similar shock during anæsthesia when large nerve trunks are severed. This can be avoided by making the skin incision under cocain or by injecting the nerve trunks with cocain.

Stein,[3] who has a wide experience in anæsthesia, draws special attention to the sudden onset of the following symptoms, viz. dilated pupils, intermittent breathing, rapid pulse and pallor, when very sensitive tissues (parietal peritoneum) are handled. Probably the greatest benefit derived from morphia is that it alleviates these unfavourable conditions, which are reflexly produced and occasioned by pain. It also prevents the stage of great excitement during which impatient administration of the anæsthetic is particularly dangerous.

If cardiac and respiratory arrest (which are usually associated with pallor or slight cyanosis and dilatation of the pupils) should occur during anæsthesia, in spite of careful attention to the above prescribed rules, there remain but three reliable procedures, viz. artificial respiration, transfusion, and cardiac massage. Artificial

[1] A short time ago we saw a fatality occur during ether anæsthesia because the stomach had not been emptied. As the anæsthetist did not immediately pay attention to this, asphyxia resulted from vomiting.

[2] According to Allan a higher temperature of the surrounding air is dangerous. In animals anæsthetised in a heated room the temperature rises while the blood-pressure falls in a marked degree.

[3] *Prager med. Wochenschr.*, 1903.

respiration is the expedient to which one naturally turns in every case. As long as respiration continues there is hope of resuscitating the cardiac and cerebral action. Many experimenters have been much astonished by the fact that animals, if artificial respiration be kept up, are not killed even by a very considerable pressure on the brain, and it is unfortunate that in man we have not got a convenient means of inducing and maintaining respiration. With Kronecker's apparatus a deep and regular respiration can be kept up for hours, by firmly tying a tube into the trachea and pumping in air periodically. There appears to us no doubt but that the inefficiency of artificial respiration in man, in a certain proportion of cases, depends upon imperfect methods of carrying it out. Larborde reflexly stimulates the voluntary muscles of respiration by rhythmical traction on the tongue, with irritation of the naso-larygneal nerves. Knapp and others extol this method, which is supposed to act by exciting the respiratory centre through irritation of the glosso-pharyngeal and superior laryngeal nerves. Strong faradic stimulation of the phrenic nerves, as already described, is very useful under certain circumstances, and we are not convinced of the general applicability of Braatz's objections to the procedure.

Of the methods in vogue for inducing passive respiratory movements, that of Schüller is, according to Djelitzin, the most effective. The same method was introduced in our own clinic quite independently by Roux. It consists in raising and forcibly depressing the lower costal arches by seizing them from above with four fingers close to the sternum (Djelitzin). How deep an inspiration and expiration are thus obtained can easily be demonstrated. Djelitzin at the same time raises the thorax and relaxes the abdomen by flexing the thighs.

Sylvester's method, also very successful, consists in stretching the thoracic muscles by raising the arms till the elbows touch behind the head, and then forcibly depressing them against the ribs and towards the sternum. The tongue must be simultaneously pulled out or tracheotomy performed. Brosch cordially agrees with Djelitzin's observations and writings on the technique of Schüller's method. He has established the fact that the greatest increase in the capacity of the thorax is obtained by increasing and decreasing the sagittal diameter. He therefore places a high cushion between the shoulders, moves the arms upwards past the head, and then forces them backwards towards the ground, thus causing inspiration. For expiration he presses the approximated elbows with increasing force against the chest wall.

Of the methods of pumping air into the lungs Kronecker's apparatus seems to us the most efficient. The mouth is kept open for expiration.

Transfusion may take the form of auto-transfusion by placing the body in a sloping position.

The supreme importance of the position of the body during anæsthesia has been recently demonstrated by the interesting experiments of Leonard Hill on the influence of gravity on the circulation. In dogs rapidly anæsthetised with chloroform, or chloroform and ether, the pressure in the carotids rapidly sinks to zero, rising immediately the body is raised into an inclined position with the head low, if the abdomen is compressed or firmly bandaged. These phenomena are not influenced by artificial respiration. With ether the blood-pressure falls much less rapidly, and the action of both anæsthetics continues for some time after their administration has been discontinued.

Opening the abdomen when the feet are lower than the head causes a serious fall in the blood-pressure. The risk run by persons in whom the blood-pressure is *a priori* low and whose heart action is feeble (changes in the heart muscle, or exhaustion from tachycardia) is particularly great if the effect of the influence of gravity on the circulation be not carefully considered. Further, the normal compensation for the influence of gravity brought about by the vaso-constrictors of the splanchnic system is upset in all persons who have been in the horizontal position, a condition occurring in a large number of our operation cases. Although cessation of respiration always occurs first, yet, according to Hill, it is the vaso-motor paralysis which induces the most urgent symptoms. But the final and most dangerous arrest of respiration (with shallow Cheyne-Stokes breathing) is the result of a failing blood-supply to the

respiratory centre and to the brain in general, and is consequent upon vaso-motor paralysis, which can only be removed by rapidly raising the blood-pressure.

That the heart can still continue to beat after the brain is paralysed is accounted for by the fact that the circulation may persist longer in the coronary arteries.

It should also be kept in mind that firm bandaging of the abdomen, which Leonard Hill has practised in animals, is an aid to the vaso-motor nerves in producing compensation for lowered blood-pressure. This procedure is, however, only permissible when it does not seriously interfere with respiration—that is to say, where respiration is almost completely thoracic, and therefore chiefly applicable to women. For this reason chloroform is very safe in parturient women (Hill). It is more advisable in every case where vaso-motor paralysis is apprehended—that is, according to Hill, in every case of narcosis, and especially chloroform narcosis—to place the patient in an inclined position.

According to Hill it is of greater importance to raise the pelvis than to raise the legs, but this must not be carried so far as to slowly engorge the heart, for chloroform itself may directly paralyse the heart muscle. This was proved by Gaskell and Shore in their experiments with crossed circulation, the brain being excluded and respiration being maintained. Hill recommends the alternate compression of the abdomen and the thorax: by the former the heart is filled and by the latter emptied. This is, in short, the procedure usually followed in performing artificial respiration.

Next to transfusion, therefore, correct position of the body is our most valued safeguard, but more as a prophylactic measure — a precaution to be taken at the commencement of the operation. Every operation under chloroform and even when the patient's blood-pressure is naturally low, should be performed with the body in a slightly sloped position, the pelvis and lower extremities being slightly raised, and attempts at resuscitation, in all cases in which the blood-pressure has fallen, should be conducted with the body inclined at a moderate angle.

Heart massage has recently proved one of the most effective measures against syncope when the latter is produced by the action of the anæsthetic on the heart.

Krönig recommends a rapid succession of blows over the præcordia, while Hill compresses the abdomen and thorax alternately. A still more effective method of carrying out this principle is by massage of the exposed heart, as recommended first by Schiff, then by Batelli [1] and Prus, and carried out by Tuffier, Hallion, Maag, and others on the living subject.

By this heroic treatment Prus succeeded in resuscitating sixteen out of twenty one animals killed by chloroform, and thirty-one of forty-four artificially suffocated although respiration had been suspended for an hour.

Kemp and Gardiner [2] were able to resuscitate by cardiac massage eleven of twenty-three dogs killed by chloroform. They recommend elevation of the pelvis, artificial respiration with intubation and an air pump, incision of the chest wall, and even resection of parts of fifth and sixth ribs. Two fingers are then passed behind the heart, and the latter is rhythmically compressed against the chest wall or against the thumb. Schiff, and also Batelli, performed artificial respiration at the same time. Care should be taken that the temperature be sustained.

Bomcard [3] has successfully performed cardiac massage in animals through an incision in the diaphragm. A mesial incision was made downwards from the xiphisternum through which the heart was pulled down and massaged till it beat again with regularity.

Prevost and Batelli have restored the heart contractions by means of alternating currents of 240 volts, one electrode being inserted in the rectum and the other over the heart. Kronecker places one electrode in the œsophagus instead of over the heart.

Prus, however, employed another aid to resuscitation, viz. transfusion, which was merely another means of attaining Hill's object of supplying blood to the heart and brain. The extraordinary effects of this in hæmorrhage, where the blood-pressure has fallen to a minimum, are well recognised. In such cases auto-transfusion is no

[1] *Journal de physiol.*, 1900. [2] *Revue med. de la Suisse romande*, Oct. 1903.
[3] *New York and Philadelphia Med. Jour.*, 1904.

longer sufficient. Moreover, as it is so often required in those cases where, combined with severe hæmorrhage, the blood-pressure is being lowered by some toxic absorption, it would appear quite justifiable as a means of resuscitation in those cases where the blood-pressure has fallen.

Borrow has seen such success follow the subcutaneous injection of relatively small quantities of normal saline solution that he is quite enthusiastic about this method. Long before Borrow's paper was published, we were in the habit, in our lectures, of recommending intravenous transfusion as a valuable remedy in cases of chloroform collapse, and we instructed one of our students, Miss Gomberg, to study the action of transfusion experimentally under Kronecker's direction.

Some of our clinical experiences are thoroughly convincing. A boy of eleven, who was being operated on for a retro-maxillary tumour, suddenly became pulseless at the end of the operation, respiration ceased, and the pupils no longer reacted. Stimulating injections and subcutaneous infusions were administered without success. Lowering the head had no effect. Tracheotomy was performed and artificial respiration begun; at the end of twenty minutes no reaction could be made out beyond an occasional spasmodic contraction of the face; the median basilic vein was opened (no blood escaped from it), and one litre of salt solution at 41° C. was slowly injected. Spontaneous respiration then appeared, the cardiac impulse became palpable, and, lastly, the pulse returned at the wrist.

After removal of a fibro-sarcoma from the base of the skull in a boy, paralysis of respiration supervened, and lasted for one hour, with a just perceptible, very rapid pulse (150), and complete unconsciousness. Chloroform had been given through a tracheotomy tube. Præcordial massage and artificial respiration produced no result, although the application of a strong faradic current to the phrenic nerves (the disc on the abdomen and the small rounded electrode on the anterior border of the scalenus anticus) caused satisfactory respiratory movements. Immediately on stopping the faradic current the pulse became weak. After an hour two litres of salt solution were transfused into the median basilic vein. One litre had been previously given subcutaneously with no effect. Almost immediately spontaneous respiration commenced, and the patient began to respond when shouted to. In cases of death from ether, such as those of Kaarsberg, where respiratory arrest occurred while the heart continued to beat, transfusion might have been equally successful.

By filling the heart with fluid, therefore, the activity of the cardiac and respiratory centres may be stimulated, even after prolonged arrest. Kemp and Gardener recommend that the saline solution used for intravenous injection (up to $2\frac{1}{2}$ litres) be heated to a temperature of 40° C., at which degree it is sufficiently warm to exert a stimulating action of the heart. According to Gottlieb's experiments, the blood-pressure may be permanently improved by repeated injection of $\frac{1}{10}$ milligram of adrenalin (*i.e.* approximately two minims of a 1-1000 solution), which effects a direct action on the cardiac ganglion (Münch). He obtained this reaction after complete arrest of the heart for five minutes, especially when he combined it with massage and compression of the præcordia.

Mankowsky even considers that, in apparent death from chloroform, injection of suprarenal extract is more efficacious than any other means of resuscitation.

Our experience in such cases points very definitely to intravenous transfusion. Subcutaneous infusion, when the blood-pressure is reduced to a minimum, is not rapid enough, although it is sufficient in cases of respiratory arrest when the pulse is good; but when syncope has supervened, and subcutaneous injection has no effect, intravenous injection may still be of use. It must be continued to such an extent that the circulatory system is so filled as to ensure that a sufficient quantity of blood goes to the heart, and is thence sent to the brain. We have used up to two litres to attain this object.

It is obvious that artificial respiration and alternate abdominal and præcordial massage must not be relied upon in cases of cessation of respiration. In so far as the fall of blood-pressure and consequent collapse depend on vasomotor paresis (Hill), transfusion is more strongly indicated than any other treatment. If, as Winogradoff,

Schmidt, and Kronecker maintain, this depends on paralysis of the cardiac ganglia, then it, like any other method, will have no influence on a fluttering heart.

It is still an open question whether any benefit is derived from direct stimulation of the cardiac muscles by the König-Mass method, which consists in rhythmical compression of the heart by repeated firm compression of the præcordia. Körte brought a patient round after forty minutes' continued cardiac arrest by this method, combined with intravenous transfusion of salt solution. Kraske was the first to point out that the success attributed to expansion and compression of the thorax in artificial respiration was, in part, due to the artificially-established circulation.

Lockhart Mummery[1] avoids giving stimulants in cases of shock. He advises placing the head low and giving an intravenous injection 1 : 20,000 solution of adrenalin in saline (in case of laparotomy it may be injected into the abdomen) compressing the abdomen, and—as has been already done in America—raising the blood-pressure by pneumatic compression of the extremities.

The improved methods of administering ether have rendered the use of methyl chloride superfluous, although no less an authority than Spencer Wells employed it as his chief anæsthetic. Similarly ethylchloride (Kélène) has no claim to be recommended as a general anæsthetic, as it is not free from danger and offers no obvious advantage over ether or bromethyl.

Ethylchloride was introduced as a general narcotic by Billeter and Carlson. It is much praised by Lotheussen for short operations, as a result of his experience with it in v. Hacker's clinic at Innsbruck. Five grammes are sprayed from fine tubes on to wool, so that it freezes, and this is then inhaled from a Breuer's mask. It is said to cause rapid narcosis, followed by rapid awakening, generally without vomiting. Dumont also praises it. He pours 5 to 10 c.c. into a large Juillard-Dumont ether mask, and when the patient is anæsthetised he continues with ether. He recommends it more especially for the induction of ether narcosis, as its own effect is very transitory, but König's experiments do not say much for it. Seitz published a fatal case not long ago in the *Correspondenzbl. für schweiz. Ärtze.*

In 1896 Soulier discussed the subject and recommended ethylchloride. Several years ago we gave it a trial for general narcosis, with unsatisfactory results, which we cannot, unfortunately, report, as the clinical records of the cases have been lost, and we are therefore not in a position to give definite information as to the preparation employed. Ethylchloride, which boils at 12·5° C., is of chief value as a local anæsthetic, acting by the withdrawal of heat.

Mixtures of different anæsthetics render it more difficult to pronounce a judgment on the individual effects of each.

Kemp points out, if the mixture containing chloroform be considered from the point of view of its volatility, ether remains ether and chloroform chloroform, and, when it is administered by the open inhalation method, the effect is that of pure chloroform. The popularity enjoyed by Harley's A.C.E. mixture, and Billroth's chloroform and ether mixture given in a special way, depends partly upon the fact that they are comparatively safe anæsthetics. If they were used separately, a much more reliable opinion of their value would be formed.

The researches of Honigmann and Kochmann (Kionka) have shown that when two narcotics are used in combination, their anæsthetic properties are considerably increased.

In our opinion it is best to be able to control the mixture by an apparatus, so that one anæsthetic can be given after or in conjunction with the other, as in Braun's apparatus already described.

By means of it the dose can be varied, and either pure chloroform, pure ether, or a mixture of both given according to requirements. If the patient be not sufficiently under the influence of the diluted ether, the chloroform cock can be further opened without exceeding a safe quantity. If, on the other hand, the full dose of chloroform has been given, it may be shut off, and ether, with the correct proportion of air, administered alone.

[1] *Lancet*, March 1904.

A double bottle is used (150 c.c. of ether and 40 c.c. of chloroform) with a bellows which, when squeezed at each inspiration, admits 90 c.c. of air. At first the air contains 6 vols. per cent of ether vapour and 1·7 of chloroform, but later, as the result of cooling, it contains only half this quantity.

Braun, like Witzel, ourselves, and others, only considers ether reliable when it is inspired in a diluted form. In 6 to 7 vols. per cent it produces an ideal narcosis without cyanosis, and without increasing salivary secretion. Where this proportion is not powerful enough, it should be strengthened with chloroform, or chloroform should be substituted. This is the principle on which his apparatus is constructed.

Willy Meyer has also shown that when ether and chloroform are mixed, a new substance, anestol, is formed, the use of which he does not consider entirely safe.

Korff has made efforts to reinforce the action of the anæsthetic by administering scopolamin and morphia, and Kionka (Kochmann) has shown that in the case of dogs the action of each element is greatly increased by the combination of the two drugs. In the case of man, however, several deaths have been recorded as the result of scopolamin-morphia narcosis. According to a more recent communication, Korff injects $\frac{1}{6}$ gr. (0·01) of morphia and $\frac{1}{60}$ gr. (0·0012 gr.) of scopolamin four hours before operation, the injection being repeated two hours later and again half an hour previous to its performance, from which procedure he has not observed any evil effects. Kümmel injects only $\frac{1}{100}$ gr. (0·0005) of scopolamin and $\frac{1}{6}$ gr. (1 cg.) of morphia 1-1½ hours before operation with a subsequent administration of ether. Death has been noted, however, by Lasek, Rys, and Zahradnicky, after a repetition of this dose. Israel has recorded one death during the operation and two fatalities after operation, while Dick has notified three deaths occurring in the course of operating.

Quite recently Matthæi has recommended alcohol narcosis, the alcohol being administered at a temperature of 50° to 60° C. by means of Kappeler's apparatus, with an enema of $\frac{1}{3}$ alcohol in water previously introduced, an alcoholic subject requiring to take beforehand a bottle of strong wine. This method may be brought into use when there are positive contraindications to the use of chloroform or ether. Death might have been prevented, for example, by the employment of alcohol narcosis, in a case we had of excision of the thyroid in a cretin with marked tracheal stenosis, where the operation was commenced without an anæsthetic, but where, on account of the patient's unruly conduct, it had to be continued under a general anæsthetic.

TREATMENT OF WOUNDS

(p) Sterilisation of Dressings, Instruments, and Lotions

All the skill brought into play by the surgeon is of no avail if steps are not taken to prevent infection of the wound. Apart from the immediate risks of the anæsthetic, which are reduced to a minimum if it is administered with sufficient care and in accordance with the directions we have laid down, the only dangers associated with an operation are wound infection and bleeding in the case of a serious operation. The exclusion of micro-organisms from the wound, according to Lister's principles, is of vital importance to the patient, though fortunately the time is long past for wounds to be poisoned by antiseptic agents.

After Fr. Schültze, Schwann and Helmholtz, Schröder and Dusch had prepared the way for the demonstration of the fact that air, after being heated, treated with sulphuric acid, or filtered through cotton wool, does not cause putrefaction if organic material be excluded, Pasteur enunciated the broad principles of the observation that no decomposition of organic material occurs without the presence of living germs. Innumerable workers, for example Tyndall in the case of the air, and Rindfleisch in the case of water, have demonstrated whence these living germs originate. Lister has, since 1867, on the foundation laid by Pasteur, built up the present method of

treating wounds by proving that decomposition in wounds only occurs after the admittance of organic particles from without. Jules Lemaire had previously formulated the axiom, "Pas de suppuration, si l'on tue les germes," while Lister, with his usual caution, stated that these organic particles are really germs capable of development.

Koch has enabled us to discover in individual cases the germs which are responsible for wound infection, and to study their action with closer attention, after Billroth had worked on the same lines, but with insufficient methods. Billroth and Thiersch assumed the presence of germs in the interior of the tissues, but the adoption of improved methods has served to prove that, in healthy individuals, germs only exist on the surface—skin and mucous membranes—and that they are always carried into the deeper tissues from the exterior.

Our knowledge of wound infection and its prevention rests on this basis. Schültze, Lesser, and Schede transplanted Lister's principles into German soil, where they at once took root and bore fruit plentifully, a result mainly owing to Volkmann's enthusiastic initiative. But in spite of the enormous amount of work contributed in the last decade to advance the procedure in the treatment of wounds, a complete understanding of the best means and methods has only been reached in a few directions. So much has, however, been ascertained that we can with absolute certainty prevent infection of wounds as far as this is dependent on the materials necessary for the treatment, and especially of everything which is comprised under the heading of dressings, instruments, and lotions destined to come into contact with the wound surface. The greatest advance in this direction is, that in the preparation of these materials we have abandoned the old highly-complicated methods in favour of those of modern simplicity, which enable us to observe the requirements we have advocated, not only in the elaborately-furnished clinics and operating theatres, but also in the simplest and most humble conditions now introduced into practice.[1]

As regards the instruments, dressings, and lotions, they can be sterilised by means of boiling, or by subjecting them to the action of circulating and compressed steam for a sufficient length of time. Infection by direct contact, generally designated as contact infection, which threatened the life of every person operated on prior to Lister's antiseptic treatment, is thus entirely prevented. Although the bacteriological therapeutics, especially in wound treatment, are not at present making remarkable progress, the acquisitions already made to our knowledge will not readily be abandoned.

The first essential in the treatment of wounds may therefore be stated as follows: all solid and fluid substances which come into contact with a wound, either directly or indirectly, must be sterilised. This is accomplished by boiling them for twenty minutes in ordinary water, or in solutions less injurious to the materials boiled, such as a 1 per cent solution of soda for instruments. Sterilisation of dressings and instruments is materially shortened by using circulating and compressed steam, a method by which, if allowed to act for fifteen minutes at 120° to 125° C., perfect sterilisation is obtained, as Tavel and his pupils have amply demonstrated.[2]

Superheated steam, however, is to be avoided. Scot Skirving[3] has made careful investigation into this matter, and finds that, so long as the steam is in contact with the water which produces it, it is saturated. When it is separated from the water its temperature may be raised by heat without its pressure being altered: the steam is then superheated, although it fails to obtain any greater amount of latent heat. If a steriliser is subjected to further heat when all the water has been converted into steam, the steam becomes superheated; and Esmarch and Rubner have shown that superheated

[1] We are not, like Walcher, inclined to limit the aseptic field in operations as much as possible. It requires an unduly greater amount of watchfulness to keep at a distance dangers which surround the body than it does to exclude them altogether. It is, of course, correct that the theoretical standard should be that nothing infective should approach the wound, and the determination to prevent menstruating nurses from attending operations was thoroughly justified.

[2] Braatz has directed attention to an important point in sterilising by steam,—that dressings should not be warmed beforehand as is customary, as if this is attempted the steam becomes superheated, and is thus no longer saturated, but rendered useless, a direction which also applies to steam not subjected to pressure.

[3] *Scot. Med. and Surg. Journal*, Dec. 1904.

steam proves less effective than saturated steam, since it has only the action of hot air, requiring the space of an hour at a temperature of 170° C. to kill the spores of organisms. For the same reason sterilisation will prove imperfect if all the air has not been previously expelled from the steriliser, which often results from failure to open the valve at the bottom of the steriliser, where the air is found to collect. The expulsion of air is also interfered with by packing too closely the dressings in the steriliser.

The prevention of infection of the dressings after sterilisation and before use was for many years overlooked and neglected. Only those materials can be regarded as completely sterilised which have been taken directly from the boiling or steaming apparatus by means of sterilised instruments or gloves, and applied to the wound, while the dressings should not be stored for any length of time. The same rule must be adopted for instruments and lotions, and the latter especially must be taken direct from the boiling apparatus and placed on the wound without being poured from one vessel into another for storage.

Cases in which sterilisation of the materials to be used immediately before the performance of an operation is impracticable seldom occur, and in such circumstances only those methods of storage are permissible which preserve the materials, dust-proof, in the vessels in which they were sterilised. This process can be carried out with an apparatus which, at the end of the disinfection procedure, can be completely shut up and easily carried without disturbance of the contents, the apparatus of Schimmelbusch proving singularly effective for this purpose on account of its simplicity.

According to Skirving, the dressings remain damp only if they are not at once removed from the steriliser while they are still hot, in which case they dry readily. He objects also to the Schimmelbusch drums on the ground that they do not close satisfactorily, and he quotes instances for his contention. He has, therefore, constructed a drum of his own devising, which is hermetically sealed by simply pushing home the lid. It is fitted with an inner wire cage, the holes being arranged round the sides of the instrument and close to the top. During sterilisation the apparatus must be placed upside down, *i.e.* with the holes downwards, as it is only in this position that the steam uniformly penetrates the dressings. Braatz employs a drum which is of somewhat similar construction, but one which has two sets of lateral openings, one above and one below.

(q) Disinfection of the Skin

It is, unfortunately, impracticable to extend sterilisation to every object coming into contact with a wound, as the human body will endure neither boiling water nor steam, owing to which circumstances the patient's skin, as well as the surgeon's hands, brought, during the operation, into intimate contact with the surface of the wound, are incapable of being sterilised, and it comes to be a question of how far the action of circulating steam or boiling water can be replaced by other means. These considerations are generally grouped under the heading of purification of the hands, and the subject of a possibly-perfect disinfection of the hands has given rise to lively discussions at the meetings of various learned bodies. The grouping under this title does not seem to be of a very happy nature, since the question involves not only the cleansing of the surgeon's hands and those of his assistants, but that of the skin of the patient. The last-named requirement has been long neglected, and even nowadays it is no uncommon sight to see the surgeon and his assistants scrupulously careful about the cleansing and scrubbing of their own hands, while the patient's skin is washed with a little soap and lotion immediately before the operation, receiving subsequently a few douches of corrosive lotion, proceedings which imply a contradiction. This procedure can only be partially excused on the grounds that infection conveyed by the surgeon's hands is calculated to have much more serious results than infection originating in the patient's skin. We shall afterwards return to the

consideration of this point. In the meantime we shall only observe that it is not very unusual for a severe form of infection to be carried from the patient's skin when this is the seat of a sore, however small it may be and difficult to recognise.

The present opinion of the majority of surgeons on the question of disinfection of the skin is, that sterilisation is not attainable by any means at present at our disposal.[1] Those who maintain that no process of disinfection can render the hands absolutely sterile insist on the use of gloves made of an impermeable material, which can be sterilised by means of boiling, and thus afford perfect protection against contact-infection from the bare hands of an operator.

The introduction of the systematic use of rubber gloves[2] is due to Halsted of Baltimore, and it affords a precaution which no surgeon can afford to neglect, the improvement in their manufacture, their cheapness, and their durability recommending their general use, while the thin rubber of which they are composed proves an additional advantage as not interfering with the sense of touch which formerly militated against their serviceability.

The chief use of rubber gloves is to protect the surgeon's hands from contamination when he is operating in the presence of pus or infected tissues, for which purpose they are indispensable in the daily routine of a practitioner's work. No careful surgeon at the present time makes an examination of the mouth, pharynx, rectum, vagina, etc., without protecting his hands with rubber gloves, while it is equally necessary to take similar precautions to prevent contact with any form of wound secretions.

Why then do we not systematically wear gloves for all operations? Because, strictly speaking, all the assistants and operation sisters should wear them as well as the operator, and this would entail great expense, as the gloves are continually liable to be torn by instruments or against edges of bone, when they have immediately to be replaced. In addition to this disadvantage, Heile has shown that the organisms on the surface of the skin may increase from 88 to 30,000 in the moist interior of a rubber glove.

As the sense of touch is necessarily somewhat impaired by the use of gloves, it is more difficult in abdominal cases to make an accurate diagnosis from palpation, or to handle smooth organs like the intestines. Their use is thus necessarily restricted. Finally, we cannot protect the skin of the patient in a similar manner, for, even although a thin sheet of guttapercha can be satisfactorily affixed to the skin by means of hot water, it does not adhere with sufficient firmness and is readily detached when handled.

What is therefore required is a method of purifying the skin, which, if it does not amount to absolute sterilisation, yet affords efficient disinfection. As we shall see, this implies the exclusion from the wound of pathogenic organisms capable of development, a point which is easily capable of demonstration. The question further arises whether, after having procured a thorough disinfection of the skin, an operator can secure any advantage by wearing cotton gloves, which are not only cheaper but more comfortable to wear. Originally introduced by Mikulicz, cotton gloves were for some time in general use, until it was proved that they failed to prevent the invasion of germs.

We can confirm the statement that after thorough systematic washing of the hands, it is beyond doubt gloves sodden with fluid and blood abound with germs, especially the staphylococcus albus, the most common organism in the human skin. This power of acquiring organisms possesses a certain advantage, as although the germs are present they remain entangled in the glove and have thus less opportunity of gaining admission to the wound. Since it has been definitely proved that the number of germs cannot increase during the time occupied by an ordinary operation, the absorptive power of gloves might be regarded as of considerable value, although we fail to attach much importance to this point. Heile has shown that 4·8 per cent of

[1] Sarwey, who, with Krönig, has already made such valuable contributions to the subject of disinfection, has recently confirmed this statement.

[2] Manteuffel first recommended their use in Germany, while Döderlein, Blumberg, Perthes, and specially Friedrich, by introducing seamless gloves, have brought them into general use.

the germs on the surface of the skin pass through stockinet gloves, while 28 per cent remain enveloped in the gloves. Thread gloves, and more notably the close-meshed yarn gloves recommended by Heile, are really only of service from their efficacy in the absorption of germs. It is also with the object of soaking up the secretions and possible germs that we cover up our wounds and the edges of the incision with gauze during the course of an operation, the gauze being frequently changed.

It is worthy of notice that germs have been shown to exist in gloves only when they are sodden with fluid and blood. If the gloves are changed frequently during the operation a definite quantity of infective material is removed from the hands at every change. The experimental investigations of Haegler and others have proved that the majority of the germs do not come from the air, but that they are derived from the surface of the skin.

Further, Mohaupt's researches demonstrate that, even after thorough purification of the skin, germs are left in the sweat glands, and that they reach the surface in the secretion in half an hour if the person sweats, otherwise within twenty-four hours. It follows, therefore, that gloves, to be really useful, must be periodically changed whenever saturated with blood or fluid.[1]

There are no micro-organisms on the surface of gloves when they are removed from the steriliser. For this reason gloves are of great value, and in our opinion their chief use depends on the fact that they prevent contact between the skin surface and ligatures and swabs, and therefore prevent the most serious of all forms of infection, namely, that which we have designated implantation infection.

Swabs can be very effectively manipulated with sterilised sponge-holders. Contact with the fingers is thus avoided. Ligatures, on the contrary, have to be taken in the fingers, even when they are kept in the glass tubes which Lanz introduced. Haegler[2] has proved that even when the hands have been most carefully cleansed, a ligature cannot be firmly drawn through the fingers without receiving germs from the skin surface. For this reason we are of opinion that it is of great importance that the nurse in charge of the ligatures, as well as the surgeon and his assistants, should put on gloves (even though they should be permeable ones) just before the ligatures are tied. This is also the reason why we always defer the tying of ligatures, however many there may be, till the end of the operation. At an operation for goitre, for example, it occasionally happens that as many as fifty to one hundred artery forceps are applied before any ligatures are tied.

Infection of ligatures from contact with the hands can be absolutely prevented if we follow Goepel's advice by wearing thread gloves over those manufactured of rubber. Goepel sterilises his gloves in a current of steam and applies them to his hands in a dry condition, while we prefer to remove them direct from the sterilised lotion and slip them on while they are wet.

Before putting on either rubber or cotton gloves, we must see that the hands have been as carefully disinfected as if the operation had to be conducted without the use of gloves, as the rubber may be readily torn and cotton may absorb germs from the skin. With or without the use of gloves, thorough cleansing of the hands and skin is therefore absolutely necessary.

Can the skin be cleansed so effectively that we can regard the process as disinfection? If the distinction between *sterilisation* (freedom from all germs) and *disinfection* (freedom from pathogenic germs capable of development) be maintained, it is possible that we can achieve disinfection of the skin even though we may have to give up the idea of absolute sterilisation. This is, in truth, the case, if the results of disinfection be measured by the success of our operations.

In 1899, in a communication dealing with the glove question read before the American Surgical Association, we gave, along with a chronological table, the results

[1] Heile has lately shown by experiments on animals that with frequent change of gloves even operations with infected hands can be carried out with impunity, that is to say, without any resultant infection of the wound.

[2] We would draw special attention to Haegler's excellent book on the cleansing of the hands, etc.

which we had obtained in all our operations (numbering 325 aseptic cases) performed during the winter session 1898-99. From these we demonstrated that with our routine and purely aseptic method of treating wounds we had not a single case of suppuration of a wound, let alone a more serious form of infection.

We are able to show also that, in an operation in which infection is apt to prove very serious, for example in excision of goitre, some hundreds of these operations could be performed with uninterrupted and faultless primary union (*i.e.* true adhesion and complete union in eight days). For all practical purposes, therefore, satisfactory disinfection of the skin and hands can be effected so that the severest operation may be undertaken without fear or danger, and with every prospect of uninterrupted repair in the wound.

Dührssen has expressed the opinion that surgical operations are in these modern times devoid of danger, basing the proof of his assertion on the results he obtained in 267 vaginal operations necessitating opening of the peritoneum, in 68 total excisions of the uterus, in 60 operations for uterine myomata (without a death) and in 500 other gynæcological operations, in all of which contact-infection was absolutely prevented.

We are completely in accord with Ahlfeld (although in other matters we seldom agree) when he says that the degree of freedom of the hands from germs may be judged by the results of operations. We should not, however, care to assert positively that in every case in which primary union occurred disinfection of the skin had been absolute. Lanz and Flach, in our clinic, have found that in wounds healing by first intention no intensely pathogenic organism, such as staphylococcus aureus, could be demonstrated, but only the staphylococcus albus and some others which, from our experience, we are not inclined to regard as actually pathogenic in the human subject. The fact of their constant occurrence in gloves used at operations where repair was faultless supports this view.

Brunner and also Budinger, however, have found staphylococcus aureus, an organism whose virulence is unquestioned, in wounds healing by first intention. But this appears to be rare, even according to their own statistics.

To what methods of procedure are the faultless results which can be obtained in an uninterrupted series of severe operations to be referred? On the so-called abstinence. But we use the word in a much wider sense than the gynæcologists, not in the sense of entire abstinence from operative interference, but abstinence from risk of infection with pathogenic and virulent germs. A surgeon who has to perform aseptic operations should most scrupulously guard his hands from possible contact with virulent pathogenic organisms. This indication cannot be too carefully remembered when it becomes necessary to touch an infected wound, or where examinations have to be made in which the surface of the skin comes into intimate contact with abundant infective material, as in the examination of the mouth, fauces, vagina, or rectum. In such cases, without exception, the hand should be protected by rubber gloves. Therein lies the true usefulness of gloves, namely in wearing them, not at the operation, but in the intervals between operations. Much laughter was caused when, at a meeting of doctors, while discussing the question of "operation gloves," we enunciated the paradox "gloves should be worn between the operations and taken off at the commencement of an operation." The true secret of freedom of the hands from germs lies in the use of gloves whenever there is a possibility of a large number of germs being pressed or rubbed into the skin. As Zweifel points out, on the grounds of Krönig and Reinecke's researches, the hands become spontaneously germ free in a short time if not constantly re-infected; and Haegler has shown that the dread that the deeper parts of the skin are always crowded with germs is exaggerated. He finds that, as a rule, there are no germs in the sweat glands, and in the hair follicles they are only found close to the surface. They may gain access to the hair follicles merely by friction, but are at once forced out again by the current of secretion. On the other hand, in every injury to the skin, however small, microbes at once begin to grow and multiply.

Neglect of the skin is therefore unpardonable. We do not consider it any excuse to

say that it is not possible for a doctor in practice to avoid contact with infective material in handling patients. If a doctor finds it impossible to avoid loading his hands with pathogenic organisms, then he must leave operative surgery to others. But we do not see any reason why a doctor who wishes to operate should not put on gutta-percha gloves when he has to make a digital examination of the mouth, throat, vagina, or rectum, or when he has to touch unclean skin, an eczema, a furuncle, or a fistulous wound. There still remains contamination by those germs which are present on our own bodies, or which fall by accident on our hands without our being able to avoid it. But against these we have a very sure defence in immediate and thorough purification before they have time to dry. This, too, is the sole occasion on which it is necessary to momentarily douche the skin with a strong antiseptic, especially with 1-1000 perchloride of mercury solution—a precaution which acquires a double significance when a mechanical cleansing of the skin is impracticable from want of water.

The methods which we employ to secure a satisfactory purification of the hands apply only to hands which are not highly infected with virulent organisms. Even for highly-infected hands we hold that a sufficient degree of disinfection is possible if, besides the mechanical cleansing, the skin is saturated with antiseptics, *i.e.* bathed and scrubbed in a 1-1000, or better, a 1-2000 sublimate solution for ten minutes. It can be proved that virulent organisms are in that way rendered sufficiently innocuous. Krönig and Blumberg have made extensive trial of sublamin. But in practice we ought not to require such strong disinfectants. It is certain that he who cannot conform to "abstinence," as above defined, can never know the ideal meaning of a purely aseptic treatment of wounds. He remains condemned to the use of antiseptics.

What are the methods of disinfection which yield at the present time the most satisfactory results? Furbringer's treatment with alcohol is the most reliable, and it has been extensively exploited by Reinecke of Zweifel's clinic; while Ahlfeld, who is an enthusiastic advocate of disinfection by means of hot water and alcohol, has established the benefit derived from the proper utilisation of this method, which has been adopted in numerous operations with excellent results.

We wash our hands with soap (and the much-defamed brush) under a stream *of very hot water*, so that the smallest wrinkle is thoroughly scrubbed, without regard to the time it takes to complete the process. The hands are not dried, but are thoroughly freed from soap under a stream of warm water. The hands are then scrubbed with fresh sterile brushes under warm running sterile water, after which they are treated to a second scrubbing with 85 per cent alcohol and fresh brushes that have been steeped in alcohol. Ahlfeld prefers to use 96 per cent alcohol. Every uncovered particle of skin is thus treated, with further brushing, inch by inch, especially the nails and nail-folds, without any regard for time, till the cleansing is as thorough as it can be made. At this stage scrubbing with a sterilised compress may be useful. Haegler finds that by this means the superficial epidermic scales, together with a number of germs harboured in them, are rubbed off. Two points in this method of purification are of importance. In the first place, the brushes, after having been sterilised by boiling, must never lie, or remain lying, in anything except a strong disinfecting fluid (1-1000 corrosive sublimate or 5 per cent carbolic acid). The latter should remain quite clear when the brushes, thoroughly boiled, are placed in it. With the above precautions taken we have never been able to find any necessity for the brushes recommended by Schleich. Should doubts be entertained with regard to brushes Sanger's sand soap may be substituted. Haegler found the brushes more efficient than Schleich's marble soap.

The second point, and one which is essential to success, is the removal of the projecting portion of the nails. The surgeon who keeps his nails long has no prospect of attaining complete cleanliness by mechanical means. If, on the contrary, the nails are cut as short as possible, there is no need for the mischievous nail-cleaning instruments, as a brush with soap and hot water, followed by alcohol, suffices to clean even the dangerous crevice beneath the nails. Then, once and for all, away with these nail-cleaners!

In this method we do not ascribe the chief importance to any disinfecting property peculiar to the alcohol. We intend, rather, by the use of alcohol after soap, to obtain a more radical removal from the skin surface of all the fatty constituents and the organisms harboured by them.

It has been shown by Fett and others that alcohol penetrates the cutis to a much greater depth than can be attained by water. Rielmann has demonstrated by the use of colouring matters that 96 per cent alcohol reaches further into the cutis, even as far as the subcutaneous tissue, and fills the hair follicles, but is only able to penetrate slightly the sweat glands on account of the pressure of the secretion. According to Leedham Green,[1] continued and energetic washing with soap and hot water, or even with marble dust or Schleich's soap, fails to diminish the number of germs. A prolonged system of washing and the use of a soap such as soft soap, rich in alkali, causes great damage to the epidermis and converts it to a sodden condition.[2] There is no antiseptic which can render the hands entirely free of germs. We would especially emphasise the opinion of Schäffer, an opinion supported by Leedham Green, that it is a mere superstition to think that any real benefit is obtained merely by dipping the hands in an antiseptic lotion. Even the use of alcohol for the purpose does not effect hand sterilisation, as, apart from dissolving fats, the disinfecting action of alcohol depends on its property of fixing the superficial layers of the epidermis.

A 70 per cent alcohol supplies the most effective action, as it is stronger than 1 to 1000 perchloride solution, the addition of lysol or biniodide of mercury failing to increase its action, while Mikulicz's spirit of soap is less effective than alcohol.[3] Engels further has shown that with Ahlfeld's method of hot water and alcohol the more deeply situated organisms in the skin retain their viability. Futh, as the result of his experiments, arrived at the same conclusion and recommends the use of rubber gloves as the only certain method of obtaining disinfection. After what we have said it is hardly necessary to observe that the skin of the patient requires cleansing for some distance around the field of operation, in exactly the same way as cleansing is necessary for the operator's hands.

By Klein's method, which is worthy of notice,[4] he first thoroughly scrubs the skin with soft soap, which is then washed off under a stream of warm water, the skin at the same time being scrubbed with fresh brushes, the operator immediately afterwards soaking his hands in ether and alcohol, in order to remove the fats. It will be seen that we have entirely given up the use of any of the more active substances to disinfect the patient's skin and our own hands. This was the result, in the first instance, of our own inability to withstand the action of corrosive sublimate. But as soon as we were convinced that it could be dispensed with without any evil consequences we countermanded its use for assistants, nurses, and patients, and we have not had the slightest reason to regret the step. To be absolutely candid, however, we must admit that we have come across individuals who can neither attain true "abstinence" nor even get as far as thorough mechanical purification. For uncleanly persons the use of strong antiseptics for the hands is an absolute necessity. Under certain conditions the same holds good for the patient's skin. Haegler considers that preliminary treatment with 60 to 70 per cent alcohol allows of a deeper penetration of the corrosive sublimate by the removal of fat.

According to Engel, the best method is that in which 99 per cent alcohol is used in conjunction with lysoform, sublamin (2 per cent according to Krönig and Blumberg) or even Bacillol alcohol. The alcohol dissolves the fats by displacement of the air,

[1] London and Birmingham, 1904.

[2] Paul and Sarwey reject soft soap on account of the injury it causes to the skin. They rightly consider that the wax ingredients of Schleich's "marble soap" are unsuitable. Dr. Saltikoff, at our request, has experimented on threads to determine to what extent waxing of silk, up till lately so common, prevented the access of organisms. The result was that germs were found to be able to pass easily through a layer of wax, while it was proved to materially hinder the action of chemical antiseptics, exactly as Paul and Sarwey had described.

[3] Compare Gotstein's recommendation on this point. According to Haegler soap spirit is not more valuable than alcohol.

[4] *Zeitschr. f. Chirurgie*, Bd. 75.

and enables the disinfectant to come into closer contact with the bacteria. Where, however, skin incisions have to be made in the neighbourhood of sources of infection from virulent organisms, or where the patient has a "quite impossible" skin, with cracks, wrinkles, and scales (we recently excised an elbow-joint in a subject of ichthyosis), one may then endeavour to arrest the action of the alcohol (99 per cent) by the addition of antiseptics; but, in our opinion, much stronger antiseptics than these should be brought into employment. When, as not infrequently happens, acne pustules, or small furuncles, are situated in the area to be operated on, each focus must be most carefully destroyed with the thermocautery.

When fistulæ, granulating surfaces, or necrotic tissues are present in the field of operation they must be mechanically removed by excision or by scraping, followed by disinfection of the surface by the thermocautery. Otherwise a severe infection is very liable to occur. When coarse, wrinkled, scaly skin is involved in the area of operation,[1] a mechanical removal of the organisms is impossible. An antiseptic fomentation of carbolic or formol-glycerine should be applied from one to two days previously, but the prognosis with regard to infection should be very guarded. Absolute security can only be guaranteed by the use of impermeable coverings (rubber gloves).

It is not yet absolutely demonstrated, even by Paul and Sarwey's admirable researches, that the number of germs is at all diminished by such chemical disinfection. We are inclined to accept Haegler's theory that only diminution of virulence is thus obtained. As these authors admit, destruction of all the germs cannot be accomplished even by means of reliable antiseptics;[2] the few that remain would certainly suffice to infect the wound, were it not that their virulence is diminished.

The last point well worth considering in this relationship is the prevention of importation of infective material from skin or mucous membranes situated at a distance from the field of operation. As regards the skin, it is nowadays customary to cover our bodies, with the exception of the face and hands, with a sterile material, and it is just as important to cover up the patient and the operating table with sterile sheets as it is for us to wear a sterilised coat, sleeves, and operating cap.

The transplantation of germs from the mouth and nares, not only of the operator and his assistants, but also of the patient, deserves special notice. We are indebted to Flügge for demonstrating how widely germs from the mouth and nares are disseminated during speech, coughing, or sneezing.

During speech, germs native to the mouth infect nutrient plates at a distance of several metres. According to Mendes de Leon's observations,[3] the number of organisms in the air exhaled during speech amount to about a quarter-of-a-million, consisting chiefly of streptococci, diplococci, staphylococci and sarcinæ. To avoid these germs it is not sufficient merely to rinse out the mouth and wear a gauze mask, as absolute protection can only be obtained by wearing a respirator made of cotton wool. The conditions here are exactly similar to those governing the use of rubber gloves. As every participator in an operation has to thoroughly disinfect the hands, so must he completely disinfect the mouth, nose, and especially the teeth. If the surgeon or his assistants are suffering from a cold or sore throat, or if cleansing of the mouth is not possible, a cotton-wool respirator should invariably be worn over the mouth, similar precautions being adopted by the patient. It is unnecessary to draw attention to the amount of infective material which exists in and around a carious tooth. Such a condition should always receive careful attention. In our numerous operations for goitre a sheet is secured to the front of the patient's neck, and spread over a support which arches over mouth, nose, and face in such a way as not to interfere with respiration, but yet completely to exclude any possibility of contaminating the site of operation. According to Leon's experiments, the addition of a layer of cotton wool

[1] Paul and Sarwey have endeavoured to demonstrate the great difference in the microbes contained in various parts of the skin according to its quality; and Blumberg has shown that even in the most superficial scratch there exist colonies of pathogenic organisms.

[2] Krönig and Blumberg recommend mercuricæthylendiamin in preference to sublimate because it does not irritate the skin or precipitate blood or albumen.

[3] Langenbeck's *Archiv*, Bd. 72.

lends considerably to the security of the mask. The covers for mouth, nose, and beard act for a time as filters, or microbe traps, and retain organisms which are exhaled and shaken out. Like the gloves they must be frequently changed. Thorough and repeated rinsing of mouth and nose, along with sponging of the beard and hair before and during the operation, have always sufficed for us if care be exercised. It is also to be noted that the patients, by thorough mechanical cleaning of the teeth and antiseptic gargling, materially lessen the risk of aspiration pneumonia after narcosis.

(r) The Prevention of Air Infection

Besides contact-infection there are two other modes of infection of wounds which play an important part in the treatment of wounds. The first of these, *air infection*, as it has long been called, was originally considered very important, but has been proved to be less so than contact-infection already described. The second, to which we have given the name *implantation infection*, is at the present time just as important as contact-infection, and even more to be dreaded.

Tavel has distinguished a fourth form of infection, which he calls *lesion infection*, which we shall discuss later on.

That *air infection* is of far less importance than contact-infection is certain; experiments, however, show that it has been somewhat neglected. We agree with Rydygier that air infection is not to be despised, for we observed in our own clinic that operations performed in the clinical lecture theatre for the benefit of a number of students were much more liable to go wrong than those performed in the aseptic operating room.[1] We cannot absolutely exclude air infection, but we can reduce it to such a minimum that it may be disregarded. This is effected by operating in dust-free air. The room in which the operation is to be performed and everything entering it must be absolutely freed from dust. Flügge has shown how difficult it is to detach germs from a damp surface by means of air currents, and also how easily dried microbes are carried away by draughts of air, and how they remain suspended for a long period.

The floor, walls, and especially the seats[2] in the operating theatre must be thoroughly freed from dust, either with hot water or with a steam jet, and special care must be taken to prevent dust being raised in any shape or form during an operation, as the restlessness of the spectators just makes the difference we have referred to above in the progress of wounds. We have been thoroughly convinced of these facts by exposing plates before, during, and after a clinic (Haegler).

The rooms most suitable for operation, and in which we obtain the best results, are those which are devoid of fixtures, such as wash-basins, etc., as Witzel very justly observes. Further, the walls should be smooth and free from recesses so that they can be readily washed down and be free from the accumulation of dust germs.

The reason why air infection is of less importance than contact-infection, as shown by Friedrich's experiments, is that germs which fall on to a wound without any pressure are far less frequently absorbed than are germs which are pressed into the tissues, whether by fingers, instruments, or by covering them over with skin, a proceeding which causes tension proportionate to the depth of the wound. Contact infection is nearly related to that form of infection to which we proposed to give the name of inoculation infection, in which the germs are introduced or rubbed into the deeper layers of the tissues. If such mechanical factors can be excluded, air infection can be easily combated by frequently douching the wound during the operation. The best lotion is hot normal saline solution, which washes germs from a wound just as well as any antiseptic fluid, without the disadvantages possessed by the latter of

[1] Heile has recently brought forward numerous proofs of how dried secretions, pus, etc., get into the air, and stick to the clothes, on which they are conveyed into the operating room.

[2] In many of the high and elegant operation rooms now in vogue this indication cannot be efficiently carried out. Hanging lights are for the same reason objectionable.

lowering the vitality of the tissue elements and by this means favouring infection. It is, however, simpler and more practical to protect the wound by means of moist gauze compresses, which, as we mentioned above, soak up blood and lymph and assist in the removal of the bacteria.

(s) Implantation Infection and the Question of Ligatures

The importance of *implantation infection* is, on the contrary, very great. It consists in the introduction of micro-organisms into a wound along with certain foreign bodies which have to be left in inside. Of these the most important are ligatures and sutures. The question of ligatures cannot be regarded as finally settled, as is evidenced by the great number of discussions on the subject, especially in gynæcological papers. New facts are constantly being accumulated to assist in determining the relative merits of silk and catgut, or of some new substitute, but a long time will in all probability elapse before this point is unanimously settled, for it is difficult to obtain a clear idea as to what disadvantages should or should not be ascribed to each particular ligature on account of the great number of factors involved. But we have for long taken up a very definite position with regard to this question, and experience has confirmed our opinion.

There is no possible doubt that catgut, introduced by Lister, has great advantages over other ligatures owing to its being so readily absorbed when introduced into the human body. But this property of easy absorption is nowadays being prejudicially affected by new methods of preparation regarded as specially reliable and valuable. Minervini has demonstrated this fact by elaborate experiments. In this way the principal advantage of catgut is being done away with. Besides this, catgut, even when sterilised, is liable, as Poppert has shown, to an unpleasant chemiotactic action owing to the inclusion of chemical products which remain active even after sterilisation. Abscesses containing sterile pus may then form,[1] delay healing and introduce secondary dangers, although this form of reaction does not give rise to progressive inflammation or suppuration. Still, Lauenstein and Braun have shown that in a large proportion of these cases the action supposed to be purely chemical turns out finally to be a true infection, with all its natural consequences.

According to Minervini and Jacobs, treatment with juniper oil, as we recommended, is one of the most reliable methods of preparing catgut, but the action must be very prolonged. We have paid great attention to this point, and have preserved all our catgut for months in juniper oil. Jacobs, after sterilising the catgut in juniper oil, impregnates it with iodoform, according to Körte's formula, and is thoroughly satisfied with the result.

It is necessary, however, before using the catgut to wash out the juniper oil by soaking in ether and alcohol, in order to avoid any serious chemical action on the adjacent tissues. For immediate use the catgut is best put into 1-1000 solution of sublimate in alcohol. We employ catgut where a wound is already infected, or where infection cannot be avoided, and especially in suppurating wounds. In all other cases we have remained true to our motto, "Away with catgut, and use silk sutures for all aseptic operations." So entirely satisfied are we with silk, that we have never even given a trial to the numerous other catgut preparations, amongst which are recommended Bergmann's sublimate catgut (especially Schäffer's formula, boiling in alcohol sublimate), the cumol-catgut of Krönig, and the iodised catgut of

[1] Krönig, that worthy investigator in the realm of antisepsis, considers that he is in a position to meet every requirement by bringing forward an uninterrupted series of cases of healing by first intention where catgut was used. But he takes twenty days as the limit of primary union—far too long a period, and Zweifel says that the stitch-holes often contain pus on the seventh day. Krönig himself admits, from statistics collected by Abel, that in fifty-six laparotomies stitched with cumol-catgut, 10 per cent suppurated, 7 per cent without any other cause. This is not to be wondered at when we consider that catgut is nothing more or less than a dead organic nutrient substance. A serous secretion, free from bacteria, by no means implies, as Haegler and Gottstein showed, that the ligature causing it is not infected.

Claudius.[1] Neither have we given a trial to metal threads such as Socin's bronze aluminium, or to the tendon preparations of Snegiroff and Marey. While catgut prepared by Hofmeister's method (boiling in formalin) is very reliable, its absorbability is impaired, and Braun's celluloid thread, though worthy of notice, is less easy to prepare than sublimate silk. The same holds true for Schäffer's gutta-percha threads, and for Pagenstecher's celluloid threads, to which Keen gives high recommendation.

W. Bartlett places the catgut, after it has been dried at 105° for twelve hours, in fluid paraffin till it becomes transparent, when it is gradually heated up to 160° C. for two hours, after which it is kept for twenty-four hours in a 1 per cent solution of iodine in methylalcohol. Webster prepares his catgut by soaking it for eight days in tincture of cloves, and eight hours in 95 per cent alcohol, when it is then stored dry.

To demonstrate what absolute success can be obtained with silk we cannot do better than refer to the results of our goitre operations. In these operations, as a rule, large numbers of ligatures are applied, and yet in a series of hundreds of cases not a single case of infection occurred.

We cannot accept the statement that a properly-prepared silk ligature or stitch may cause either early or late inflammation, and we repeat that it is only antiseptically-prepared silk, in conjunction with prevention of accumulation of blood and retention of wound secretion, which safeguards us against both primary and secondary infection.

Haegler pointed out that in all cases where the ligatures were merely aseptic, even though the course of the wound be favourable or only a little serum gathers (which may be sterile), the tissues along the track caused by the suture itself contain embedded in its substance countless organisms. Every porous substance readily absorbs wandering germs and holds them fast, just as gloves do. Care, therefore, must be taken that the germs which have penetrated into the wound shall be unable to develop in the ligatures and sutures before an accumulation of blood or serum is no longer possible, and the normal circulation is re-established by perfect union, which renders the bacteria harmless or carries them away. Impregnation of silk with antiseptics is easily managed, and according to Haegler's experiments the threads keep the antiseptic, specially mercuric salts, for long periods. Indeed, it is only gradually washed out into the body fluids.[2] For this reason we attach great importance to the exclusive use of thin silk, because it is more easily impregnated and is still more closely enveloped by the healthy tissues. No trouble is experienced even when 50-100 fine silk ligatures are used, while coarse ligatures may give rise to suppuration.

The necessity for antiseptic ligatures is emphasised by the fact that each thread is tied with a certain amount of force round a bleeding vessel or round other tissues, and therefore causes a certain degree of tissue-necrosis. As may be demonstrated, necrosed tissues play the part of foreign bodies, and, moreover, foreign bodies capable of absorption; and the antiseptic in the ligature is therefore called upon to prevent the development of the organisms which may have penetrated into the necrotic tissue of the stump. From this point of view it may even be desirable that the thread should not be too rapidly absorbed. The early loss of mechanical support is therefore a grave objection to the use of catgut. If the ligatures are once rendered efficiently antiseptic, then, according to Haegler, it is of little importance whether they be tied with hands carefully cleaned or not. Nevertheless, as we should avoid infringement of any rule, we consider it advisable, at least, to attempt to prevent contact of the ligatures with the skin by putting on a pair of sterilised thread or rubber gloves, or to prevent the ligature passing from hand to hand by using small glass holders

[1] Stone (*New York Med. Record*, Nov. 1904) advises first putting the raw material in 4 per cent aqueous solution of formalin for twenty-four hours, washing for twelve hours and then treating with the solution of iodine in potassium iodide.

[2] This is the reason why the best of observers (compare the careful experiments of Krönig and Blumberg) constantly overrate chemical disinfection. The antiseptics cannot be completely washed out of a thread.

(Halsted and Lanz) which can be held in the hand. Our method of preparing silk, the absolute reliability of which we can vouch for, is as follows.[1]

The skeins of fine silk (Nos. 1 and 2) are treated as follows:—

1. Placed in ether for twelve hours.
2. Placed in alcohol for twelve hours.
3. Boiled for five minutes in a 1 per thousand colourless neutral solution of corrosive sublimate.
4. Wound round spools with hands covered with rubber or thread gloves.
5. The spools are again boiled in the same sublimate solution for ten minutes just before the operation.
6. The ligatures are then handed out of the sublimate solution in which they were last boiled. They have therefore always remained in the same glass.

(t) The Significance of Necrotic Tissue in regard to Infection. Prevention of Necrosis

Even though a fresh wound has been treated according to the principles enunciated, we must not conclude that we have necessarily obtained a condition of absolute sterility. It has been proved by endless recent researches that even where operations are conducted with the greatest care and with every attention to asepsis organisms are almost invariably found in the wound both during and after operation, while a great number of organisms are found in the drainage tubes which have been used for a day or two to draw off blood and serous exudate. In our clinic Flach and Lanz have for a whole year conducted exhaustive experiments on this subject, as has also Tavel, and more recently Brunner (*vide* his work on wound infective diseases). It must, however, be taken into account that when the wounds were examined by these investigators, the present precautions, such as the use of sterile rubber gloves, or cotton-wool respirators, etc., had not yet been introduced. Otherwise more favourable conditions would probably have been ascertained.

The undeniable fact that we are not yet able to secure absolute sterility, even in a wound which we inflict under the most favourable circumstances, renders it our duty to pay greater attention to certain technical factors other than the sterilisation and disinfection of dressings, and skin, and hands. This leads us to a consideration of what Tavel has called "*lesion infection.*" It is a remarkable fact that even though our skin and mucous membranes are covered with enormous numbers of micro-organisms we do not in any way suffer. It requires an injury to the tissues before the bacteria can acquire power over the cells and produce a disturbance in the normal balance of the tissues. Tavel and his pupils have collected a great number of facts demonstrating the importance of this factor.

Any lesion, however small, of the epithelial covering of the skin or of a mucous membrane, be it a purely mechanical rupture of continuity, an injury due to chemical causes, to drying up, or to derangement of circulation, such as accompanies catarrh, may allow of the entrance and development of such micro-organisms as may have been in the neighbourhood. Walthard has proved this by a series of admirable experiments in the case of the peritoneum, and Haegler has shown that wherever the outer skin is wounded, however insignificantly, a portal is opened whereby the entrance of germs is rendered possible. Now in all operations a wound is obviously present. Without a wound there would be no injection, and therefore the term "lesion infection" seems to us too general and not explicit enough for what Tavel means to suggest.

The important factor which induces a predisposition to infection in the lesion is

[1] We have not employed silk impregnated with the powerful antiseptics recommended by Haegler, Merlin, and Stinson (Merlin, for example, recommended a 1 per cent ethereal solution of corrosive sublimate for silk or catgut, while Haegler boils for one or two minutes in a 5 per cent sublimate solution) because they are unnecessary, and because such strong sublimate impregnation produces a too energetic local chemical action; and if many ligatures were applied, poisoning is to be anticipated.

the death of larger or smaller portions of the tissue. We can, in carrying out an operation, very largely determine the amount of damage to the vitality of the tissues. Bumon, amongst others, has on this account recently pointed out that the technique of an operation has a much greater influence on the subsequent course of a wound than was ascribed to it during the period of enthusiasm which followed the introduction of the antiseptic method of treating wounds.

It is the technique which decides whether the germs which fall on every wound, especially on necrotic tissue, shall develop to a dangerous extent or not. As we have mentioned, we do not consider a wound infected until pathogenic organisms have developed in it. Until such a development has occurred a wound is only what Friedrich would call "under suspicion of infection," and can still heal if the bacteria are destroyed.

Recent researches, of which those of Schimmelbusch, corroborated by Ricker and Noetzel, have aroused most attention, have shown that if, for example, a wound in a mouse's tail be inoculated with anthrax, absorption of organisms and dissemination to distant organs takes place from the wound in an extraordinarily short space of time, even in a few minutes. Were the bacteriological conditions the same in every case, we should have to admit in every operation the presence, not only of wound infection from organisms gaining access to the wound itself, but also of a general infection of the whole organism. But the admission and absorption of bacteria do not constitute infection in the clinical sense. It is only when the organisms develop and produce harmful toxins in the body that inflammation and general symptoms appear. In the case of a wound in which, in spite of the presence of bacteria, complete union has taken place in a few days without inflammation and with the patient in perfect health, it is impossible clinically to speak of general infection. We therefore agree with Friedrich in asserting that it is wrong to consider such experiments as parallel to the process of repair in operation wounds.

On the other hand, we regard it as a matter of capital importance that, in speaking of the infection of a wound, one should distinguish not only between organisms which are pathogenic to man and those which are not pathogenic, but also between those which are virulent and those which, for the time being, are not virulent. These organisms which are neither pathogenic nor virulent get into the blood by purely physical processes of absorption. But this rapidity of absorption, far from acting prejudicially, exercises, on the contrary, an entirely favourable influence on repair. Micro-organisms which are not adapted to a particular soil are neither pathogenic nor virulent, and are destroyed in the blood and healthy tissues. This also holds good for pathogenic or virulent organisms so long as they gain access to the living blood or healthy tissues separately or in small numbers. But it is another matter when virulent organisms reach a stage of luxurious growth in a wound, due to the presence of suitable nutrient media (blood and lymph), and especially foreign bodies (ligatures) or necrotic tissue.

Friedrich has shown, by a series of admirable experiments, that if an animal be inoculated with a pathogenic organism in just such a manner as would occur if accidental inoculation occurred (*e.g.* malignant œdema in guinea-pigs), six to eight hours must elapse before the infective material which is developing disseminates itself through the tissues, and becomes injurious and dangerous on account of its toxin. This has a very important bearing on the treatment of wounds, and its importance is emphasised by the fact, proved by the same author, that if the inoculation be performed with organisms which have already passed through the animal, the incubation period is much shorter, and for this reason the clinical symptoms of infection appear much more rapidly. The germs are rendered much more virulent by passage through a similar soil.

Further, Friedrich has shown that pathogenic and virulent micro-organisms require a certain time for division, as Koch also found, and consequently serious infection cannot occur until this time has elapsed. This time is dependent on the presence of decayed tissue (ligatures, extravasation, necrosis).

We must see that micro-organisms should be offered no chance of developing in

the wounds until the defensive apparatus of the normal body is again set in working order by the re-establishment of the normal circulation. To prevent development we must not only prevent the access of "pathogenic" germs in the manner above indicated, but we must remove as many of the "saprophytic germs" as possible. Besides porous foreign bodies—especially ligatures—there are many other soils which serve as nutrient media for the growth of micro-organisms: they include especially, necrotic tissues in the form of portions of the surface of the wound itself (*e.g.* ligature pedicles), and fluid, chiefly blood, exudates into the wounds. Dorst, under Tavel's supervision, has shown how much easier it is to produce an infection of an artificial hæmatoma than of healthy tissues, and Linser, likewise under Tavel, has experimentally demonstrated the comparative harmlessness of an injection even of pathogenic organisms into healthy tissue, as compared with injection into tissues which have been artificially injured or whose circulation has been artificially obstructed. Even 1 c.cm. of a culture of staphylococcus aureus which is absorbed in healthy tissues, will rapidly cause an abscess with all its sequelæ if the circulation has been first of all impeded by strangulation of the tissues. A bactericidal property has been attributed to the secretions of the wound; but Brunner has already pointed out that though such may exist it is far outweighed by the nutritive value of the secretion for bacteria. Practical experience leads us very decidedly to question the defensive value of the secretions from the wound where inoculation has actually occurred.

To prevent "lesion infection" (Tavel) or, as we prefer to call it, "necrosis infection," everything must be avoided during an operation which causes severe damage to the tissues, *e.g.* splitting, crushing, and tearing. Incised wounds are most innocent in this respect, a fact long recognised and proved by Tavel, whereas crushing, even to a slight extent, is followed by a more or less extensive necrosis of the surface of the wound. For this reason an experienced operator has more prospect of obtaining uninterrupted repair in his wounds than a novice, though both operate under precisely similar conditions as to sterilisation and disinfection.

Besides refraining from unnecessary splitting, crushing, and tearing of the tissues, the avoidance of chemical or thermal injury is just as important for the prevention of necrosis. According to Walthard's experiments drying is more deleterious for certain tissues than anything else. This can be avoided by repeated irrigation with warm normal saline solution. The method of "dry operating," much advocated in earlier days, is thus contraindicated, although even by it the unfavourable effects can be minimised by covering up the tissues and so preventing cooling or evaporation. In certain operations, such as those on the abdomen, the covering of the contents with warm compresses or copious irrigation with salt solution at the proper temperature is of supreme importance, not only on account of the danger of infection, but also as a preventative against the shock which accompanies every severe operation, and in the splanchnic region often followed by circulatory trouble. This method was probably first introduced at the clinic at Berne.

No less important than the prevention of thermal injuries is the prevention of chemical injury. This indication is very frequently neglected. There are a certain number of surgeons who refuse to discontinue the practice of douching and washing out wounds with antiseptic solutions, in spite of the fact that it has been demonstrated that death of the micro-organisms on a wound surface cannot be brought about without severe injury to the tissues. The proof of this is due to Kontschewsky. He has demonstrated delay in karyokinesis and in repair, as Goldberg and others have also done. Antiseptic washing and douching can, therefore, only be occasionally justifiable when the chemical injury caused by it is more than counterbalanced by the infective material destroyed. This occurs in wounds which are already badly infected. In recent wounds, however, douching with antiseptics should be entirely given up and an indifferent osmotic fluid, such as normal saline solution at the body temperature, should be used instead. We never employ any other form of irrigation than this, which we use freely. It was not until we gave up antiseptics that we arrived at the knowledge of what perfect repair in wounds really meant. Koller, under Tavel's

direction, has shown that, in rabbits, wounds caused by infected shot give the best results when they are cleansed with an indifferent solution, whereas the use of the best kinds of strong antiseptics did not save the animal from progressive inflammation with fatal results.

If one cannot avoid leaving stumps of tissue behind which necrose from being ligatured or from other causes, one must bear in mind that such stumps and necrotic tissues produce exudation of leucocytes and fibrin without bacteria (according to Burkhard [1]) and to a greater extent in the presence of bacteria, which find in the exudations conditions necessary for their development. Necrotic tissues must therefore be protected antiseptically by saturating them with anti-bacterial substances, such as alcohol, iodine, iodoform, or bismuth. Bröse has shown that when chloride of zinc has been applied to a wound, the resulting eschars (50 per cent zinc chloride) afford absolute protection against the development of pathogenic organisms. Alcohol and bismuth possess a similar anti-bacterial though not bactericidal action.

A third factor in the building up of a technique to avoid necrosis consists in preventing the accumulation of fluids, more especially of blood, in the wound. This is best attained by arresting all hæmorrhage, by applying artery forceps to every bleeding point, and by closing the vessels at the end of the operation, avoiding the use of ligatures and substituting torsion wherever possible. Torsion is quite sufficient for small vessels, and deserves to be widely employed. Next to torsion, crushing by means of small angiotribes (strong artery forceps) has recently come into prominence as a very useful method of closing vessels without ligatures. But angiotribes are still more valuable, because they allow us to squeeze and compress large pedicles of tissue to such an extent that when a ligature is applied the resulting stump is reduced to a minimum and is quite dry. We introduced pressure forceps—histiothriptors they were called—for this purpose in dividing the isthmus of the thyroid long before Doyen brought out his well-known instrument. Crushing of tissues is now one of the best means we possess of dealing with masses of tissue which are liable to decompose in a wound, and it plays an important part in the removal of all organs which have a pedicle requiring to be tied.

A further means of preventing the accumulation of dead material in the wound is by the avoidance of cavities and by the complete approximation of the surfaces of the wound. Complete closure of a large irregular wound is, however, not always possible, especially when deep sutures endanger important structures. There is then no choice but to prevent the accumulation of fluid in the cavities by drainage. The drainage tube should be introduced at the point where the outflow of blood and serum is likely to be greatest.

Such drainage meets the requirements demanded by Friedrich, viz. that fluid containing bacteria should not be allowed to accumulate under injurious tension. The drainage tube creates a flow of fluid from the wound which carries with it the micro-organisms. To Starcke belongs the credit of having, before Friedrich, drawn attention to the importance of the flow of serum in preventing the ingress of germs.

For drainage we have long advised the exclusive use of glass tubes provided with large lateral openings. They are easily kept absolutely sterile, and they keep the wound open. In wounds which are to be completely closed it is desirable to introduce a gauze swab before suturing, and before the last suture is applied to withdraw it, pressure being at the same time applied over the wound. The surfaces of the wound are thus brought into exact contact.

Lastly, it must not be forgotten that the circulation in the edges of the wound is to be interfered with as little as possible by avoiding tension or injurious pressure, and by facilitating the venous return from the wound by a suitable position. Maintenance of nerve influence would not appear to be a matter of indifference, if only on account of its influence on the circulation; for in cocainisation of the cord, as recommended by Bier, a marked tendency to unfavourable symptoms in the wound has been noticed.

[1] Langenbeck's *Archiv*, Bd. 74.

(u) The Treatment of Infected Wounds

The treatment of primary operation wounds must be considered as entirely different from the treatment of such wounds as are already infected with pathogenic and virulent infective material. Under this heading are included all those accidental wounds which have been infected directly with virulent organisms, or which are not brought for advice when recent, and which have not been protected from further infection by spontaneous adhesion. It is customary to designate such wounds merely as "infected wounds," as opposed to operation wounds which are merely "under suspicion of infection."

When we say the treatment is to be entirely different from the treatment of aseptic wounds we feel that it is necessary at once to prevent a misunderstanding and to eradicate the idea that it is a matter of no importance whether or not such an infected wound be treated with sterile dressings, lotions, and properly-cleansed hands. Neglect of these rules is often the means of converting a single infection into a mixed infection. Moreover, even with septic wounds the absolute rule to exercise the greatest care and most rigid asepsis in regard to the cleansing of the skin and hands and the sterilisation of instruments and dressings should never be broken.

Opinion is still divided as to the proper treatment for infected wounds, especially in regard to the question as to whether antiseptics should be used or are best left alone. In the light of Schimmelbusch's experiments, which showed that germs which have gained access to a wound penetrate into neighbouring tissues in a few minutes and enter the circulation, no great benefit can be expected from antiseptic treatment; and since, according to the unanimous opinion of clinicians, rapid growth of germs and their accompanying dissemination in healthy tissues occur chiefly in the case of pathogenic organisms, that is, virulent micro-organisms, antiseptic treatment would appear to be of least benefit in just the worse cases, since it is, as a rule, applied too late.

The method of treating accidentally-infected wounds (as recommended by Volkmann in the treatment of compound fractures) by douching with strong antiseptic solutions is still customary.

The majority of doctors consider it their duty to wash out accidental wounds with a 1-1000 sublimate solution, this being regarded as the most rapidly-acting antiseptic, and Henle's experiments seem to favour such antiseptic methods from the point of view of experience. The careful researches of Friedrich, and especially of Tavel and his pupils, lead to very different conclusions.

The late Dr. Koller, working under Tavel's direction, proved that in shot wounds in rabbits inoculated with certain organisms, antiseptic treatment not only served no useful purpose, but caused actual injury, the same result occurring whether the wounds were irrigated with sublimate or carbolic lotion, or treated with iodine or the thermo-cautery. The majority of animals subjected to this treatment succumbed, whereas a large number of animals treated on merely aseptic principles recovered. Friedrich obtained like results when using special material for infecting the wounds. Contamination of a wound is favoured by all such measures as tend to lower the vitality of the tissues, and therefore by all unnecessary mechanical, chemical, or thermal injury. How very differently crushed wounds and incised wounds behave when infected is a matter of common observation. Linser, also at Tavel's instigation, showed how distinctly this difference of susceptibility to definite infective material can be demonstrated, as he found that incised wounds healed although contaminated with a large dose of virulent organisms, whereas crushed and lacerated wounds invariably developed the usual sequelæ of infection. A similar difference may be demonstrated between wounds whose surfaces are cauterised with chemical substances and similar wounds left untreated. The danger consequent upon admitting organisms after allowing a wound to dry has been demonstrated by Walthard in the case of the peritoneum. The condition common to the surface of the wound in all these injuries consists in the loss of vitality and necrosis of the superficial tissue elements, frequently only to a microscopic but occasionally to a macroscopic degree. All powerfully-

active antiseptic measures increase the necrotic change in the tissues. For this reason, as a general rule, whether in infected wounds or in wounds only suspected of being infected, the principle must be observed that injury to the surface of a wound by means of chemical agents must be avoided, and when, owing to the presence of foreign bodies and germs, the wound requires to be cleaned this must be effected with an indifferent lotion, such as we possess in the most suitable form in normal saline solution. This is the best treatment for wounds which are accessible to it. But the condition met with in punctured wounds offers another point for consideration in the treatment of infected wounds. We refer to the prevention of all tension and pressure within the tissue, the importance of which has been emphasised by Friedrich. Free opening-up of the part as a precaution against tension must therefore be added to douching with a chemically and thermally indifferent solution (normal saline), because if infection sets up inflammation the resulting tension is much greater than that caused by effused blood and exudate.

No measure for relief of tension is so efficient as the open treatment of the wounds, a method which was introduced and most successfully employed by Kern, and especially by Burow before the days of antiseptics.

Friedrich, as the result of his researches, has arrived at the conclusion that there is only one method of treating spreading infection, namely, by open treatment of the wound; and he points out that the difference of opinion as to the advantageous action of antiseptics is due to the fact that antiseptics were employed at one time in conjunction with, and at another time without, open treatment of the wound. The open method of treating a wound possesses the advantage that besides preventing tension on the surface of the wound and in the tissues, it induces a flow of the exudation from the deeper parts towards the surface. This results in a mechanical extrusion of germs, and owing to the bactericidal properties of the exuded serum, a retarding influence is exercised on their development. Infected wounds must, therefore, be freely laid open by a suitable incision (avoiding all unnecessary tearing and bruising) in order to prevent tension and to admit of aseptic douching. The salutary effects of this treatment, especially in the early stage of extravasation of urine, are very remarkable, as the temperature, which may have been as high as 42° C., falls to 36° immediately after incision.

Although even in infected wounds there is good reason for avoiding any further injury to the tissues, yet the fact must not be overlooked that a number of wounds are already so far under the influence of bacteria that these have already caused extensive necrosis by their toxic action. Only one course is here possible, namely, to remove as quickly as possible the necrosed tissues. This can easily be done as regards necrotic tissue, which is merely loosely adherent on the surface of wounds. Necrosed blood, leucocytes, and fibrin can easily be washed away by douching or sponging. Adherent sloughs and infected tissues require a different treatment.

Friedrich, in his experiments on wound infection with malignant œdema, succeeded in demonstrating that infection and death can be definitely prevented by careful and fairly free incision of the whole surface of the wound within an hour of infection and before development of the bacilli has begun. In the same way, excision of a wound is indicated where it is certain that changes are confined to the superficial layers only. That such is the case may often be recognised by changes in colour and consistency. Obviously-necrosed tissue may be removed with a knife and scissors. Where the changes in the tissues have led to induration and inflammatory thickening the sharp spoon may be advantageously employed for the removal of the necrosed granulation tissues.

But cases are frequently met with in practice in which the symptoms of deeper and more extensive infection have already supervened to an extent which absolutely precludes the possibility of complete excision of all the necrosed, or even of the infected tissues. In cases where this treatment cannot be carried out, even by amputation, we must be content to endeavour to prevent further spread of the disease from the necrosed areas by means which will hinder its development, but which will not further injure the subjacent tissues, and so cause more extensive necrosis. For this

purpose the various dry methods are most suitable when the relations of the wound are not such that the same end may be attained by continued douching and poulticing. If the latter methods are applicable, they should be carried out with antiseptic solutions just strong enough to exercise a retarding influence on organismal development (salicylboric solution, chloride of zinc, lysol 0·2 per cent, etc.). Starcke also recommends these weak lotions. The most satisfactory means of drying up the necrosed tissues are, on the one hand, swabbing with alcohol, which causes shrinkage of the tissues, and, on the other hand, the application of powders, the most important of which are iodoform and bismuth subnitrate, which entail no injurious effects on the deeper tissues.[1] A. Fränkel has recently made a praiseworthy attempt to show that the effect does not greatly depend on the nature of the powder, and that in many cases iodoform might be replaced by wood charcoal.

This method of freely laying open the diseased tissues, in order to limit putrefaction occurring in the necrosing parts of the wound, cannot be carried out in all infected wounds with necrosis of the tissues. Many deep wounds do not admit of being opened up in the sense understood by the open treatment of wounds. In such cases we must confine ourselves to open up the wound freely enough to admit of agents capable of preventing the development of germs being brought into contact with the most inaccessible parts of the wound. The most efficient means to this end may be grouped under the term "antiseptic tamponage." This method is specially designed to prevent the development of germs in the deeper parts of the wound, and it serves at the same time partly as a drain. When the skin, fasciæ, etc., have been sufficiently opened up and the wound has been washed with an indifferent lotion, the whole cavity is stuffed with iodoform gauze, or with a suitable substitute, which must be renewed as soon as the secretion raises it from the surface of the wound. Such tamponage is also employed in newly-made wounds when they are very liable to infection, and, as a rule, whenever an operation has been performed without preparation, or in the region of old foci of inflammation, or in the neighbourhood of the passages of the body which may be injured (as in the vicinity of the throat or intestine). In such cases recourse should be had to secondary sutures, which are highly recommended for doubtful cases, and the introduction of which was considered by Starcke to be epoch-making. The wound remains open, protected by aseptic dressings or tampons soaked in a weak antiseptic, and a few days later the sutures are tied and a large drainage tube is employed till the secretion from the wound has dried up.

[1] Considerable value should be attached to the application of diluted alcohol, recently revived and brought into favour again by Salzwedel. According to Epstein, 50 per cent alcohol is most efficient and increases the efficiency of other antiseptics, such as sublimate. Salzwedel, Elsner, as well as Minervini and Tschirikow, confirm the efficacy of 55 per cent alcohol, and they have shown that 7 per cent alcohol is capable of *preventing* the development of staphylococci. That touching with pure carbolic acid, as recommended by Bruns and Honsell, may be of use under certain circumstances, *e.g.* where sloughs are already present, is undoubted.

SECTION II

SURGERY OF THE VASCULAR SYSTEM

A. SURGERY OF THE HEART AND PERICARDIUM

The heart, ever active and difficult to deal with, has at last yielded to surgical treatment. Several important works have now appeared on "The Surgery of the Heart," the most important being those of Brentano, Terrier and Reymond (translated and enlarged by Lardy and Beck) and of Braun. Previously Paré had recognised that every wound of the heart is not necessarily fatal, and Morgagni had shown that one of the chief causes of death was due to compression of the heart by the accumulation of blood in the pericardium. In 1888 Fischer gave a careful review of 452 cases of injury to the heart and pericardium, and showed that in a certain number of cases recovery had resulted. Rose has pointed out that to save life it is necessary to prevent the heart's action becoming oppressed by the extravasated blood.

The majority of persons who receive a cardiac injury, even a perforating wound of the heart wall, do not die directly from the injury (as in Kronecker's case of stab of the heart), but from the subsequent loss of blood combined with the emptying of the heart, the result of pressure of the extravasated blood on the large veins (Cohnheim). It has been proved by the statistics and experiments of Del Vecchio, Bode, Elsberg, Salomoni, Bloch, and Filipoff, that a perforating wound will cicatrise firmly if the results of bleeding are avoided. A fibrous scar is formed, which may, however, later on lead to the formation of an aneurism and rupture.

If a person who has sustained an injury in the region of the heart is found to be suffering from great dyspnœa with cyanosis, or from collapse and anæmia, and with corresponding variation in the pulse, and if on examination hæmorrhage into the pericardium, with or without simultaneous hæmothorax, is discovered, immediate exposure of the heart is clearly indicated, first, with the object of opening the pericardium and emptying out the extravasated blood which is compressing the heart, and, second, of suturing the wound in the heart.

1. Exposure and Suture of the Heart. When, from the position of the wound and the symptoms of collapse and dyspnœa described above, there is presumption of an injury to the heart, it is the duty of every surgeon to be prepared to promptly open the pericardium and lay bare the heart with the least possible damage to the neighbouring structures.

That this can be attained in various ways is shown by Terrier and Reymond, who found in 1900, that in eleven cases of heart injury, ten different operative methods were put into practice. The position of the injury as regards the heart naturally modifies the method employed, *i.e.* whether it is to the right or left of the sternum, above in the region of the auricles or below in that of the ventricles. But in such an operation as exposure of the heart, which demands rapidity of execution under

exciting conditions, it is urgently necessary that the surgeon be familiar with one method of procedure which can be adopted in any case with which he is called on to deal.

The surgeon must first of all be able to open the pericardium without increasing the danger from further severe hæmorrhage, or without the necessity of a severe preliminary operation, and especially without injuring the pleura. It generally happens that in injuries of the heart, the pleura is damaged as well, but we are not justified in causing still further injury and possibly producing a fatal collapse from the production of a sudden pneumothorax.

Although only a small area of the pericardium is uncovered by the pleura, incisions must be strictly maintained within these limits,* the uncovered area corresponding to the junction of the sixth costal cartilage with the sternum (*vide* Fig. 27). According to Terrier and Reymond, the interpleural space varies considerably in size and position, but in the majority of cases one can only expect to succeed in avoiding injury to the pleura, and still more to be able to expose and retract the pleural reflexion by keeping within this limit.

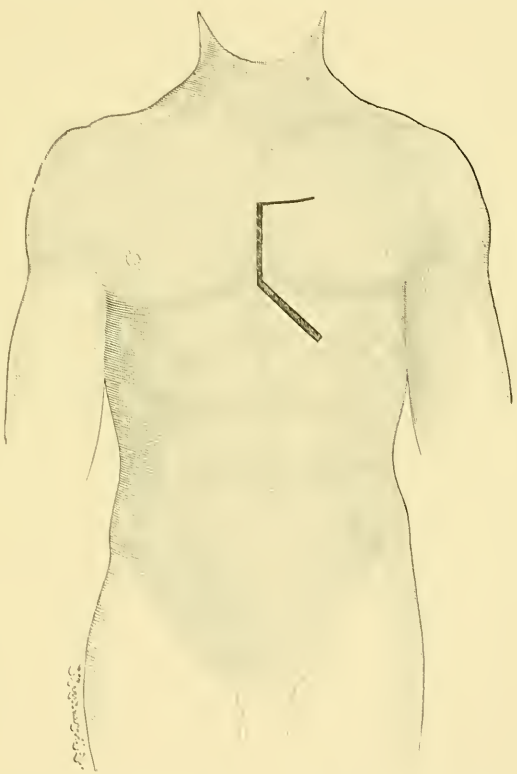

Fig. 24.—Incision for exposure of the heart. The primary incision along the sixth rib is indicated by a broad line, while the transverse cut along the third (or second rib) is represented by a finer line.

Secondly, after having rapidly exposed the pericardium, where it is in contact with the chest wall, the surgeon must know how to release it sufficiently from the overlying pleura so that it may be freely incised and the heart fully exposed. This necessitates turning back a portion of the chest wall ("volet" of the French), and this can only be done quickly and with safety when the pleura has been pushed aside at the site of incision.

If attention is paid to these preliminaries there is no risk of injuring the surrounding structures. We are glad to observe that Terrier and Reymond in their comprehensive work on cardiac surgery recommend the same procedure as we advised in 1902 (*vide* the 4th edition of this work).

The incision resembles that introduced by Delorme for exposure of the lung, and adopted by Podrez for exposure of the heart. The method of dividing the chest wall is that of Guidone and Fontan, while the treatment of the pleura is the method described by Lannay. Terrier and Reymond give an admirable detailed description of the operation.

Operative Procedure. The skin is quickly but thoroughly disinfected with soap and warm water, ether and alcohol (avoiding antiseptics), sterilised gloves being worn. An incision, 10 cm. (4 inches) long, is made from the middle line of the sternum along the sixth costal cartilage as far out as its junction with the rib, dividing the costal attachment of the rectus abdominis. The fibres of the pectoralis major and of

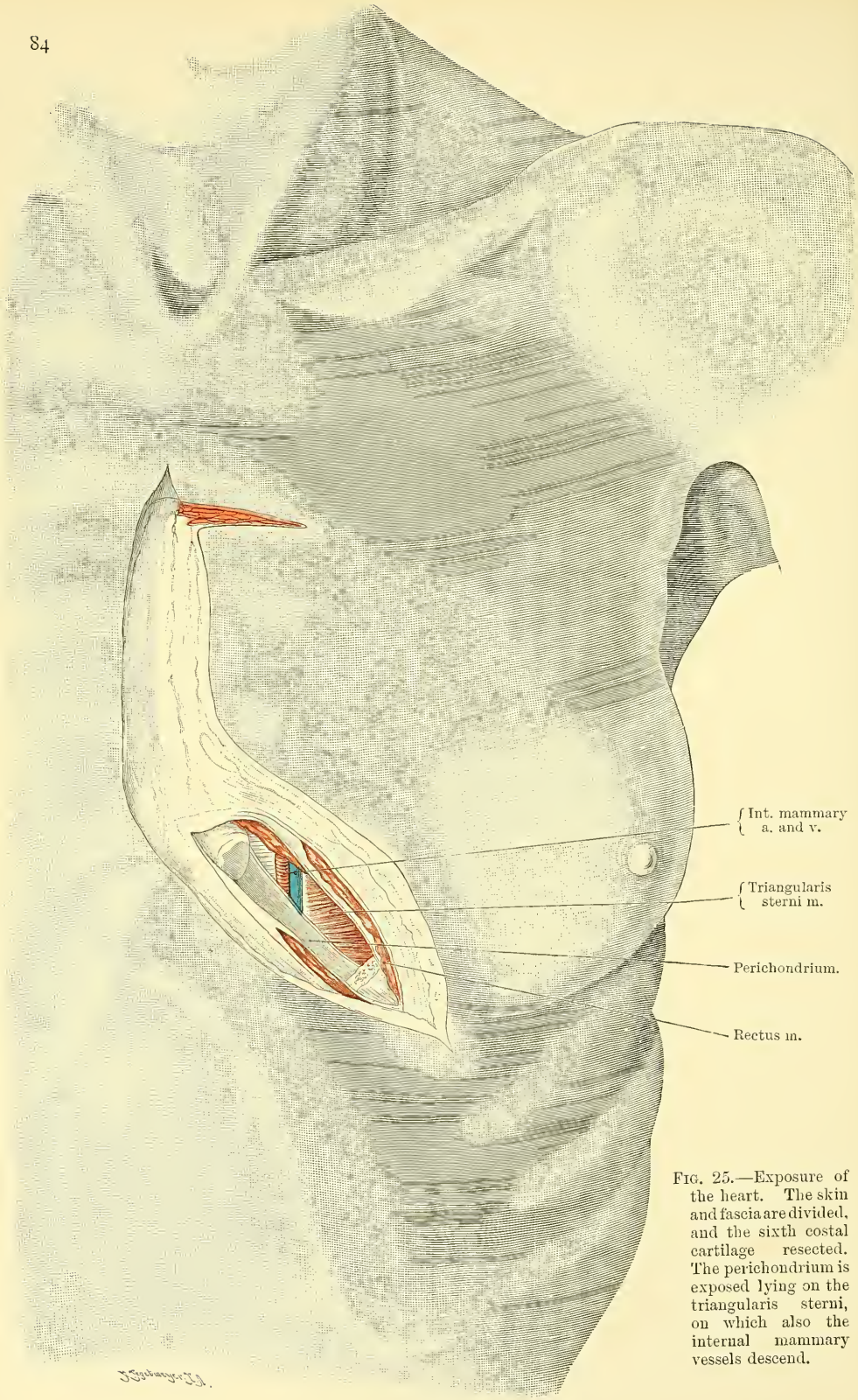

FIG. 25.—Exposure of the heart. The skin and fascia are divided, and the sixth costal cartilage resected. The perichondrium is exposed lying on the triangularis sterni, on which also the internal mammary vessels descend.

the rectus are separated from the upper and lower borders of the rib, while the intercostal muscles are also detached above and below with the knife. After the posterior surface of the perichondrium has been freed with a raspatory, the sixth costal cartilage is then divided close to the sternum, and when raised up with a hook, the connecting bridge between it and the seventh costal cartilage is cut through.

The internal mammary artery and vein are exposed descending vertically a finger's breadth from the edge of the sternum, and are divided between two ligatures. Behind them the musculo-tendinous triangularis sterni is seen spread out like a fan, and is divided close to the sternum.

The triangularis sterni which (as was first pointed out by Delorme and Mignon) is adherent to the pleura is retracted outwards. The pleural reflection can often be recognised by the presence of a layer of fat, and can be easily separated from the pericardium so that the anterior surface of the latter can be exposed down to its attachment to the diaphragm. The tough, glistening pericardium can then be safely opened, if urgent relief is required, *i.e.* if the heart is seriously compressed by effused blood.

If there is no great urgency the procedure is as follows:—According to the situation of the wound in the heart, the incision is prolonged upwards in the middle line of the sternum to the fourth, third, or, if the wound is situated higher up, to the level of the second costal cartilage. At the upper end of this wound, an incision, 8 cm. long (3 inches) is carried transversely outwards through the pectoralis major down to the cartilage and bone of the corresponding rib (usually the third), from the upper border of which the muscular and tendinous fibres of the intercostal muscles are detached.

The pleura, along with the triangularis sterni, is then carefully separated from the deep surface of the fifth costal cartilage and pushed aside, while the rib is divided with bone forceps close to the sternum, a finger being pushed behind the forceps. The costal cartilages of the fourth and third ribs are dealt with in exactly the same manner.

The costal cartilages are now raised, and after the triangularis sterni and pleura have been further retracted, are broken across at their junctions with the ribs, while if necessary the ribs themselves are broken further out. A flap of the thoracic wall is thus turned outwards and the pericardium exposed from the auricles above to the apex below. It may now be freely incised if this be found necessary.

Terrier and Reymond assert that by throwing back a flap in this way one can readily detect and clamp any tear in the pleura.

When the injury is situated in the region of the heart, the operation is naturally commenced over the seat of injury so that it may thus be limited in extent. For example, in Grekow's case (a wound of the left ventricle through the second intercostal space), the heart was sutured after removal of the third and fourth costal cartilages. In such a case as this the incision described may be begun above, although it introduces a risk of injuring the pleura. The second rib must also be divided, if an examination of the great vessels has to be undertaken.

If better access is required to the right heart, especially to the region of the right auricle, the soft parts (muscle, fascia, and pleura) of the other side are separated from the posterior surface of the sternum, the latter being then divided transversely above and below with cutting forceps, and turned back as a flap by bending the costal cartilages of the other side. When this flap is fully bent backwards the cartilages break, according to Terrier and Reymond, at the junction with the rib, and not at the junction with the sternum.

Exposure of the heart from the front by resection of the sternum (the method adopted by Podrez, Wehr, Rydygier and Pagenstecher) is in our opinion too mutilating an operation in the majority of cases, and should be reserved for cases of injury of the right heart. For wounds in this situation Rotter recommends the formation of a flap, which is turned back like a folding door on a median hinge, when the right auricle, right ventricle, great veins, and arch of the aorta are thoroughly exposed. Access can only be obtained to these structures by turning back the sternum to the right, and we consider that the method of Ninni, Rydygier and Rotter, in which the

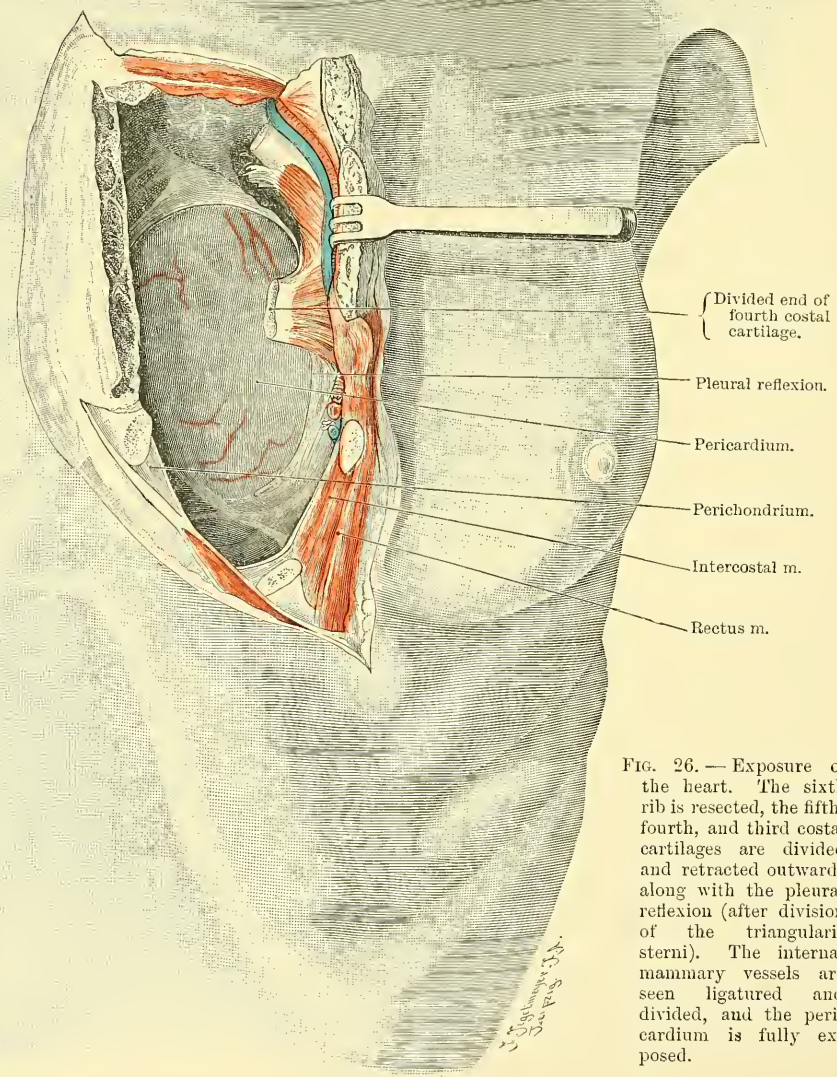

FIG. 26. — Exposure of the heart. The sixth rib is resected, the fifth, fourth, and third costal cartilages are divided and retracted outwards along with the pleural reflexion (after division of the triangularis sterni). The internal mammary vessels are seen ligatured and divided, and the pericardium is fully exposed.

base of the flap is made at the sternum, produces more injury than the operation we recommend.

Two fingers should be passed behind the heart, which should be raised up before the sutures are inserted. To explore the posterior surface of the heart Terrier and Reymond grasp the apex with a pair of Museux's forceps, the same instrument which Longo uses for securing the edges of the wound.

According to Rehn, it is important to leave the ends of the first suture long, as the seat of the injury can then be pulled up and the insertion of a continuous suture is facilitated. Heitler recommends that the heart should be painted with cocain before introducing the sutures so as to prevent reflex arythmia.

The strictest asepsis must be observed throughout the operation as otherwise death may result from pericarditis and pleurisy. If the operation is aseptically carried out the pericardium and pleura should be immediately stitched up, while a drain is necessary only in infected cases.

Vaughan has observed that the prognosis is better if several hours have already elapsed since the injury, for in these cases the damage is not so severe. His case died of hæmorrhage, 2000 c.cm. of blood being found in the pericardium and pleura, so that it is well to resort as early as possible to saline transfusions.

It is beyond doubt that we can attain our object by various methods, and the position of the external wound is to be considered in choosing our procedure. Rehn, Parozzanni and Pagenstecher have reported successful cases of suture of the heart. The latter surgeon was able to collect 10 cases of heart suture with 6 recoveries (all being wounds of the ventricles). Other methods have been employed unsuccessfully by Farina, Cappelen, Giordano; and for exposure of the heart only, by Stelzner, Podrex, and others.

The results of cardiac surgery up to the present time show that it is the duty of every physician and surgeon to take immediate and active measures in cases of injury in the cardiac region, associated with symptoms of involvement of the heart. The latter consist, apart from acute anaemia, of "herztamponade" (impairment of the heart's action by effusion), specially referred to by Morgagni, and described by Rose as a diagnostic symptom of cardiac injury. In this connection the following points are to be specially noted:—

1. Blunt force may also damage the heart without producing any external wound. Mansell-Moulin removed a large quantity of blood from the pericardium, the result of a heavy blow three weeks previous, and the patient recovered.

2. Still more remarkable are the effects of gunshot injuries, where, although the shot had not penetrated the pericardium, serious injury to the heart was produced, as in eight cases collected by Deschamps. On the other hand, shot can be tolerated in the heart for a considerable time without the appearance of severe symptoms.

3. Further, one must not forget that punctured wounds inflicted by a needle are often very serious. Loison collected 23 such cases, 14 of which resulted in death. The worst cases are those in which the needle remains stuck in the thoracic wall, as the heart then tears itself against it. Terrier and Reymond found 3 recoveries (cases described by Foy, MacDougall, and Stelzner), in which the needles were simply pushed right into the heart, as they could not be removed.

4. It must be remembered that the initial symptoms are not necessarily of a serious nature, as some patients can even walk (as in A. Paré's case), but afterwards die suddenly, Stewart adducing such a case observed by a colleague and another by Izzo. There may even be an entire absence of dyspnœa and cyanosis, the result of compression of the great veins (Cohnheim) or of associated pulmonary complication (hæmothorax). If these complications are present the pulse is almost insensible, the cardiac region is dull, and when there is an associated injury to the lung the heart's action makes a gurgling noise which naturally renders the diagnosis much easier.

Watson, Senn, Begouin, Bruhl, and others have proved the efficiency of cardiocentesis in animals in cases of entrance of air into the veins, and thence into the right side of the heart, and in cases where the right side of the heart was over-distended with blood. The procedure has also been employed in the human subject.

5. Finally, it must be borne in mind by the resident physicians who generally see these cases first, that in rupture of the heart secondary to diseases of the arteries, the patient does not die immediately, but may live for twenty-four hours or more. Even in these cases, therefore, it is justifiable to attempt to relieve the pressure on the heart (herztamponade), and even to suture the ruptured organ.

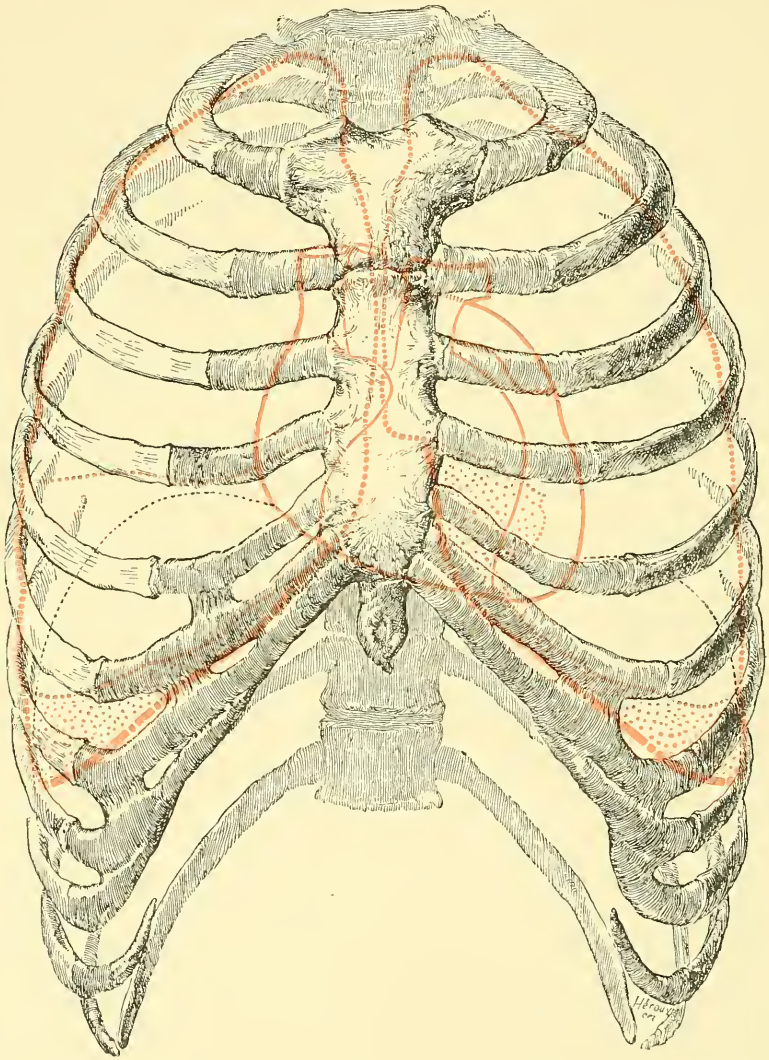

FIG. 27.—Combination of figures from Spalteholz and Merkel's *Anatomy*, showing the outlines of the heart (red line), lungs (thick dotted red lines), and the pleuræ (thin dotted red lines). The diaphragm is outlined in black.

In addition to the treatment of pericarditis, cardiac injuries and foreign bodies in the heart, cardiac surgery has developed in three other directions, namely—cardiac massage, cardiocentesis, and cardiolysis.

In considering the treatment of collapse under chloroform, exposure and massage of the heart have been recommended as important measures. Tuffier has exposed and massaged the heart in animals in which cardiac paralysis had been produced by

means of an anæsthetic, and also in a case of syncope from embolus while Rotter refers to Kuliabko's and Maag's experiments on animals. Sick succeeded in resuscitating a case by means of cardiac massage when there had been complete collapse for the space of an hour (Helfreich's clinic).

It is interesting to note that since J. Wolf reported a recovery from a wound of the heart in 1642, Del Vecchio in 1895 was the first to suture the heart successfully in the case of a dog, and after two unsuccessful attempts by Cappelen and Farina in 1896, Rehn in 1897 published the first famous successful cardiorrhaphy in man. Elsberg later on laid down precise directions for the treatment of the exposed heart, and Terrier and Reymond were able to collect 51 published cases in which operation was undertaken for cardiac injury, in 19 of these cases with complete success.

F. T. Stewart, in 1904[1] collected 60 cases with 23 recoveries. To show the importance of asepsis, it is interesting to note that not less than 13 of the 37 deaths were due to infection. In 57 cases the pleura was injured as well. Of the 4 cases

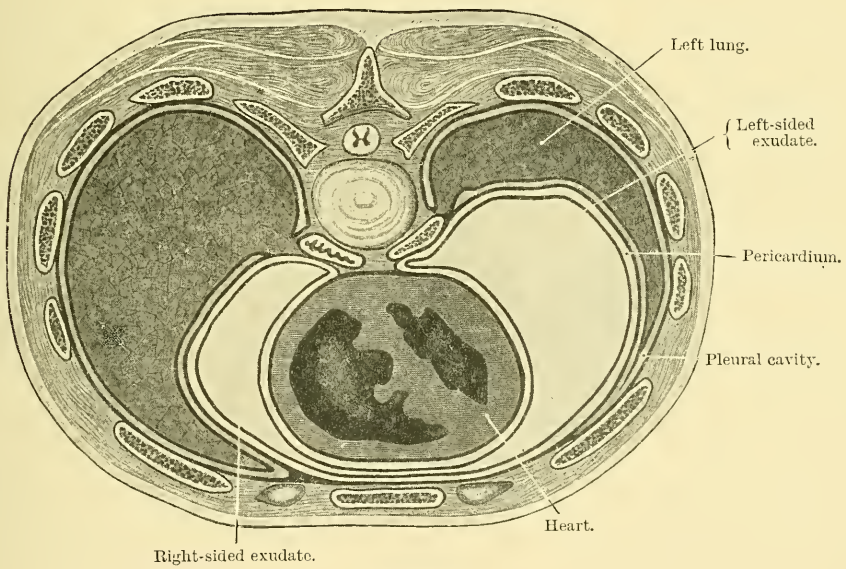

FIG. 27*a*.

in which there was injury to the coronary arteries, Stewart's patient only, in whose case the injury was produced at the operation, recovered by means of suture.

2. Puncture, Incision and Drainage of the Pericardium. Fig. 27 (after Spalteholz) indicates the outlines of the heart and pericardium in relation to the anterior wall of the thorax. The base of the pericardium extends transversely across the root of the ensiform process from a point 2 cm. ($\frac{3}{4}$ inch) to the right of the sternum, to a point 7 cm. (3 inches) to the left of the sternum, *i.e.* to the apex beat in the fifth intercostal space. Above, it reaches as high as the second rib, *i.e.* the root of the great vessels—in other words, the origin of the brachio-cephalic trunk (innominate artery) from the aorta, and the bifurcation of the pulmonary artery. A corresponding portion of the superior and inferior venæ cavæ is enclosed within the pericardium. Its posterior surface, according to Luschka, reaches as high as a line drawn through the middle of the manubrium sterni.

Paracentesis of the pericardium is indicated, according to Curschmann, in cases of serous, sero-fibrinous and hæmorrhagic effusion:—(1) when the fluid is rapidly increasing and oppressing the heart and lungs, causing dyspnœa, cyanosis, and a small

[1] *Transactions of the Coll. of Phys. Philadelphia*, 1904.

rapid pulse; (2) and when absorption does not take place, especially if there is concurrent disease of the heart and lungs or the presence of fluid in the pleura.

Curschmann uses a flat trocar with a lancet-shaped flattened point. It is fitted with a stop-cock, to which a rubber tube is attached, and the fluid is very slowly drawn off.

In selecting the site where we should make the puncture, which is only indicated when there is an extensive effusion, Curschmann has shown that the choice is determined by conditions quite different from those which fix the site when the heart itself is to be reached in cases of injury to the organ. The portion of the pericardium, which is in closest contact with the thoracic wall, is to be avoided in performing paracentesis, for when fluid accumulates in the pericardium it does so chiefly laterally, and at the same time distends the pericardium outwards, specially to the left, and backwards. In this way the heart itself comes to be closest to the chest wall. Fig. 27*a* reproduces in horizontal section the appearance of an extensive effusion after Curschmann's excellent demonstration.

Curschmann, therefore, advises puncture in the mammary line in the fifth or sixth intercostal space, or even farther out so as to ensure reaching the fluid. The needle, of course, traverses both layers of pleura. If the puncture is made close to the sternum, as recommended by Delorme, Mignon and Voinitsch, care must be taken to avoid the internal mammary vessels which lie one to two centimetres from the edge of the sternum. Puncture in this position as well as at Dieulafoy's point (6 cm. from the edge of the sternum) is attended with the risk of injury to the heart. Lateral puncture necessarily injures the pleura, although the lung escapes as it is pushed aside in all extensive effusions, which alone justify puncture. According to the researches by Ferrand and Voinitsch-Sianojentzky, a small quantity of fluid collects in the pericardium between the heart and the diaphragm, chiefly anteriorly and towards the apex when the patient is in the sitting posture; and when the patient is in the recumbent posture it also collects between the chest wall and the anterior surface of the heart towards its base, and round the large vessels. Paracentesis pericardii is in such cases not free from danger of injuring the heart. The use of puncture for small effusions should therefore be extremely limited.

The removal of a serous effusion is only indicated when there are symptoms of pressure on the heart, *i.e.* when the effusion is very extensive. In these cases puncture, according to Curschmann's directions, is of itself sufficient.

When the effusion is of a sero-fibrinous or hæmorrhagic character, in addition to causing pressure on the heart there is the further risk of pericardial adhesions forming after the fluid has coagulated. This formation is best prevented by pericardiotomy rather than paracentesis, as the coagulated lymph can only be thoroughly removed by the former procedure.

The statistics in regard to suppurative pericarditis are so convincing that aspiration by simple puncture is no longer regarded as adequate. Terrier and Reymond quote a thesis by Fevrier, in which 9 cases of suppurative pericarditis treated by puncture are reported with 9 deaths. On the other hand there were 6 recoveries in 19 cases treated by incision without resection, and 8 recoveries in 14 cases treated by incision and resection. Reichardt reports 2 cases successfully operated on by Lindner (in Ewald's clinic).

In 1884 Gussenbauer introduced the correct route by which to open the pericardium, viz. by resection of the fifth rib. Ollier has also practised this method, while Roberts and Porter established the technique and raised it to the status of a normal procedure.

To avoid the necessity of resecting a rib, Larrey reaches the pericardium through an incision along the lower border of the seventh rib, a route which Mintz has recently approved. An incision, 7 cm. long (3 inches), is made along the lower border of the seventh rib, and the abdominal muscles are detached and the cartilage divided in two places and turned upwards. In this way the pericardium is exposed in a few minutes. Delorme and Mignon resect both the sixth and fifth ribs.

A number of surgeons have favoured trephining and resection of the sternum, a

method which was recommended by Riolan and which has lately received the support of Voinitsch and Giordano. Since Voinitsch has proved by experiments with gelatine injections that in the sitting posture small effusions collect in the recess between the anterior attachment to the diaphragm and towards the apex, this position is to be considered the most suitable to secure drainage at the operation as well as afterwards. If there is any risk attached to the administration of a general anæsthetic, the resection of the rib and the opening of the pericardium may be satisfactorily accomplished under local anæsthesia.

3. Cardiolysis. The term cardiolysis is applied to the operation in which the pericardium is opened for the treatment of extensive pericardial adhesions. Delorme devised the operation originally for the treatment of pleural adhesions, and afterwards applied it to the heart.

Very free access is essential, and for this reason a preliminary operation, similar to that described for injuries to the heart, is required. In our fourth edition we observed that in the real "symphyse cardiopericardique" of Delorme this operation is not free from danger, as the heart may be torn in spite of the greatest care.

When the adhesions involve the structures adjacent to the pericardium, namely, the sternum, mediastinum, diaphragm, and lungs, Brauer has endeavoured in another way to free the heart from the great mechanical disadvantage to which it is subjected in pushing the surrounding structures, *e.g.* when it pulls in the chest wall at every systole.

He makes no attempt to separate the indurated adhesions, but endeavours to mobilise the thoracic wall in front of the heart by means of resection. The term cardiolysis does not therefore quite aptly describe the operation. It might be termed pericardiolysis as it implies removal of portions of the sternum, although it is really a thoracolysis præcardiaca.

Simon (who with Peterson operated on Brauer's cases) employed a method similar to that Rotter uses to expose the pericardium, viz. by means of a swing-door flap with the base at the middle line. A flap of skin and muscle is thrown back, several ribs are resected, and a corresponding portion of the sternum is removed. Simon considers that it is absolutely necessary to remove the posterior layer of the periosteum of the sternum in order to prevent a fresh formation of bone. The removal of the sternum is the most critical stage of the operation.

This method undoubtedly affords relief from the cardiac insufficiency, dyspnœa, cyanosis, hepatic congestion and ascites, which result from indurated adhesive pericarditis, and has been suggested as a means of access to effusions in the pericardium, the complete removal and permanent drainage of which has to be taken into consideration.

There seems to be no reason why one should not proceed to the removal of effusions in the pericardium in the same way as with exposure of the pericardium for injuries of the heart. As there is only a limited area where it is tolerably certain that the pericardium is not covered with pleura, there is a double reason for choosing this region for puncture and incision when dealing with purulent effusions, so as not to infect the pleura.

In the case of a simple pericardiotomy, we therefore advise resection of the sixth rib at its junction with the sternum, using an oblique incision along the course of the rib (*vide* the low oblique incision in Fig. 26). The cartilage is removed, the posterior layer of the perichondrium and the triangularis sterni pushed aside together with the pleura, and an incision is then made into the pericardium large enough to admit a finger.

If this does not give sufficient room for separating the indurated adhesions, the fifth rib also may be removed, by means of a short vertical incision, as is advised by Ollier, Porter, Delorme and Mignon. If a pocket of pus still remains in the anterior cul-de-sac of the pericardium, the seventh rib may also be removed (Mintz) and free drainage obtained by pushing the pleura aside. If necessary the pericardium may be incised as far as the cardiac apex, a procedure which Reichard regards as essential.

To prevent the formation of dense adhesions between the heart and pericardium,

it is well in all cases of suppurative pericarditis to interfere at an early stage and wash out the coagulated fibrin. Normal saline is employed for this purpose as the use of corrosive sublimate, carbolic and other antiseptics must be regarded as positively harmful. Irrigation with weak (1 per cent) iodoformol may be considered in the recumbent position, but the semi-recumbent posture should be adopted to ensure good drainage of the exudate.

Beck [1] has reported three cases of mediastino-pericarditis (Brauer). The patients exhibited symptoms of tugging on the thorax during systole, diastolic cardiac impulse, degeneration of the myocardium, congestion of the liver and kidneys, and ascites due to pleuritic effusion.

The operation consisted in a partial resection of the bony thorax. A flap of skin and muscle was turned upwards, extending from the sternum to the anterior axillary line, and the convex free-border reaching down to the lower border of the sixth rib. The third, fourth, fifth, and sixth ribs were resected from the sternum to the anterior axillary line. The three patients recovered, and all the symptoms of congestion were relieved.

B. SURGERY OF THE LARGE ARTERIES

1. Ligature of the Abdominal Aorta. Keen of Philadelphia (1900) [2] has published the most recent article on ligature of the aorta giving 13 recorded cases. The first case was operated on by Sir Astley Cooper (25th June 1817), and the latest by Tillaux and Riche.[3]

In no instance has ligature proved successful. Tillaux and Riche's patient died thirty-nine days after the ligature from the effects of the altered circulation. The ligature did not give rise to ulceration, but, in this case, the occlusion of the aorta was incomplete. Keen's patient lived forty-eight days after the operation and died as a result of ulceration at the site of ligature, with consequent hæmorrhage.

Further attempts to ligature the aorta cannot therefore be justified, and other methods must be adopted for the treatment of aneurysm (the most common indication), such as the insertion of silver wire, or the use of intra-muscular injections of gelatine (2 to 5 per cent in 200 g.). In injuries to the aorta ligature must be effected by other methods.

Keen has devised a special instrument for compressing the aorta. By means of a screw, two horizontal plates are gradually approximated and the aorta is obstructed, the instrument being left in position for the requisite time (two to three days) and then removed. We venture to think that it would be more advisable to follow Lambotte's advice and use a metal clamp which would flatten the aorta from the front backwards, as in Keen's case circular constriction proved disastrous. Such a clamp could easily be removed at any moment.[4]

From the evidence afforded by the literature on the subject it is quite clear that in man, as in dogs, it is possible to ligature the aorta without producing fatal circulatory disturbances. The profound initial congestion—in Keen's case, the head and neck becoming livid — the acceleration of the pulse and the altered circulatory relations associated with paralysis of the legs, strangury and diminution in the secretion of urine may all disappear without permanent evil results.

As in previous cases, the operative procedure must be regulated by the prevalent conditions. When the peritoneum can be easily separated from the abdominal wall the operation may be satisfactorily performed extra-peritoneally, and we refer the reader for details of the operation to our description of ligature of the left common iliac artery, a method which we regard as a distinct improvement on its predecessors. The primary oblique incision is simply made a little higher up, convenient access is obtained, and the fasciæ, not the muscles, are divided. The vertical

[1] *Deutscher Chirurgencongress*, 1904.
[2] *American Journal of Med. Science*, Sept. 1900.
[3] *Revue de chir.*, 1901.
[4] *Brit. Med. Journ.*, Oct. 1904.

and transverse limbs of the angled incision through the fascia may be enlarged to any extent without any resultant harm.

If the peritoneum cannot be readily separated on account of inflammatory or hæmorrhagic infiltration, access to the aorta must be obtained by means of a median laparotomy. In Keen's case the pancreas was pushed up, and the vertebral column was reached between the pancreas and the stomach after division of the gastrocolic omentum, certainly no easier a route to follow than by access from the left side. Every case must be carefully considered before a decision is arrived at as to the method of procedure, while no one but an expert surgeon should attempt the operation. The advantages of arterial suture can only be observed in special cases, but, *a priori*, there is no reason why arterial suture should not be employed, more especially if the line of suture can be strengthened by the superposition of a reinforcing tissue such as fascia, periosteum, or peritoneum. Cases have been recorded where fatal hæmorrhage was prevented simply by the relation of the injury in the aorta to the spinal column.

2. Ligature of the Innominate Artery. To ligature the innominate artery an oblique incision (Gräfe, Winniwarter) is made from the junction of the middle and lower thirds of the anterior border of the right sterno-mastoid to the anterior surface of the manubrium sterni. After the skin and fascia are divided, the sternal origin of the sterno-mastoid is separated from the sternum. Two veins are to be avoided, namely, the transverse vein connecting the two anterior jugulars at the suprasternal notch, and the transverse terminal portion of the anterior jugular behind the origin of the sterno-mastoid. The outer borders of the sterno-hyoid and sterno-thyroid muscles, which are attached to the posterior surface of the manubrium sterni, are drawn inwards along with the branches of the descendens noni nerve, and the second layer of fascia is then divided. In this way the common carotid artery is reached behind the sterno-clavicular articulation. The right inferior thyroid vein is ligatured and divided. After passing between the sterno-mastoid and the muscles last named we follow the carotid downwards to its junction with the subclavian, below which the trunk of the innominate is ligatured, the pleura, which lies posterior and external, being avoided. The left innominate vein crosses from left to right in front of the artery. The vagus nerve, which descends in front of the subclavian artery, the recurrent laryngeal nerve, which winds round it, and the phrenic nerve remain uninjured.

Mott, who first attempted ligature in 1818, employed a horizontal incision along the clavicle. In our opinion this is not so effective a method and is only necessary in cases where it is desirable to expose the subclavian as well. On the other hand, a vertical incision in the middle of the neck in the interval between the sterno-thyroid muscles (Pirogoff) is the simplest method and entails the least amount of damage in cases where the pulsation of the artery can be felt above the sternum. In these cases, as well as in the performance of low tracheotomy, the artery can easily be reached with the finger.

Smith[1] has reported a case in which the innominate, common carotid, and vertebral arteries were successfully ligatured after an injury to the subclavian.

3. Ligature of the Common Carotid Artery (*vide* Fig. 28). The common carotid artery passes vertically upwards in the shortest direction from the chest to the head. It may be felt in its entire extent alongside of the trachea and œsophagus, and may be securely compressed against the vertebral column, preferably at the level of the cricoid, opposite which may be felt the projecting transverse process of the sixth cervical vertebra, the so-called carotid tubercle. The level of the cricoid cartilage is the seat of election for ligaturing the artery. The incision to expose it runs transversely in the line of cleavage of the skin, at the level of the cricoid cartilage, the middle of the incision being at the anterior border of the sterno-mastoid, the direction of which corresponds to a line passing from the angle of the jaw to the sterno-clavicular articulation.

The skin and platysma having been divided, the *transverse superficial cervical nerve* is seen passing forwards over the sterno-mastoid from its posterior border. The nerve

[1] Cf. Jordan, *Handbuch der prakt. Chir.*, Stuttgart, 1900.

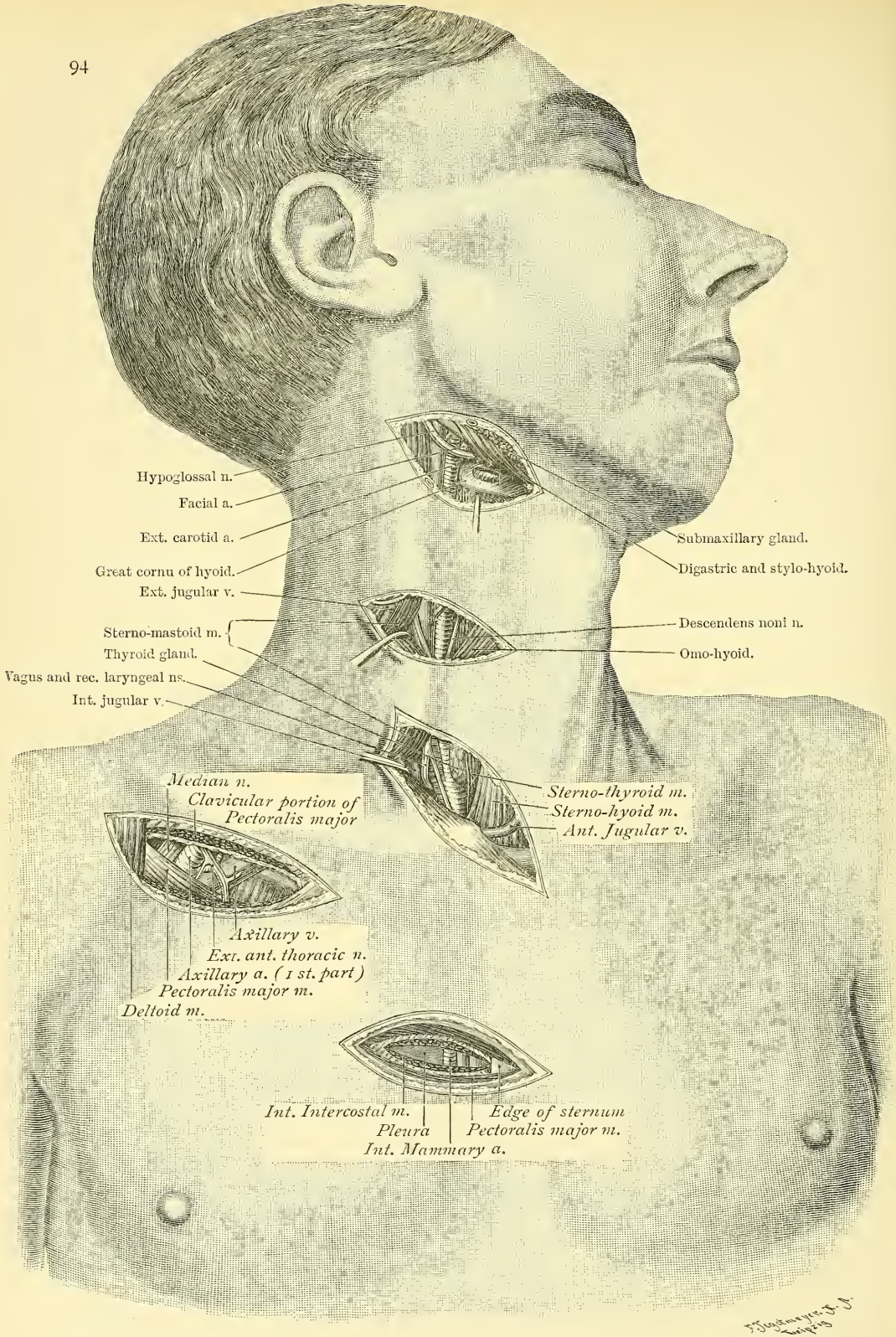

FIG. 28.—Ligature of the lingual artery above the greater cornu of the hyoid. Ligature of the common carotid at the level of the cricoid cartilage. Ligature of the innominate artery. Ligature of the first part of the axillary artery. Ligature of the internal mammary artery.

is avoided, and the fascia is divided so as clearly to expose the muscular fibres of the sterno-mastoid, the anterior border of which is drawn outwards with a blunt hook, exposing beneath it the omo-hyoid muscle, which passes upwards and somewhat inwards. The artery is now sought for in the angle formed by the divergence of those two muscles. It is still covered by a second fascia, which at the same time forms the sheath of the vessel. On opening the sheath the artery is exposed. The descendens noni nerve passes downwards upon the sheath and gives off branches passing forwards to the muscles which ascend to the larynx. This nerve is carefully drawn inwards. Great care must be taken that the vagus, which lies close to the posterior surface of the artery, is not included in the ligature. It may here be remarked that this close apposition occasions symptoms of pressure upon the vagus (slowing of the pulse, dyspnœa, and syncope) when the artery has to be compressed. The internal jugular vein lies upon the antero-lateral aspect of the artery, with the sympathetic nerve behind.

The risk associated with ligature of the common carotid artery is very considerable. According to Pilz, Lefort, and Zimmermann,[1] in antiseptic as well as in pre-antiseptic days, about one-third of the patients operated on died of cerebral disturbances. The condition of the arteries is an important factor in this respect as, if the collateral circulation is defective, the risks are considerably increased. Ligature is therefore to be avoided, if possible, when there is any arteriosclerosis, although in young robust individuals there is no risk of untoward results.

Temporary ligature of the common carotid is generally of great service. It is indicated, *e.g.*, when the source of hæmorrhage in the region of the pharynx cannot be ascertained, or when bleeding in the area of the internal carotid cannot be controlled by other means, while it also proves invaluable during arterioraphy.

G. Fowler[2] has even attempted to render excision of the Gasserian ganglion bloodless by the temporary ligature of both common carotids.

We suggest that the metal clamps used by Lambotte in the case of small arteries are suitable appliances for securing temporary closure, since less injury is caused by merely flattening out the intima and muscularis than by adopting a circular ligature.

Ceci[3] has proposed as a means of diminishing the danger incurred by ligature of the common and internal carotid, the method of tying the jugular vein on the same side in order to prevent anæmia of the brain. (Cf. Ligature of the Internal Carotid, No. 4.)

(a) Branches of the Common Carotid Arteries

4. Ligature of the Internal Carotid (see Fig. 29). In intracranial hæmorrhages (with the exception of those due to the middle meningeal artery), ligature of the internal carotid is preferable to that of the common carotid, as the collateral supply through the angular termination of the facial and the ophthalmic arteries is retained. The operation is identical with that for ligature of the external carotid, except that intervening between the two vessels we find the stylo-glossus and stylo-pharyngeus muscles, along with the deep fascia and the stylo-maxillary ligament.

In pharyngeal operations, in which sudden profuse hæmorrhages may occur, as well as in occasional cases of tonsillotomy, it is important to be certain as to whether the bleeding arises from the internal carotid, or from the branches of the external carotid (pharyngeal and tonsillar arteries). As regards tonsillotomy, although the internal carotid can be felt pulsating behind the tonsil, injury of the artery is not usually to be apprehended. The tonsillar branch of the palatine artery and the ascending pharyngeal artery are more likely to be the seats of injury, as they ascend towards the base of the skull within and in front of the internal carotid.

Boari[4] has shown the value of simultaneous ligature of the internal carotid and jugular vein (Ceci's theory), as he performed this operation with complete success

[1] Cf. Jordan, *loc. cit.*
[2] *Buffalo Med. Journ.*, June 1903.
[3] Paris Surgical Congress, 1904.
[4] *Policlinico*, 1905.

on a man aged forty-nine, for a gunshot wound inflicted on the carotid and the cavernous sinus.

5. **External Carotid** (Fig. 29). When ligature of the external carotid is sufficient for the arrest of hæmorrhage, the common carotid must never be ligatured in its place, as the procedure is dangerous, giving rise, according to Pilz and Friedländer, to brain disturbances in 19 to 32 per cent, and to a fatal termination in 13 to 18 per cent, of the cases in which it has been adopted.

Wyeth has reported similar results in a collection of 789 cases, but, in his experience,

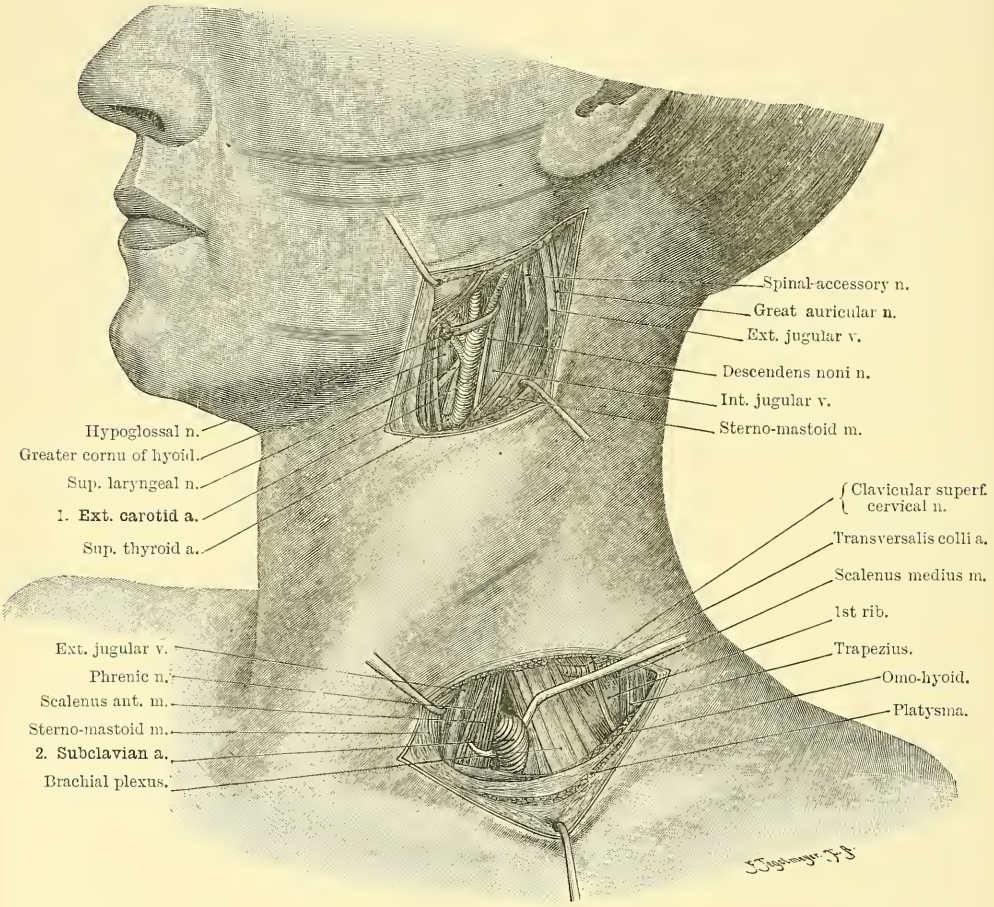

FIG. 29.—Ligature of the external carotid with the origins of the lingual, facial, and occipital arteries. Ligature of the subclavian artery.

the mortality from ligature of the external carotid is only 4·3 per cent (169 cases), while Lipps in 130 operations had only two fatalities. Ligature of the external carotid is not only indicated in hæmorrhage and when malignant tumours are adherent to it, but also as a prophylactic measure in extensive operations upon the jaws, the nose, and the face, while it also diminishes to a very great extent the hæmorrhage during resection of the jaw and operation on the naso-pharynx.

All hæmorrhages in the region of the head, with the exception of intracranial and intraorbital ones, can be arrested by ligaturing the external carotid artery and also the arteries from the vessels of the dura mater.

The point in our normal incision where the artery is felt to pulsate and where it is ligatured is at the anterior border of the sterno-mastoid muscle. The edge of this muscle is considerably more vertical than is usually represented, being drawn forwards towards the angle of the jaw by the cervical fascia. The artery is ligatured opposite a point which lies a finger's-breadth vertically below the angle of the jaw. To expose the vessel, therefore, we employ that part of our normal incision which courses over this region. The incision divides the skin and the platysma, the fibres of the latter passing upwards and forwards over the margin of the jaw, forming occasionally a well-developed muscular layer. At the posterior part of the wound is the external jugular vein, and behind it the great auricular nerve, both ascending vertically upon the sterno-mastoid. They are not divided, but are drawn backwards. On division of the cervical fascia the anterior border of the sterno-mastoid is exposed, and the facial vein is seen passing downwards over the digastric muscle to join the jugular. After drawing downwards the former vein, and ligaturing some of its branches, we get the external and internal carotid arteries into view, the latter lying posteriorly. The internal carotid gives off no branches, whilst the external carotid is identified by giving off the superior thyroid close to its origin, and farther up the lingual and other branches. These vessels cannot by this means be mistaken. Ligature of the external carotid is not an easy operation, because the only guides are soft parts (especially the sterno-mastoid muscle), which may vary with each operation. It is an excellent rule, therefore, after retraction of the sterno-mastoid to begin the dissection at the lower border of the digastric muscle. The hypoglossal nerve, which is recognised by the curved course it pursues, and from which the descendens hypoglossi is given off, is here the chief landmark. By division of the fascia immediately below the loop, the external carotid artery will be exposed, with the nerve curving from behind round it. Before applying the ligature, however, the operator must make certain, by observation of its branches, that it is not the internal carotid which has come into view. The descendens noni nerve, which supplies the depressors of the larynx, must be avoided, and it is still more important to avoid the *superior laryngeal nerve*, which passes transversely forwards behind the artery and the thyro-hyoid muscle.

The majority of the branches of the external carotid, viz. the *superior*, *thyroid*, *lingual*, *facial*, *and occipital arteries*, may be ligatured at their origin from the same incision. The course of these four important branches is sufficiently characterised by their direction, namely, downwards, forwards, upwards, and backwards respectively; and for practical purposes they may be regarded as springing from that part of the carotid which is crossed by the hypoglossal nerve. When those arteries are to be ligatured more peripherally, situations are to be selected which are more readily accessible and less dangerous.

(b) Branches of the External Carotid

6. Ligature of the Superior Thyroid Artery (Fig. 30). Ligature of the superior thyroid artery by itself is not easily performed. Unless there are any special difficulties in the way we always tie the artery in goitre operations, after the thyroid has been freed and "dislocated."

The operation is effected in the following manner:—An incision 6-7 cm. (2½ to 3 in.) long is carried obliquely upwards from the middle of the thyroid cartilage across the anterior border of the sterno-mastoid muscle. The skin, platysma and fascia are divided, and the anterior border of the sterno-mastoid is defined and retracted, the external jugular vein and the great auricular nerve being carefully avoided in the posterior angle of the wound.

The omo-hyoid muscle, which runs upwards and inwards under cover of the sterno-mastoid, is then freed along its outer border and is drawn inwards, while the facial vein, which joins the common facial vein above and behind, is freed and retracted backwards.

If the loop of the superior thyroid artery has not come into view, the guide to the situation of the artery is furnished by the large anterior branch which can

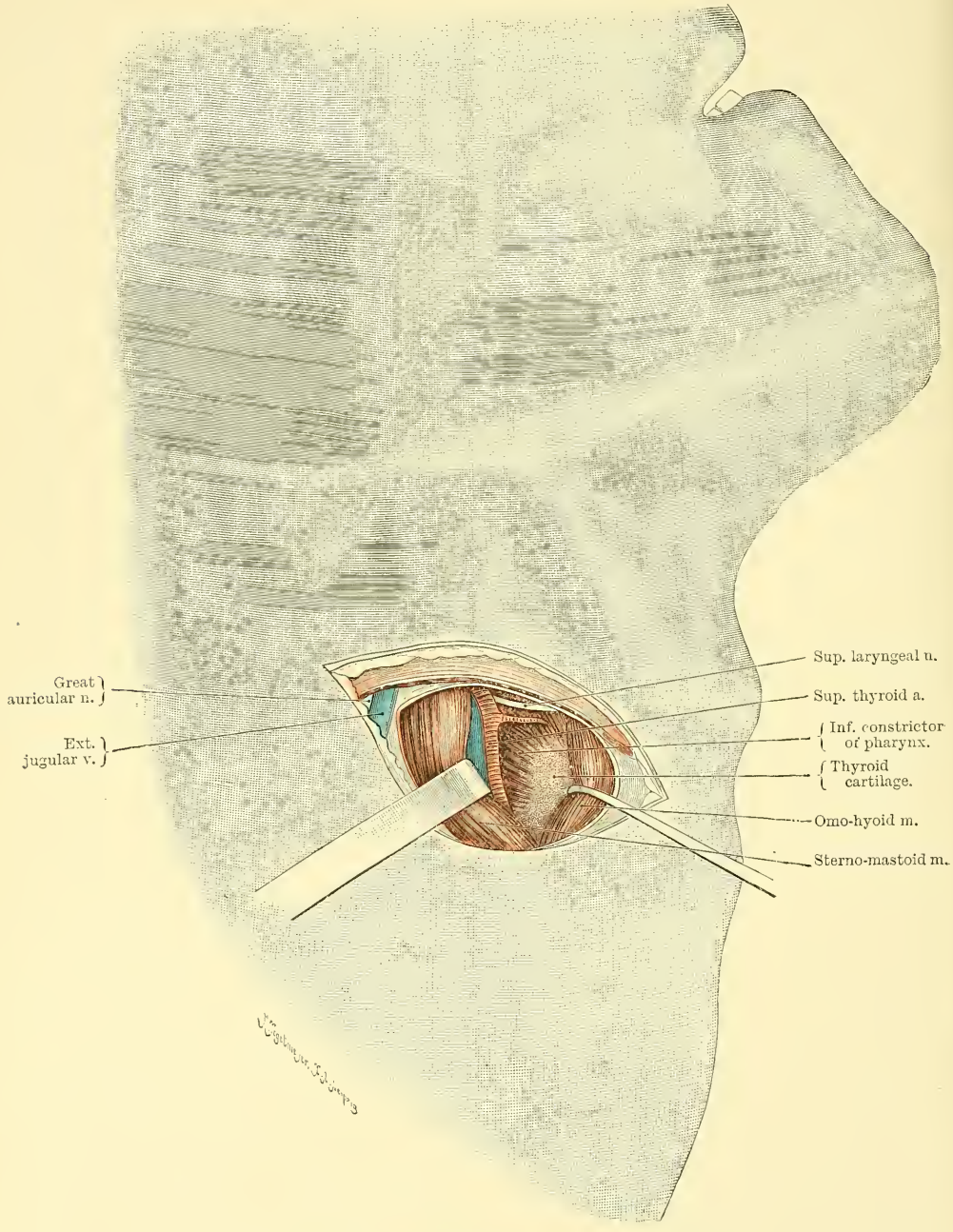

FIG. 30.—Ligature of the superior thyroid artery.

almost invariably be felt at the posterior border of the thyroid cartilage in the interval between the larynx and the upper pole of the thyroid body when this is high in position. By following this guidance we find the main trunk lying on the outer surface of the inferior constrictor of the pharynx, with the superior laryngeal nerve situated a little higher up.

As the trunk of the superior thyroid is extremely short, it is more effective to place the ligature beyond the hyoid and superior laryngeal branches, so as to cause no interference with the circulation in the larynx. The muscular branches must be included, particularly the crico-thyroid branch, which forms a free anatomosis with the vessel of the other side.

The artery is most satisfactorily divided between two ligatures, so that the operator may be able to pull the upper pole of the thyroid downwards and ensure the certainty of having also ligatured the posterior branch. Otherwise the danger is incurred of the establishment of collateral circulation from the numerous communications of the hyoid and laryngeal branches.

A nerve which accompanies the artery must be isolated, since its inclusion in the ligature may cause severe toothache and earache.

In difficult cases it is advisable to expose the external carotid artery by the same incision and isolate the superior thyroid artery at its origin, otherwise the large veins connected with the upper pole of the thyroid gland often make isolation of the artery near the gland very difficult. In women suffering from Basedow's disease, in whom it is important to obtain a fine scar, the incision should be carried not too obliquely but rather more transversely over the middle of the wing of the thyroid cartilage on to the sterno-mastoid muscle. At the upper pole of the gland the artery lies under cover of the capsule, which must therefore be divided, by which means the upper pole can be drawn downwards, and the operation consequently facilitated.

7. Ligature of the Lingual Artery. Ligature of the lingual artery is of great importance because it supplies a deeply-situated organ, the direct arrest of hæmorrhage from which is not always easy of attainment. So it is often desirable to perform a prophylactic ligature. The artery has a very definite course, inasmuch as it is directed towards the hyoid bone, and is placed close to the posterior extremity of its great cornu. It is most conveniently ligatured at this situation, because in most people the extremity of the great cornu of the hyoid bone can be felt through the skin, and therefore serves as a very distinct guide for the incision, which is made in the direction of our normal incision from the edge of the sterno-mastoid muscle along the great cornu of the hyoid bone as far as its body. The incision extends through skin, platysma, and fascia, just as if the object was merely to expose the great cornu of the hyoid bone. The facial vein often passes vertically downwards, or downwards and backwards, across the field of operation. The lower border of the submaxillary gland appears beneath the upper edge of the wound, below which the posterior belly of the digastric and the stylo-hyoid muscles descend towards the body of the hyoid bone. Those muscles are at a higher level than the seat of ligature.

It is advisable to press forward the hyoid bone from the opposite side of the neck. After exposing the great cornu in this way, we seize it with a hook and the bone is drawn forwards, a process which has the great advantage of rendering the entire field of operation more superficial. At the thickened posterior extremity of the cornu of the hyoid bone the fibres of the hyo-glossus muscle ascend vertically in a characteristic manner. The hypoglossal nerve passes from behind forwards upon the outer surface of this muscle, and behind the extremity of the hyoid bone it winds round the external carotid artery. The operator must now be very careful to cut through neither more nor less than the muscular fibres of the hyo-glossus close above the club-like extremity of the great cornu of the hyoid bone, immediately above which the artery is situated. We consider this to be the most reliable method of ligature.

As a second method for ligaturing the lingual artery, the incision above the digastric muscle has been recommended in the space known as Pirogoff's triangle. This is described by Winiwarter as due to Pirogoff-Hueter, while Roser, Malgaigne and Béclard incised underneath the digastric. The incision is made parallel to the great

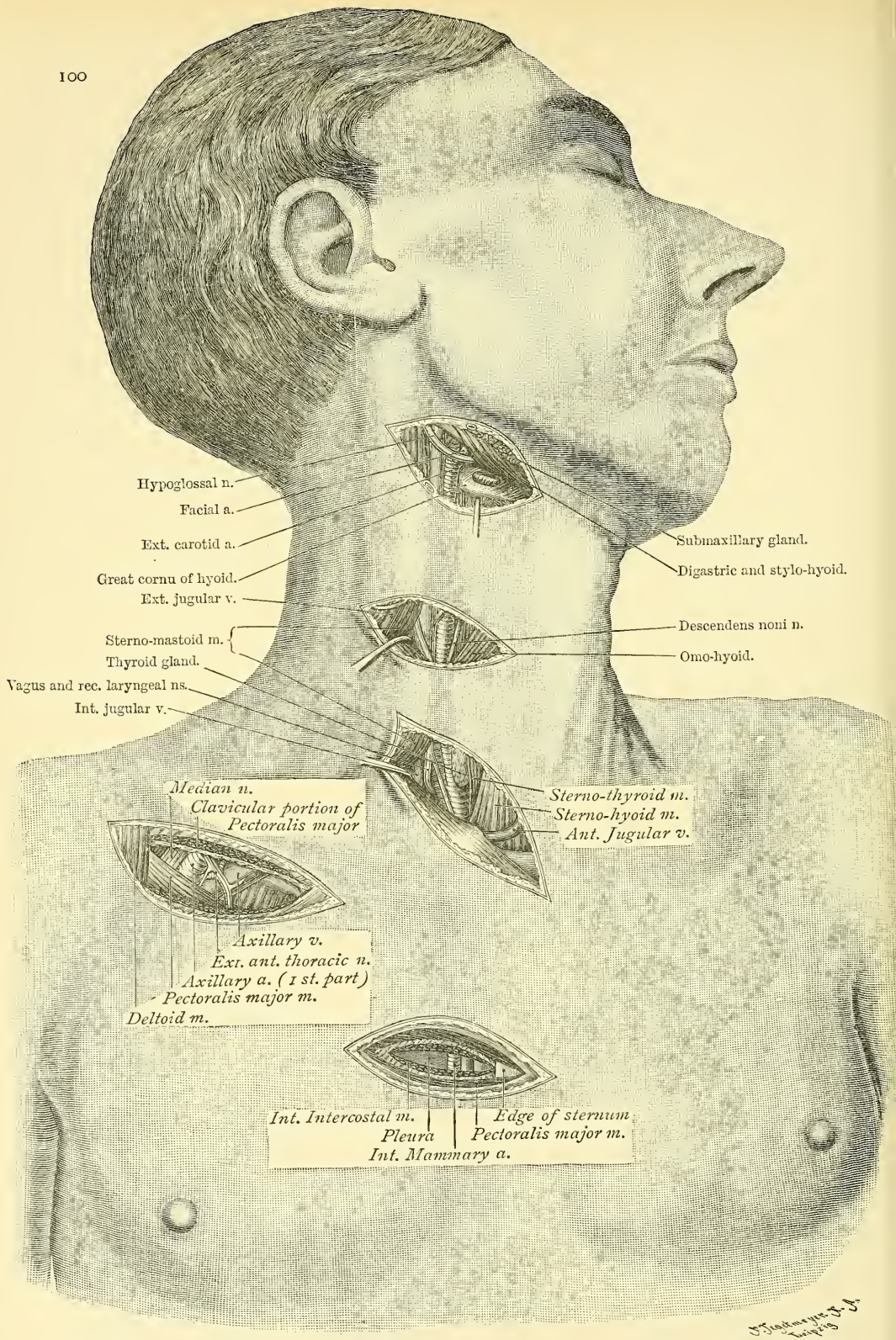

FIG. 31.—Ligature of the lingual artery above the greater cornu of the hyoid. Ligature of the common carotid at the level of the cricoid cartilage. Ligature of the innominate artery. Ligature of the first part of the axillary artery. Ligature of the internal mammary artery.

cornu of the hyoid bone through skin, platysma, and fascia, and the lower border of the submaxillary gland is drawn upwards along with the facial vein. The artery lies in the angle formed by the upper border of the digastric (together with the stylo-hyoid muscle) and the posterior border of the mylo-hyoid under the ascending fibres of the hyo-glossus. Upon the outer surface of this latter muscle is the hypoglossal nerve, and often the lingual vein.

We recommend ligaturing the artery in Béclard's triangle, and further consider it unnecessary invariably to look for the artery at its origin from the external carotid, as proposed by Mériel, for the above method is one of extreme safety and entails less

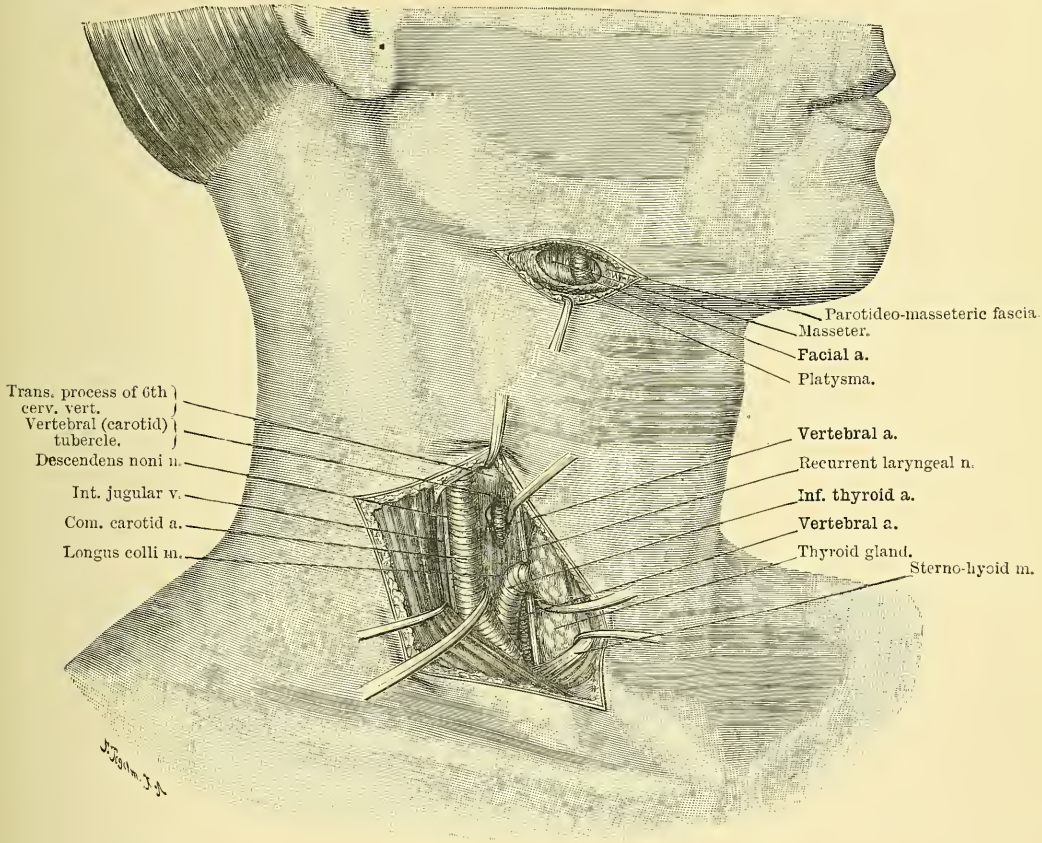

FIG. 32.—Ligature of the facial artery. Ligature of the inferior thyroid and vertebral arteries.

damage if care is taken to grasp the tip of the great cornu of the hyoid with one of our artery forceps or with a hook, and to make the incision close to the bone and just through the hyo-glossus muscle. Thiersch had previously recommended the method of pulling up the hyoid bone with a hook.

8. Ligature of the External Maxillary Artery (Facial) (Fig. 32). The place for ligaturing this artery can be very definitely determined, as it ascends over the lower border of the jaw just at the anterior border of the masseter muscle. It is accompanied by the facial vein, which, however, is not so constant in its course. An incision is made parallel to the margin of the jaw opposite the anterior border of the masseter. After dividing the skin, platysma, and fascia, we expose the artery, which is then to be freed from its surroundings. The supramaxillary branch of the facial nerve, which courses along the margin of the jaw, is to be carefully avoided.

Fig. 34 illustrates the incision suitable for ligature of the facial artery at the angle of the mouth. Bleeding from the labial arteries (*e.g.* in harelip operations) or from the angular artery can readily be controlled by the application of appropriate clamps to the cheek and lip.

9. Ligature of the Sterno-mastoid Artery is only undertaken in the case of injury.

10. Ligature of the Occipital Artery (Fig. 33). The occipital is the largest artery of the scalp, appearing at the inner border of the splenius muscle, midway between the external occipital protuberance and the highest point of the mastoid process, where it pierces the strong fascia and ascends over the occiput under the aponeurosis.

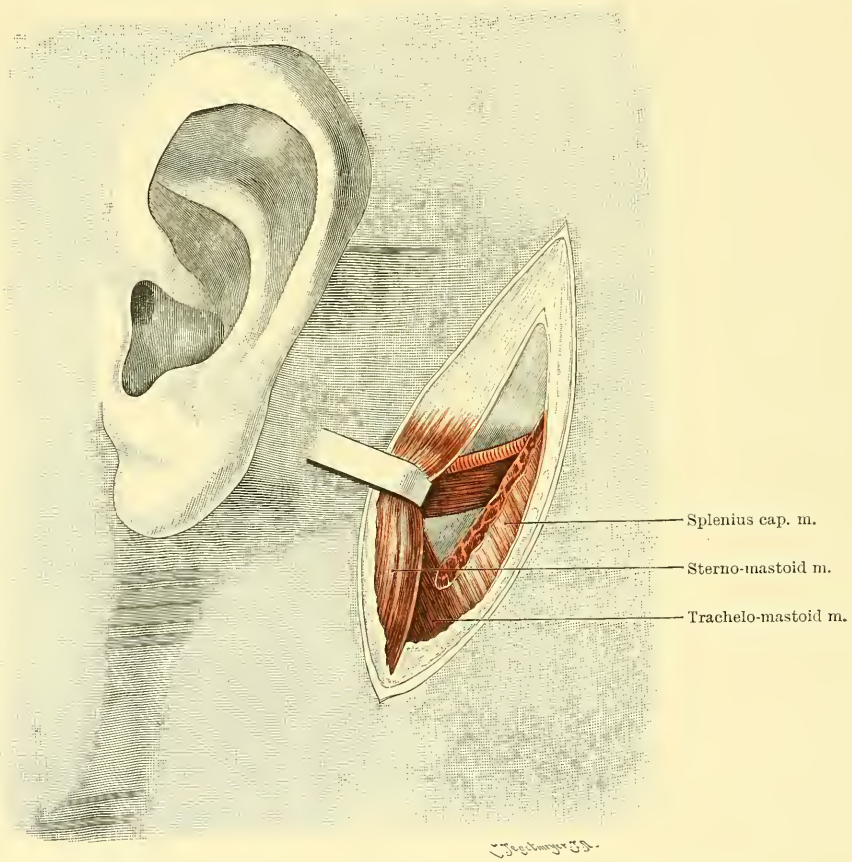

Fig. 33.—Ligature of the occipital artery underneath the splenius capitis.

The incision extends from a point immediately behind the mastoid process downwards along the posterior border of the sterno-mastoid muscle, the centre being placed opposite the tip of the mastoid process. The posterior border of the sterno-mastoid is exposed and its tendinous insertion is separated from the skull and retracted forwards. The splenius capitis, the fibres of which run obliquely upwards and forwards, is then exposed and divided transversely. At its anterior border the longissimus capitis muscle comes into view, under which the artery will be found running transversely backwards in contact with the skull.

The artery may be tied higher up where it lies underneath the fascia at the outer border of the trapezius muscle, and ascends to the skin of the occiput. Here the artery is joined by the great occipital nerve, which passes upwards and outwards.

The artery may also be ligatured at its *origin* by an incision similar to that for ligature of the external carotid. Here it passes under the digastric and stylo-hyoid. The occipital vein is not invariably found lying close to the artery.

Kappis[1] has collected 21 cases of aneurysm of the occipital artery in which either ligature or excision of the aneurysm was performed.

11. Ligature of the Posterior Auricular Artery. This artery, which ascends in the interval between the auricle and the mastoid process, is liable to be injured

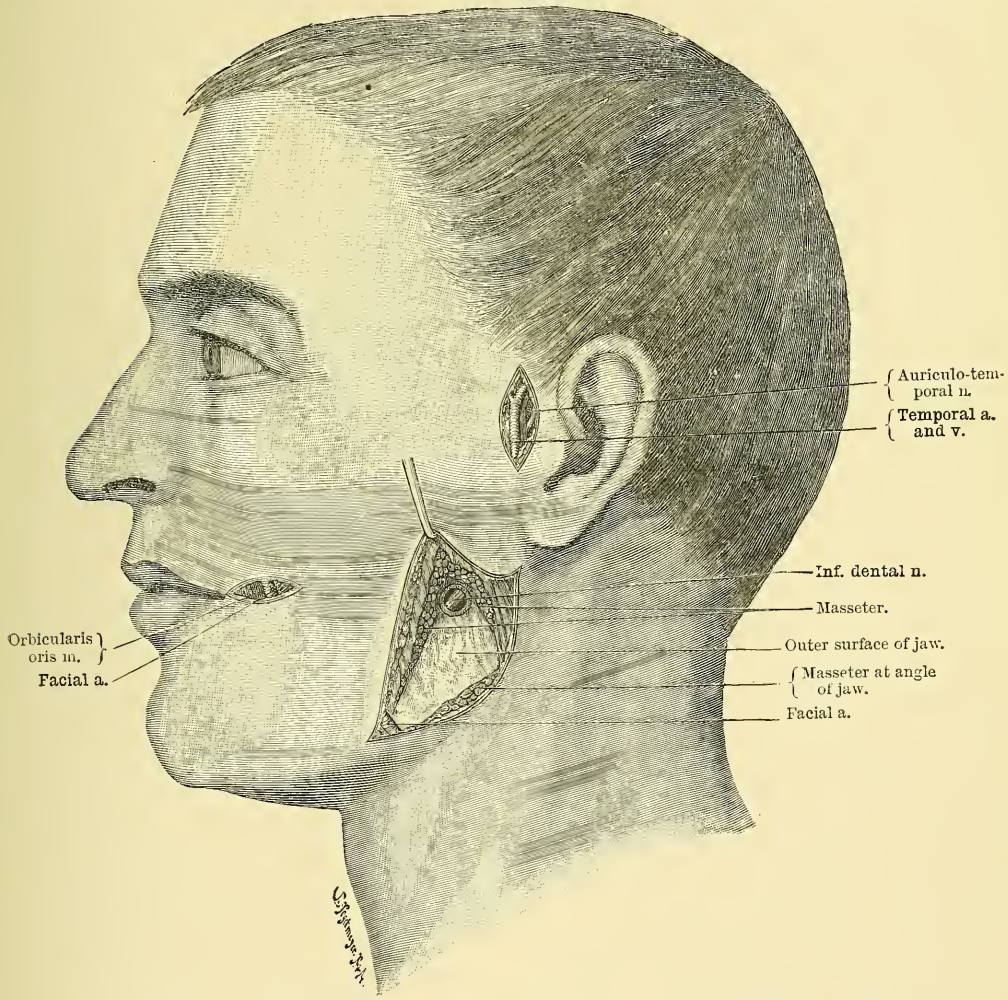

FIG. 34.—Ligature of the facial artery. Ligature of the temporal artery. Trephining the ascending ramus of the jaw to expose the inferior dental nerve.

only by an incision made too close to the auricle. With the incision we have described and which is now in general use for exposure of the mastoid process, the artery is pushed forwards along with the soft parts in operation on the antrum.

12. Ligature of the Ascending Pharyngeal Artery. 13. Ligature of the Ascending Palatine Artery. Ligature of these two arteries, which are in contact with the lateral wall of the pharynx, is only necessary in case of injury, ligature of the external carotid above the lingual artery, as a rule, being preferable.

[1] *Beiträge zur klin. Chir.* Bd. 40.

14. Ligature of the Internal Maxillary Artery. Notwithstanding the large size of this artery and its branches, ligature is seldom employed, as the artery lies entirely under cover of the lower jaw, at first behind the neck and then under the coronoid process.

Ligature of the external carotid above the origin of the facial artery is generally adopted in most cases of hæmorrhage in the region of the upper jaw, temple, or base

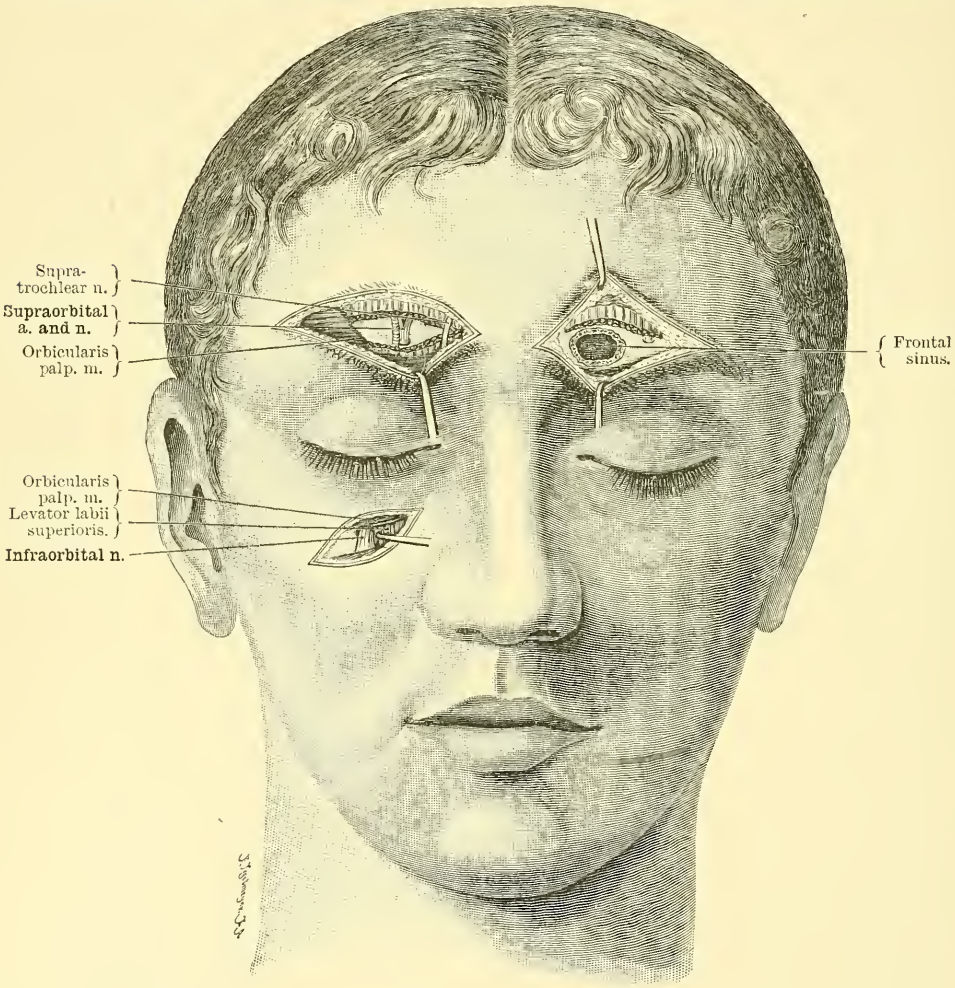

FIG. 35.—Ligature of the supraorbital artery. Exposure of the supraorbital nerve. Infraorbital nerve. Opening of the frontal sinus.

of the skull, when the bleeding cannot be controlled by simple ligature of the bleeding points or by other means.

The most important of its branches is the large middle meningeal artery, exposure of which branch is frequently necessary. But since the procedure of trephining is unavoidable in order to ligature this artery, we refer the reader to the chapter on Surgery of the Brain (section on Surgery of the Nervous System) for consideration of the subject.

15. Ligature of the Superficial Temporal Artery (Fig. 34). In contrast with the internal maxillary artery, the other terminal branch of the external carotid,

namely, the superficial temporal artery, is easily accessible for ligature, and it can be traced from the point where it crosses the zygoma as far as the temple and forehead.

The pulsation of the superficial temporal can be felt by inducing pressure on the zygoma $\frac{1}{2}$ cm. in front of the attachment of the helix, bleeding from its branches being easily controlled by pressure over this point, where it may also be ligatured, a vertical incision being made 1 cm. in front of the anterior end of the helix. After the skin is divided, the fascia and then the superficial layer of the aponeurosis are exposed, the artery lying under the fascia.

The position of the *temporal vein* is not constant. It is generally parallel to and behind the artery.

(c) Branches of the Internal Carotid

16. Ligature of the Ophthalmic Artery or of its terminal branches the **Supra-orbital and Frontal Arteries** (Fig. 35). The supraorbital is the principal artery of the forehead. It is smaller than the temporal artery, and leaves the orbit at the supraorbital notch, which serves as the guide in ligaturing the vessel. The course of the artery is vertically upwards through the fibres of the orbicularis and under the aponeurosis. After the eyebrow is shaved off, a transverse incision is made over the supraorbital margin.

(d) Subclavian Artery and its Branches

17. Ligature of the Subclavian Artery (Fig. 36). Arising behind the manubrium sterni, the artery arches over the pleura and apex of the lung and above the first rib between the scalenus anticus and medius, then passing beneath the middle of the clavicle between the subclavius and the serratus magnus to the outer surface of the thorax. It may be securely compressed at the outer border of the scalenus anticus muscle.

To ligature the artery a transverse incision is made a finger's-breadth above the clavicle, the operator beginning over the clavicular portion of the sterno-mastoid and passing outwards and slightly upwards to end at the anterior border of the trapezius. After division of the skin and platysma, the clavicular branches of the descending superficial cervical nerve are seen and must be divided. They pass over the clavicle to supply the skin over the shoulder and chest down to the level of the second rib. The external jugular vein, which lies along the posterior border of the sterno-mastoid, and finally winds round it to join the internal jugular, is to be avoided. It is dangerous to open this vein, because it is kept patent where it passes through the fascia, and air may be drawn into it during inspiration. In case it cannot be drawn inwards, a double ligature is to be applied before it is divided. After division of the fascia the omo-hyoid muscle appears at the inner angle of the wound, and passes upwards and inwards in the fatty tissue which contains the lymphatic glands of the triangle. The muscle is drawn either upwards and outwards, or downwards and inwards. In the fatty tissue lie the suprascapular artery, running outwards behind the clavicle, and the superficial cervical artery, running backwards and upwards. Above the latter, but under the deep fascia, is the larger transversalis colli artery, which passes backwards either upon or through the cords of the brachial plexus. After the adipose tissue has been removed the large nerve cords of the brachial plexus (covered by a thin fascia) appear between the scaleni, and pass almost vertically downwards under the clavicle. The relation of the artery to the plexus is very definite. The scalenus anticus is now followed downwards in front of the plexus to its attachment to the scalene tubercle (*tubercle of Lisfranc*) of the first rib, behind which lies the artery overlapped by the nerves. Internal to the scalenus anticus is the bulbous portion of the internal jugular vein; in front of the artery, and separated from it by the scalenus anticus, is the subclavian vein. The phrenic nerve descends into the chest upon the anterior surface of the scalenus anticus. The thoracic duct ascends from the chest into the neck close

to the scalenus anticus, and opens into the angle between the subclavian and internal jugular veins.

18. Ligature of the Vertebral Artery (Fig. 37). The operation for ligaturing the vertebral artery is similar to that for the inferior thyroid, but is more difficult, as the artery lies much deeper, behind the prevertebral fascia, and overlapped by the outermost fibres of the longus colli. The so-called *carotid tubercle* at the transverse process of the sixth cervical vertebra affords an excellent guide to the artery. The same tubercle is also made use of in tying the common carotid—hence its name. It

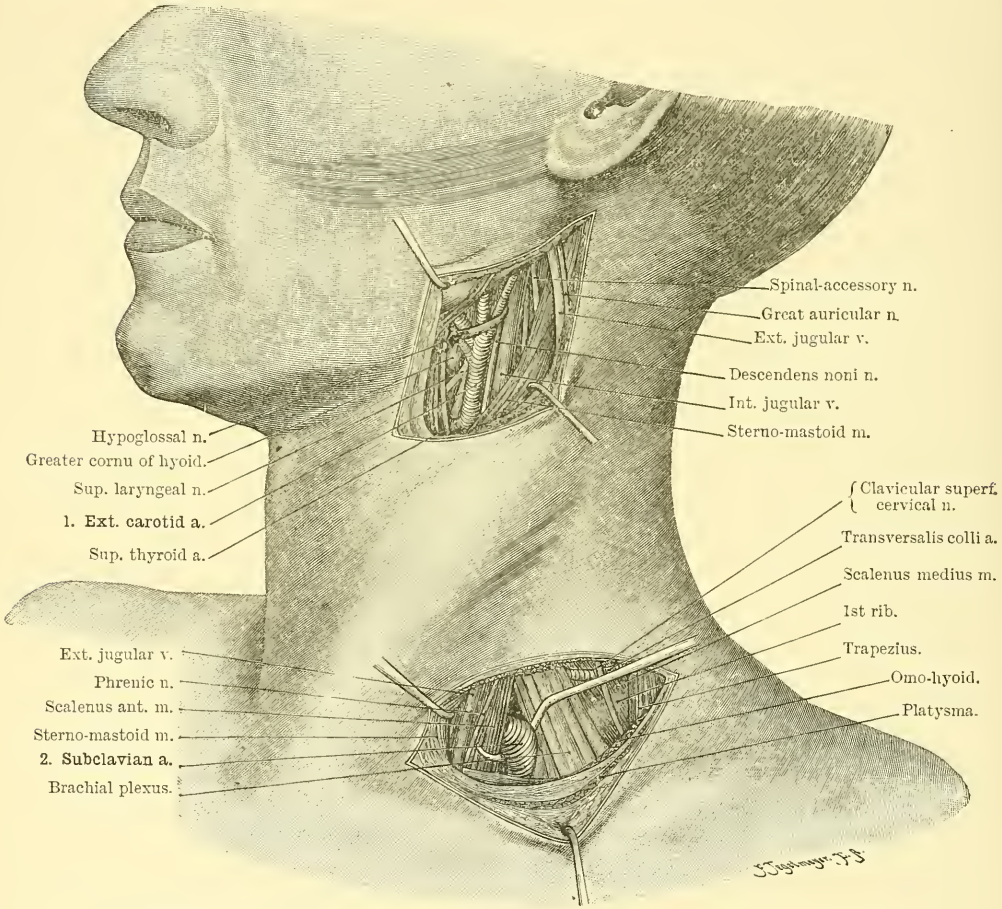

FIG. 36.—Ligature of the external carotid with the origins of the lingual, facial, and occipital arteries. Ligature of the subclavian artery.

is of no great significance, however, in ligaturing the carotid, but is very important in tying the vertebral, because the artery passes under it to enter the foramen in the corresponding transverse process. It would, therefore, be more to the purpose to speak of the projection as the *vertebral tubercle*. The artery passes towards the under surface of this tubercle. After drawing the sterno-mastoid outwards along with the large vessels, and the sterno-hyoid and sterno-thyroid inwards, we divide the prevertebral fascia above the arch of the inferior thyroid artery, when the vertebral artery will be felt ascending vertically upon and partly within the fibres of the longus colli, and disappearing at the lower surface of the transverse process of the

sixth cervical vertebra. Externally lies the scalenus anticus, and upon it the *phrenic nerve*, which descends from the outer border of the muscle across its anterior surface to enter the upper aperture of the thorax. Below the arch of the inferior thyroid artery the vertebral ascends almost vertically along with the recurrent laryngeal nerve.

Ligature of the vertebral artery on one side presents no point of special interest. Both arteries have been ligatured by Alexander and Baracz for epilepsy. Jordan attributes the operation we described to Frays and Kocher.

19. Ligature of the Internal Mammary Artery (cf. Fig. 37). The internal mammary artery supplies the inner surface of the anterior wall of the thorax, and

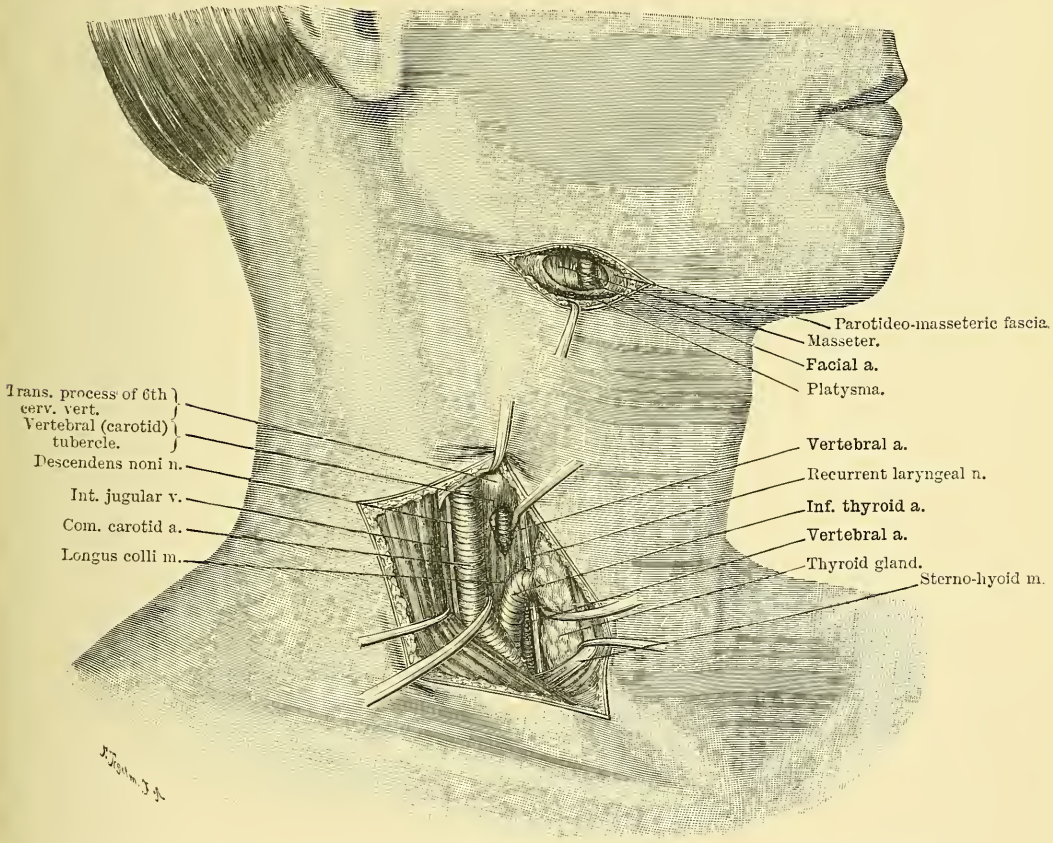

FIG. 37.—Ligature of the facial artery. Ligature of the inferior thyroid and vertebral arteries.

gives off perforating branches to the skin. It lies, with its accompanying vein, upon the pleura, separated from it only by a very thin layer of fascia, and lower down also by the triangularis sterni muscle. Anteriorly lie the costal cartilages and the intercostal muscles.

It is ligatured by making a transverse incision in those intercostal spaces opposite which the sternum is narrowest, preferably, therefore, the second. The incision is carried from the middle line of the sternum transversely outwards between the costal cartilages. After dividing this very thin and often interrupted membrane we reach the muscular fibres of the internal intercostal, which pass downwards and outwards with a well-marked fascia upon their under surface. After these are divided the artery is seen descending upon the pleura about $\frac{1}{2}$ to 1 cm. from the border of the sternum,

the vein lying to its inner side. In the lower intercostal spaces the internal mammary artery lies somewhat farther from the border of the sternum ($1\frac{1}{2}$ to 2 cm.) than it does higher up, and is separated from the pleura by the triangularis sterni muscle, on which it lies. In these intercostal spaces the artery requires consideration mainly in the operation for opening the pericardium.

Of its two terminal branches (superior epigastric and musculo-phrenic), ligature of the superior epigastric has only to be considered when the rectus abdominis is divided transversely in a laparotomy, the artery being found on the posterior surface of the muscle included within the sheath.

20. Ligature of the Superior Intercostal Artery. This artery is so deeply placed that the question of ligaturing it only arises when it has been accidentally injured during excision of the inferior cervical sympathetic ganglion.

21. Ligature of the Inferior Thyroid Artery (cf. Fig. 37). From a surgeon's

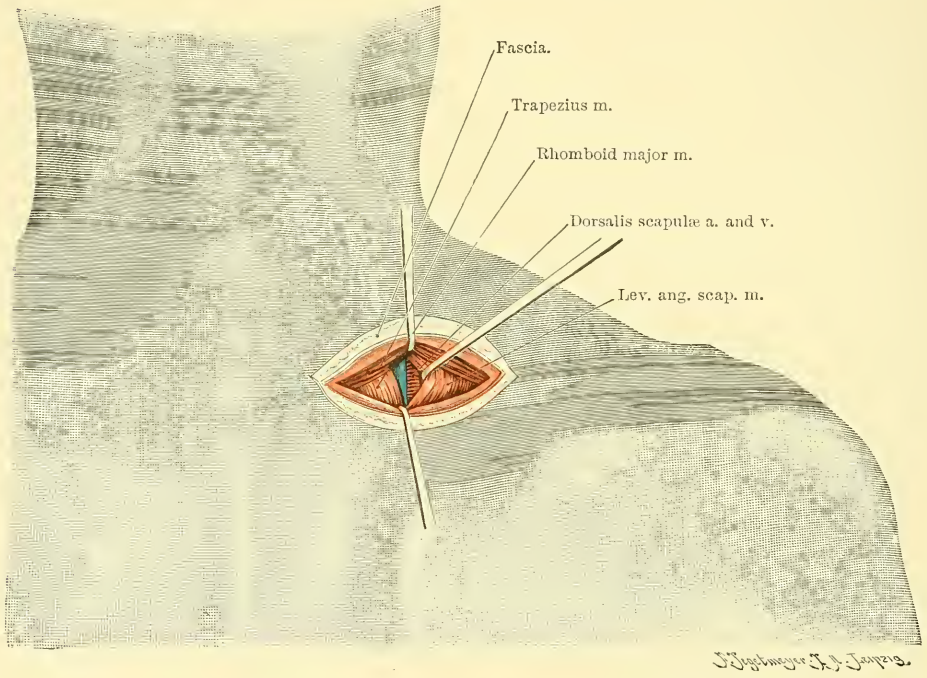

FIG. 38.—Ligature of suprascapular artery at the superior angle of the scapula.

point of view, the inferior thyroid artery is certainly the most important branch of the thyroid axis, on account of its relation to the thyroid gland. The ascending cervical, superficial cervical, and suprascapular arteries have frequently to be ligatured in operations in the region of the supraclavicular fossa. The last-named artery, which runs behind the clavicle to reach the scapula, is specially liable to injury.

[In this connection *vide* Ligature of the Subclavian Artery, p. 105 and Fig. 36.] The suprascapular artery may be ligatured with advantage in operations involving the scapula, as it sends large branches to the supra- and infra-spinous fossæ.

Ligature of the inferior thyroid artery is not easily performed. Its isolation may be so difficult that we often prefer to remove half the thyroid gland, while, on the other hand, during goitre operations it can be readily ligatured, if the lateral lobe is dislocated,—according to the method we describe,—the ligature always being applied after dislocation of the thyroid.

The artery passes inwards behind the common carotid, describing at the same

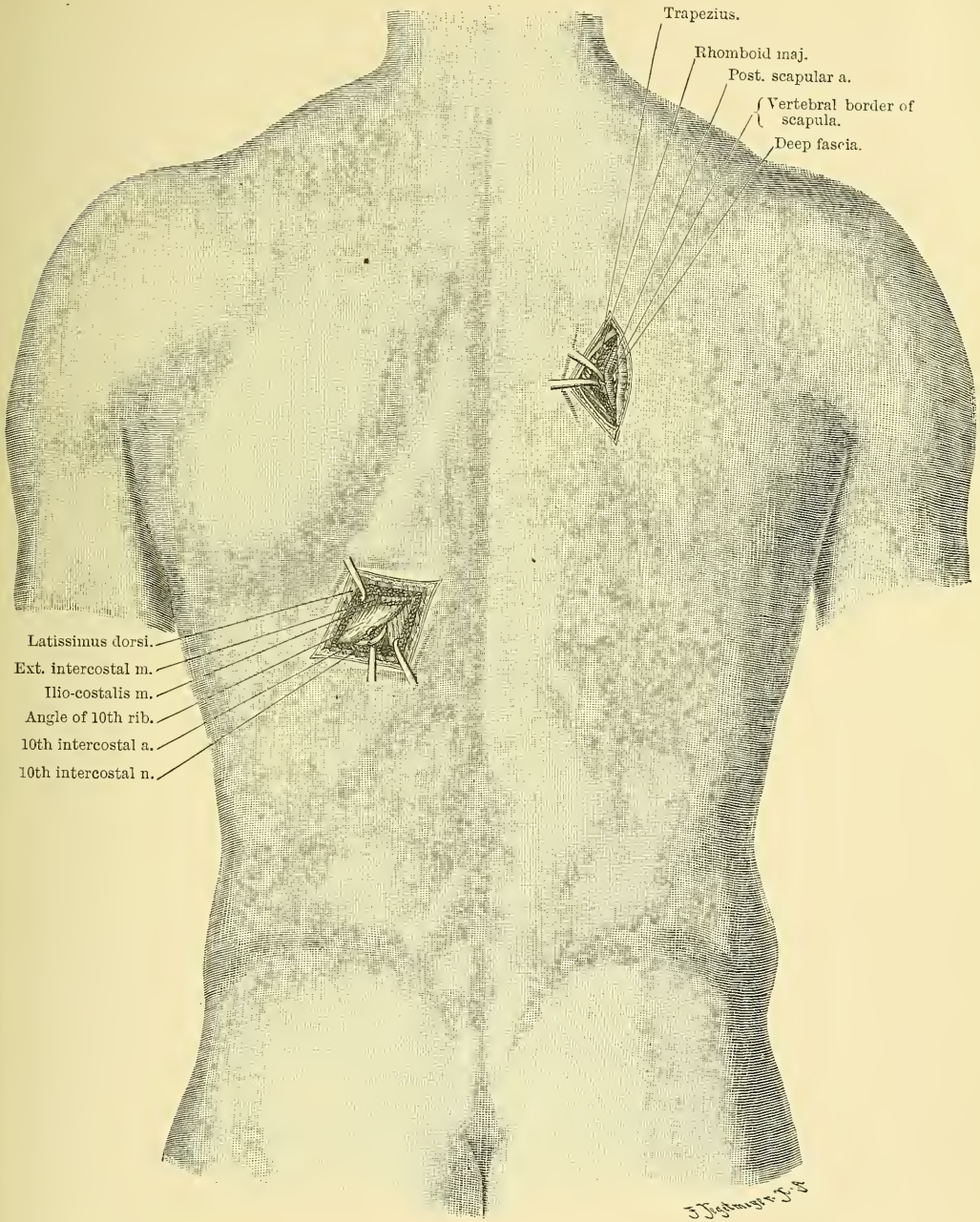

FIG. 39.—Exposure of the 10th rib and the 10th intercostal artery and nerve. Ligature of the posterior scapular artery.

time a well-marked curve convxe upwards. It can be safely exposed here on the anterior surface of the vertebral column, or in the transverse part of its course on the longus colli muscles.

A transverse incision of some length is required in the lower third of the neck,

in the direction of the "collar" incision which we recommend for excision of the thyroid, and extending from the prominence of the sterno-mastoid muscle to the middle line. The skin, platysma, and deep fascia are divided as already described. By forcible retraction of the sterno-mastoid outwards (see Fig. 37) and the sterno-thyroid inwards, the carotid artery is exposed in the outer and the thyroid gland in the inner part of the wound. By division of the capsule of the gland they can be separated. The inferior thyroid artery lies behind the gland.

All hæmorrhage must be carefully arrested during the operation, in order that a satisfactory view of the parts may be obtained, and the recurrent laryngeal nerve (which is the main motor nerve for the larynx) thereby preserved from injury where it crosses behind the artery. The nerve usually crosses behind the bend of the artery and ascends upon the longus colli muscle, from which it continues upwards in the groove between the trachea and œsophagus to the lower border of the cricoid cartilage. The cardiac branches of the sympathetic must not be injured, nor indeed the trunk of the sympathetic, which often consists of two parts embracing the artery. When the thyroid gland is enlarged the fascia must be freely divided so that the gland may be raised and drawn towards the middle line with a large blunt hook-retractor, in the course of which the inferior accessory thyroid vein is divided between two ligatures, while the sterno-thyroid muscle must be freed in the middle line, detached high up, and retracted outwards.

22. **Ligature of the Transversalis Colli Artery** (*vide* Fig. 36). This large artery is ligatured by the method adopted for the subclavian artery above the clavicle. The artery is readily recognised from its position at the outer border of the scalenus medius and the course it takes between the trunks of the brachial plexus. The suprascapular and the superficial cervical arteries lie respectively below and above it.

23. **Ligature of the Posterior Scapular Artery** (Fig. 38). This terminal branch of the transversalis colli deserves special mention, as it can be ligatured both at the superior angle of the scapula where it lies under the insertion of the levator anguli scapulæ, and at the vertebral border of the scapula beneath the insertion of the rhomboids.

(*a*) *At the upper angle of the scapula.* An incision is made from a little outside the vertebra prominens, obliquely outwards and slightly downwards towards the shoulder. It passes over the place where the superior angle of the scapula can be felt. The skin, fascia, and trapezius are divided parallel to the fibres of the muscle, whereby the upper border of the rhomboideus minor is exposed, running from above downwards and outwards. Externally is the thick belly of the levator anguli scapulæ descending from the neck to be attached to the angle of the scapula. By pulling this muscle outwards we find the artery upon its under surface. Upon the thorax lie the upper part of the ilio-costalis muscle internally, the insertion of the scalenus posticus superiorly, and the ribs and intercostal muscles externally.

(*b*) *At the inner border of the scapula* (Fig. 39). At the level of the middle of the infra-spinous fossa the artery will be found by making an incision along the inner border of the scapula. At the upper angle of the incision is the oblique lower edge of the trapezius muscle, the strong aponeurosis of which is divided close to the edge of the scapula. On detaching the tendinous insertion of the rhomboideus major from the scapula the artery will be seen upon the under surface of the muscle, running parallel to the border of the scapula on the serratus posticus crossing the upper border of the rhomboideus minor.

(e) Axillary Artery and Arteries of the Arm (Figs. 40 and 41)

24. **Ligature of the Axillary Artery** (Figs. 42, 43, 44). According to anatomical description, the axillary artery extends from the subclavius muscle on the under surface of the clavicle to the lower border of the pectoralis major (anterior axillary fold). It can be ligatured at three points in its course.

(*a*) *By a transverse incision below the clavicle* (Fig. 42). The incision is made 1 cm. below the middle third of the clavicle, dividing the fibres of the platysma together

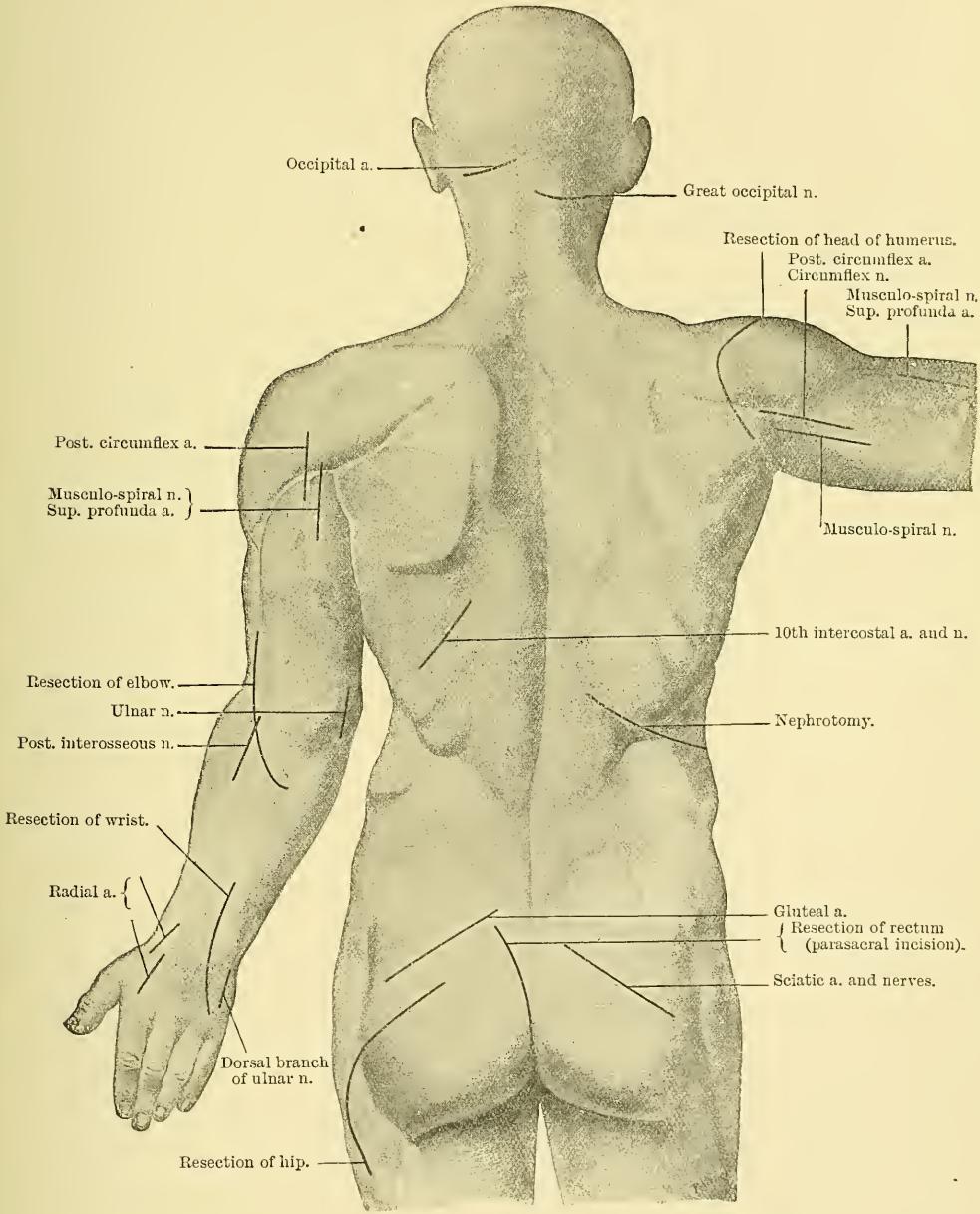

FIG. 40.

with the sensory *supra-clavicular nerves*. In dividing the fascia, we must avoid the *cephalic vein* at the anterior edge of the deltoid. The clavicular fibres of the pectoralis major are now divided, and the cephalic vein, together with the branches of the acromio-thoracic artery and the anterior thoracic nerves, is drawn upwards. The

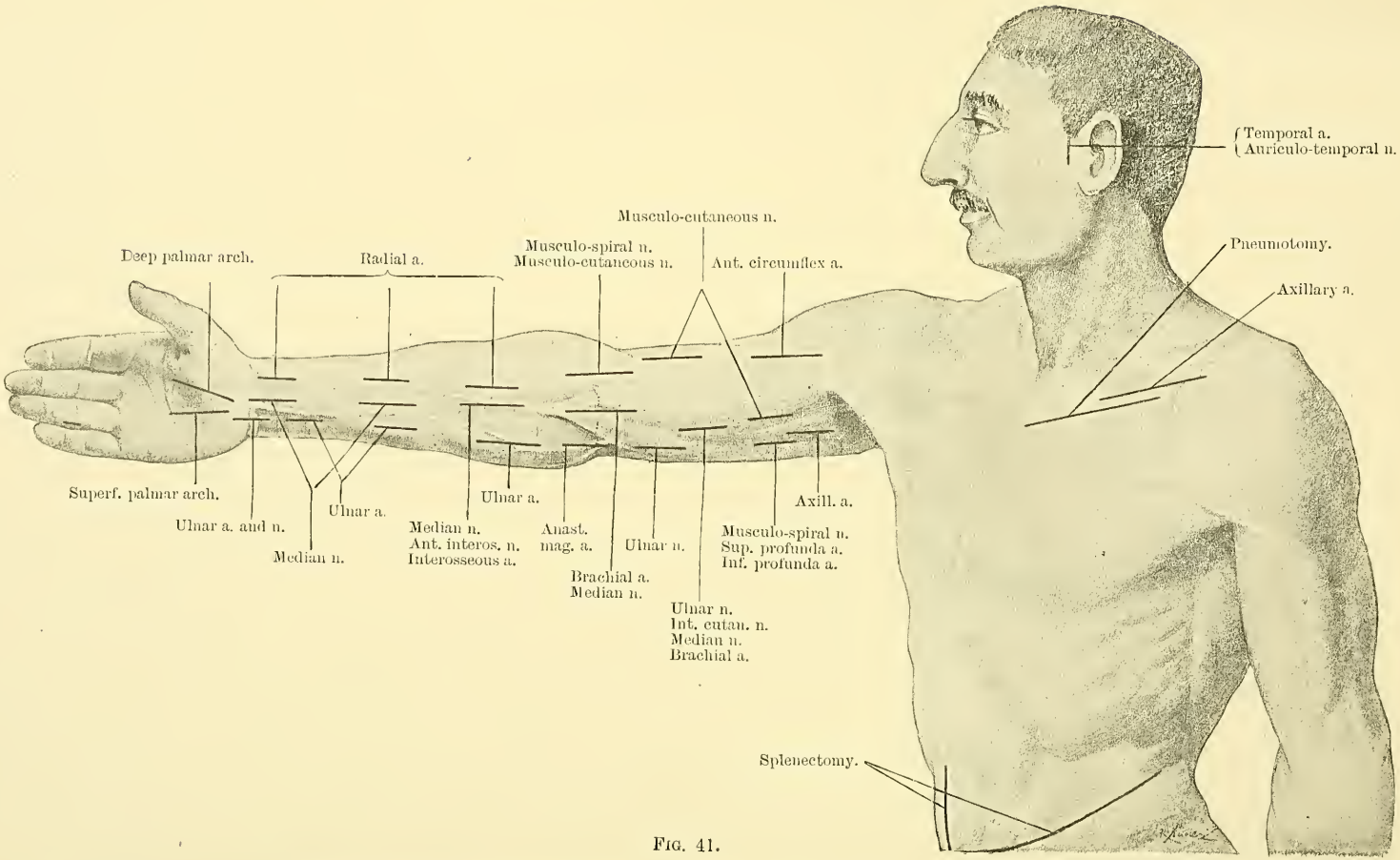
Temporal a.
Auriculo-temporal n.
Pneumotomy.
Axillary a.
Splenectomy.
Musculo-cutaneous n.
Deep palmar arch.
Radial a.
Musculo-spiral n.
Musculo-cutaneous n.
Ant. circumflex a.
Superf. palmar arch.
Ulnar a. and n.
Median n.
Ulnar a.
Median n.
Ant. interos. n.
Interosseous a.
Ulnar a.
Anast. mag. a.
Brachial a.
Median n.
Ulnar n.
Ulnar n.
Int. cutan. n.
Median n.
Brachial a.
Musculo-spiral n.
Sup. profunda a.
Inf. profunda a.
Axill. a.

FIG. 41.

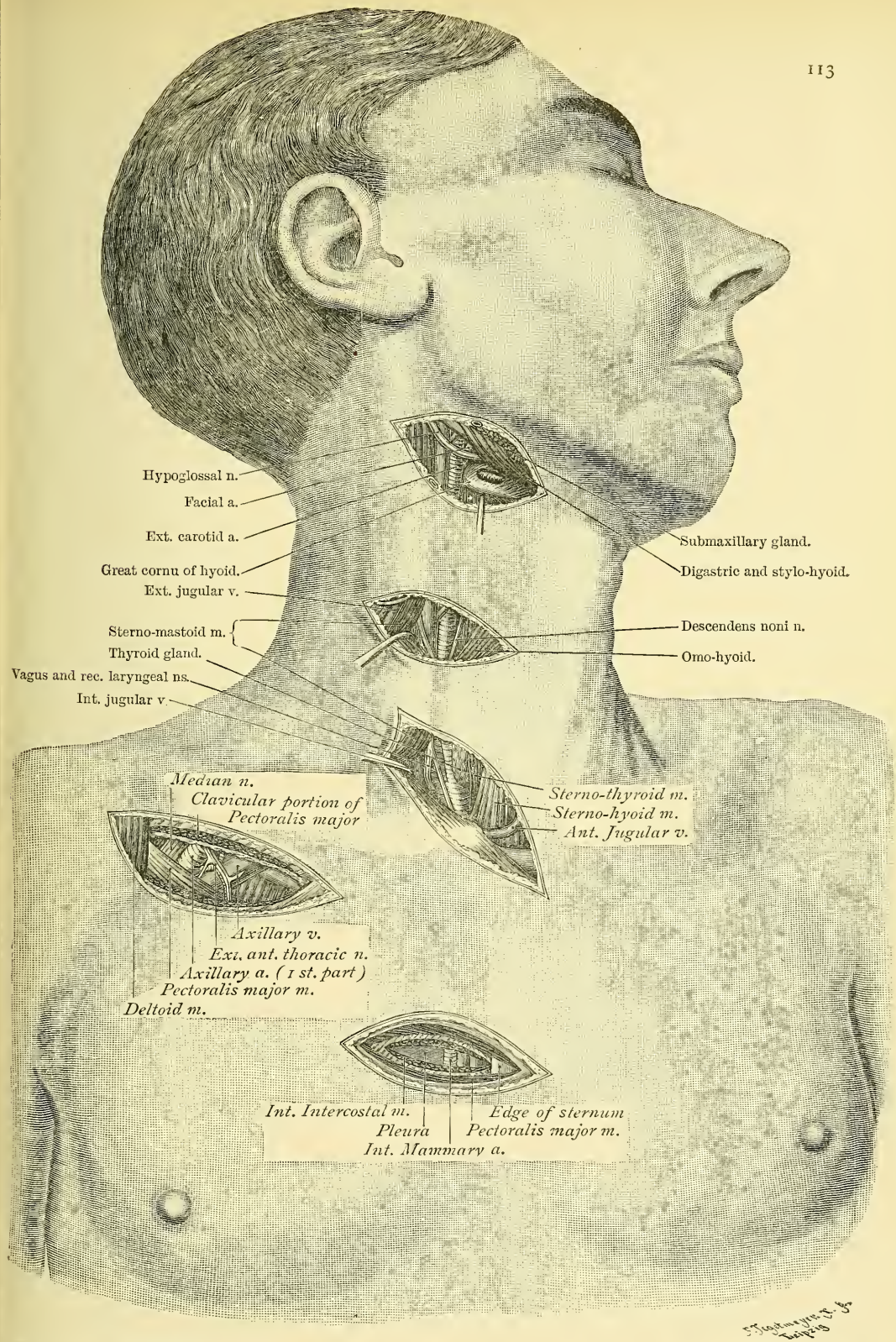

FIG. 42.—Ligature of the lingual artery above the greater cornu of the hyoid. Ligature of the common carotid at the level of the cricoid cartilage. Ligature of the innominate artery. Ligature of the first part of the axillary artery. Ligature of the internal mammary artery.

nerves are small, appearing below the clavicle, and cross the vessels to supply the pectoral muscles. The costo-coracoid membrane is divided below the clavicle, and the upper edge of the pectoralis minor is exposed. The *axillary vein* now appears, and externally the *cords of the brachial plexus* are exposed. The most superficial of the larger nerve trunks alongside the vein is the outer head of the median. After it is freed along its inner edge, the artery comes into view underneath it in the angle between the clavicle and the upper border of the pectoralis minor, lying upon the serratus magnus muscle.

(*b*) *By a longitudinal incision between the deltoid and the clavicular portion of the pectoralis major* (Fig. 43). The surface guide to the vessel is afforded in this situation by the visible and palpable hollow between the deltoid and pectoralis major muscles. The incision is begun over the junction of the outer and middle thirds of the clavicle, and

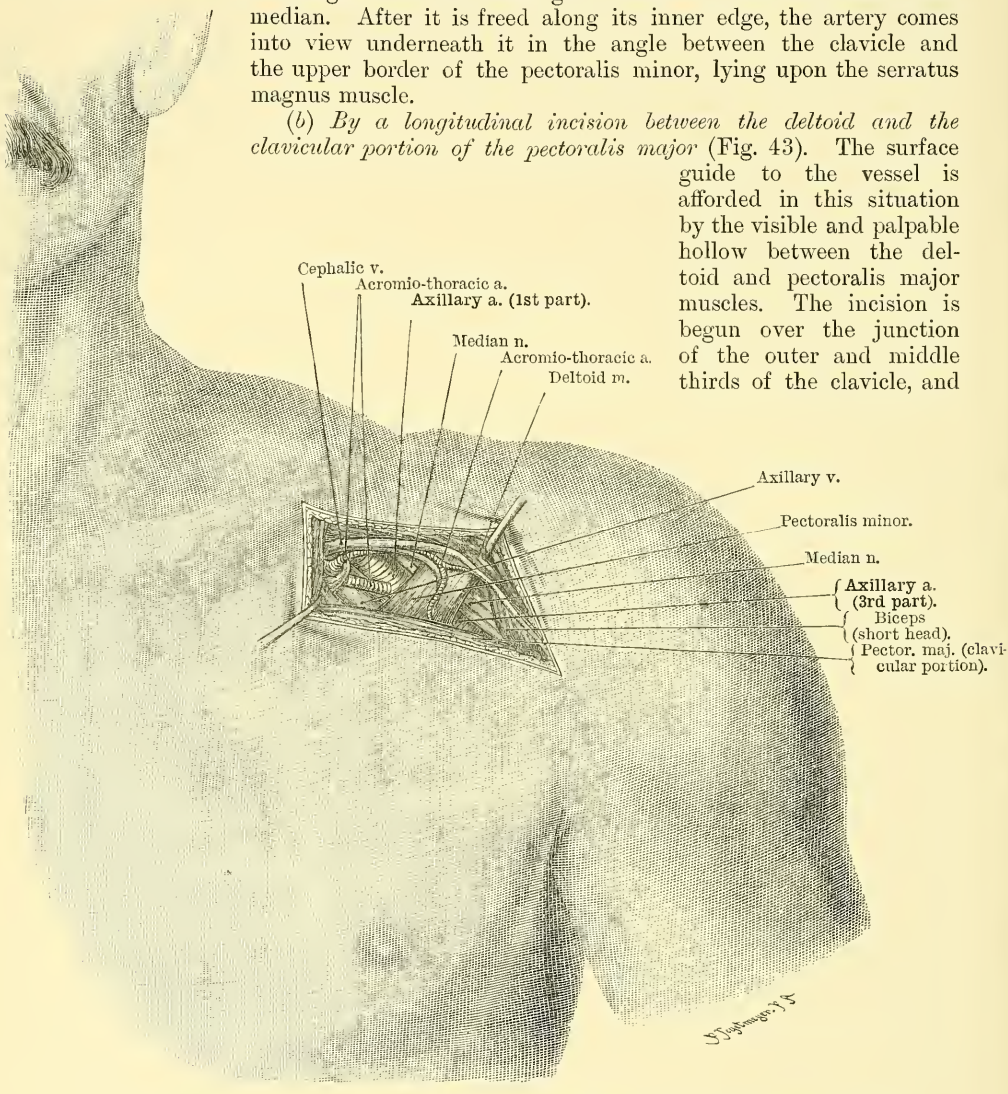

FIG. 43.—Ligature of the axillary artery, above or immediately below the pectoralis minor.

passes downwards over the coracoid process along the groove between the deltoid and the clavicular portion of the pectoralis major as far as the junction of the anterior fold of the axilla with the upper arm. The cephalic vein appears at the edge of the deltoid. The muscles are separated as far down as the upper edge of the tendon of the pectoralis major. On drawing the arm downwards the short head of the biceps appears from beneath the deltoid, and under the inner edge of the former is the coraco-brachialis muscle, pierced by the musculo-cutaneous nerve.

The lower border of the pectoralis minor is exposed from the coracoid process towards the thorax: between it and the coraco-brachialis lie the vessels and nerves, the large vein being internal. The axillary vein and the median nerve [inner head] are now drawn inwards, when the axillary artery will be seen lying beneath and external to them. External to the artery is a smaller collateral vein.

The operation is more easily performed by separating the pectoralis major muscle from the clavicle for a short distance. The artery may also be ligatured above the pectoralis minor with this incision.

As will be observed from Fig. 43, the operation is rendered simpler if the pectoralis minor is divided at the coracoid process. Kolliker[1] even regards division of the pectoralis major as the normal method for exposing and ligaturing the axillary artery. It should, however, be reserved for specially-difficult cases. As already stated in clearing out the axilla in disease of the breast, the pectoral muscles are divided so that the main vessels may be completely exposed up to the clavicle.

(*c*) *From the axilla to its lowest end* (Fig. 44). The line of the vessel is from the middle of the clavicle to the middle of the anterior fold of the axilla. The artery is in contact with the outer wall of the triangular prismatic space between the thorax internally, the pectoralis major and minor anteriorly, and the scapula covered by the subscapularis muscle posteriorly. With the arm fully abducted, an incision is made through the skin and fascia along the line of the internal bicipital groove over the inner edge of the prominence of the coraco-brachialis. The muscular fibres of the coraco-brachialis are exposed, with the large nerves of the axilla—which may be felt through the skin upon the prominence of the head of the humerus—lying along its inner border. The dissection is now to be continued between the musculo-cutaneous and median nerves, otherwise a collateral vein running alongside the coraco-brachialis may easily be taken for the artery. The smaller external nerve is the *musculo-cutaneous*; the larger internal one is the *median*, which is single below, but higher up consists of two cords, the external of which unites above with the musculo-cutaneous, the artery lying in the fork between the two heads of the nerve. The *ulnar* and *internal cutaneous nerves* lie internal to the artery, the *musculo-spiral* and *circumflex* behind it. The main *vein* is quite internal to the artery, and a smaller collateral vein lies external to it.

25. Ligature of the Superior Thoracic Artery (Fig. 42). This artery arises from the axillary at the lower border of the subclavius muscle, and in ligaturing it the operator must be careful not to include the internal and external anterior thoracic nerves, which supply the pectoral muscles. The operation is similar to that of ligature of the axillary (see 24*a*).

26. Ligature of the Acromio-thoracic Artery. This is the chief artery of supply to the acromial region, and is exposed at the upper border of the pectoralis minor, through the incision described in 24*b*. It has most frequently to be ligatured in opening into the shoulder-joint by an incision between the deltoid and pectoralis major, as its acromial branch which runs outwards over the coracoid, and its humeral branch which descends in the above interval, are divided.

27. Ligature of the Lateral Thoracic (Long Thoracic) Artery. This branch of the axillary is given off at the lower border of the pectoralis minor. With the arm fully abducted, an incision is made immediately behind the swelling formed by the pectoralis major in the anterior fold of the axilla. The lower border of the pectoralis minor is exposed, and the artery is found under cover of this muscle lying on the serratus magnus. Behind it, the posterior thoracic nerve runs downwards on the serratus magnus, which it supplies.

28. Ligature of the Anterior Circumflex Artery (Fig. 45). Incision along the anterior border of the deltoid opposite the surgical neck of the humerus. The cephalic vein lies upon the fascia. It is important to define the groove between the deltoid and pectoralis major, and after division of the fascia the muscles are separated from one another, the deltoid being drawn outwards and the pectoralis major inwards. The outer borders of the short head of the biceps and the coraco-

[1] Lindner, *Inaug. Diss.*, Leipzig, 1904.

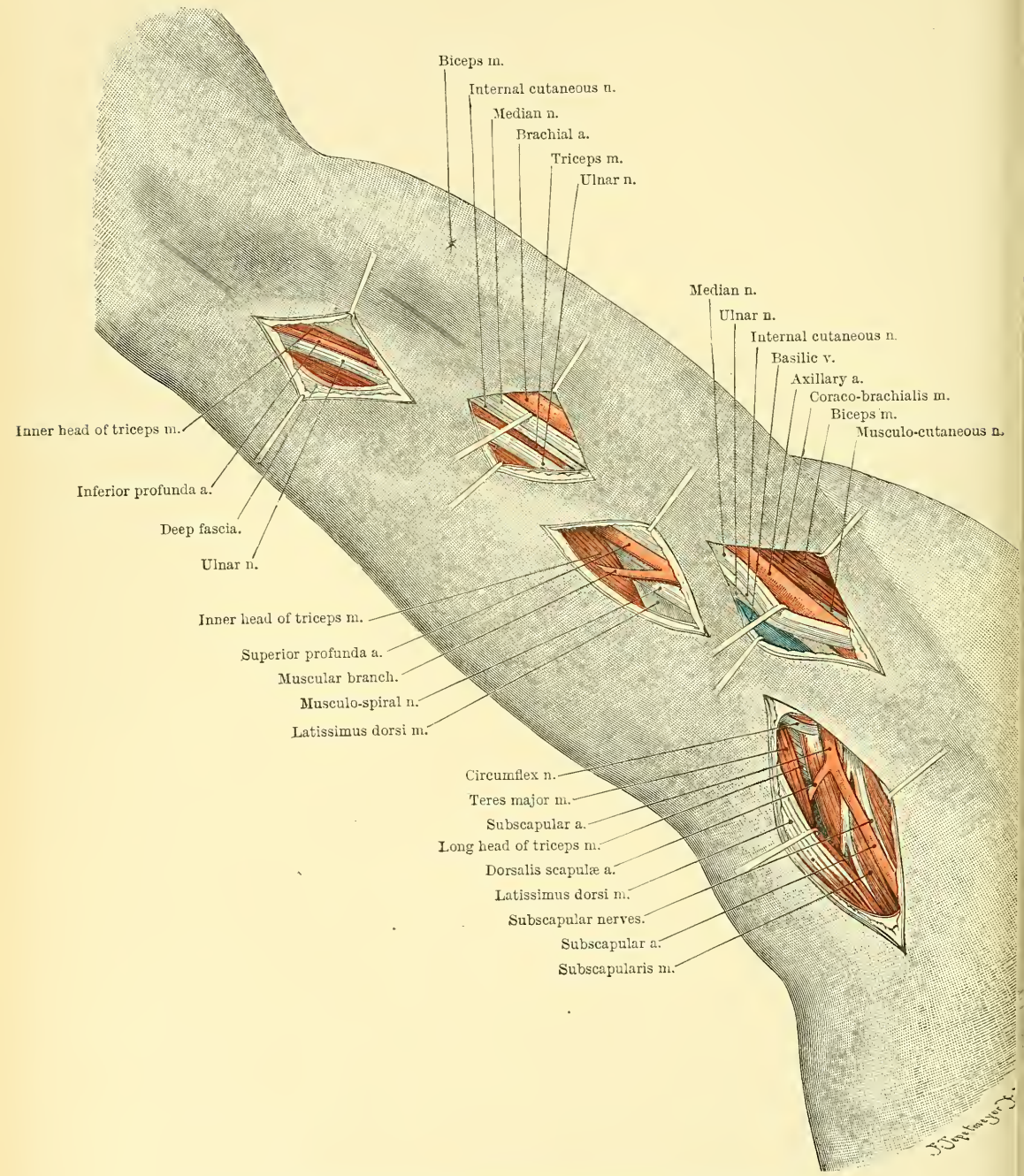

FIG. 44.—Axillary artery, brachial artery, superior profunda artery, subscapular artery, median, subscapular, musculo-spiral, and circumflex nerves.

brachialis muscles which descend under the pectoralis major are exposed and drawn inwards. The artery is seen between the two heads of the biceps, running transversely in some fat immediately below the head of the humerus and above the insertion of the pectoralis major.

29. Ligature of the Posterior Circumflex Artery (Fig. 46). If the posterior border of the deltoid muscle be pressed towards the surgical neck of the humerus, the angle which this muscle forms with the posterior scapular muscles may be distinctly felt. The skin and the fascia (which is adherent to the deltoid) are divided longitudinally over the above-mentioned situation. The posterior border of the deltoid having been exposed and drawn forwards, the lower edge of the teres minor

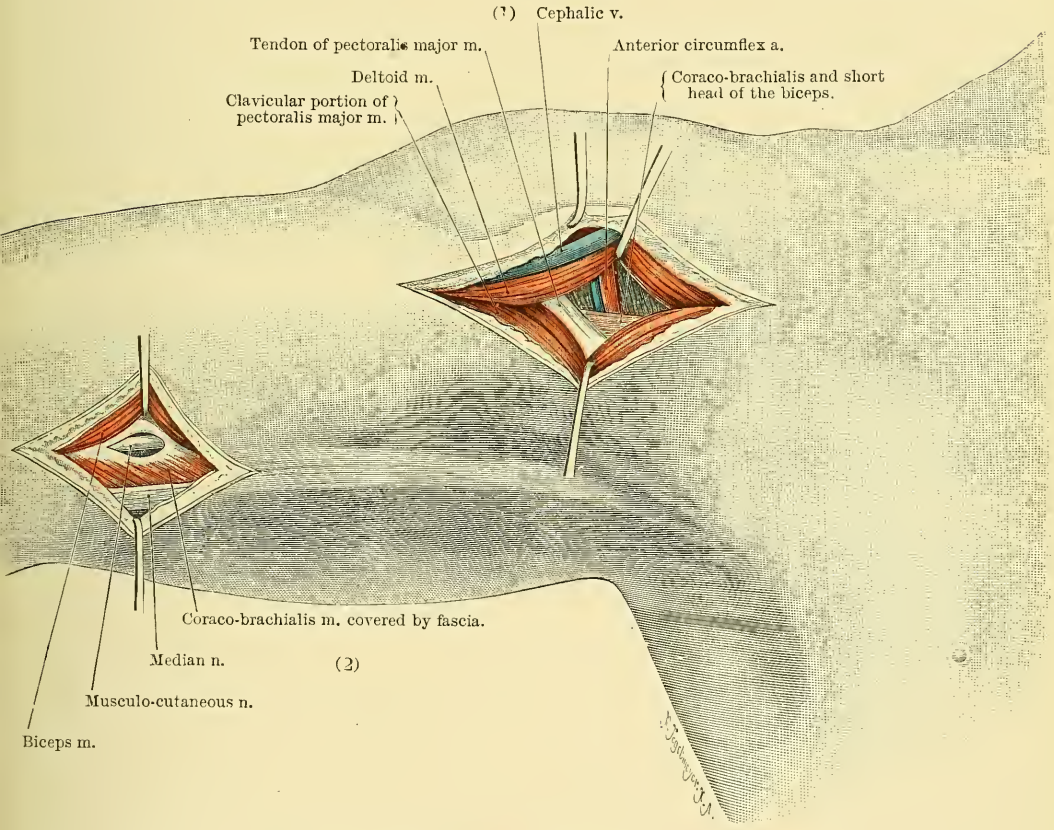

FIG. 45.—(1) Ligature of anterior circumflex artery. (2) Musculo-cutaneous nerve.

and, in front of it, the tendon of the long head of the triceps are brought into view. In the angle between the teres minor and the upper border of the long head of the triceps the posterior circumflex artery, along with the circumflex nerve which is above it, comes out from before backwards. The latter curves round the posterior surface of the humerus in order to enter the under surface of the deltoid, after having given off a branch which runs downwards along its posterior border. Below the nerve the posterior circumflex artery curves forwards out of the interspace between the teres minor above and the teres major below, and divides into ascending and descending branches. The main trunk surrounds the neck of the humerus. Below the posterior circumflex, and separated from it only by the long head of the triceps, the *dorsalis scapulæ artery* will be seen winding round the axillary border of the scapula.

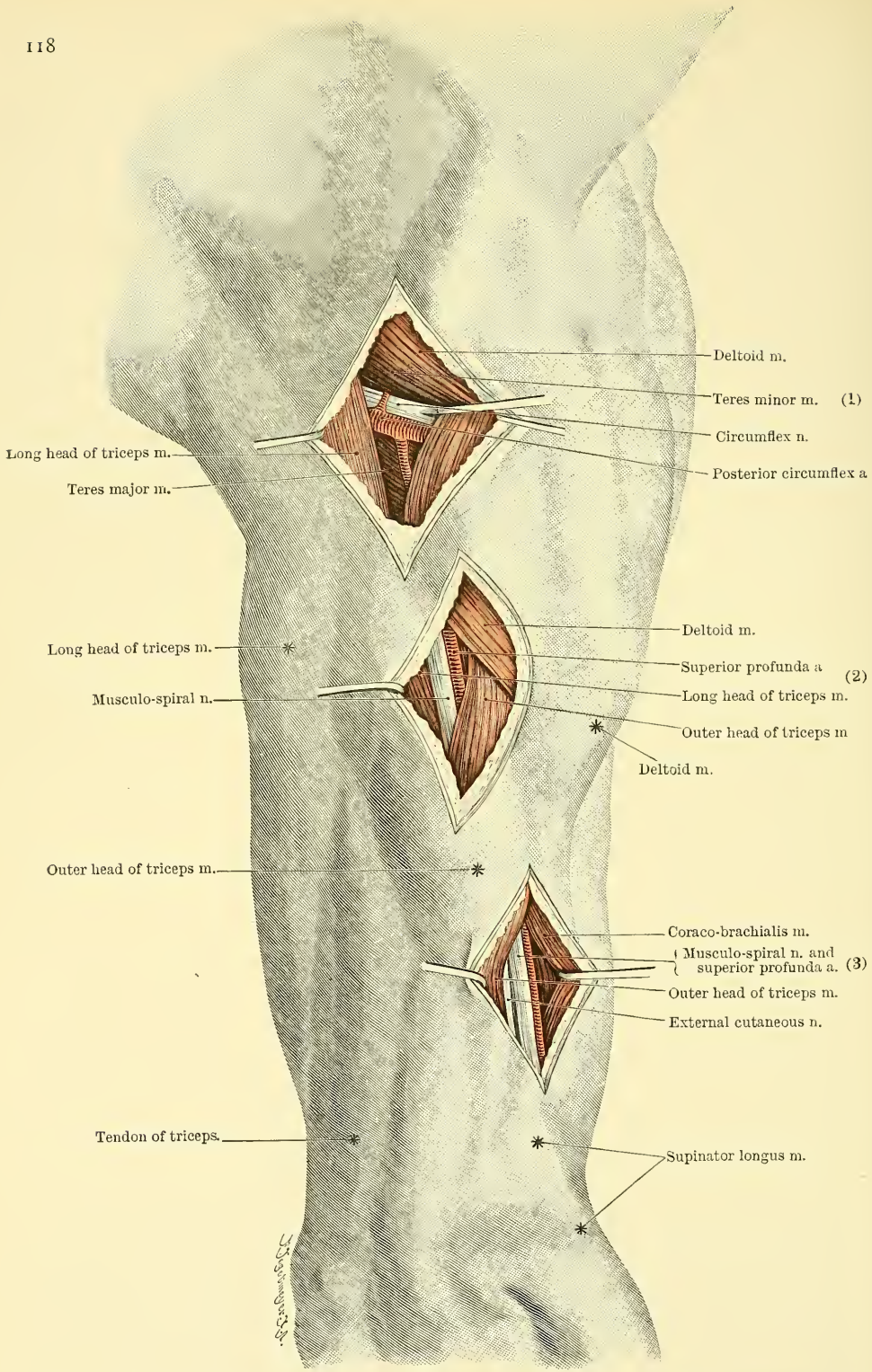

FIG. 46.—(1) Ligature of posterior circumflex artery, circumflex nerve. (2) and (3) Musculo-spiral nerve and superior profunda artery.

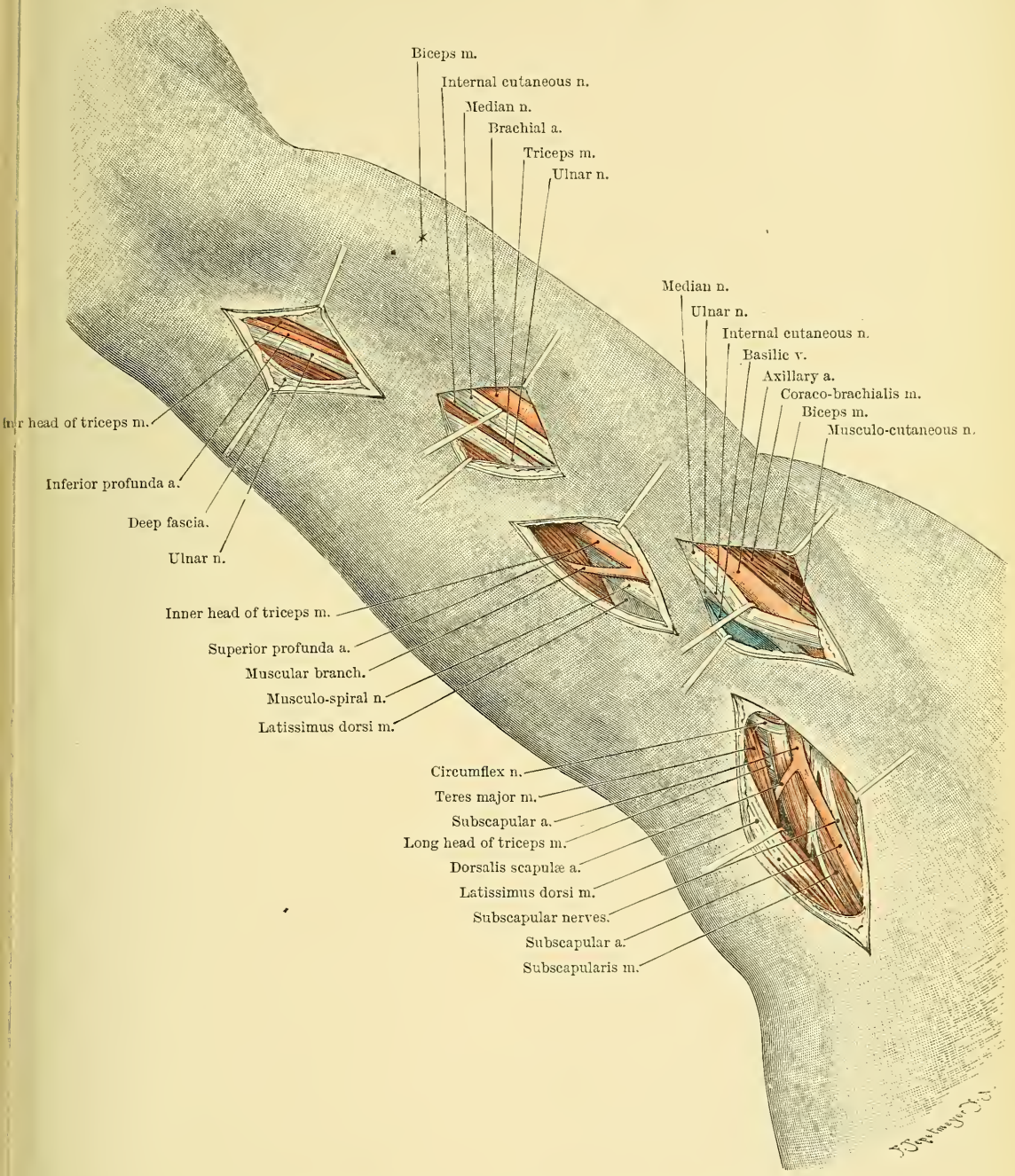

FIG. 47.—Axillary artery, brachial artery, superior profunda artery, subscapular artery, median, subscapular, musculo-spiral, and circumflex nerves.

30. Ligature of the Subscapular Artery and its branches, the Circumflexa scapulæ (Dorsalis scapulæ) and Thoraco-dorsalis (Fig. 44). The limb being fully abducted, an incision beginning at the arm is carried along the anterior surface of the posterior axillary fold. Intercosto-humeral branches going to join the lesser internal cutaneous nerve may appear upon the fascia. After dividing the fascia we find the artery lying in loose cellular tissue at the edge of the insertions of the latissimus dorsi and teres major muscles, which together form the posterior axillary fold. About an inch from its origin it gives off the dorsalis scapulæ artery, which passes backwards. At the upper angle of the incision the circumflex nerve may be seen upon the projection caused by the head of the humerus.

The largest branch of the subscapular artery, the dorsalis scapulæ, reaches the posterior surface of the scapula in company with a branch of the subscapular nerve, by passing backwards in the space between the teres major and latissimus dorsi below, the subscapularis and teres minor above, and the long head of the triceps externally. It can be exposed from behind by the same procedure as described for the posterior circumflex artery (No. 29 and Fig. 46).

The other main branch is the thoraco-dorsalis, the continuation of the trunk in the gap between the latissimus dorsi and the serratus magnus (Fig. 44).

(f) Brachial Artery and its Branches

31. Ligature of the Brachial Artery (Fig. 47). The best landmarks in examining the upper arm are the internal and external bicipital sulci: the biceps and the long head of the triceps can be gripped between the fingers and raised up from the bone.

The brachial artery can be felt in the entire length of the upper arm along the internal bicipital sulcus, from the head of the humerus, which can be palpated through the axilla, down to the middle of the bend of the elbow: the median nerve, which crosses the middle third of the artery from without inwards, can also be felt, while the artery can be compressed in its whole length against the biceps.

(*a*) *In the middle.* An incision is made along the line of the median nerve, which is very distinctly felt in the internal bicipital sulcus when the arm is abducted. Upon the fascia is the slender *lesser internal cutaneous nerve.* The fascia having been divided, the inner border of the biceps is defined and drawn outwards. The median nerve is then completely exposed, freed, and drawn inwards. Immediately under it is the brachial artery (with its two venæ comites) lying in front of the intermuscular septum. Internal to it is the internal cutaneous nerve. The ulnar nerve lies under the fascia covering the inner head of the triceps at the hinder part of the internal bicipital sulcus.

Below the middle of the upper arm the *basilic vein* and the *internal cutaneous nerve* will be seen at the place where they pierce the fascia. They may be exposed by the same incision as for ligature of the brachial artery.

(*b*) *At the elbow.* We make an incision in the direction of the axis of the forearm, beginning internal to the biceps tendon a little to the ulnar side of a point midway between the condyles of the humerus. The oblique median basilic vein and the main branches of the internal cutaneous nerve are seen lying upon the fascia. Under the superficial fascia is the aponeurotic bicipital fascia, the fibres of which run in a characteristic manner downwards and inwards. Immediately under it, or covered by a thin layer of fat, lies the brachial artery, with its two venæ comites. Externally is the biceps tendon. The division of the brachial artery into radial and ulnar takes place a finger's breadth below the level of the joint.

32. Ligature of the Arteria collateralis radialis superior. Ligature of this artery is performed only in the case of injury and then at its site.

33. Ligature of the Arteria profunda brachii (Superior profunda) (Figs. 44 and 46). (*a*) *Upon the inner aspect of the arm in its upper third—at the lower border of the latissimus dorsi muscle* (Fig. 44). An incision commencing at the level of the

posterior axillary fold is carried downwards along the internal bicipital sulcus. The lesser internal cutaneous nerve is met with upon the fascia. The fascia is divided over the prominence of the long head of the triceps behind the white line of the internal intermuscular septum, and the dissection is continued towards the bone upon the anterior surface of the long head and above the origin of the inner head of the triceps. By following up the large branch to the inner head of the triceps, we meet with the trunk of the superior profunda artery lying against the bone.

Behind the artery lies the musculo-spiral nerve, which descends from above over the tendon of the latissimus and passes towards the posterior surface of the humerus between the inner and the long heads of the triceps. An operator must be careful not to go too far backwards, as otherwise he would pass behind the nerve and artery which are situated close to the bone in the internal bicipital groove. The musculo-spiral nerve is identified by its resting upon the latissimus.

(*b*) *Above the middle of the posterior surface* (Fig. 46). As a guide to the incision, a line is drawn along the posterior surface of the upper arm from a point a finger's-breadth behind the posterior border of the deltoid and close to the long head of the triceps down to the tip of the olecranon. The incision begins below the level of the posterior axillary fold, and passes downwards along this line in the interval between the long and outer heads of the triceps, which are separated from one another down to the bone. The nerve lies between the inner and outer heads of the triceps after having passed under the long head at the lower border of the latissimus dorsi. Parallel to and in front of the nerve lies the superior profunda artery, which is also in contact with the inner surface of the humerus.

(*c*) *Upon the outer aspect of the upper arm in the lower third* (Fig. 46). An incision is made at the outer border of the outer head of the triceps (the limits of which can easily be made out by grasping it from behind), extending vertically upwards from the external condyle of the humerus to a point midway between it and the insertion of the deltoid. The muscular fibres of the triceps are exposed by continuing the dissection along the external intermuscular septum, and separating the brachialis anticus muscle from it as far as the bone. The artery passes obliquely from behind forwards, accompanied by the musculo-spiral nerve, which lies close to the bone.

34. Ligature of the Arteria collateralis media (branch to Inner Head of Triceps). This vessel, which runs in the fibres of the inner head of the triceps, is ligatured only in wounds incurred by the latter muscle.

35. Ligature of the Arteria collateralis radialis inferior. This is the terminal branch of the superior profunda, lying behind the external intermuscular septum, and found in the lower third of the arm at the lateral border of the outer head of the triceps. The posterior interosseous nerve is closely associated with it.

36. Ligature of the Arteria collateralis ulnaris superior (Inferior profunda Artery) (Figs. 47 and 44). This artery accompanies the ulnar nerve. In the *upper third* of the arm it lies along with the nerve posterior to the large vessels, and is to be ligatured by the same incision as for the brachial artery, with this difference, that the median nerve is drawn outwards, and one passes internal and posterior to the main vessels.

From the middle of the arm downwards the artery lies behind the internal intermuscular septum. The incision (Fig. 44) is the same as for exposure of the ulnar nerve, the fascia being divided behind the intermuscular septum. The artery lies beside the nerve upon the muscular fibres of the inner head of the triceps.

At its *lower end* the artery can be felt upon the posterior surface of the internal epicondyle, and is to be looked for accompanying the ulnar nerve behind the internal intermuscular septum.

37. Ligature of the Arteria collateralis ulnaris inferior (Anastomotic Artery). The artery lies upon the base of the internal epicondyle above the origin of the pronator radii teres. It can be felt there. It is found after dividing the strong fascia upon which lie the anterior branch of the internal cutaneous nerve and the junction of the median basilic with the basilic vein.

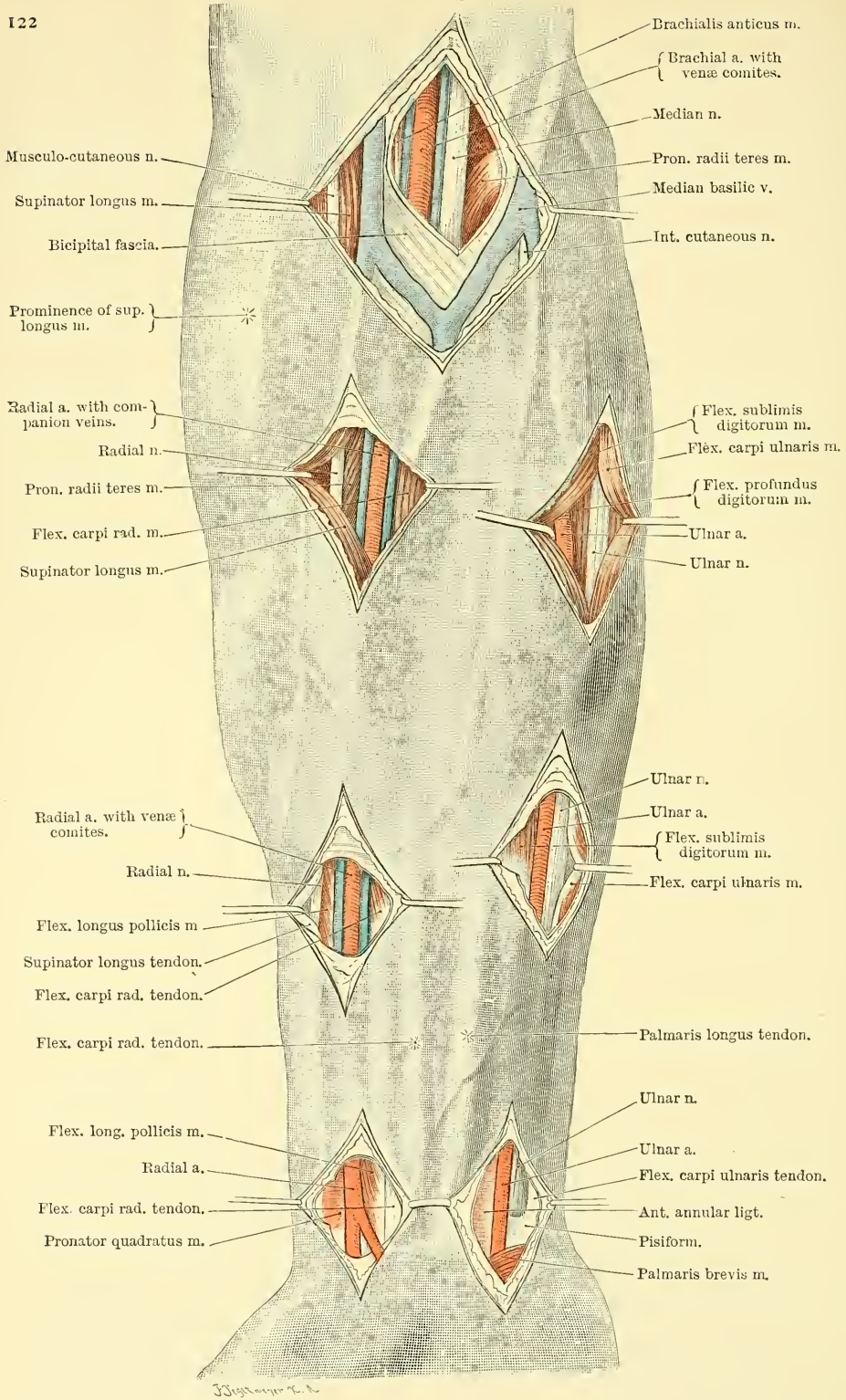

FIG. 48.—Brachial artery. Radial and ulnar arteries.

(g) Arteries on the Forearm and the Hand

38. Ligature of the Radial Artery (Figs. 48 and 49). This vessel, the direct continuation of the brachial artery, is easily felt in two-thirds of its length. It is nowhere covered by muscles, except in the upper third, where it is slightly overlapped by the supinator longus muscle. The direction of the artery is indicated by a line from the middle of the bend of the elbow, down the front of the forearm, and along the "pulse" to the ridge on the trapezium.

(*a*) *In the upper third* the artery lies more deeply upon the supinator brevis and the pronator teres, between the projecting supinator longus and the flexor carpi radialis muscles. An incision is made along the interval which may be distinctly felt between the two latter muscles. The median cephalic vein and a large branch of the musculo-cutaneous nerve appear upon the fascia. The fascia is divided, and the supinator longus muscle is drawn well outwards. The artery is found lying deeply upon the insertion of the pronator radii teres. To the radial side of the artery, and at some distance from it, is the radical nerve covered by the supinator longus.

(*b*) *In the middle third.* Incision in the interval (in which the radius may be felt) between the flexor carpi radialis and supinator longus muscles. In this interval the artery lies upon the radial origins of the flexor longus pollicis and flexor sublimis digitorum muscles. The *radial nerve* lies at a little distance to its radial side, more under cover of the supinator longus, beneath which it passes backwards.

(*c*) *Above the wrist.* The hand being dorsiflexed, an incision is made between the prominent tendon of the flexor carpi radialis and the edge of the radius. The skin and fascia are divided. At the lower border of the pronator quadratus the artery passes deeply towards the radial aspect of the wrist-joint, and sends merely the small superficial volar branch downwards to the palm over the ridge on the trapezium. The tendons of the extensor ossis metacarpi and extensor primi internodii pollicis lie enveloped in their sheath external to the artery at the edge of the radius. The radial nerve is no longer to be seen, as it passes backwards under the tendon of the supinator longus at the lower third of the forearm.

(*d*) *On the back of the wrist* (*in the so-called Tabatiere*) (Fig. 49). Longitudinal incision from the lower end of the radius to the base of the first metacarpal bone between the prominent tendons of the extensor primi and extensor secundi internodii pollicis. The vessel can here be felt through the skin. In the subcutaneous tissue parallel to the tendon are the radial vein and nerve, which are to be avoided: the latter can be felt upon the outer side of the radius. The artery courses obliquely beneath the above-mentioned structures upon the scaphoid and external lateral ligament.

(*e*) *On the back of the hand* (Fig. 49). This vessel goes to form the main part of the deep palmar arch.

Incision from the upper end of the first interosseous space along the ulnar side of the tendon of the extensor secundi internodii pollicis. The vessel can be felt here. The branches of the radial nerve and vein which lie upon the fascia are to be avoided. The dissection is continued between the bases of the first and second metacarpal bones, upon which the artery lies just before it passes towards the palm, under the tendinous arch joining the two heads of origin of the first dorsal interosseous muscle. The broad tendon of the extensor carpi radialis longior, which is inserted into the second metacarpal bone, appears upon the ulnar side. The artery has previously given off the common digital branch for the forefinger and thumb, which may readily be mistaken for the main trunk.

The radial recurrent, posterior radial carpal, and superficial volar, branches of the radial artery, are only ligatured in the case of injury. The superficial volar is a small twig which assists in forming the superficial palmar arch (*q.v.*), and runs downwards under the delicate fascia of the muscles of the thenar eminence.

39. Ligature of the Ulnar Artery (Fig. 48). The ulnar artery can be felt in the lower third, being for the most part uncovered by muscles. After arising at an angle from the brachial artery, it passes between the flexor sublimis and flexor profundus

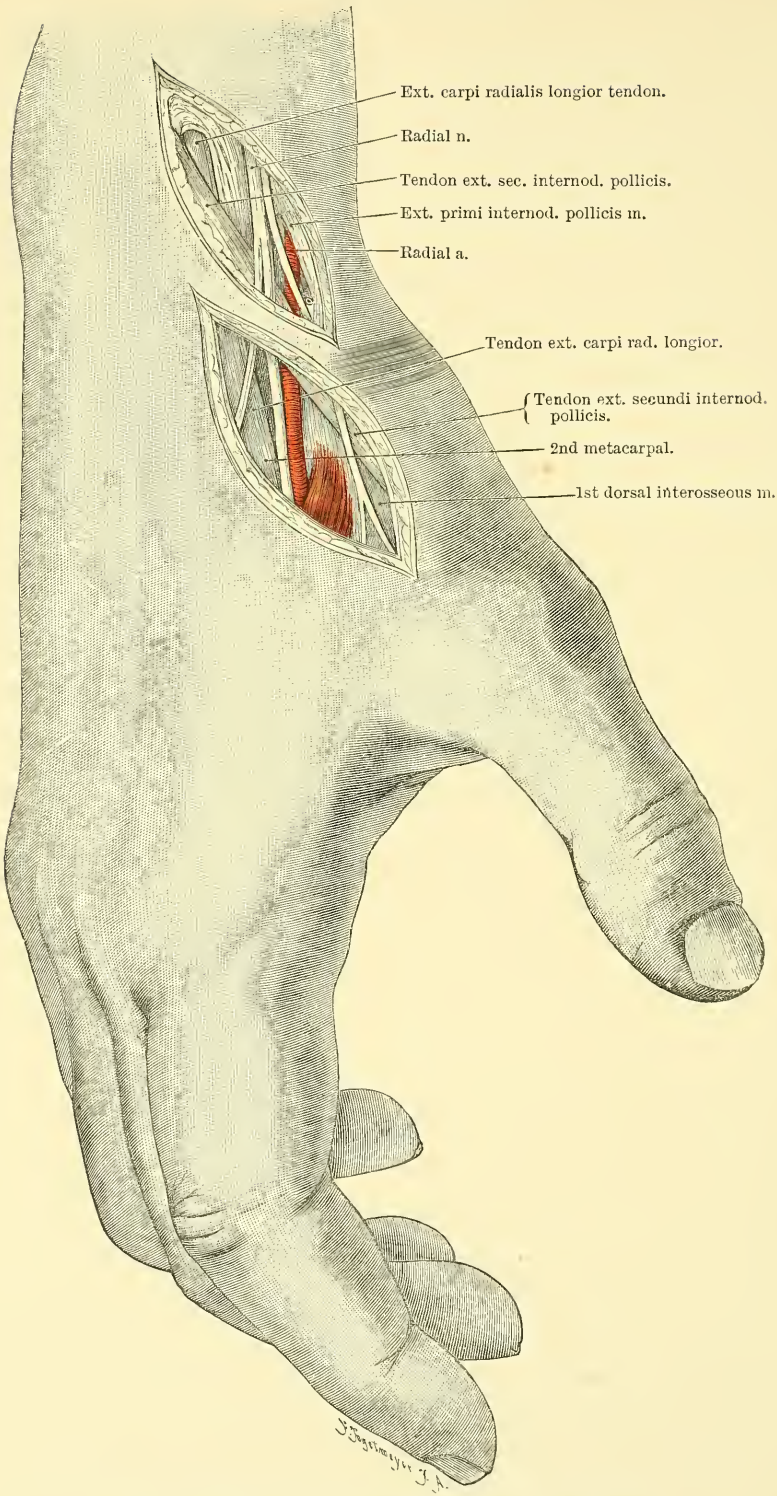

FIG. 49.—Radial artery on the back of the wrist. Radial nerve.

digitorum muscles. Incisions for ligaturing the artery are made along a line extending from the internal condyle for the humerus to the projection of the pisiform bone. This line does not correspond to the course of the artery, which in its upper part lies much more towards the middle line. To ligature it at its origin, the directions already given for ligature of the brachial at the bend of the elbow suffice, except that the incision is prolonged somewhat more downwards.

In the upper half. With the arm held abducted, an incision is made in a line descending vertically from the posterior edge of the internal epicondyle of the humerus. The incision must not be begun higher than four finger-breadths below the epicondyle (*i.e.* at the junction of the upper and middle thirds of the forearm), and must not fall in front of the above line: it strikes the radial edge of the flexor carpi ulnaris, which is indicated by a distinct intermuscular septum. Occasionally the ulnar nerve can be felt through the skin. After division of the skin, the anterior ulnar vein along with a branch of the internal cutaneous nerve comes into view. In the fascia is the intermuscular septum between the flexor carpi ulnaris and the subjacent flexor sublimis, indicated by a distinct white line. The fascia having been divided along this line, the finger is passed deeply at the outer border of the flexor carpi ulnaris and somewhat outwards upon the anterior surface of the flexor profundus digitorum, the flexor sublimis being drawn aside. If the right intermuscular space has been struck, the ulnar nerve will first be met with. By passing external and somewhat anterior to the nerve, we find the artery lying $\frac{1}{2}$ to $1\frac{1}{2}$ cm. (according to the height) to its outer side. Higher up, the artery is still further external to the nerve.

In the lower half. An incision is made down to the flexor sublimis in the interval between the flexor carpi ulnaris and the palmaris longus. This interval is definitely marked out by projecting a line vertically upwards from the radial border of the pisiform bone. After the skin and fascia have been divided the dissection is carried down upon the flexor sublimis and *not under* the flexor carpi ulnaris. The artery lies between two venæ comites. The ulnar nerve is close to its ulnar side.

40. Ligature of Common Interosseous Artery (Fig. 50). This branch of the ulnar artery may be exposed by the same incision as that for the ulnar artery in its upper third (Fig. 48), by passing down upon the flexor profundus digitorum until the median nerve with its branches is met with. The interosseous artery passes under the nerve towards the interosseous membrane between the flexor profundus digitorum and the flexor longus pollicis. The interosseous branch of the median nerve lies upon the artery. The interosseous artery may also be exposed by the same incision as that for the median nerve in the upper third. The ulnar artery here lies deeply towards the supinator brevis and above the tendinous arch of the flexor sublimis digitorum, beneath which, close to the radius, the interosseous artery is given off.

Of the other branches of the ulnar artery, ligature of both the ulnar recurrent arteries at the elbow, or of the anterior or posterior ulnar carpals at the wrist, need no special consideration. For ligature of the profunda branch of the ulnar, which helps to complete the deep palmar arch, see No. 42.

41. Ligature of Superficial Palmar Arch (Fig. 51). Longitudinal incision from the junction of the thenar eminence towards the ring finger, the middle of the incision being opposite a line drawn across the palm at the level of the web of the abducted thumb. The superficial arch may be felt pulsating at the point where these two lines intersect. After division of the skin, the superficial fascia (which is often of considerable thickness), and the strong aponeurotic palmar fascia, the arch is at once exposed embedded in fat beneath the smooth under-surface of the latter. The arch is the continuation of the ulnar artery, and at this point it curves outwards towards the thumb. Passing downwards from the arch are the common digital arteries. The arch lies upon the digital branches of the median and ulnar nerves, the latter being exposed. If the artery cannot be found here, the ulnar artery may be ligatured at the pisiform bone.

The *ulnar nerve* may be exposed by a similar incision. Its superficial division

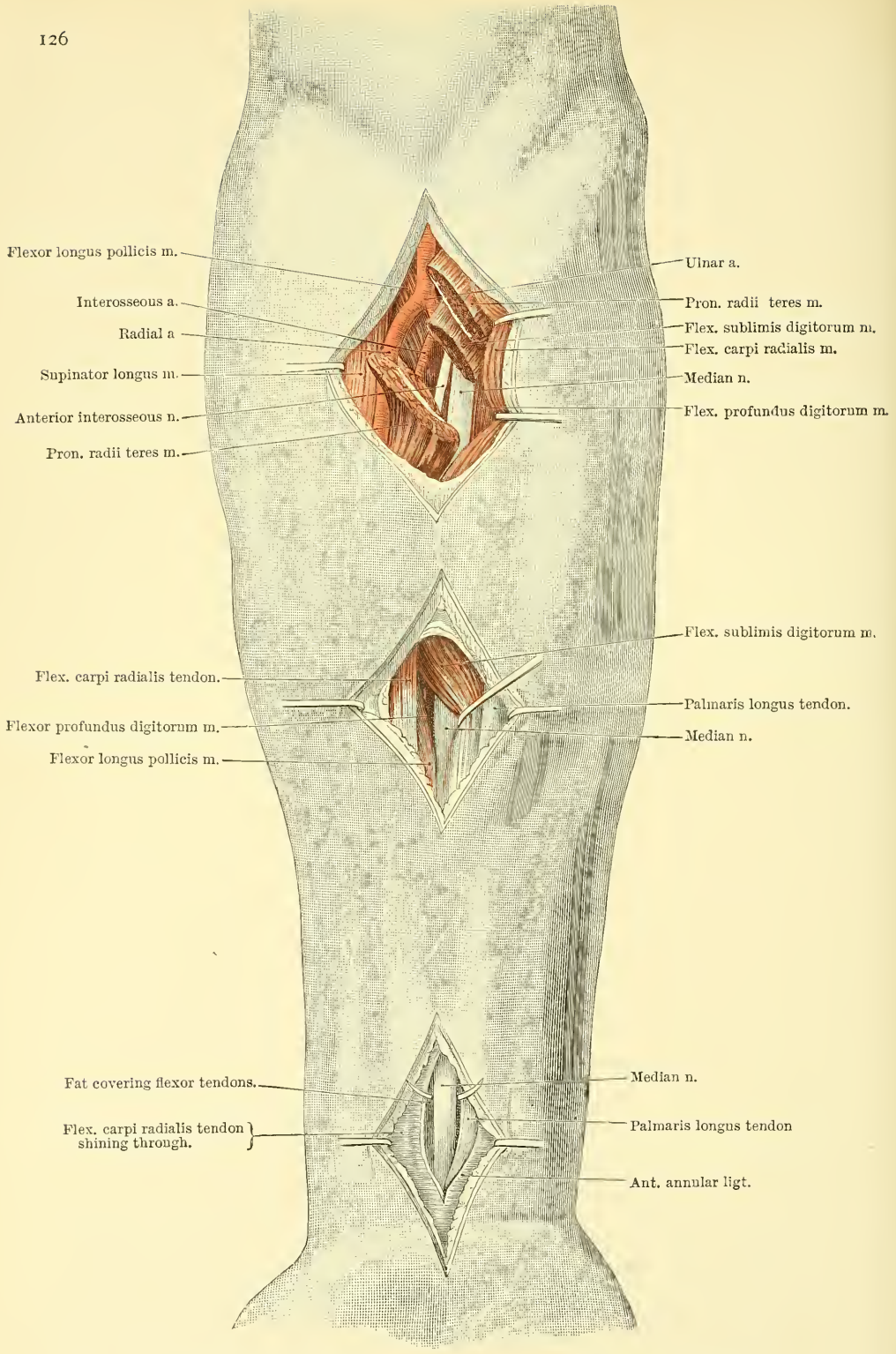

FIG. 50.—Median nerve, anterior interosseous nerve, interosseous artery.

descends over the hook of the unciform bone, which can be felt through the skin. The deep division passes between the abductor and flexor brevis minimi digiti at the ulnar side of the hook of the unciform, and supplies the flexor brevis and opponens minimi digiti, the two inner lumbricals, and all the interossei, together with the adductor pollicis.

42. Ligature of the Deep Palmar Arch (Fig. 51). In the contrast with the superficial arch, the deep arch is formed mainly by the radial artery. It gives off large branches to the radial side of the hand, whilst its interosseous branches are small. It does not reach so far downwards as the superficial arch. To expose it, an incision is made from the junction of the two thenar eminences along the opponens crease towards the index finger, the middle of the incision corresponding to the middle of the ball of the thumb. After division of the skin and palmar fascia the superficial arch is ligatured. The superficial muscular layer of the thumb (opponens pollicis) is ligatured, and, together with the anterior annular ligament, is slightly incised at the upper end of the wound. At a deeper plane is the slender first lumbrical muscle with the white flexor tendon of the index finger to its ulnar side. The dissection is continued along the radial side of the lumbrical between it and the thumb muscles. By retracting the muscles of the thenar eminence upwards, together with the branch of the median nerve supplying the muscles, and the adductor transversus pollicis downwards, we find the artery lying between the bases of the first and second metacarpals running transversely on the deep fascia covering the bones and the interossei muscles.

43. Ligature of the Digital Arteries in the Palm and of the Collateral Digital Arteries. The large digital branches of the superficial palmar arch are ligatured through an incision in the palmar fascia, similar to that for ligature of the superficial palmar arch.

The collateral digital arteries, which can easily be felt, may be tied on either side of the palmar aspect of each proximal phalanx, being distributed to the middle and distal phalanges.

The metacarpal arteries from the deep palmar arch, the dorsal interosseous branches from the carpal arch, and the small dorsal digital branches to the proximal phalanx are only ligatured in cases of wounds inflicted on the palm.

(h) Branches of the Thoracic Aorta

44. Ligature of the Intercostal Arteries (Fig. 52). Of the intercostal branches of the descending thoracic aorta, which extends from the fourth to the twelfth dorsal vertebra, only those from the third to the eleventh need be taken into consideration. In exposing the bodies of the vertebræ (costo-transversotomy) we have to ligature them near their point of origin, where they lie under cover of the lower margin of the head of the rib.

The anterior division of the intercostal artery, which is closely applied to the lower border of the rib, is the one most commonly ligatured. Primarily it lies on the pleura, but it is not generally long in insinuating itself below the internal intercostal muscles.

The chief branch of this artery runs between the two intercostal muscles at the lower border of the rib, a smaller branch running along the upper border of the subjacent rib. The artery is not easily ligatured, because it lies hidden under the overhanging lower margin of the rib. The oblique fibres of the external intercostal muscle are divided close to the rib and drawn downwards. The nerve, and with it the artery, can now be drawn down out of the groove of the rib, when an aneurysm needle is carefully passed round the artery. To secure the vessel with greater safety a piece of the overlying rib may be resected subperiosteally.

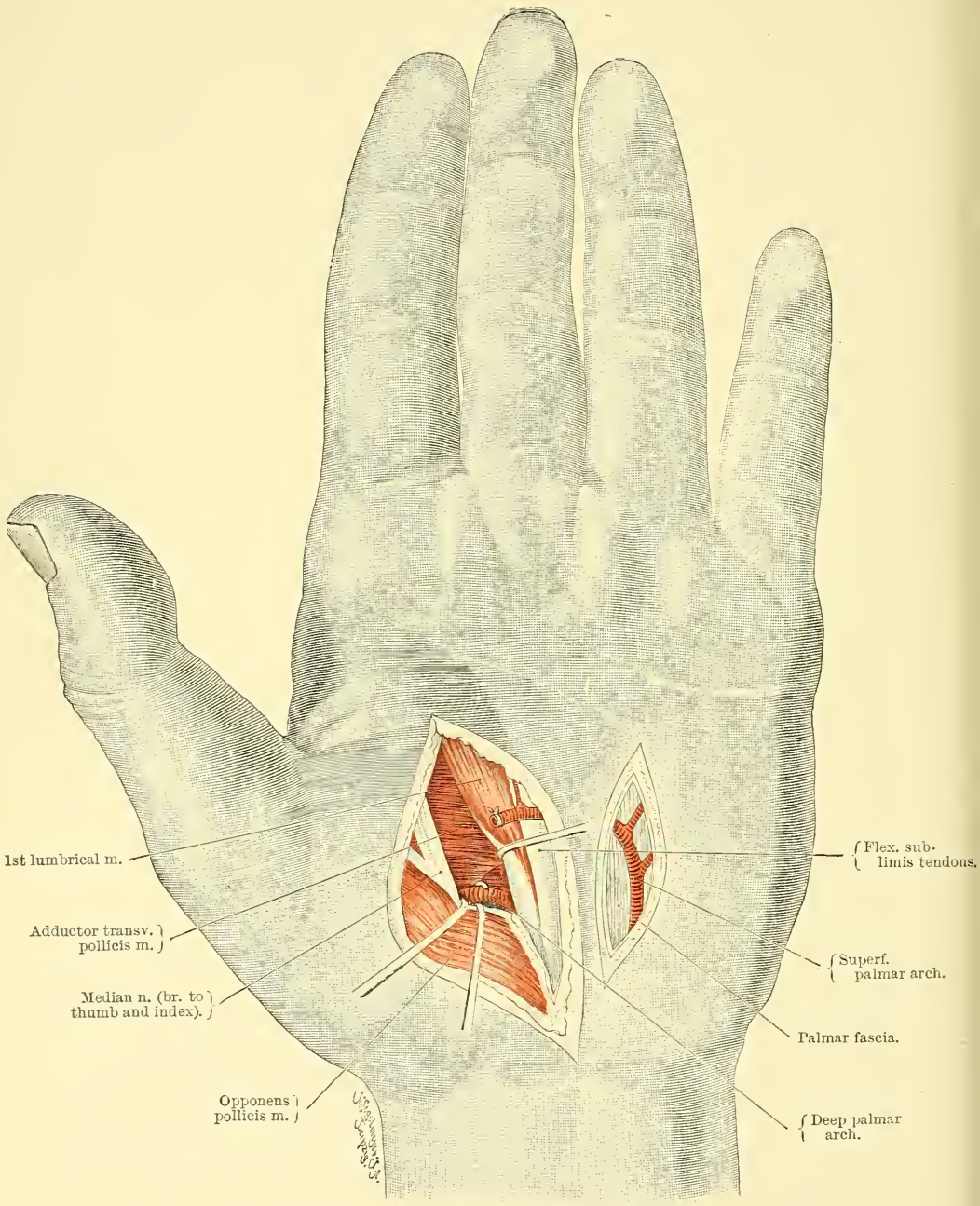

FIG. 51.—Ligature of the superficial and deep palmar arches. The stump of the superficial arch is represented as lying directly on the flexor sublimis, whereas the palmar fascia really intervenes.

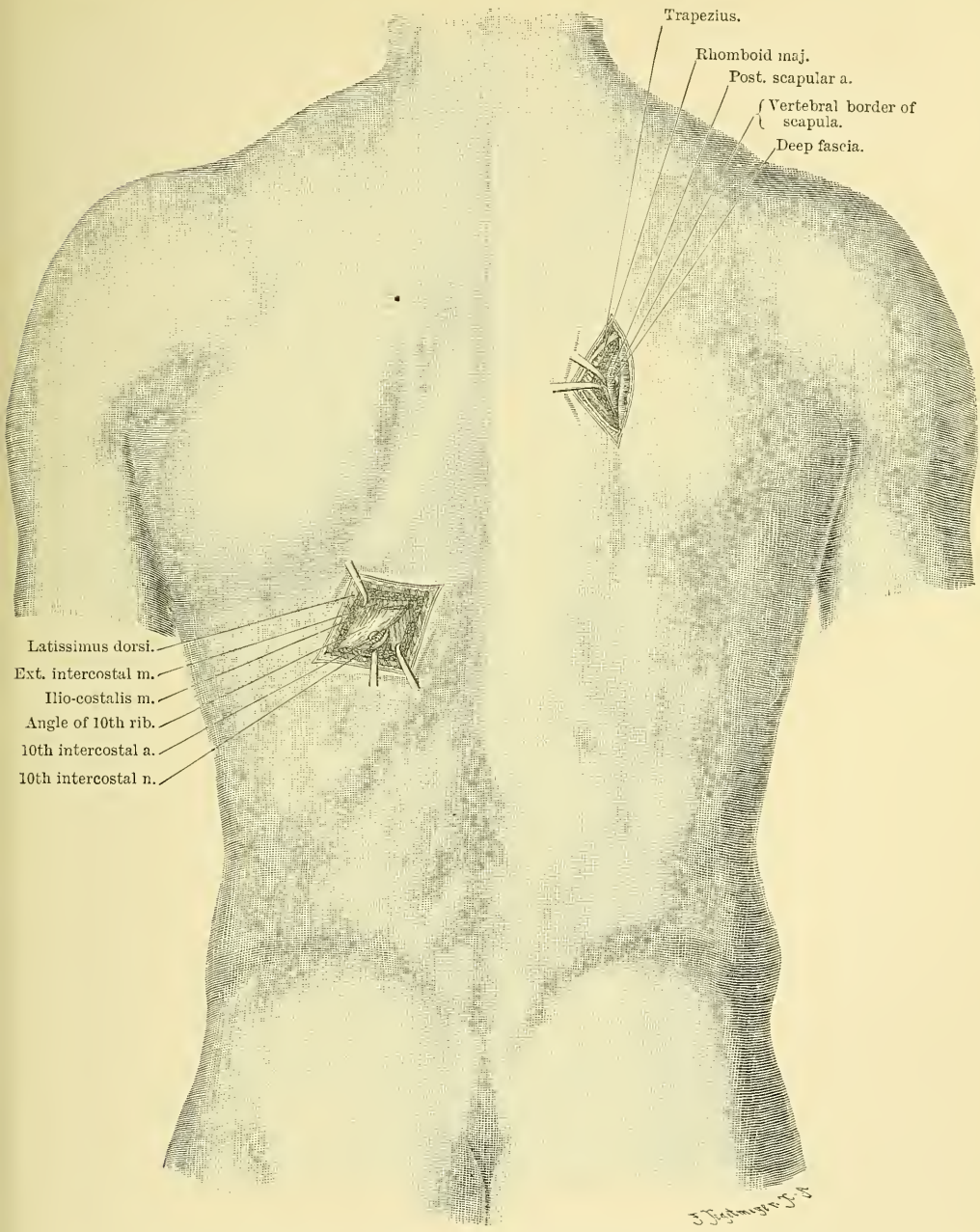

FIG. 52.—Exposure of the 10th rib and the 10th intercostal artery and nerve. Ligature of the posterior scapular artery.

(i) Branches of the Abdominal Aorta

Ligature of the abdominal aorta has already been considered (see p. 92).

45. Of the **Parietal Branches** of the abdominal aorta, the phrenic arteries which are distributed on the under surface of the diaphragm need not be considered. The

middle sacral artery, which is the terminal branch of the aorta, is ligatured in detaching the soft parts from the coccyx and sacrum, *e.g.* in excision of the rectum.

The large lumbar arteries, which are overlapped at their origin by the crura of the diaphragm and the ilio-psoas muscle, are distributed to the abdominal walls. Their position makes it impossible to ligature them without inflicting extensive injury on the surrounding parts.

Of the visceral branches of the abdominal aorta,

46. The Cœliac Axis, which arises above the pancreas, cannot be ligatured on account of the importance of its branches. Likewise, ligature of the hepatic artery, a branch of the cœliac axis which has occasionally suffered injury in the excision of a carcinoma of the stomach, proves fatal within a few days as the result of sudden interference with the function of the liver. Extreme care must therefore be exercised to avoid injury to the hepato-duodenal ligament in which it lies to the left of the common bile duct and the portal vein. According to Haberer,[1] the hepatic artery may be ligatured at a point immediately before its division into the right and left hepatics (Art. hepat. communis), and also before it gives off the pyloric artery, beyond which point ligature is impossible.

But, if we may judge by the results of pylorectomy, the main branch of the hepatic artery (viz. the gastro-duodenal) as well as its two branches, the superior pancreatico-duodenal and the right gastro-epiploic arteries, may be ligatured without hesitation.

The pyloric branch may also be ligatured, even if the gastro-duodenal has been divided (according to Fricker's experiments, see note under 47).

After ligature of the superior pancreatico-duodenal a sufficient blood-supply is provided by the inferior pancreatico-duodenal branch of the superior mesenteric (Fricker).

47. Ligature of the Coronary Artery. Like the pyloric branch of the hepatic, the coronary artery can be ligatured without endangering the blood-supply of the stomach. It may be excised in its entire length (as is often effected in cases of carcinoma of the stomach) in removing a chain of malignant glands along the lesser curvature. The corresponding veins can be equally well ligatured, as the anastomosis between the vessels on the greater and lesser curvatures is very rich. The vessels are found along the lesser curvature between the layers of the small omentum.

Simultaneous ligature of the coronary and left gastro-epiploic may be followed by serious results, although Dr. Fricker has shown experimentally that the gastro-duodenal or the right gastro-epiploic may be ligatured at the same time as the pyloric artery without injurious effects, as a sufficient blood-supply is provided by the vessels running from left to right (*vide* No. 48).

48. Ligature of the Splenic Artery. This artery, the largest branch of the cœliac axis, is ligatured in the case of injury either of the spleen or of the trunk of the vessel, the most important indication being in cases where a deep gastric ulcer has eroded the artery and caused serious hæmorrhage.

The same applies to its branch, the left gastro-epiploic artery, as well as to the other vessels already mentioned, the right and left coronary arteries, the right gastro-epiploic and also the gastro-duodenal. The splenic artery runs transversely outwards behind the stomach along the upper border of the pancreas.

49. Provisional and Permanent Ligature of the Arteries of the Stomach, Pancreas, and Duodenum. Although this subject is considered in connection with resection of the stomach, attention must be called to the interesting researches undertaken by Fricker[2] at our suggestion, as they show how the circulation can be fully maintained along the greater and lesser curvatures by the arteries on the left side, after ligature of the coronary and gastro-duodenal arteries.

Fricker's experiments were conducted on dogs, in which the conditions are precisely similar to those in man. His observations have proved that, owing to the complete restoration of circulation, the numerous adhesions otherwise so frequently observed after operation are found to be absent, a point to which we shall return in discussing resection of the stomach.

[1] *Arch. f. klin. Chir.* Bd. 78.

[2] *Inaug. Dissert.*, Bern., 1902.

A loop of intestine and a large part of the stomach can be kept free of blood for one to one-and-a-quarter hours by means of clamps (like Doyen's in the form which we have modified), without any permanent disturbance of the circulation resulting in the case of dogs.

50. Ligature of the Superior Mesenteric Artery. Ligature of this vessel, the main artery of the small and large intestine, is not to be attempted. The artery enters the root of the mesentery below the pancreas, a point to which we call attention, as a large branch of the artery may be injured during the excision of a tumour which is adherent to the intestine or mesentery. In the event of this accident occurring, it is necessary to ascertain the vessels in the region of the mesenteric attachment to the intestine in which pulsation has disappeared, for the whole portion of intestine affected must at once be resected.

In the small intestine the rami intestini tenuis are more closely related to one another near the gut than are the main branches for the large intestine (ileo-colic, right and middle colic arteries), which are widely separated and only communicate through numerous arterial arches. In the case of the large intestine, therefore, one main trunk cannot replace another, and experience has shown that in lesions, especially of the middle colic, the left colic (branch of the inferior mesenteric) is not sufficient to maintain the nutrition of the transverse colon. It should be made an absolute rule, therefore (*vide* Resection of the Stomach), in all injuries of the colic arteries, or in operations necessitating resection of the transverse colon, to remove every portion of the bowel in the mesentery of which pulsation cannot be felt.

A further important indication for exposing the superior or inferior mesenteric arteries is to be found in thrombosis or embolism of the mesenteric vessels.

The symptoms of this condition[1] are very characteristic, comprising sudden acute colic, vomiting, and severe bleeding from the stomach and intestine, with the early signs of peritonitis.

Jackson, Porter, and Quinby[2] have collected 214 cases of embolism and thrombosis of the mesenteric vessels. The treatment consists in immediate resection of the gangrenous portion of gut.

51. Ligature of the Inferior Mesenteric Artery. Although this artery originates at a lower level than the renal and spermatic arteries we shall now give it consideration, because what has been said regarding ligature of the superior mesenteric and its branches applies equally to the ligature of the inferior mesenteric artery. It is not advisable to ligature the trunk of the vessel or its main branch, the left colic, although ligature of one of the sigmoid arteries is a less serious operation, for the reason that the latter are more numerous.

It is doubtful whether the terminal branch, the superior hæmorrhoidal artery, can be ligatured with impunity, as the descriptions given by Rehn and others of amputation of the rectum would lead us to believe. It is, of course, tied in a complete extirpation of the rectum, in which case, however, a preliminary ligature is of the greatest advantage. But it is very doubtful to what extent the branches of the hypogastric, more especially the middle hæmorrhoidal, can be relied on to maintain the circulation.

On the other hand, no risk is incurred in ligaturing one of the two branches of the superior hæmorrhoidal artery which descend close together behind the rectum, as there is an ample cross anastomosis between the two vessels.

52. Ligature of the Renal Artery. Despite the importance of the suprarenal glands, ligature of the suprarenal arteries is only undertaken in the course of other operative procedures.

Ligature of one renal artery is undertaken in excision of the kidney, the temporary application of a clamp being an effective measure in preventing loss of blood during a partial excision of the kidney, and especially in splitting the renal pelvis.

Ligature of the renal vessels has recently been recommended by Major Holt in the treatment of long-standing renal fistulæ.

[1] Cf. four observations by Körte published by Falkenberg in Langenbeck's *Archiv*, Bd. 70.

[2] *Journal of Amer. Med. Assoc.*, June 1904.

53. Ligature of the Internal Spermatic Arteries (cf. also No. 54 and Fig. 53). Ligature of these long delicate arteries running from the aorta in front of the second lumbar vertebra to the testicle is of little surgical importance. Instead of ligaturing them near the seat of their origin, a simpler method is to operate close to the testicle or to the ovary in the female.

The artery is reached by exposing the spermatic cord through our inguinal excision, and dividing the aponeurosis of the external oblique muscle over the inguinal canal. Apart from injuries, the chief indication for ligaturing the artery is to produce atrophy of the testicle and epididymis, in which case it is generally included in the whole bundle of vessels, *i.e.* spermatic veins and the artery to the vas.

The ovarian artery is ligatured along with the uterine, so as to control the hæmorrhage associated with a complete hysterectomy.

(k) Common Iliac Artery and its Branches

54. Ligature of the Common Iliac Artery[1] (Fig. 53). The common iliac artery commences at the bifurcation of the aorta opposite the fourth lumbar vertebra at the level of the umbilicus, where it lies on the inner border of the psoas. The common iliac veins are situated behind the right common iliac artery, the left vein occupying a higher and the right vein a lower level. The ureter, and, on the right side, the superior hæmorrhoidal artery (from the inferior mesenteric) cross it in front.

Ligature of the common iliac is only indicated in conditions of severe injury, for unless the collateral circulation is satisfactory, gangrene supervenes in nearly half the cases. Ligature of this artery is a necessary preliminary to interilio-abdominal disarticulation. Temporary ligature (first attempted by Travers and performed several times by Schönborn) or temporary compression (which, according to Madelung and McBurney, is best accomplished intra-peritoneally)[2] are preferable methods of operation.

An oblique incision is made, parallel to and three fingers'-breadth above Poupart's ligament, dividing skin and superficial fascia, the superficial epigastric artery being ligatured. The aponeurosis, and in the outer part of the incision the muscular fibres of the external oblique are divided parallel to the direction of the fibres. The internal oblique and transversalis are then split in the direction of their fibres, retracted, and their combined aponeurosis is further divided with the knife. The sheath of the rectus is now opened in a vertical direction, and the muscle retracted inwards. The underlying fascia transversalis and peritoneum can then be easily separated with the finger from the fascia of the abdominal muscles down to Poupart's ligament, and also off the fascia covering the ilio-psoas muscle in the internal iliac fossa, this separation being continued as far as the bifurcation of the common iliac at the edge of the psoas. The pale red ureter is here observed crossing the artery obliquely, and is raised up along with the peritoneum. In the male the spermatic vessels, which descend in front of the ureter and in front of the external iliac artery to reach the internal abdominal ring, are also elevated. In the female, the ovarian artery crosses in front of the external iliac artery to enter the suspensory ligament of the ovary.

The external cutaneous nerve and, at the crest of the ilium, the iliac branch of the ilio-lumbar artery, a branch of the internal iliac, are encountered on the fascia iliaca. The genito-crural nerve lies on the main artery, its genital branch, which enters the inguinal canal at the internal abdominal ring, being also raised up, while the crural branch pursues the course of the external iliac artery. On the left side the inferior

[1] *Vide* Kümmel 1884, and Dreist, *Deutsche Zeitschr. f. Chir.* Bd. 71.

[2] Compare the admirable compilation by Tillmann on ligature of blood-vessels of the pelvis. Tillmann calculates the mortality from ligature of the common iliac artery at 55 per cent (Dreist) even in antiseptic days. Gebson was the first to ligature the artery intra-peritoneally in 1812, and Mott extra-peritoneally in 1827.

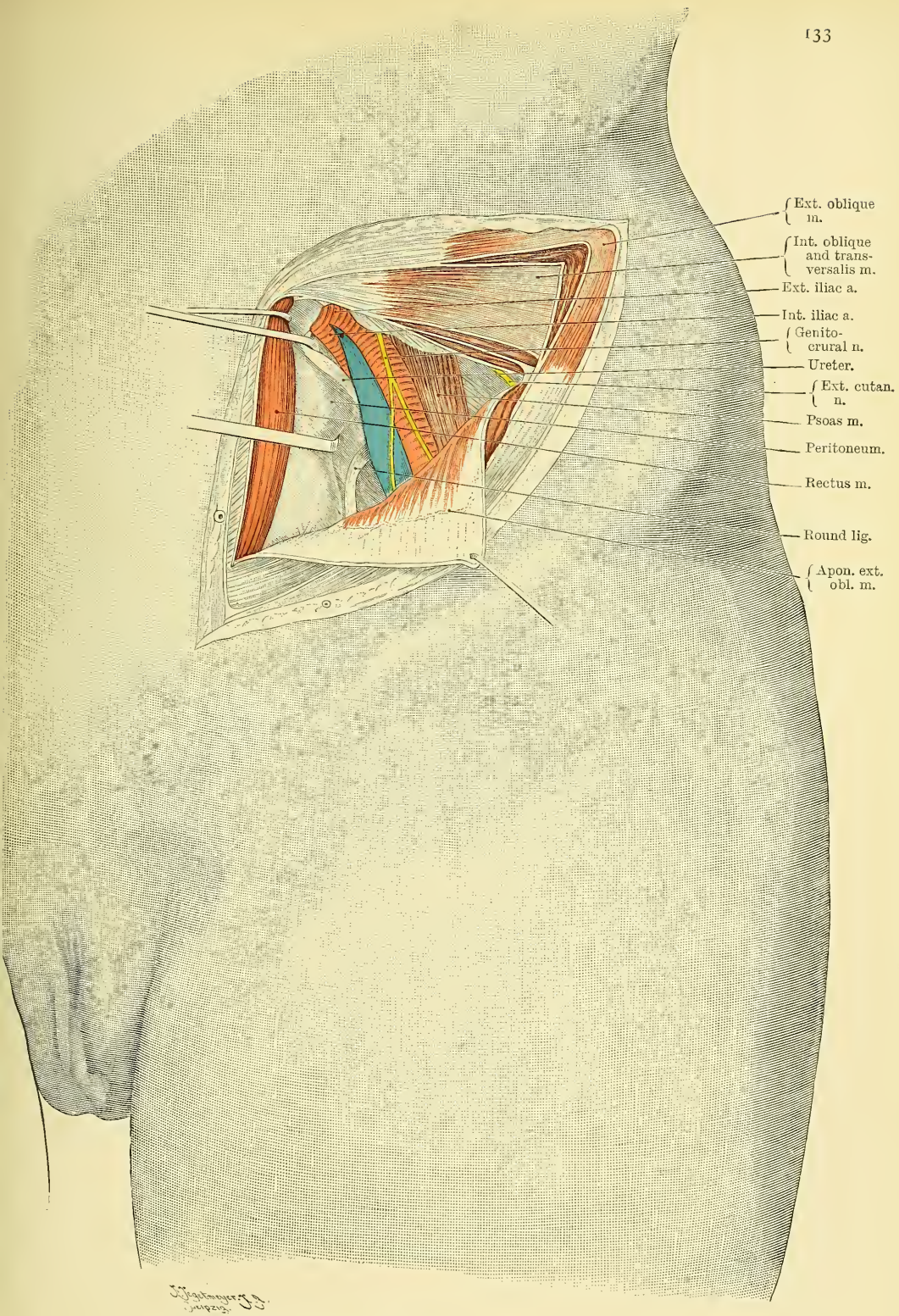

FIG. 53.—Angular incision for ligature of the common iliac artery. (Only a small part of the trunk of the artery is here represented.)

mesenteric artery or its sigmoid branches, and especially the superior hæmorrhoidal artery, cross in front of and to the inner side of the ureter, and are also raised up.

This procedure for ligaturing the common iliac artery differs essentially from that described in our 4th edition (Mott's incision), and also from all the methods mentioned by Tillmann. We regard it as a great advance on other methods, because the process entails division of neither muscles nor nerves. Further, by making a simple long oblique incision through the skin and fascia, and then an angled incision through the deeper fasciæ and muscles, we can obtain much better access without causing further injury. By splitting the deeper muscles in the line of their fibres, *i.e.* transversely, and by opening the sheath of the rectus in a vertical direction we turn down a three-cornered flap (see Fig. 53), which gives excellent access to the bifurcation of the common iliac artery and even of the aorta itself.

We would recommend this incision when a free exposure of the internal iliac fossa is desired. It should be performed in preference to the intra-peritoneal method except in cases when the peritoneum is so closely adherent that it cannot be separated (*e.g.* in Aneurysm).

(l) Hypogastric Artery and its Branches (Pelvic Arteries)

55. Internal Iliac Artery (Fig. 53). The internal iliac artery can be ligatured by the same method as that described for the common iliac, or transperitoneally with the patient in the Trendelenburg position, as has been successfully attained by Dennis and Treves. Extra-peritoneal ligature is preferable to intra-peritoneal as it is simpler and less dangerous. It is only when the vessels on both sides are to be ligatured that the intra-peritoneal method should be adopted.

The artery passes forwards from the bifurcation of the common iliac artery, upon the inner aspect of the psoas muscle, and in front of the sacro-iliac articulation. It then passes inwards and downwards into the true pelvis, from the point where the common iliac artery is crossed by the ureter. The ureter, which descends in front of the artery, is raised up along with the peritoneum. According to Baudet and Kendirdjy, the internal iliac artery has been ligatured for hypertrophy of the prostate, for inoperable cancer of the uterus, in excision of the rectum, for vascular tumours, and for aneurysm of the gluteal and sciatic arteries.

Quénu and Duval recommend the transperitoneal method with a mesial incision, the peritoneum of the posterior abdominal wall being divided over the promontory of the sacrum 3 to 5 cm. from the middle line.

Krönig has ligatured both internal iliacs for inoperable cancer of the uterus, in which cases the intra-peritoneal operation is preferable, Pfannenstiel's transverse curved incision between the umbilicus and pubis being the best, while Kosler (Niermer) places the incision (7 cm. long) 1 cm. above the line of the pubic hair. The bifurcation of the aorta is exposed and the peritoneum split longitudinally for a length of 10 cm. (4 inches), after which the bifurcation of each iliac artery is defined by blunt dissection, and both internal iliac arteries are ligatured.

Vuillet[1] has successfully ligatured the internal iliac artery intra-peritoneally, for secondary hæmorrhage from the gluteal artery.

56. There is no indication, except in the course of an operation, to isolate and ligature the *superior vesical* artery (umbilical artery in the fœtus), which traverses the pelvic wall to reach the apex of the bladder.

57. The ilio-lumbar artery runs backwards behind the psoas, and is continued along the crest of the ilium, where it lies on the iliacus muscle and anastomoses with the circumflex iliac artery. It is ligatured in operations involving the iliac fossa from behind.

The chief importance attached to this artery is that it forms an anastomosing link between branches of the aorta and of the hypogastric (internal iliac) (*vide* No. 54).

58. The Obturator Artery (Fig. 54) in its course to the obturator canal is

[1] *Arch. internat. de chirurgie*, Gand, 1904.

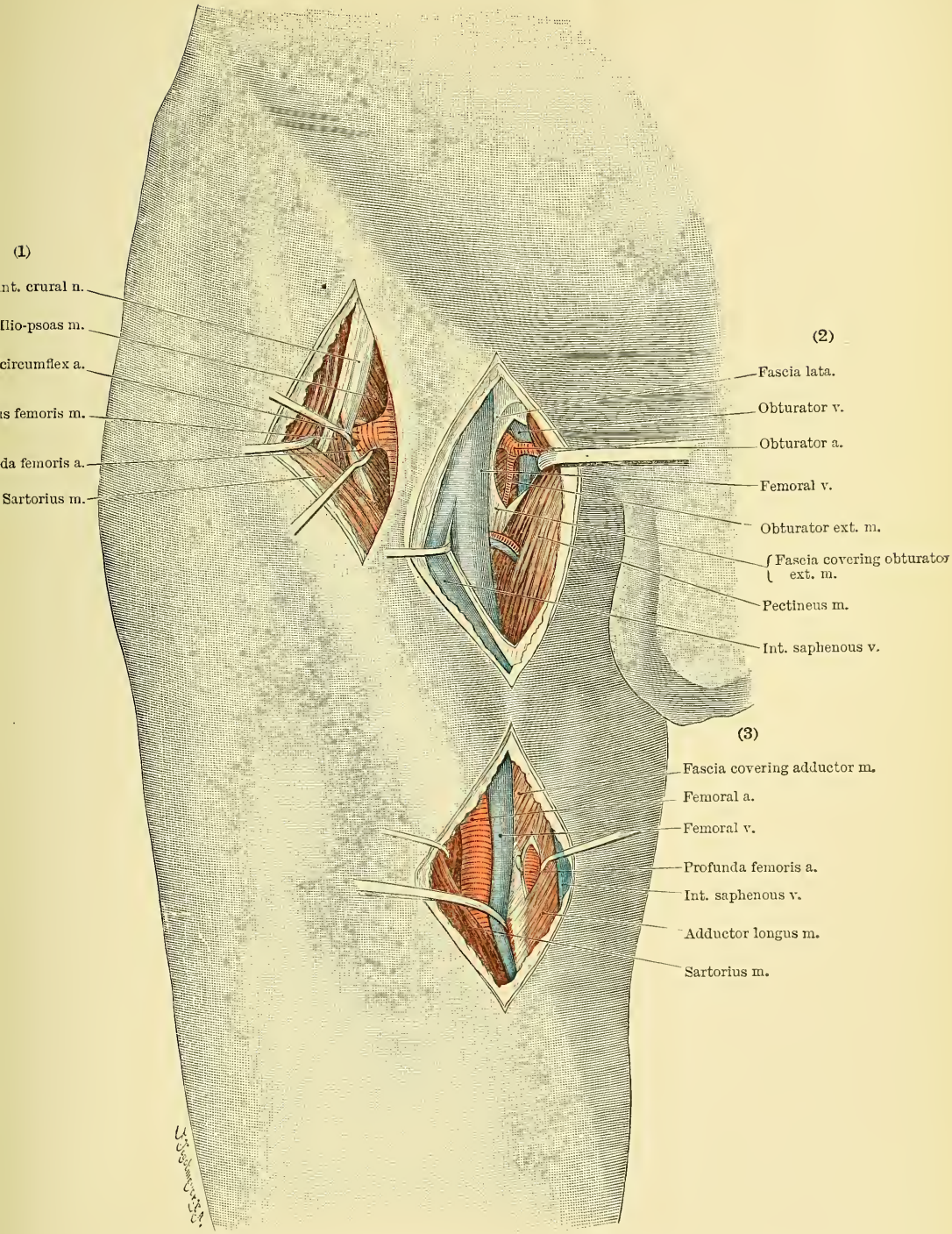

FIG. 54.—(1) Ligature of profunda femoris artery and external circumflex artery. (2) Ligature of obturator artery. (3) Ligature of profunda femoris artery.

situated between the peritoneum and the obturator internus muscle. Its pubic branch, which ascends on the back of the pubis to the inner side of the crural ring, may be injured in relieving the constriction of a femoral hernia.

(*a*) *In the pelvis.* The peritoneum is raised up in the same way as for ligature of the internal iliac artery. The artery may have to be ligatured in the pelvis when it arises abnormally from the deep epigastric, and when it is injured in the course of an operation for femoral hernia. The deep epigastric itself would then have to be tied.

(*b*) *Ligature at its exit from the obturator canal at the upper border of the obturator externus muscle* (Fig. 54). The incision—the same as for ligature of the internal circumflex branch of the profunda femoris—descends vertically from a point a finger's-breadth internal to the middle of Poupart's ligament. The skin, superficial fascia, and superficial layer of the fascia lata are divided. The internal saphenous vein, which lies upon the fascia, is drawn outwards. The strong pectineal fascia is divided just internal to the femoral vein. After the outer border of the pectineus muscle has been defined the latter is separated from the os pubis and fascia over the obturator externus, and is drawn well inwards. The strong transversely-striated fascia over the obturator externus muscle is now divided, and the finger, passed above the upper border of the muscle, feels for the under surface of the horizontal ramus of the pubis, below which the artery leaves the obturator foramen accompanied by the obturator nerve which lies above it.

59. The Lateral Sacral Artery is ligatured when divided in resection of the sacrum.

60. Gluteal Artery (Fig. 55). The place where the artery is ligatured may be ascertained through the skin by feeling for the upper edge of the great sacro-sciatic foramen, at the level of the upper end of the gluteal fissure and of the upper edge of the gluteus maximus muscle. Here the artery passes backwards from under cover of the pyriformis.

The incision corresponds to the upper two-thirds of a line extending from the posterior superior iliac spine to the upper border of the great trochanter. The skin, fascia, and thick gluteus maximus—the fibres of which run parallel to the incision—are divided. After division of the fascia over the lower border of the gluteus medius, the muscle itself is exposed and drawn upwards. On the finger being passed under it the upper margin of the great sacro-sciatic foramen is felt. Here, above the upper border of the pyriformis, the large gluteal artery passes directly backwards out of the pelvis and at once gives off large branches, the largest passing outwards. The *superior gluteal nerve* passes out of the pelvis along with the artery, and runs outwards between the gluteus medius and minimus, to end in the tensor fasciæ femoris muscle.

61. Sciatic Artery (Fig. 55). Incision corresponding to the middle two-thirds of a line extending from the posterior inferior iliac spine to the base of the great trochanter. The incision is below and parallel to that for ligature of the gluteal artery. The skin, the thick subcutaneous fat, the fascia, and the fibres of the thick gluteus maximus are divided. The lower border of the pyriformis muscle is visible under the gluteus maximus, and is clearly exposed with the finger. The artery, accompanied by the inferior gluteal nerve, appears from under the proximal end of the pyriformis. The nerve, after giving off large branches to the gluteus maximus and a branch to the small sciatic nerve, is continued vertically downwards under the fascia of the back of the thigh. The spine of the ischium and the lesser sacro-sciatic ligament which is attached to it serve as a guide to the place of exit of the artery from the pelvis.

62. Inferior Vesical Artery. This artery is ligatured *in loco* in exposing the base of the bladder.

63. Artery to the Vas Deferens. This artery is only of importance in that it acts as a substitute for the spermatic artery in maintaining the nutrition of the testicle. If necessary it can be ligatured by means of the inguinal incision over the spermatic cord, where it lies close to the vas deferens.

64. Middle Hæmorrhoidal Artery. This artery, which is ligatured in excision

of the rectum, is found closely applied to the wall of the rectum above the coccygeus and levator ani muscles and the pelvic fascia.

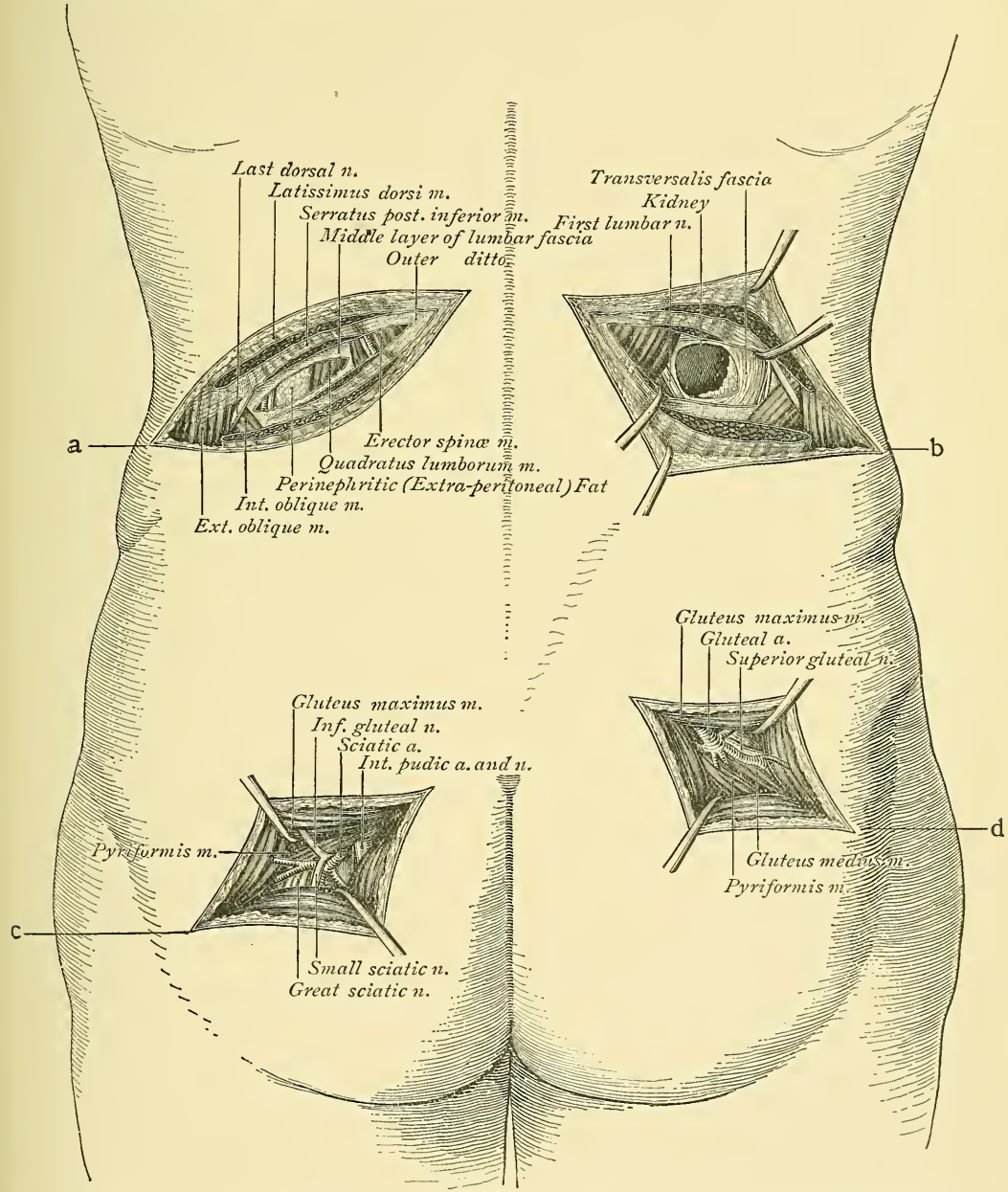

FIG. 55.—(*a*) and (*b*) Nephrotomy. (*c*) Ligature of the sciatic and internal pudic arteries, and exposure of the great sciatic, small sciatic, and internal pudic nerves. (*d*) Ligature of the gluteal artery and exposure of the superior gluteal nerve.

65. The Uterine Artery. Ligature of the uterine artery is chiefly performed as a preliminary to excision of the uterus, extirpation of large myomata, or in order to produce atrophy of uterine myomata.

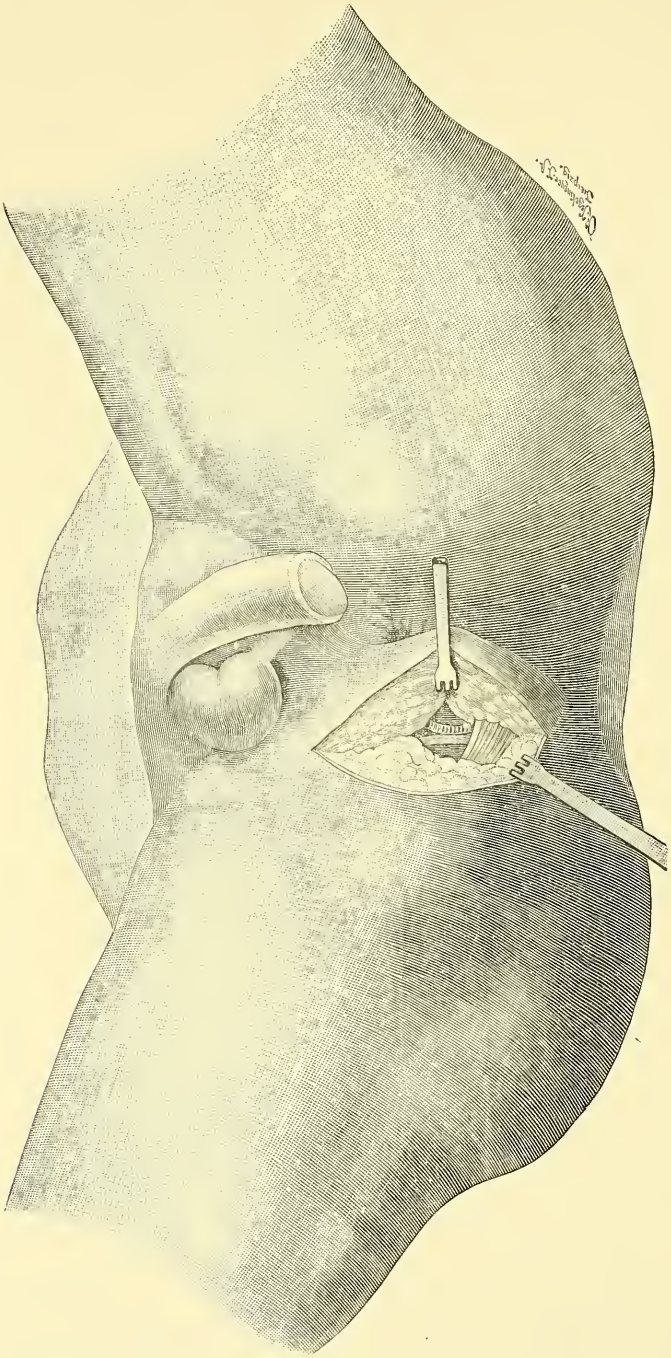

FIG. 56.—Ligature of the internal pudic artery at the ischial tuberosity.

As it is difficult to reach from the iliac fossa, the intra-peritoneal route is to be preferred, an incision being made into the broad ligament parallel to and behind the round ligament, 1 cm. from the "linea innominata" (Altoukhow). The ureter and the ovarian vein remain behind with the posterior layer of the broad ligament.

The artery can also be ligatured after it has crossed the ureter in its course to the cervix uteri. It is found close to the lateral wall of the uterus between the layers of the broad ligament, where it gives off a branch to the vagina and a branch which passes behind the uterus to anastomose with the artery of the other side.

66. Internal Pudic Artery (Fig. 55). (*a*) This vessel may be ligatured from behind through the same incision as that made for ligaturing the sciatic artery (*vide* No. 60). At its exit from the pelvis it lies below the pyriformis muscle internal to and deeper than the sciatic artery, and re-enters the pelvis by passing round the base of the ischial spine. The relation of the artery to the ischial spine can be readily determined. The internal pudic nerve lies on the artery.

(*b*) *Ligature in the perineum* (Fig. 56). Longitudinal incision at the inner edge of the tuber ischii, one-third being placed in front and two-thirds behind, through skin, thick fatty layer and perineal fascia. Anteriorly, the transversus perinei muscle is defined and retracted forwards, while the edge of the gluteus maximus and the sacro-sciatic ligament are exposed in the posterior end of the wound. After division of the fascia covering the obturator internus along the inner border of the tuberosity the artery is found deeply placed, accompanied by the pudic nerve, the latter being more superficial.

The branches of the internal pudic artery, viz. the inferior hæmorrhoidal, superficial perineal, dorsal and profunda arteries to the penis (or clitoris) and the artery to the bulb, are ligatured when divided in the course of operation.

(m) External Iliac Artery and its Branches (Arteries of the Lower Extremity)

67. Ligature of the External Iliac Artery (Fig. 57). The results of ligature of the external iliac artery are more satisfactory than those of the common iliac, as there is a free collateral anastomosis between the internal iliac and the branches of the common femoral and profunda femoris. The artery is much more easily ligatured than the internal iliac.

An incision is made close above and parallel to the middle third of Poupart's ligament, with division of the skin and well-developed superficial fascia, while the superficial epigastric artery, which ascends vertically in the fascia, must also be divided. After division of the aponeurosis of the external oblique, the internal oblique and transversalis muscles need not be similarly treated as Tillmann and Cooper propose, but are detached upwards from out of the groove of Poupart's ligament with the handle of the scalpel, and the dense transversalis fascia which closes each groove behind is divided. The artery, together with some lymphatic glands, lies beneath some fatty tissue under Poupart's ligament. Internal to it is the vein, and external to it the fascia of the psoas muscle. The *anterior crural nerve* lies deeply between this muscle and the edge of the iliacus, about 2 cm. ($\frac{3}{4}$ in.) external to the artery. Upon the artery is the slender crural branch of the genito-crural nerve, which supplies the skin of the inner half of the front of the thigh in its upper part. According to Currie,[1] who collected eight cases of ligature of the external iliac, the transperitoneal operation is necessary in dealing with an aneurysm, although it should not be regarded as the normal procedure.

The branches of the external iliac artery, namely, the *deep epigastric* and the *deep circumflex iliac* arteries, may be exposed at their origin above Poupart's ligament, below the abdominal muscles and the fascia transversalis, by the same incision as that for the external iliac artery.

68. Ligature of the Deep Epigastric Artery. This artery arises a short distance above Poupart's ligament, lying behind the fascia transversalis and running upwards and inwards along the inner side of the internal abdominal ring.

(*a*) *Ligature at its origin* (Fig. 57). The artery may have to be ligatured at its origin in wounds of the abdominal wall, or when an abnormal obturator artery

[1] *Annals of Surgery*, vol. 4, 1905.

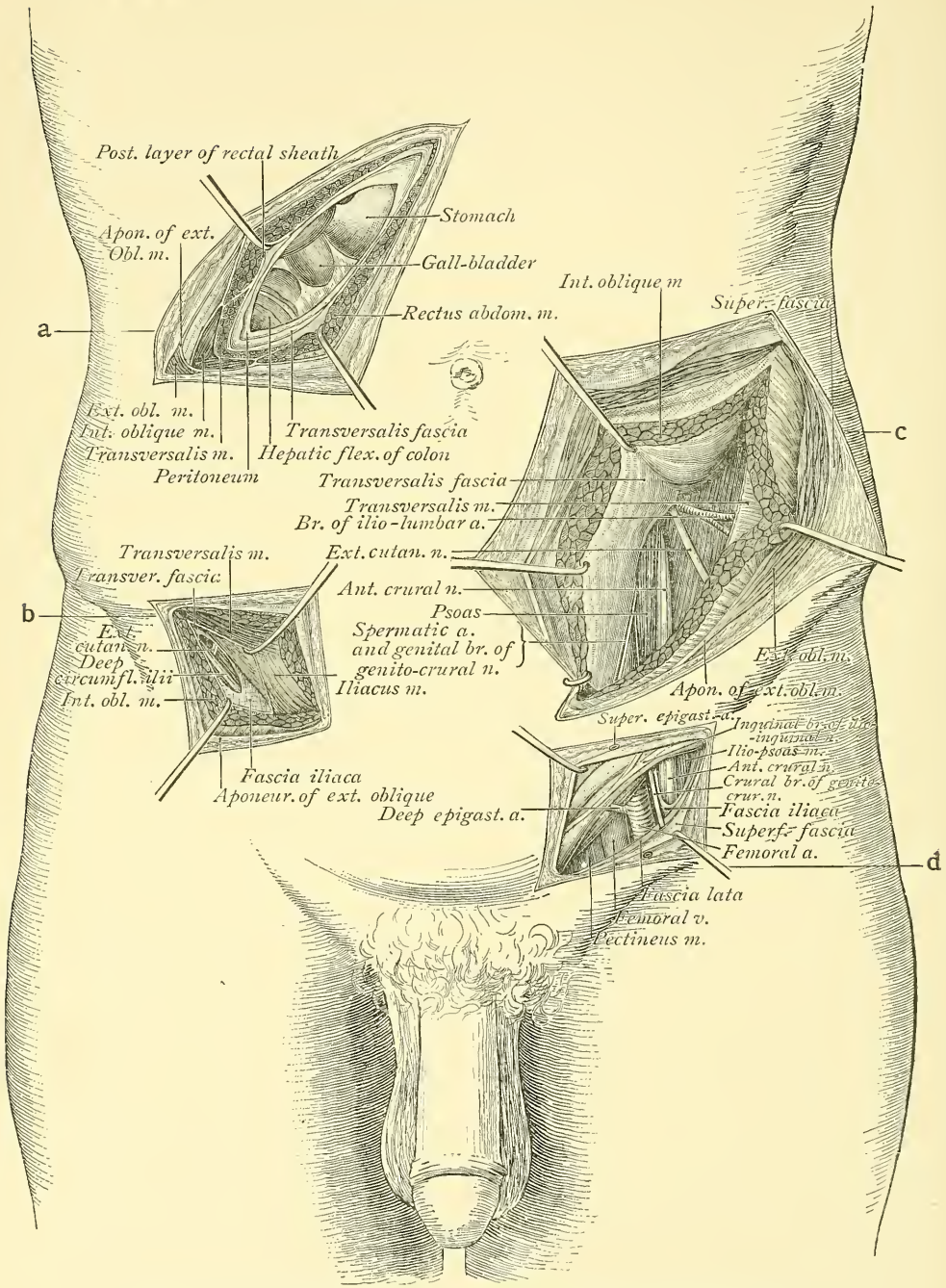

FIG. 57.—(*a*) Cholecystotomy. (*b*) Ligature of the deep circumflex iliac artery. (*c*) Ligature of the common iliac artery. (*d*) Ligature of the common femoral artery.

from the epigastric has been injured in dividing the constriction of a strangulation in femoral hernia. It is exposed in the same way as the external iliac artery. At its origin it lies in front of the external iliac vein and to the inner side of the main artery.

(*b*) *Ligature at the outer border of the rectus* (Fig. 57*a*). This is effected by an incision three fingers'-breadth above and parallel to the inner half of Poupart's ligament, the operator dividing skin, superficial fascia, the strong oblique fibres of the aponeurosis of the external oblique, and the transverse fibres of the aponeurosis of the internal oblique and transversalis muscles, which fuse together to form the anterior layer of the sheath of the rectus. The outer edge of the rectus is exposed and drawn

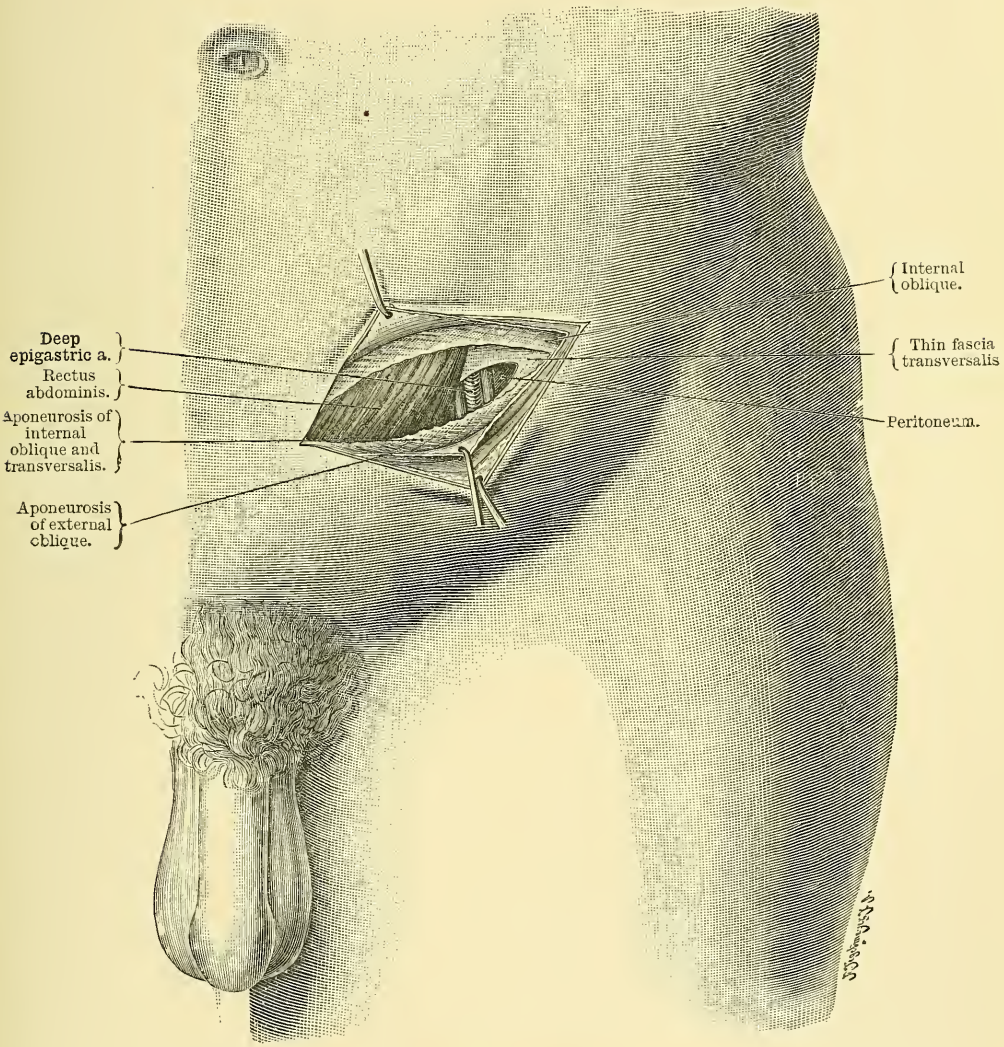

FIG. 57*a*.—Ligature of the deep epigastric artery.

inwards. Beneath it, and covered by a very thin layer of connective tissue (fascia transversalis), is the extra-peritoneal fat, and upon it the artery, ascending obliquely from below upwards and inwards under the edge of the rectus.

69. **Ligature of the Deep Circumflex Iliac Artery** (Fig. 58). An incision is made above the outer third of Poupart's ligament, with division of the skin, the superficial fascia, and the strong oblique fibres of the external oblique. The thick ascending fibres of the internal oblique, and the transversalis muscle are separated and pulled

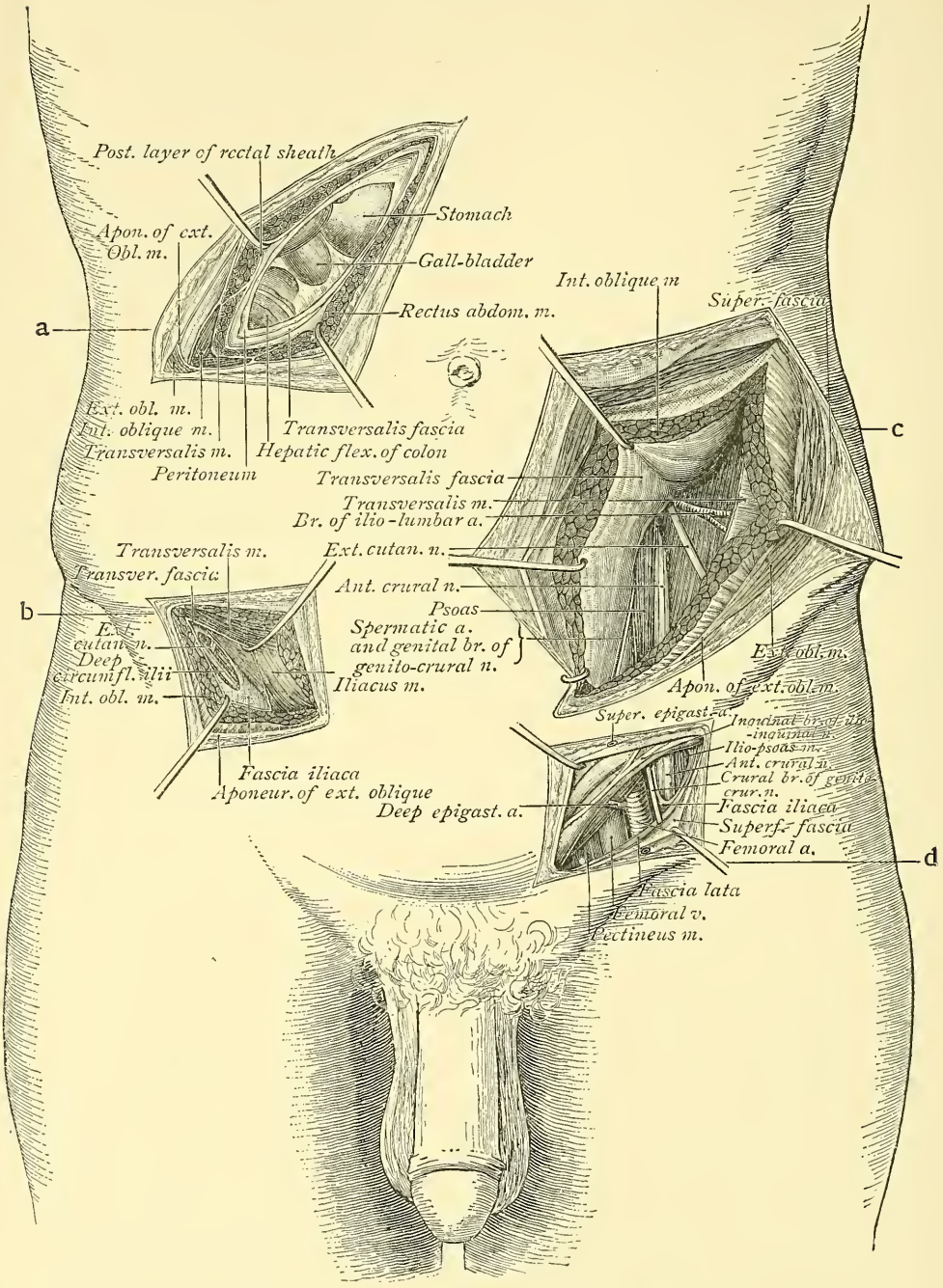

FIG. 58.—(*a*) Cholecystotomy. (*b*) Ligature of the deep circumflex iliac artery. (*c*) Ligature of the common iliac artery. (*d*) Ligature of the common femoral artery.

apart. Between the two latter muscles are some vessels and branches of the ilio-inguinal nerve. The transversalis fascia is now divided, and the peritoneum is carefully raised from the iliac fascia. After division of the iliac fascia the artery is found lying

parallel to Poupart's ligament upon the iliacus muscle. The external cutaneous nerve passes obliquely downwards behind it. It is important to know the relation of parts along this incision, as it is often employed in opening psoas abscesses. A psoas abscess lies underneath the fascia.

70. Ligature of the Femoral Artery (Fig. 59). The femoral is the direct continuation of the external iliac artery, coursing in a line from the middle of Poupart's ligament directly downwards towards the middle of the posterior aspect of the knee-joint, and passing from the inner towards the posterior surface of the femur at the junction of the middle and lower thirds of the bone. The incisions for ligaturing the artery, however, are made along a line extending from the middle of Poupart's ligament to the adductor tubercle, because in the lower part the artery is reached not from the front but from the inner aspect.

Common femoral artery in the flexure of the groin.[1] An incision is made parallel to and below the middle third of Poupart's ligament, followed by ligature of the superficial epigastric artery in the subcutaneous tissue, and division of the superficial layer of the fascia lata below Poupart's ligament. The artery, along with the origins of the deep epigastric and deep circumflex iliac arteries, appears below the middle of the ligament lying upon the pubic bone, where it may be distinctly felt. The crural branch of the genito-crural nerve lies upon the sheath of the vessel. Internal to the artery is the femoral vein : external to it the fascia covering the ilio-psoas, and beneath the fascia the trunk of the anterior crural nerve at the outer edge of the psoas.

In the upper third, at the apex of Scarpa's triangle. The skin and fascia lata (the latter forming the anterior sheath of the sartorius) are divided along the line already mentioned. The sartorius is freed and drawn outwards. Under this muscle are the sheath of the vessel and branches of the anterior crural nerve, the large internal saphenous nerve being external to the artery. The femoral vein is to its inner side. Upon the fascia, external to the incision, is the middle cutaneous nerve, while the internal saphenous vein lies internal to the incision.

Above the opening in the adductor magnus (at the lower part of Hunter's canal). Longitudinal incision is made at the junction of the middle and lower thirds of the thigh (reckoned from the anterior superior iliac spine to the lower end of the femur), along the groove which can be felt between the adductor and extensor muscles. The internal saphenous vein is avoided, and after division of the fascia, the sartorius muscle, which is recognised by its longitudinal fibres, is drawn inwards and backwards. The dissection is continued down to the fibres of the fascia covering the vastus internus, which are directed obliquely forwards. This fascia is divided at the anterior edge of the white glistening tendon of the adductor magnus, to which it is adherent. The artery lies very near the bone. Posterior and external to it is the vein, whilst the long saphenous nerve lies in front of the sheath. One must take care not to pass too far backwards—that is to say, behind the adductor tendon.

Upper part of popliteal artery—**(a) From the Inside.** Incision is made behind the prominent cord-like tendon of the adductor magnus, which is inserted into the adductor tubercle. Posteriorly lie the sartorius, the tendons of the gracilis, and semitendinosus, and under the latter the muscular substance of the semi-membranosus. The long saphenous vein is found in the subcutaneous tissue. After division of the fascia the muscular fibres of the sartorius appear. On the dissection being continued deeply between it and the tendon of the adductor magnus, the artery will be found upon the bone, behind the tendon, embedded in fat. The popliteal vein lies posteriorly, and between it and the integuments is the internal popliteal nerve. On drawing the sartorius muscle backwards the *internal saphenous nerve* is exposed, accompanied by the superficial branch of the *anastomotica magna artery*, both passing backwards across the inner edge of the tendon of the adductor magnus.

(b) From the Outside. Ligature of the popliteal artery below the opening in the adductor magnus, in the upper part of the popliteal space, is more easily effected from

[1] We regret that anatomists have not employed the term common femoral artery, as the two main sources of the blood-supply, the profunda for the thigh and the femoral proper for the leg, are still united.

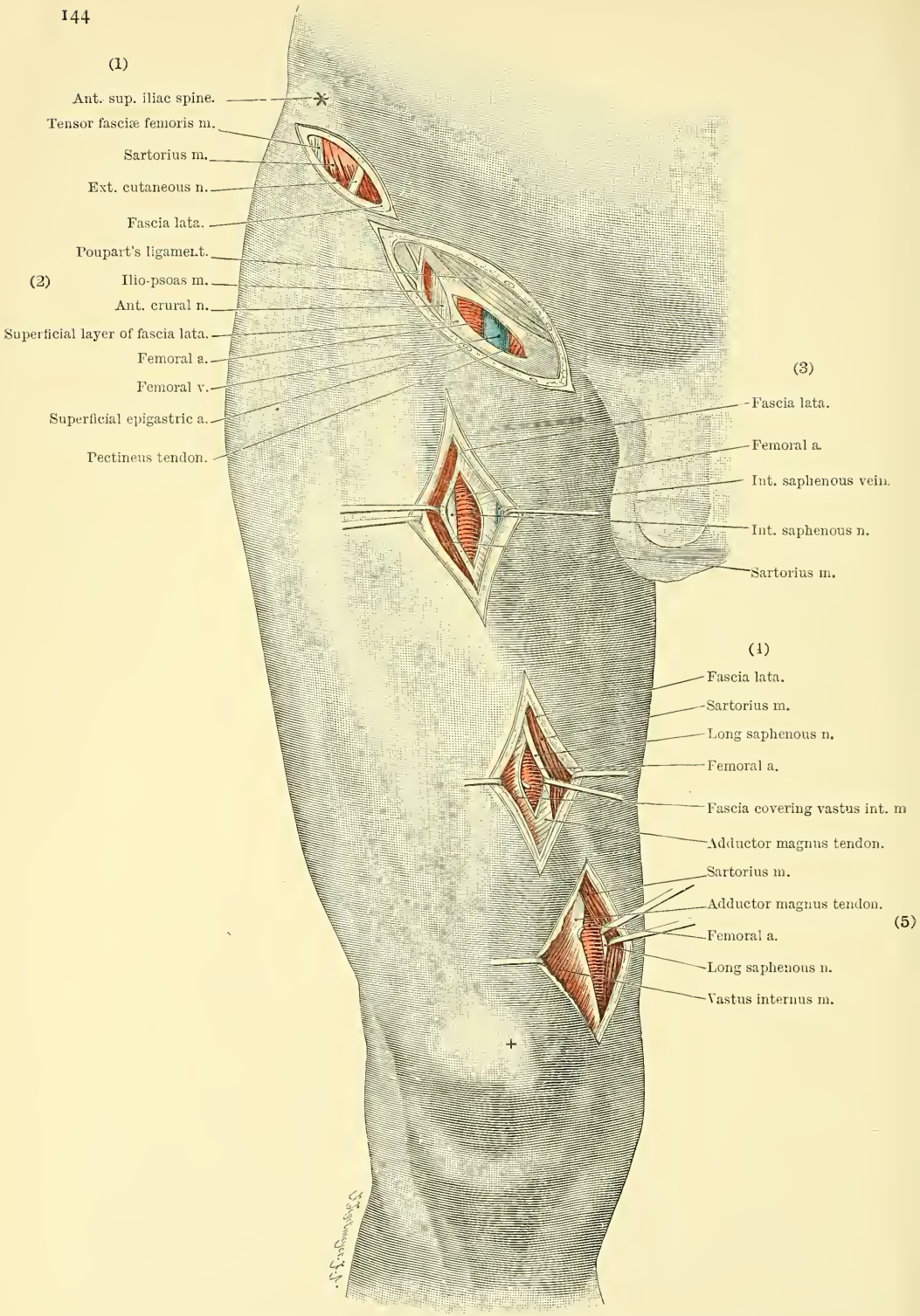

Fig. 59.—(1) External cutaneous nerve. (2) Common femoral artery. (3) Femoral artery. (4) Femoral artery at the opening in the adductor magnus. (5) Femoral artery at the lower end of the femur.

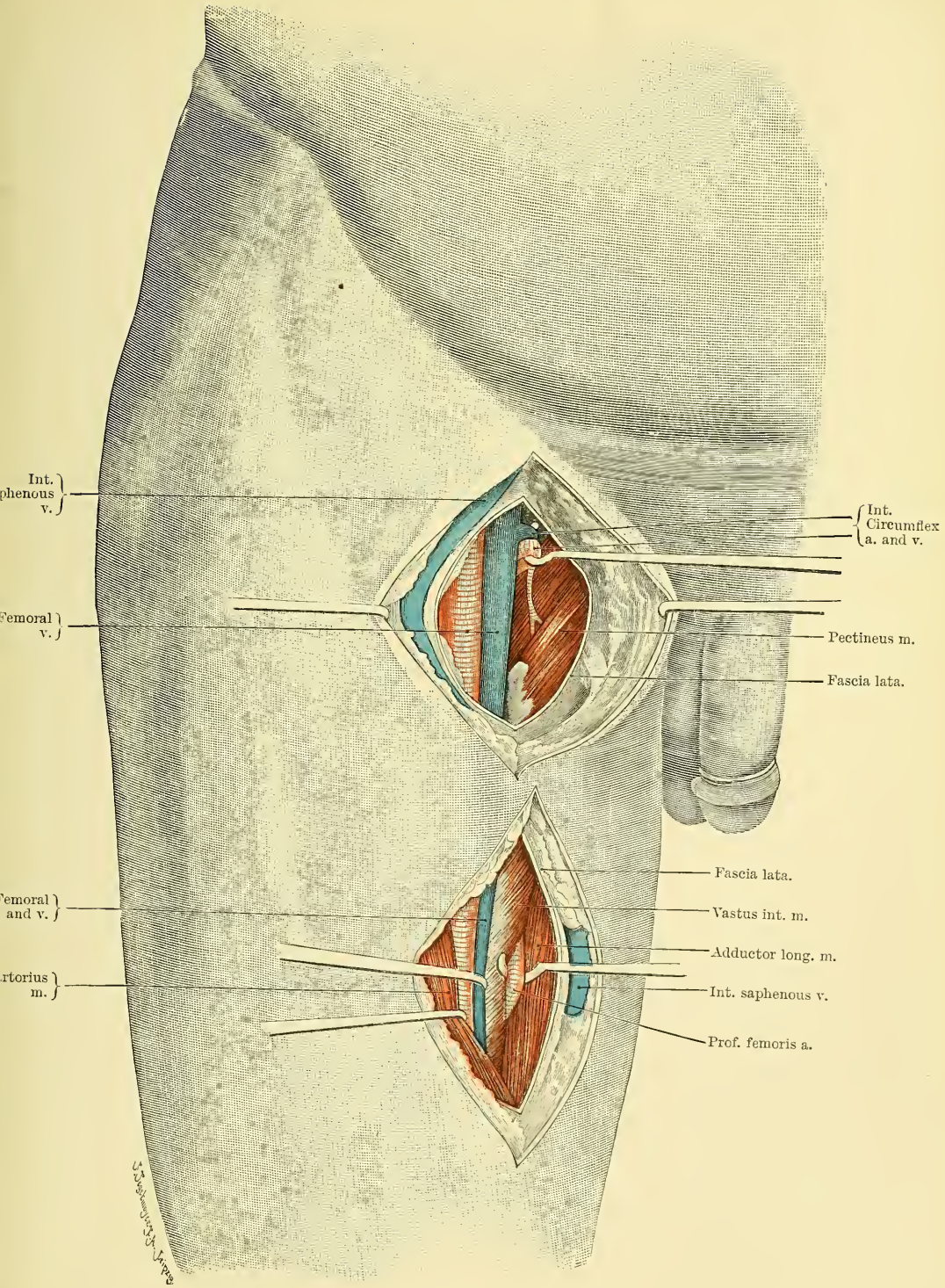

FIG. 60.—Ligature of internal circumflex artery.

the outer than the inner side. The incision is 8 to 10 cm. ($3\frac{2}{3}$ to 4 in.) long, extending upwards from the back of the external condyle of the femur through the skin and strong fascia lata. In front of the incision are the ilio-tibial band and the tendon of the vastus externus, behind which the finger is passed deeply towards the trigone of the femur, while the short head of the biceps is separated from the bone with a blunt dissector and retracted backwards. In the fat, along the inner edge of the biceps, is the popliteal nerve, superficial to which is the popliteal vein, with the popliteal artery situated more deeply and to its inner side.

The small branches of the common femoral artery, viz. the superficial epigastric, superficial circumflex iliac, and external pudic, are only ligatured in the case of accidental or operation wounds. The superficial epigastric lying in the fascia is frequently cut, and is always divided in the inguinal incision we recommend for hernia and for operations on the testicle.

71. Ligature of the Internal Circumflex Artery (Fig. 60). This artery arises as a rule from the common femoral, although in many cases it takes its origin from the profunda femoris. An incision is carried vertically downwards from a point a finger's-breadth internal to the middle of Poupart's ligament. The long saphenous vein, which is met with upon the fascia, is drawn outwards. The pectineal fascia is divided internal to the saphenous opening, so as to expose distinctly the muscular fibres of the pectineus. The artery passes above the outer border of this muscle above its insertion into the femur, and thence along the lower border of the obturator externus directly downwards and backwards to the inner aspect of the femur, where it gives off a large superficial branch which passes inwards over the pectineus muscle.

The artery is freed from the fatty tissue at the inner aspect of the femoral vein. When arising from the profunda artery it passes inwards behind the femoral vein; but when from the common femoral, it occasionally passes in front of the vein.

72. Ligature of the Profunda Femoris Artery (Fig. 61). (*a*) *At its origin from the common femoral.* An incision is carried vertically downwards from a point two fingers'-breadth below and 1 cm. external to the middle of Poupart's ligament. The centre of the incision is to be opposite the level of the base of the great trochanter. After division of the skin and the strong fascia lata the inner edge of the sartorius is exposed and drawn outwards. Under it is the inner edge of the rectus, close to which, embedded in fat, are the branches of the anterior crural nerve, which descend in front of the ilio-psoas muscle near its insertion. On drawing the nerves outwards, the outer surface of the femoral artery appears, with the profunda artery passing outwards and downwards from it; whilst arising from the latter is the external circumflex artery, which passes transversely outwards beneath the rectus. The point of origin of the vessel corresponds to the lower part of the palpable projection of the ilio-psoas muscle.

(*b*) *At the upper edge of the insertion of the adductor longus.* An incision is made through the skin and fascia at the junction of the upper and middle thirds of the femur a hand-breadth below the inner edge of the fold of the groin, in the same line as for ligature of the femoral artery—that is, in the groove where the bone can be felt between the adductors and extensors. The sartorius is drawn outwards, but instead of dividing the deep fascia over the vessels (sheath of the vessels), as is done in ligaturing the femoral artery, the fascia over the adductor longus is divided internal to the femoral vessels, and the dissection is continued deeply along the fibres of the adductor longus towards the bone, as far as the inner aspect of the vastus internus, the fibres of which pass obliquely downwards and forwards. The artery will be found at the posterior attached edge of the vastus internus immediately above the upper end of the insertion of the adductor longus, under which it is continued downwards.

73. Ligature of the External Circumflex Artery. (*a*) *At its origin*: the operation is the same as that for ligature of the profunda femoris (*vide* Fig. 61 and No. 72*a*).

The artery at once divides into a descending branch, which passes downwards beneath the rectus as far as the knee, and

(*b*) An ascending branch which runs outwards under the rectus, and which may

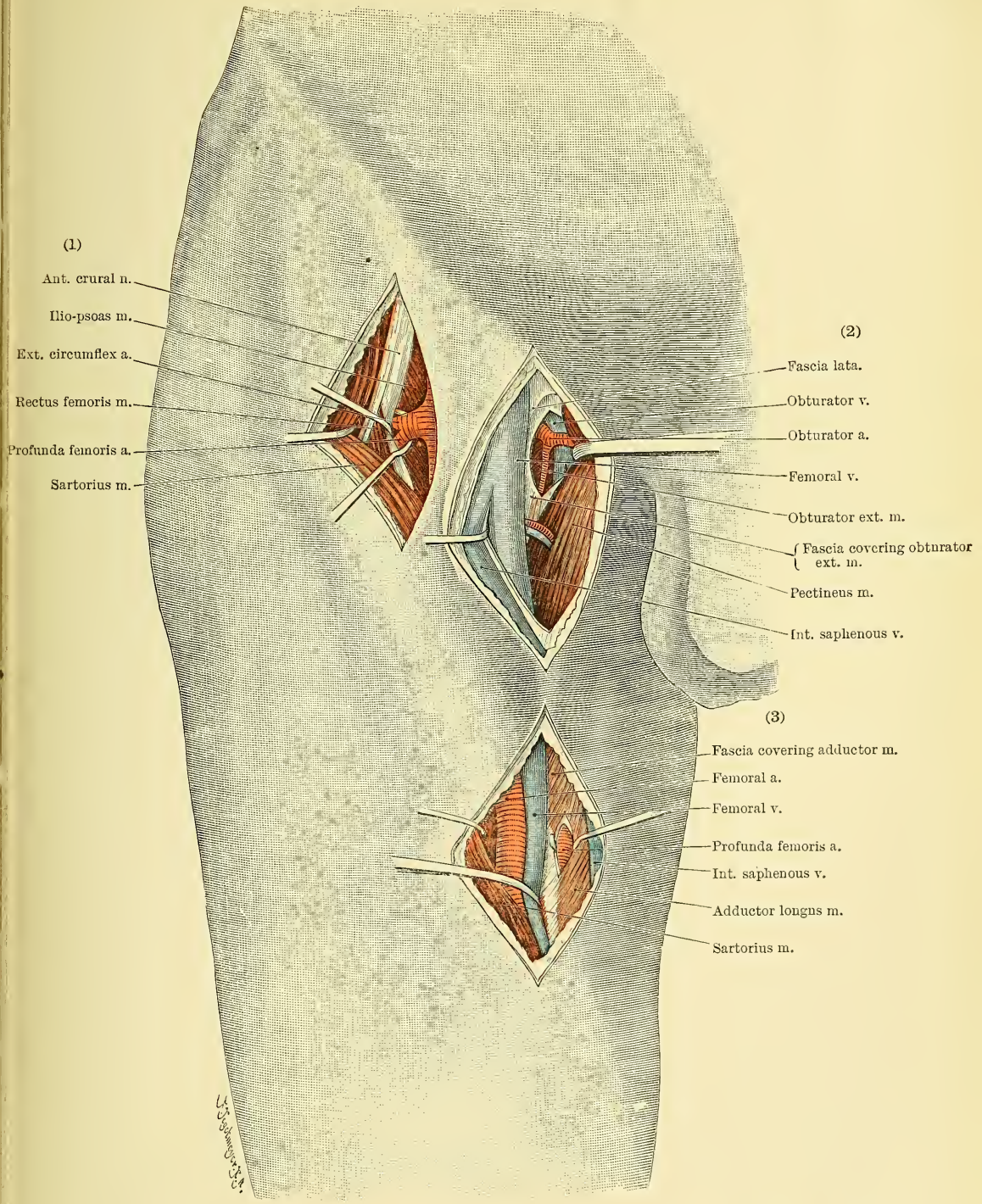

FIG. 61.—(1) Ligature of profunda femoris artery and external circumflex artery. (2) Ligature of obturator artery. (3) Ligature of profunda femoris artery.

be ligatured at the base of the great trochanter as a terminal branch of the external circumflex artery, where it is frequently injured in the course of operations.

The terminal branch may be exposed on the bone by an incision through the skin a finger's-breadth below the most prominent lateral projection of the great trochanter, and by the division of the strong fascia lata (aponeurosis of the gluteus maximus) and the glistening tendinous attachment of the vastus externus muscle.

74. Ligature of the Perforating Arteries. The terminal branches of the profunda femoris, *i.e.* the perforating arteries reach the back of the thigh in close contact with the inner side of the femur, and are occasionally ligatured in accidental wounds.

75. Ligature of the Anastomotica Magna Artery (Fig. 59). An incision is made through the skin and strong fascia along a line extending vertically upwards from the adductor tubercle of the femur. The sartorius muscle is drawn backwards. Under it, embedded in fat, is the long saphenous nerve accompanied by the superficial branch of the anastomotica magna artery. To find the deep branch, pass in front of the prominent glistening tendon of the adductor magnus towards the bone in the substance of the vastus internus. The artery arises from the femoral in front of the opening in the adductor magnus, so that it may be ligatured by the same method as that for the femoral itself. The superior internal articular branch of the popliteal artery is seen lying transversely upon the bone above the internal condyle.

(n) Popliteal Artery and its Branches

76. Ligature of the Popliteal Artery (Fig. 62). A vertical incision is made over the middle of the popliteal space opposite the knee-joint. The short saphenous vein is to be avoided at the lower part of the incision. It ascends between the two heads of the gastrocnemius and opens into the popliteal vein. To its outer side is the communicans fibularis nerve. The dissection is continued through the fat to the inner side of these structures and between the heads of the gastrocnemius. The internal popliteal nerve is the first structure to appear. When this is drawn outwards the popliteal vein comes into view, closely bound down by a strong sheath to the subjacent popliteal artery, which lies above upon the fat covering the femoral trigone, and below upon the popliteus muscle.

The muscular branches of the popliteal artery are represented by the sural arteries which end in the two heads of the gastrocnemius, while there are five articular arteries, viz. the superior and inferior external and internal, and the azygos, the latter of which is very conspicuous. These vessels are only ligatured in the case of injuries or operation wounds.

77. Ligature of the Anterior Tibial Artery (Fig. 63). This is the first large branch of the popliteal artery, and reaches the front of the leg by passing directly forwards above the upper end of the interosseous membrane. It can only be ligatured from the front of the leg. The course of the anterior tibial artery is indicated by a line extending from the projection at the anterior aspect of the outer tuberosity of the tibia (midway between the tubercle of the tibia and the head of the fibula) to the mid-point between the two malleoli.

In the upper third. An incision is carried downwards from a point midway between the tubercle of the tibia and the head of the fibula, beginning a thumb's-breadth below the outer tuberosity of the tibia. After division of the skin and fascia, the outer edge of the tendinous origin of the tibialis anticus, which arises from the outer tuberosity, is seen : it corresponds to the intermuscular space between the tibialis anticus and the extensor longus digitorum. This space is now opened up with the finger down to the interosseus membrane, through which the artery passes from behind forwards, about a finger's-breadth below the head of the fibula. The anterior tibial nerve reaches the artery somewhat farther downwards, coming from the outer side under the extensor communis digitorum muscle. The transverse branches of the nerve to the tibialis anticus are given off very high up.

In the middle third. An incision is made 3 cm. (rather more than an inch) external to the anterior edge of the tibia along the palpable and often visible furrow at the outer border of the tibialis anticus muscle. The fascia is divided along the white line corresponding to the above furrow (a second white line, somewhat farther outwards, corresponds to the intermuscular septum between the extensor longus hallucis and the extensor longus digitorum), and the finger is passed down to the interosseous membrane, upon which is the artery, under cover of the muscular fibres

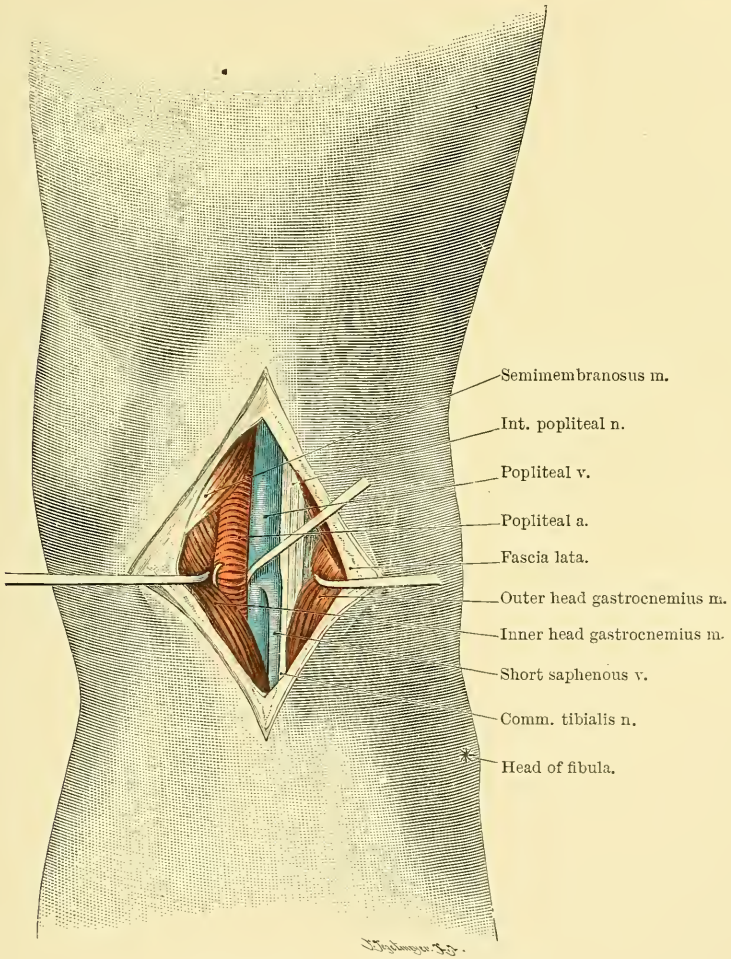

FIG. 62.—Ligature of popliteal artery.

of the tibialis anticus, between it and the extensor longus hallucis. The anterior tibial nerve lies upon the outer side of the artery.

In the lower third. An incision is made at the outer edge of the tendon of the tibialis anticus (the first large projecting tendon which lies external to the anterior border of the tibia), between it and the tendon of the extensor longus hallucis. After we have divided the skin and the strong fascia, the last-named tendon is clearly exposed and drawn outwards. The finger is now passed down towards the outer surface of the tibia. The first structure to appear external to the muscular fibres of the tibialis anticus muscle is the anterior tibial nerve beneath which is the artrey.

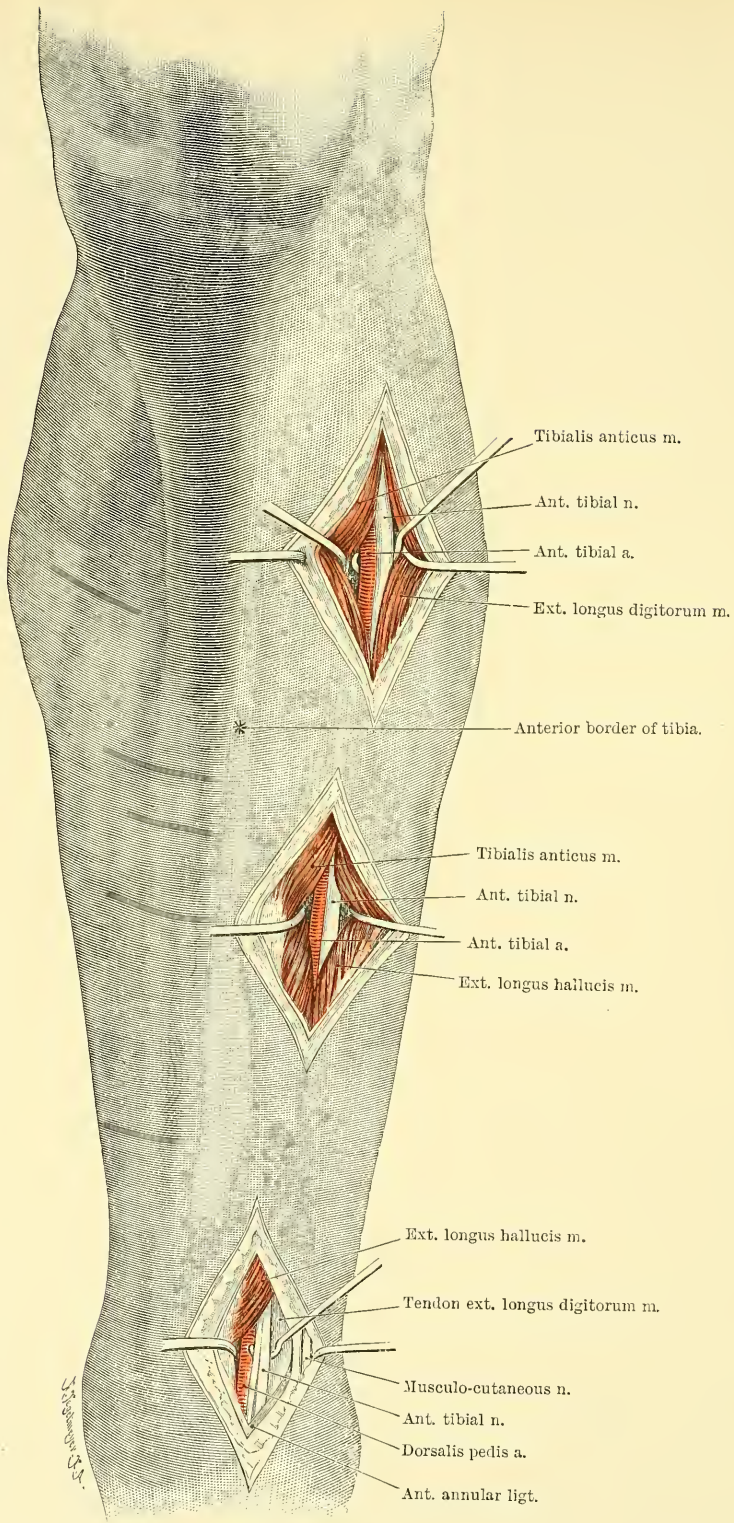

FIG. 63.—Anterior tibial artery and nerve.

As regards ligature of the small branches of the anterior tibial artery, viz. the anterior and posterior tibial recurrent and the internal and external malleolar arteries, only that of the dorsalis pedis on the dorsum of the foot requires consideration (*vide* No. 80).

78. Ligature of the Posterior Tibial Artery (Figs. 64 and 65). (*a*) *In the upper third of the leg* (*truncus tibio-peronealis*) (Fig. 64).[1] That portion of the posterior tibial artery between the origin of the anterior tibial and the peroneal artery may be conveniently referred to as the truncus tibio-peronealis. Incision is made downwards along the middle line, beginning at the level of the head of the fibula three fingers'-breadth below the popliteal crease. In division of the fascia, the short saphenous vein and communicans tibialis nerve are avoided and drawn outwards. The line of junction of the two heads of the gastrocnemius is sought for, and the tendinous raphe is freely divided. The large vessels and nerves to the heads of the gastrocnemius are drawn aside. Beneath the outer head of the gastrocnemius is the upper border of the soleus extending obliquely from above downwards and inwards; and upon it, also passing downwards and inwards, is the slender tendon of the plantaris muscle. The posterior tibial artery begins at the bifurcation of the popliteal, opposite the lower border of the popliteus and upper border of the soleus muscles. The edge of the latter muscle must be drawn downwards, or better nicked, in order to reach the posterior tibial artery, the corresponding vein and nerve being drawn outwards. The anterior tibial artery passes to the front through the interosseous membrane about $2\frac{1}{2}$ inches below the line of the knee-joint (a finger's-breadth below the lowest part of the head of the fibula). The tendinous surface of the soleus can be distinctly seen descending obliquely inwards towards the inner border of the tibia, under the inner head of the gastrocnemius.

(*b*) *In the upper half* (Fig. 65). The incisions for the posterior tibial artery lie in the direction of a line extending from the lower edge of the internal tuberosity of the tibia to a point midway between the internal malleolus and the tendo Achillis.

The incision is made half an inch behind the inner border of the tibia. The long saphenous nerve and vein (the latter in front) run in the line of the incision, and care must therefore be taken to avoid them. After division of the fascia the inner border of the gastrocnemius appears, and is drawn aside with a blunt hook. The oblique fibres of the subjacent soleus are now seen arising by a broad attachment from the tibia. They are to be divided until the strong obliquely-striated deep fascia which is attached to the posterior surface of the tibia is exposed, on dividing which the muscular fibres of the flexor longus digitorum come into view. The finger is now introduced into the wound and directed outwards between this muscle and the fascia covering it, when the artery will be felt lying upon the tibialis posticus muscle $1\frac{1}{4}$ inch beyond the inner border of the tibia. The large posterior tibial nerve is beyond the artery—that is to say, to its outer side. The tibialis posticus muscle lies upon the interosseous membrane. One must be careful not to pass between the tibia and the flexor longus digitorum. The mistake which is most frequently made is to pass in between the gastrocnemius and the soleus, instead of dividing the whole thickness of the latter muscle.

In the lower third (Fig. 65). An incision is carried downwards from the angle at the upper end of the visible and palpable furrow between the inner border of the soleus and the deep flexors (the flexor longus digitorum lying next the inner border of the tibia).

The long saphenous vein and nerve are to be avoided in dividing the skin and fascia. The free inner border of the soleus is then exposed and drawn backwards, when the tendon of the flexor longus digitorum (with its muscular fibres behind it) will be seen lying upon the tibia. On dividing the thin fascia covering the deep flexors, the artery will be found immediately under it to the outer side of the flexor longus digitorum. The posterior tibial nerve lies still more external.

Behind the internal malleolus. Incision is made midway between the posterior

[1] The portion of the artery between the origin of the anterior tibial and the peroneal artery ought to possess a distinctive name.

border of the internal malleolus and the tendo Achillis, dividing the skin, superficial fascia, and the strong transversely striated deep fascia. Between the internal malleolus and the artery are the tendons of the tibialis posticus and flexor longus

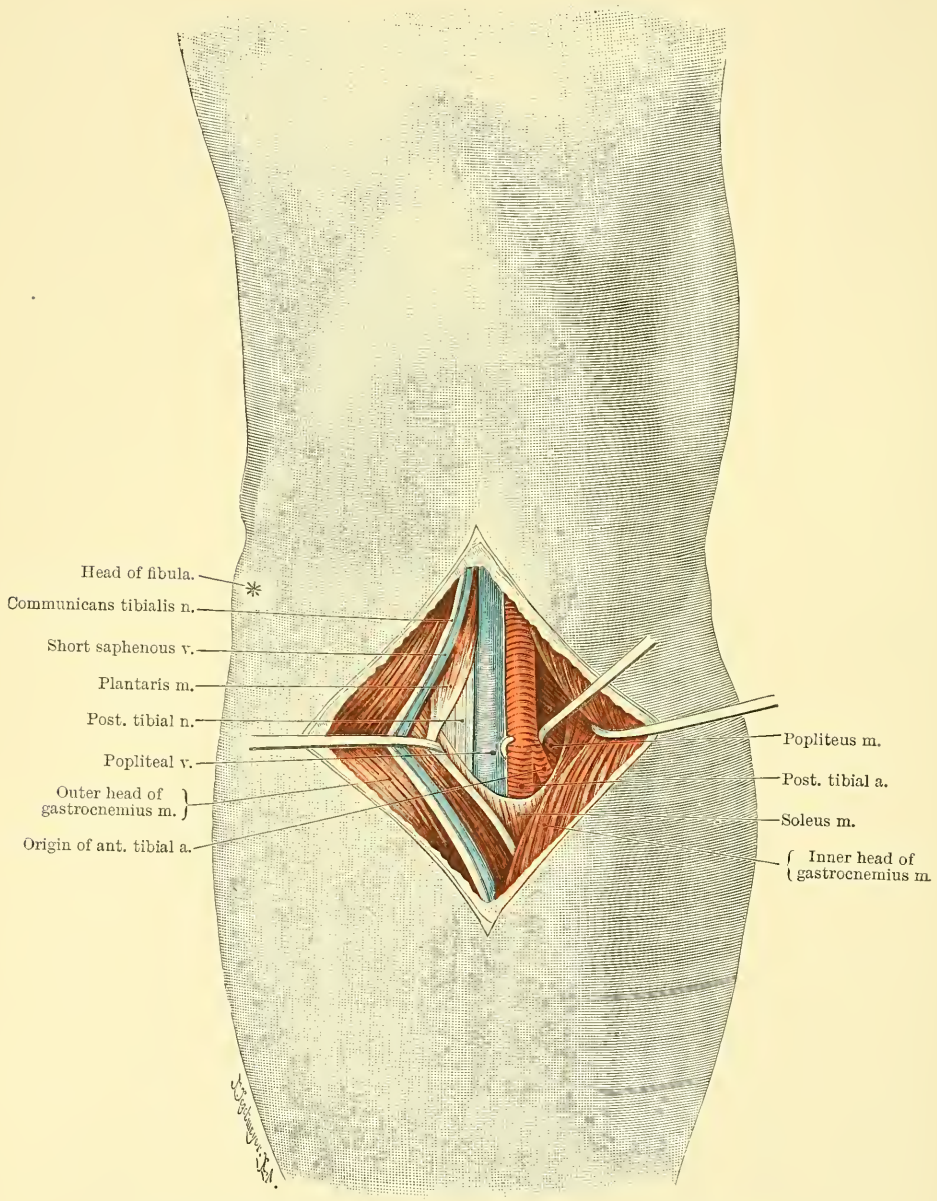

FIG. 64.—Ligature of posterior tibial artery above the origin of the peroneal.

digitorum, which lie in the order mentioned from before backwards. Behind the artery is the large posterior tibial nerve, and behind it again the tendon of the flexor longus hallucis. In this operation care must be taken not to pass in amongst the fat lying in front of the tendo Achillis.

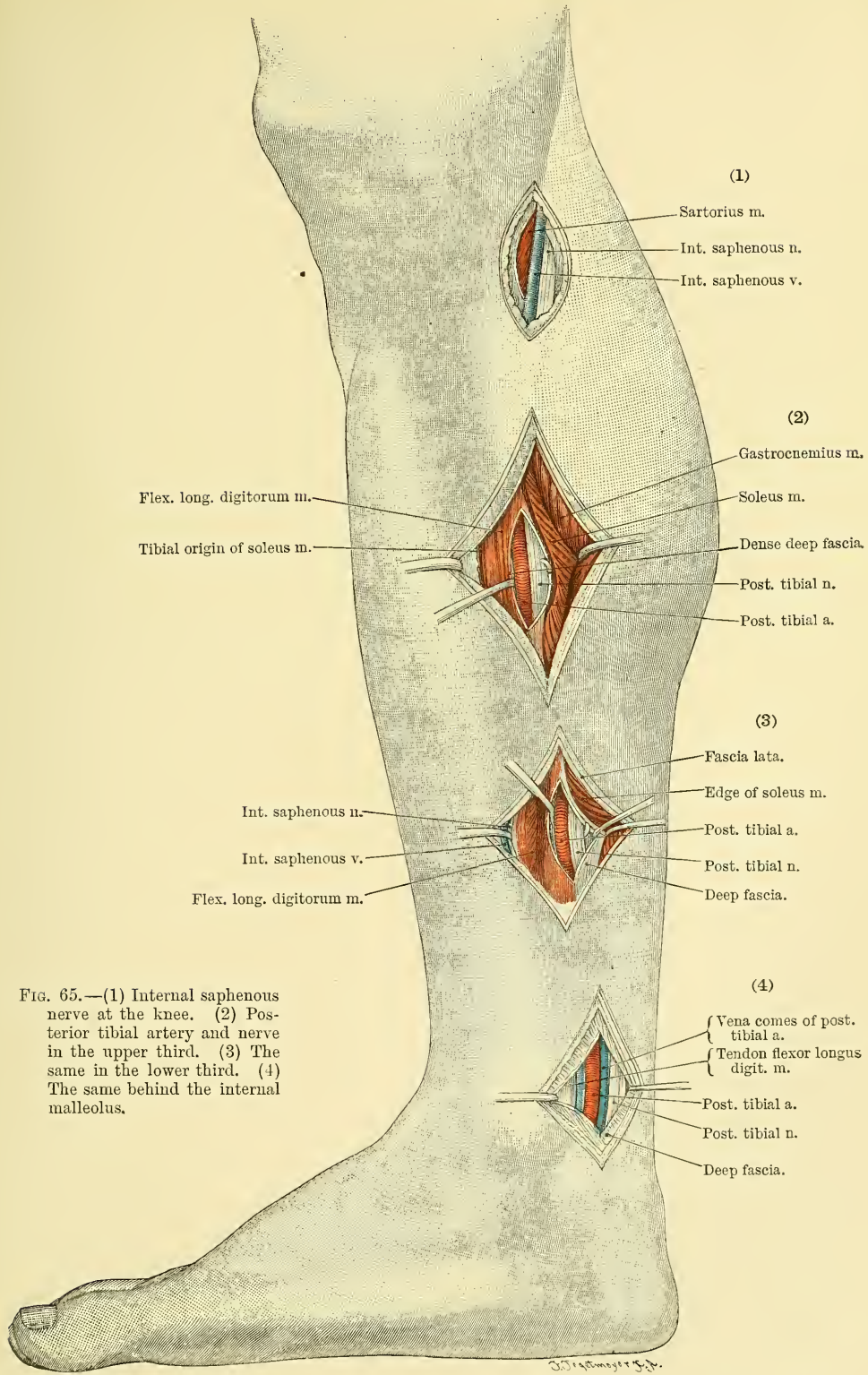

FIG. 65.—(1) Internal saphenous nerve at the knee. (2) Posterior tibial artery and nerve in the upper third. (3) The same in the lower third. (4) The same behind the internal malleolus.

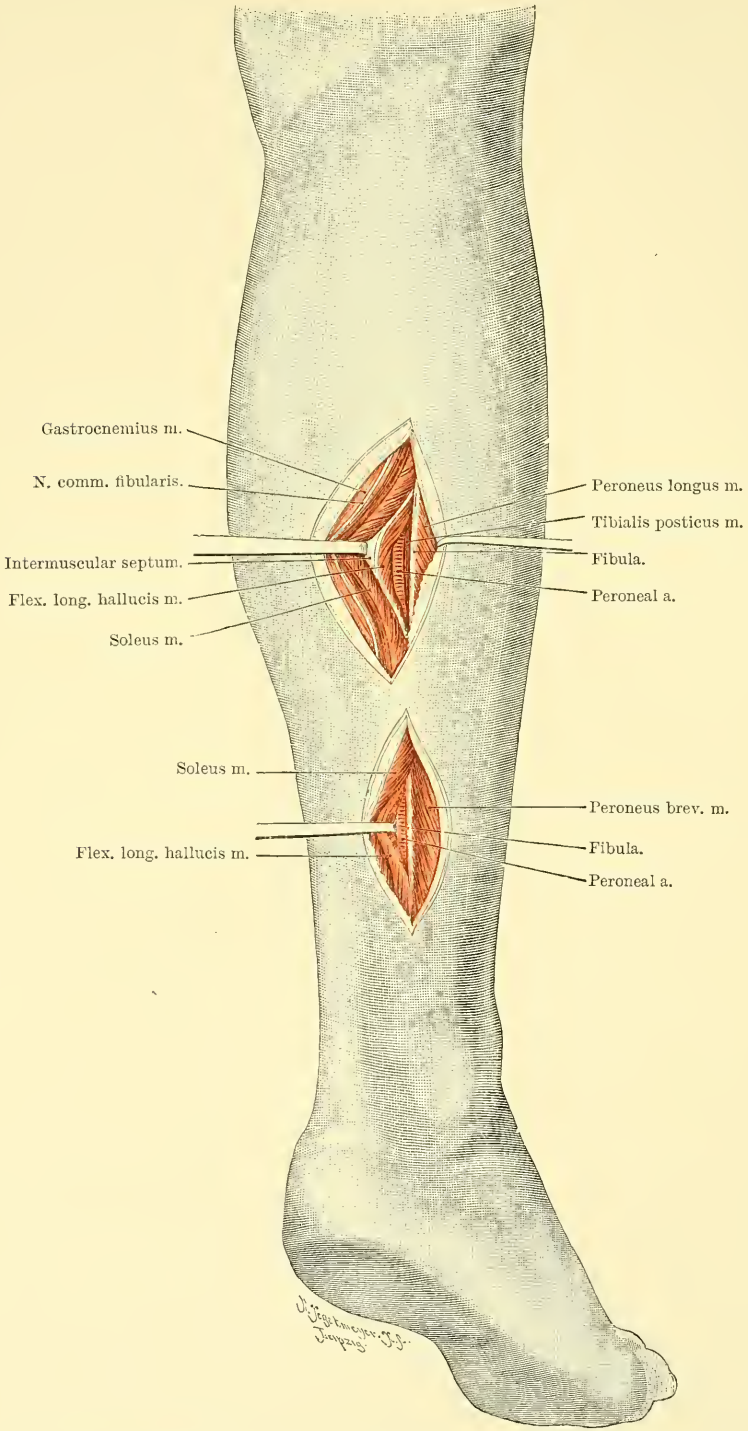

FIG. 66.—Ligature of peroneal artery in the middle and lower third of the leg (postero-external aspect).

79. Ligature of the Peroneal Artery (Fig. 66). The course of the vessel is indicated by a line continued from the popliteal artery down along the inner part of the posterior surface of the fibula. The posterior surface of the fibula may be felt through the skin along the whole length of the leg. The incisions for ligaturing the artery are made along a line drawn from the posterior border of the head of the fibula to a point midway between the external malleolus and the tendo Achillis.

(*a*) *In the upper half.* Incision is made behind the muscular projection of the peronei muscles down to the posterior surface of the fibula, which can be readily felt. The nervus communicans fibularis is observed running downwards along the outer border of the gastrocnemius, the soleus lying deeper. After division of the fascia covering the soleus the muscle is separated by blunt dissection from the posterior surface of the deep fascia (ligamentum intermusculare posticum), until the peroneus longus is exposed on the fibula external to the soleus. The deep fascia is now divided and raised from the posterior surface of the fibula along with the muscular part of the flexor longus hallucis, until the groove between the fibula and the tibialis posticus is reached. The artery runs nearly vertically downwards on the latter muscle.

(*b*) *At the junction of the middle and lower thirds.* Incision is made on the posterior surface of the fibula. The fascia between the soleus and the peroneus brevis (on the fibula) is split and the soleus retracted outwards, and after dividing the fascia (Lig. intermusculare posticum) covering the flexor longus hallucis, we dissect the latter off the posterior surface of the fibula, thus exposing the fascia which covers the tibialis posticus under which the artery has its position.

(o) Arteries of the Foot

80. Ligature of the Dorsalis Pedis Artery (Terminal Branch of the Anterior Tibial) (Fig. 67). The course of the vessel is indicated by a line extending from midway between the two malleoli to the hinder end of the first interosseous space.

At the ankle-joint. The skin is divided longitudinally midway between the two malleoli. The internal branch of the musculo-cutaneous nerve is seen running in the direction of the incision, and is drawn outwards. The fascia, along with fibres of the anterior annular ligament, is divided over the tendon of the extensor longus hallucis (here partly muscular), which is drawn inwards. The artery is now exposed, the anterior tibial nerve lying upon its outer aspect.

Below the ankle. An incision is made along the line already mentioned. The inner branch of the musculo-cutaneous nerve which lies upon the fascia is drawn outwards. Under the fascia lie internally the tendon of the extensor longus hallucis, and externally the innermost tendon and the muscular fibres of the extensor brevis digitorum, which on being drawn downwards and outwards exposes the artery which lies beneath it upon the tarsal ligaments. The anterior tibial nerve is upon the outer side of the artery.

Where it dips down into the first interosseous space. An incision is made through the skin and fascia between the bases of the first and second metatarsal bones. The internal branch of the musculo-cutaneous nerve is avoided and drawn outwards along with the internal saphenous vein. Internally is the innermost tendon of the extensor brevis digitorum, and still farther inwards the broad tendon of the extensor longus hallucis. The artery, with the cutaneous termination of the anterior tibial nerve lying upon it, appears from beneath the outer edge of the extensor brevis tendon, and gives off the large first dorsal interosseous branch.

The small branches of the dorsalis pedis, viz. the tarsal and metatarsal arteries, the latter forming an arch on the dorsum of the foot, may have to be ligatured in accidental wounds of the foot.

Of the branches to the toes only the dorsalis hallucis artery requires consideration. It is the continuation of the dorsalis pedis in the first interosseous space.

81. Ligature of the Plantar Arteries (the Terminal Branches of the Posterior Tibial Artery). (*a*) *Below the internal malleolus* (Fig. 68). The posterior tibial

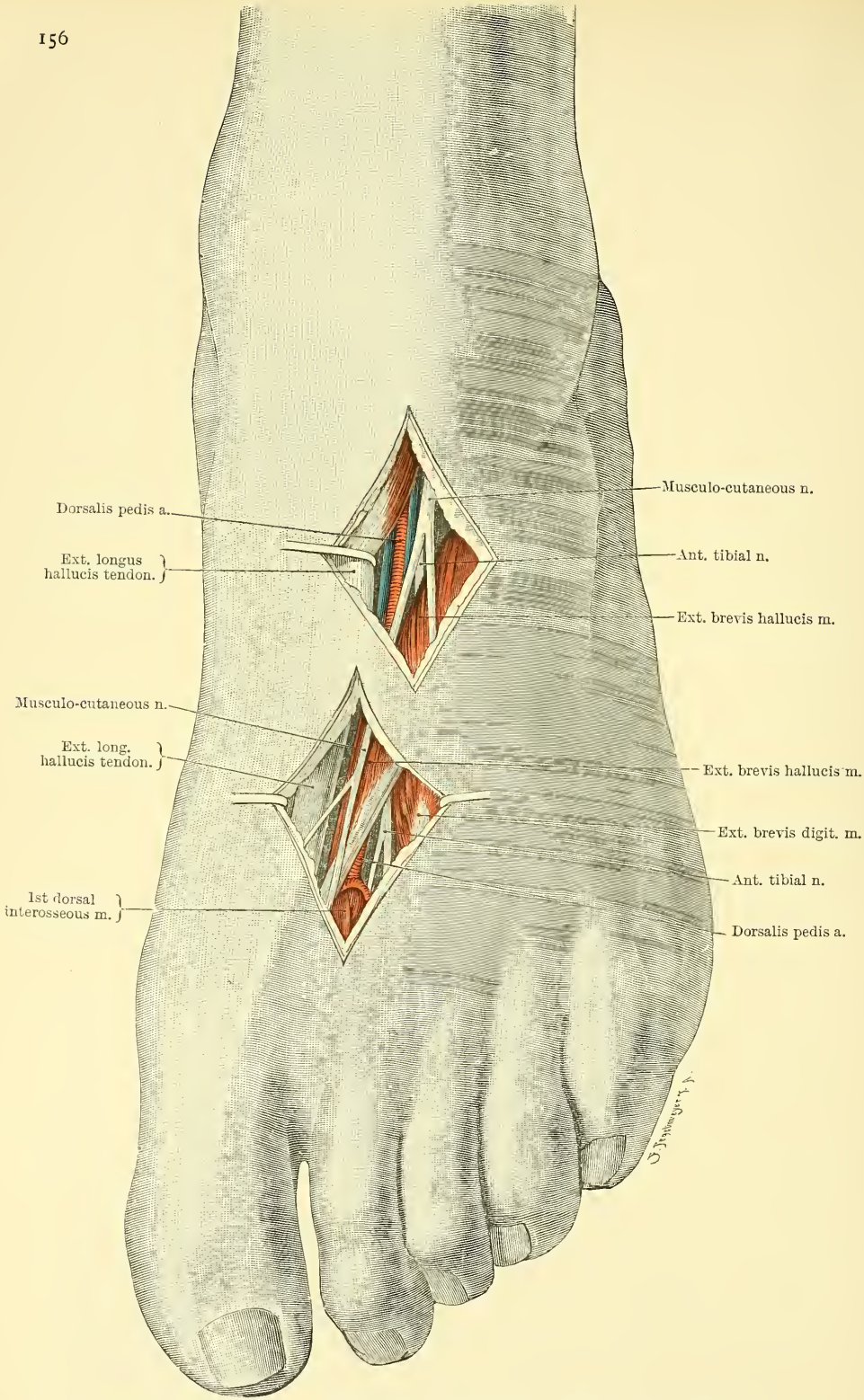

FIG. 67.—Dorsalis pedis artery, with anterior tibial and musculo-cutaneous nerves.

artery is the parent trunk of the two plantar arteries, and may be termed the arteria plantaris communis. An incision is made beginning a finger-breadth below and in front of the sustentaculum tali is carried horizontally backwards along the inner border of the foot above the prominence of the abductor hallucis muscle. After division of the skin and fascia the abductor hallucis is exposed, and separated downwards from the subjacent deep fascia. On dividing the latter we find the plantar vessels opposite a line continued downwards from the posterior border of the internal malleolus. The posterior tibial nerve lies immediately below the artery.

(*b*) *Internal plantar artery* (Fig. 69). An incision is made in a line from the point of the heel to the great toe, beginning in front of the ball of the heel and extending forwards. The skin, a thick layer of fat, and the dense longitudinal fibres

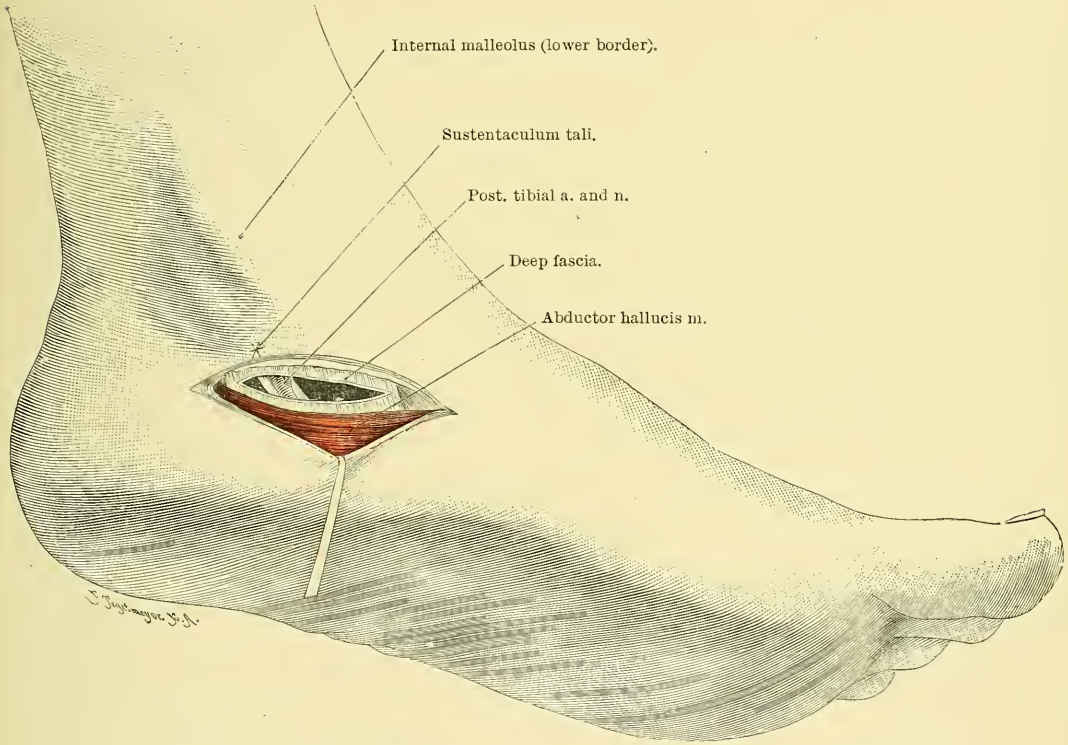

FIG. 68.—Plantar arteries at their origin from the posterior tibial artery. Posteriorly, the posterior tibial nerve.

of the plantar fascia are divided. The muscular substance of the abductor hallucis is exposed, and the artery is found passing under it into the sole. The flexor brevis digitorum lies external to the artery.

(*c*) *External plantar artery* (Fig. 69). An incision is made from immediately in front of the ball of the heel forwards in the direction of a line from the point of the heel to the fourth toe. On division of the skin, abundant fat, the strong plantar fascia, and the muscular fibres of the adjacent edges of the flexor brevis digitorum and abductor minimi digiti are exposed, with the artery lying between them.

(*d*) *The plantar arch at the first interosseous space* (Fig. 69). An incision is made backwards in the hollow outside the ball of the great toe, in the direction of a line from the second toe to the point of the heel, through skin, abundant fat, and the strong plantar fascia. Upon the inner side of the wound is the tendon of the flexor longus hallucis along with, posteriorly, the muscular fibres of the abductor hallucis,

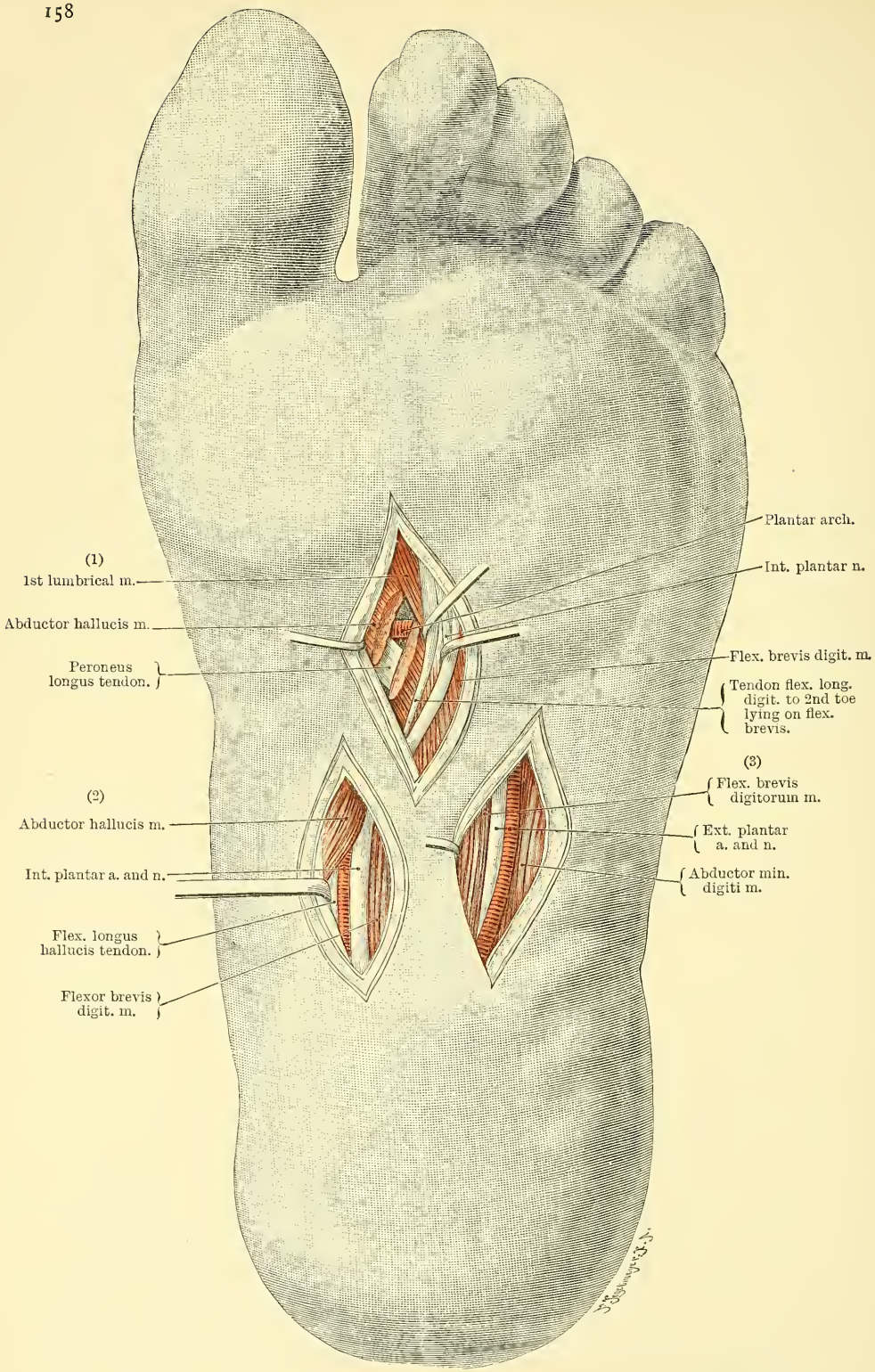

FIG. 69.—(1) Plantar arch. (2) and (3) Internal and external plantar artery and nerve.

and, anteriorly, those of the flexor brevis hallucis: these structures are drawn inwards. Upon the outer side of the wound is the large internal plantar nerve with its branches to the second and third toes : these are drawn towards the little toe. The nerve to the great toe does not come into view. The short flexor tendon of the second toe and the subjacent long flexor tendon with the first lumbrical muscle are exposed and drawn outwards, the powerful adductor hallucis muscle which lies still deeper being then exposed. After cutting through this muscle the artery will be found lying deep at the first interosseous space where it joins the dorsalis pedis artery. The artery lies upon the interosseous muscles. To the inner side of its termination is the projecting border of the first metatarsal bone, to the base of which is inserted the tendon of the peroneus longus muscle.

C. SURGERY OF THE VENOUS SYSTEM

(a) General Indications for the Exposure and Ligature of the Larger Veins

Veins are now exposed and ligatured much more frequently than was the case in former years. A vein, like an artery, has to be ligatured for the arrest of hæmorrhage, but, owing to the low blood-pressure in a vein, bleeding is much more easily arrested by pressure or plugging than is possible with an artery.

In the case of an injury to a large vein, it is often unwise, and indeed impracticable, to apply a ligature. For example, there is considerable risk in ligaturing such veins as the superior and inferior venæ cavæ, the common iliac, the innominate, or even the femoral vein, and to a less extent the subclavian and jugular veins. In these cases plugging, when properly applied, is generally sufficient.

We have on more than one occasion successfully dealt with the hæmorrhage following a wound at the junction of the jugular and subclavian veins by means of plugging. This injury is most liable to occur in the course of the removal of a malignant gland (secondary to carcinoma mammæ) situated in the angle between the two veins. Similarly, when the occasion arises, the internal jugular vein can be plugged with safety at its exit from the skull (jugular foramen), when it has to be divided in excising malignant growths which reach high up in the neck.

We have observed, however, that when plugging is adopted in cases of this nature, especially if the central end of the circulation remains open, serious complications often arise from the displacement of thrombi into the heart and lungs with the production of infarcts and gangrene. Suture should therefore be substituted for plugging whenever possible.

Injuries of all large veins on the cardiac side of the common femoral and subclavian veins should be dealt with by suture. In consequence of the low blood-pressure in the veins, wounds in the latter heal satisfactorily after suture. According to Jacobsthal,[1] Czerny was the first (1881) to adopt suture of a vein in man ; while a year later Schede published a series of cases and brought the operation into general repute. We have adopted it successfully in the case of the innominate vein, at the junction of the internal jugular and subclavian veins, using for the purpose a continuous suture of fine antiseptic silk. A small wound may be dealt with by holding up the edges of the rent with forceps and passing a ligature round them. Tichow[2] has made a study of the process of repair following suture of veins.

Apart from the control of hæmorrhage, ligature of veins is chiefly undertaken to produce artificial changes in the circulation, ligature of the saphenous vein for varicose veins in the lower extremity being one of the best-known and most widely performed operations. Ligature of veins may also be undertaken for the cure of

[1] *Samml. klin. Vorträge*, 1905.

[2] *Centralbl. f. Chir.*, 1895.

varices elsewhere. In the lower extremity the object of ligature is to relieve hydrostatic pressure.

The superior longitudinal sinus is ligatured for the cure of epilepsy, a method of treatment recently advanced and recommended by Delagenière.

Carrel [1] has recently shown that a portion of a vein can be utilised to replace a defect in an artery by means of a plastic operation, the former being sutured between the two ends of the artery. Carrel and Guthrie [2] have even suggested that in cases where an artery is obliterated, the circulation may be reversed and gangrene prevented by uniting the central part of the artery with the peripheral part of the vein. We here reproduce two diagrams from Carrel's work, for the use of which we are indebted to Harvey Cushing, who further states that the outer wall of the interpolated portion of vein rapidly undergoes considerable hypertrophy.

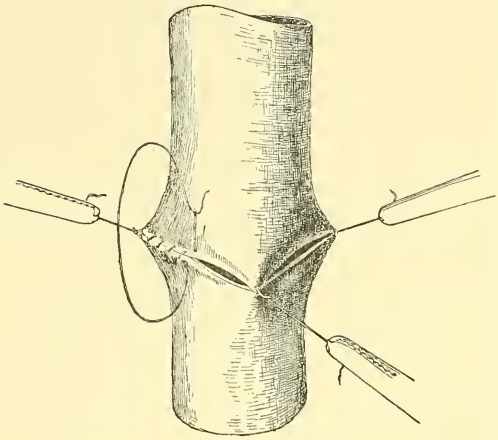

FIG. 70. — Technique of end-to-end arterial suture (Carrel). The lumen of the artery is converted into triangular shape, and the finest silk and needles are used. The cut ends are simply united with a continuous suture.

Figs. 70 and 71 show how Carrel prevents stenosis of a vein after suture. By means of three traction stitches the lumen of the vessel is opened out in a triangular form and stitched with the finest linen thread (Valenciennes lace) or 500 Alsatian cotton (Cushing) or the thinnest China silk thread on the finest needles (Kirby 13-14, Cushing 15-16). The tunica intima is not included in the case of larger arteries. Carrel has in this way successfully performed end-to-end as well as end-to-side anastomosis both in arteries and in veins, and has even been able to transplant whole organs (kidney, thyroid), and even invert the arterio-venous circulation.

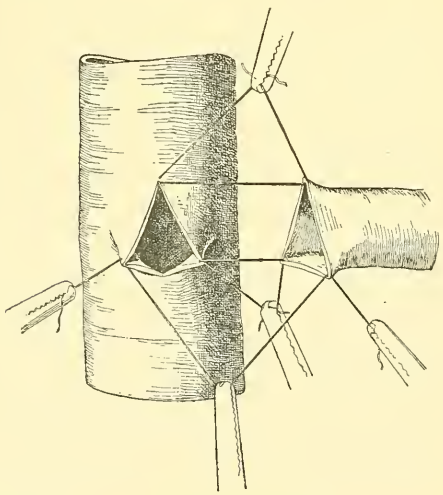

FIG. 71.—Technique of end-to-side arterial anastomosis. From a sketch by Cushing.

According to Jacobsthal, Lambert, an English surgeon, first suggested arterioraphy, while Hallowell in 1759 was the first to carry it to a successful issue. He closed a wound in the brachial artery by means of a circular stitch inserted over a steel needle. After repeating the earlier experiments of Gluck, Postemsky and Horoch, Jassinowsky has perfected the technique of arterioraphy by experiments on the aorta and carotid, while Murphy and Dorfler have proved the advisability of including the intima in the suture.

After Murphy had discovered the invagination method in the case of vessels which had been cut transversely, Payr perfected the technique of the operation by

[1] *Technique opératoire des anastomoses vasculaires*, etc., Lyon, 1902.
[2] *Annals of Surgery*, Feb. 1906.

stripping back the artery wall over a small magnesium ring slipped over the proximal end, so that the endothelium projects and can be approximated with the endothelium of the distal end (intussuscipiens), to which it is joined by suture. After circular resection of the femoral artery (Kümmel, 5 cm.), Murphy and Kümmel have obtained union of the ends of the vessels by invagination, without interfering with the lumen of the vessel. Permanent arrest of hæmorrhage was secured in 33 out of 35 cases of lateral arterial suture.

Apart from injuries, thrombosis is an equally important indication for operation. Two classes of cases must be recognised. In the first the chief indication is to restore the circulation by removal of the clot, *i.e.* by incision of the vein, and removal of the thrombus with subsequent suture.

In the second class, which is even more important, the object is an urgent one, and consists in the immediate removal of the thrombus in order to prevent its displacement, with subsequent ligature or suture of the vein. The majority of surgeons are, as a rule, too supine with regard to this class of case, for whenever thrombosis occurs in a vein (most commonly in the lower extremity) there is always the extreme danger of the clot becoming suddenly detached, with the production of embolism in the pulmonary arteries.

Whenever, therefore, a large vein becomes thrombosed, there is always the attendant risk of this catastrophe, which may occur unexpectedly and prove suddenly fatal, and the question of arresting it by cutting down and removing the thrombus must always be borne in mind.

The removal of infective thrombi is quite as important as that of an aseptic one, which is only dangerous on mechanical grounds. At the present time, their removal is mainly practised in connection with otitis media. It is the lateral sinus and the internal jugular vein which are most commonly explored and ligatured or plugged when they have been attacked by infective inflammatory processes. Hitherto surgeons have been too timid in the early treatment of infective thrombosis in the veins of the extremities and trunk. Such conditions require drastic measures. The results of ligature of the pelvic veins in puerperal conditions (Bumm) are so satisfactory that even here the evil consequences of infection can be prevented by active measures.

(b) Exposure, Suture, and Ligature of Individual Veins

82. Exposure of the Superior Vena Cava. Suture of the superior vena cava may have to be considered in the case of wounds involving the first two right intercostal spaces. In its upper portion the vena cava is covered on the right by the pleura, while lower down it lies within the pericardium. It can be reached by resecting the second costal cartilage in the manner described under exposure of the heart. The sternum must be turned back as a flap, however, if good access is to be obtained to the vena cava and both innominate veins.

Figs. 72, 73, and 74 show the method of osteoplastic resection of the manubrium sterni necessary to expose the upper part of the anterior mediastinum. Even in the event of closure of the superior vena cava an anastomosis would be established through the connections of the innominate, jugular and subclavian veins. Closure of the superior vena cava has in fact been observed on several occasions (Houzel).

Resection of the manubrium sterni for suture or ligature of the superior vena cava is performed as follows: A transverse incision (Fig. 72) is made down to the bone along the episternal notch crossing both sternal ends of the clavicles. The periosteum is freed, the communicating arch between the anterior jugular veins being avoided, and the sterno-clavicular joints are opened, after which the left pectoralis major is detached from the sternum along with the periosteum, for the latter manœuvre a vertical incision being carried downwards over the first and second left costal cartilages.

A transverse incision is then made at the level of the second costal cartilage, and the first and second costal cartilages are separated from the perichondrium and

divided. The bone having been raised with a strong hook, the capsule of the left sterno-clavicular joint is cut through posteriorly, after which the periosteum is detached from the posterior surface of the manubrium with a raspatory, so that the latter can be divided at the junction of the manubrium and body without injuring the pleura and internal mammary vessels (Fig. 73).

The portion of the sternum is then raised with a hook and turned over to the other side (Fig. 74). By this procedure the first and second right costal cartilages break at the junction with the bone.

The periosteum on the posterior surface of the manubrium is now carefully opened in the middle line, by which means we expose on the right and left of the sternum, the internal mammary vessels descending on the pleura and surrounded by some fatty tissue and small glands.

If proper care is exercised, the two layers of pleura can be pushed to either side. The remnant of the thymus gland is seen occupying the middle line and resembling a mass of fat accompanied by veins. Below it, the ascending arch of the aorta is observed. Above the latter and at the level of the first rib the left innominate vein passes transversely outwards, while to the right near the aorta a portion of the superior vena cava is noticed. A large thyroidea ima vein enters the left innominate from above. The retracted pleura forms the vertical boundaries, right and left, of this anterior part of the superior mediastinum.

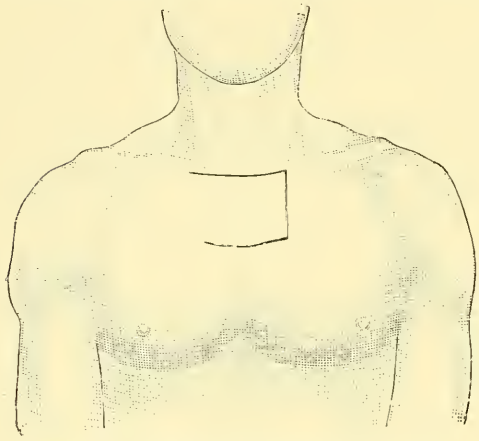

FIG. 72.—Incision for osteoplastic resection of the manubrium sterni.

83. Ligature and Suture of the Inferior Vena Cava.[1] Goldmann[2] has recently made careful investigations regarding ligature of the inferior vena cava in connection with special cases. The vein is most likely to be torn in separating tumours of the right kidney (Lindner). Occasionally the rent in the vein has been stitched (v. Schede, v. Zoege, Busse, Grobe, Garrè). In Schede's case the right renal vein was cut too short in the excision of a malignant kidney. He, however, closed the opening in the side of the vena cava with fine catgut, the wound becoming completely cicatrised in four weeks without any thrombosis and with only slight narrowing of the lumen. In v. Zoege's case (nephrectomy for malignant disease of the kidney) a rent in the inferior vena cava 9 cm. long and $2\frac{1}{2}$ cm. broad, was successfully closed by suture.

Whenever one has to deal with tumours of the kidney which are at all adherent, the incision should always be made sufficiently large to allow of the vena cava being sutured, *i.e.* the peritoneum should be freely opened and the relations of the growth to the vena cava determined, as Heresco and v. Zoege advise. Notwithstanding this precaution, it is not always possible to suture the vein, and ligature may have to be employed. Goldmann refers to the excellent results which Houzel, Heresco, Albarran, Bottini and Hartmann have obtained by this means. Lindner, indeed, regards the vena cava in the same light as all other large veins in the body, *i.e.* not only can it be ligatured, but it can also be excised when adherent to tumours or thrombosed.

It must be pointed out, however, that the above remarks only apply to the vena cava below the entrance of the renal veins, as ligature above this point is fatal. According to Goldmann, this has been proved by Gosset and Lécène, while Purpura

[1] Cf. Niebergall, *Deutsche Zeitschr. f. Chir.*, 1892, Bd. 33. Schede, Langenbeck's *Archiv*, Bd. 43, 1892. Houzel, *Revue de Chir.* Bd. 23.

[2] *Beiträge zur klin. Chir.* Bd. 47, 1905.

has found experimentally that death need not occur, if, from an already existing stenosis of the vena cava, a collateral circulation has been established.

Goldmann quotes 112 cases of thrombosis of the vena cava observed by Vimont. In these the congestion was more marked (œdema and ascites) than after ligature and closure of the vena cava. In the latter the symptoms of congestion may be

FIG. 73.—Osteoplastic resection of the manubrium sterni. The sterno-mastoids are detached from the sternum and turned upwards, the sterno-clavicular joints opened, and the capsule on the left side is detached from the sternum. The first and second costal cartilages are then divided close to the sternum, and the sternum is cut across with a chisel below the level of the second cartilage.

absent. Injection experiments by Lappe, Poirier, Goldmann, and others, have shown that after ligature of the inferior vena cava the blood is returned to the heart

without difficulty and, that of the numerous auxiliary anastomoses in existence, the veins in and about the spinal canal, in the groin and the azygos veins, are the principal channels by which it is effected.

It would seem, therefore, quite legitimate to ligature the vena cava below the renal veins, and even to resect a portion of its length. A case has recently been

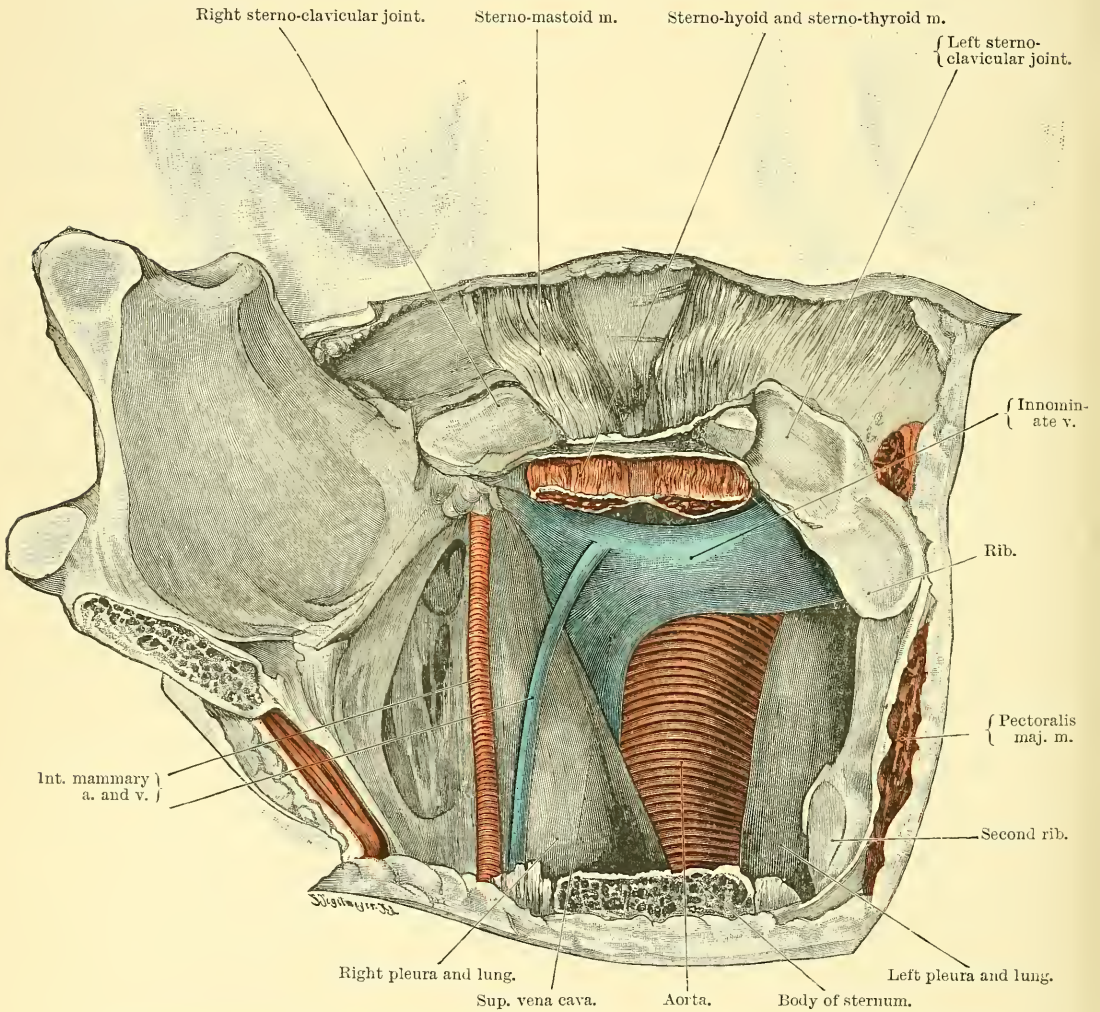

FIG. 74.—Osteoplastic resection of manubrium sterni. The sternum is turned over to the right side. The depressors of the larynx are seen detached from the back of the manubrium. The right and left pleuræ and lungs are exposed bounding the anterior mediastinum.

described by Houzel in which the initial disturbance in the circulation was perfectly compensated.

84. Ligature and Suture of the Innominate Veins. During the removal of deep-seated tumours in the neck, especially in intrathoracic "struma," severe hæmorrhage is often encountered from the tearing of deep veins (thyroidea inferior and ima). The bleeding from these veins can be temporarily arrested by pressing the bleeding-point, or the left innominate vein, against the posterior surface of the sternum, while it can be permanently controlled by plugging, where ligature is not possible.

Jordan reports two cases of wounds of the innominate vein in which recovery occurred. Ricard also reports a case in which a wound in the right innominate vein, accidentally produced during the removal of malignant glands, was successfully treated by lateral suture, while a case of Brohl's in which the left innominate vein was ligatured (excision of sarcoma) also proved successful, in the latter case temporary resection of the clavicle being performed.

If we take into account that even thrombosis of the vena cava superior is tolerated, provided it develops slowly, it is not so surprising that unilateral ligature or even excision of one innominate vein is possible owing to the large cross anastomosis between the veins of the neck. In Brohl's case, not the smallest disturbance was noted after excision of the innominate, internal jugular and subclavian veins and the thoracic duct.

Occlusion of the innominate vein by ligature is well tolerated even when there has been no preliminary stenosis to establish a collateral circulation. Goldmann refers to two cases (Heinecke and Bardenheuer) reported by Ziegler, and also one of his own, in which (like a case reported by Plucker) ligature (or resection) was undertaken owing to the spread of a tuberculous process to the wall of the vein. Both cases recovered.

It is of great importance to know that recovery can occur in these circumstances, for, in dealing with glands and other tumours ("struma") situated at the inlet of the thorax the surgeon is very often in grave doubt as to whether operation is justifiable. There is one gland in particular, the removal of which we have several times found very troublesome on account of bleeding. It is situated in the angle between the jugular and the subclavian vein at the point where the external jugular, and on the left side the thoracic duct enter. In such cases it is satisfactory to know that when the hæmorrhage can be arrested by plugging, one may proceed to ligature the innominate together with its tributary veins.

Ligature of the innominate vein is, however, in the presence of adhesions not always possible without a preliminary division of, or an osteoplastic operation on, the clavicle, the first and second costal cartilages, or the manubrium sterni. The large projecting sternal end of the clavicle is a troublesome impediment. An incision similar to that for excision of the manubrium sterni is made in the suprasternal notch, and prolonged along the clavicle on one side only. The sterno-clavicular attachment of the sterno-mastoid muscle is divided, the joint capsule opened, the articular end of the clavicle raised up, the costo-clavicular ligament divided, and the clavicle pulled forcibly downwards. If this fails to give sufficient access, the first costal cartilage must be divided and pulled downwards and outwards. If still further room is required, the second costal cartilage and the junction of the manubrium with the body of the sternum must be divided and a flap turned back similar to that for ligature of the vena cava.

Tributaries of the Innominate Vein

85. Ligature of the Thyroidea Ima Vein. Of the smaller branches of the innominate vein, especially those from the anterior mediastinum, the vertebral, deep cervical, internal mammary, superior intercostal, and thyroidea ima veins, only the latter have any practical significance as regards ligature. The thyroidea ima vein is often ligatured in goitre operations and the performance of low tracheotomy.

In opposition to anatomical descriptions, we consider "venæ thyroideæ imæ" and not "inferiores" the only proper designation for the veins which descend from the isthmus and lower pole of the thyroid gland, as their course closely corresponds to that of the thyroidea ima artery, while the inferior thyroid artery is accompanied by an exceedingly small inferior thyroid vein.

The thyroidea imæ veins anastomose freely with one another and form a plexus (Plexus, thyr. impar.). One or two main trunks can, however, be readily isolated on one or other side of the middle line, for the control of hæmorrhage. To expose

them an incision is made above the sternum (longitudinal or transverse) dividing the skin and the fascia connecting the sternothyroid muscles in the middle line.

86. Ligature of the "Common" Jugular Vein. In surgical nomenclature the internal jugular vein of the anatomists is called the common jugular vein, in order to distinguish it from that portion of the internal jugular vein above the entrance of the common facial vein, and we do not see why this nomenclature (proposed by Krause) should not be adopted by anatomists.

Ligature of the "common" jugular vein is one of the most important in the chapter on ligature of veins, not merely because it is very frequently wounded, *e.g.* in the excision of malignant tumours, but also because it has often to be ligatured in dealing with infective conditions in its tributary areas, especially in connection with certain complications of otitis media. The "common" jugular is more easily ligatured than the internal jugular vein ; but in order to avoid the risk of embolism, it is only adopted when the thrombus already extends farther down, otherwise the internal jugular above the entrance of the common facial vein is to be ligatured.

As a rule, the "common" jugular vein can be tied on one side without any fear of serious congestion. Fatal disturbances of the cerebral circulation occur only in exceptional cases.

In only one out of 91 cases collected by Rohrbach[1] did death result from softening of the brain, the case being one in which the lateral sinus was most abnormal. It was of a diminutive size, while the jugular vein of the opposite side was also so small that the escape of the venous blood from the cranium was considerably interfered with. Cases have also been recorded by Linser[2] (from Brun's clinic) and Kümmel. From an examination of a number of skulls, Linser found a very small jugular foramen present in 3 per cent (generally on the left side).

It seems indicated that special consideration should be paid to the "common" jugular vein, especially the right, so that lateral suture may be substituted for ligature where practicable. It is admitted that this cannot be done in cases of resection for malignant disease. Schede's experiences show that lateral suture of these veins is a very safe operation. Sometimes the vein may even be opened to remove an infective or malignant thrombus and then be stitched up again. Jacobsthal collected 10 cases of suture of the jugular vein.

The common jugular vein is exposed in the same way as the common carotid (*vide* No. 3, Fig. 28). It lies to the outer side of the common carotid artery, According to Goldmann, Dangel has reported a case of bilateral ligature of the "common" jugular vein with only temporary disturbance of the circulation

Tributaries of the "Common" Jugular Vein

87. Superior Longitudinal Sinus of the Dura Mater. Bleeding from wounds of this sinus may be controlled by plugging, which is often the only method possible. This also applies to the cavernous sinus (*e.g.* wounds during extirpation of Gasserian ganglion).

Bleeding from the superficially situated sinuses can be dealt with by ligature, *e.g.* the superior longitudinal, the lateral (on one side) and the occipital sinus. Ligature of the superior longitudinal sinus has further been recommended by Delageniere as a cure for epilepsy, a fact which also proves that no risk is attached to the operation. For the method of performing the operation, we refer to the chapter on trephining.

88. Ligature of the Lateral Sinus. Of the intracranial vessels, the lateral sinus, next to the middle meningeal artery, is most frequently the object of surgical interference. The sinus on one side is often divided and ligatured in exposing cerebellar tumours, particularly those situated in the angle near the pons.

The sigmoid portion of the sinus is opened in inflammatory conditions of the tympanic cavity and mastoid cells when the wall of the sinus has been involved, and infective thrombosis and pyæmia are threatened.

[1] *Bruns Beiträge*, Bd. 17. [2] *Ibid.* Bd. 28.

The sinus is reached by trephining over it, when it is incised, cleared out, and plugged. (See chapter on trephining.)

89. Ligature of the Occipital Sinus. The small mesial occipital sinus which extends from the Torcular Herophili to the foramen magnum is ligatured in extirpating cerebellar tumours (*vide* chapter on trephining the cerebellum).

90. Ligature of the Spheno-parietal Sinus. This sinus, which occupies a groove in the bone behind the coronary suture, and which opens into the cavernous sinus, may give rise to troublesome bleeding if wounded in trephining over the temporal region. It may require double ligature.

91. Diploic Veins. Occasionally in the course of trephining, severe venous hæmorrhage may arise from injury to a larger diploic vein, in which case the bleeding can only be controlled by plugging. The veins of the diploë are devoid of valves, and communicate by emissary veins with the sinuses of the dura mater and with veins outside the cranium.

92. Ligature of the Superior and Inferior Ophthalmic Veins. When the orbit is opened from without on account of orbital cellulitis, the question of ligaturing the veins in the orbit, which empty mainly into the cavernous sinus, and to a slight extent into the pterygoid plexus, may arise in order to prevent the backward extension of an infective thrombus, above all to the sinus.

93. Ligature of the Internal Jugular Veins. The internal jugular vein is ligatured during the extirpation of tumours situated high up in the neck, more especially carcinomatous and sarcomatous glands. As a rule, a ligature can be applied at the base of the skull, *i.e.* just below the jugular foramen, without any evil effects.

Occasionally, however, the tumour reaches so near the base of the skull that plugging alone is possible. Plugging is in these cases quite reliable, owing to the presence of the bone, and secondary hæmorrhage seldom occurs.

Madelung in a dissertation[1] collected 11 cases of ligature of the internal jugular vein, in none of which bad results were observed. It is better, however, to follow Schede's advice, and close the vein by lateral suture if possible, when it has only been cut into or partly resected. Schede's results from this operation have been uniformly good.

Ligature of the internal jugular vein plays a very important part in connection with the treatment of complications of otitis media, more especially thrombosis of the lateral sinus. Its object is to prevent the production of embolism from the detachment of an infective clot.[2] It is definitely indicated whenever trephining the mastoid process and clearing out the sinus do not suffice to dispel the signs of general infection.

The operation is performed according to the rules given for ligature of the external carotid (*vide* No. 5 and Fig. 29). The common facial vein is exposed and the ligature is applied at a higher level, provided no thrombus has already extended into the common jugular vein. The common facial or its two tributaries, the anterior and posterior facial veins, seldom call for separate ligature.

94. Ligature of the External Jugular Vein. There is one important point in connection with ligature of the external jugular vein. The vein opens in the angle between the common jugular and subclavian veins (*i.e.* into the innominate vein). Injuries in this situation are apt to be followed by aspiration of air as the mouth of the vein is kept open by the cervical fascia.

Ligature of the vein low down is therefore a necessary precaution, when division higher up cannot be avoided in the course of an operation. The position of the orifice of the vein corresponds closely to the origin of the sterno-mastoid muscle from the clavicle, behind which it lies.

The vein is always divided in operations on the neck in which our normal incision is used (*i.e.* from the mastoid process to the hyoid bone). Accompanied by the great auricular nerve, the vein runs vertically downwards on the outer surface of the sterno-mastoid muscle (*vide* Fig. 29).

[1] Schewen, Rostock, 1887.

[2] Cf. Heine, *Operationen am Ohr*, Berlin, 1904.

95. Ligature of the Anterior Jugular Vein. This vessel, which terminates in the external jugular vein, must be remembered when dividing the sterno-mastoid muscle at its origin. The vein lies behind the muscle.

The anterior jugular vein is much more frequently ligatured in the course of operations in the middle line of the neck where it lies under cover of the platysma. It is systematically tied in goitre operations in which the transverse curved incision is employed (*q.v.*).

96. Ligature of the Subclavian Vein. Next to the "common" jugular, the largest tributary of the innominate is the subclavian vein.

Suture of the subclavian vein should always be preferred to ligature. Schede mentions two cases in which suture was successfully performed, and not long ago we employed a lateral suture in a case where the vein was accidentally torn in the course of the removal of malignant glands. Plugging may also be employed, but it is not to be advised on account of the risk of a clot becoming detached and giving rise to pulmonary embolism.

The vein has, however, been successfully ligatured. A description of the procedure is given in No. 17 and Fig. 36. It must be remembered that the subclavian vein crosses the first rib in front of the scalenus anticus, while the artery passes behind the latter. This makes ligature more difficult on account of the clavicle, especially somewhat externally.

97. Ligature of the Axillary Vein (*vide* Figs. 42-44). The axillary vein is frequently ligatured, *e.g.* in excision of malignant glands adherent to it. The vein lies in front of and to the inner side of the artery. (For its exposure, see the method illustrated in Figs. 42-44.)

98. Ligature of the Veins of the Arm. It is unnecessary to give a special description of the technique for ligature of the veins of the arm, as they pursue a course similar to that of the arteries, with the exception of the cephalic, basilic, and median veins. They, however, rarely require to be ligatured specially, though, perhaps, insufficient attention is paid to the indications for preventing displacement of clot in severe infective conditions of the arm. Their superficial position renders their recognition easy in the forearm or elbow for bleeding or transfusion. The median vein is most frequently selected for this purpose (cf. No. 31 and Fig. 4).

Branches of the Inferior Vena Cava

99. Ligature and Suture of the Common Iliac Vein. Ligature of the common iliac vein is only employed in cases of extreme necessity or where, in consequence of long-continued pressure on the vein, a collateral circulation has been already established. All circumscribed injuries to the vein should be closed by suture.

The vein is exposed by a similar procedure to that for the corresponding artery (*vide* No. 53 and Fig. 53). The left vein lies behind and on the inner side of the artery, while the right vein lies behind the right artery.

100. Ligature of the Hypogastric Vein (Internal Iliac). Ligature of the internal iliac vein is not so serious an operation as is that of the common iliac vein. It is undertaken to prevent the development of puerperal pyæmia in cases where the uterine venous plexuses are thrombosed. Bumm[1] successfully ligatured both internal iliac and ovarian veins in a case of this description, while Trendelenburg had previously carried Freund's suggestion into practice. Bumm's operation was performed intraperitoneally, a method which allowed him to determine exactly the position and extent of the thrombosis. For the technique of ligature of the hypogastric vein, see Internal Iliac Artery (No. 54, Fig. 53).

101. Ligature of the Common Femoral Vein. As a result of Braun's observations,[2] which showed that the femoral vein was almost the only outlet for the blood from the lower extremity, ligature was for a long time carefully avoided. The researches of Kammerer, Niebergall, and Jordan, however, agree with v. Bergmann's

[1] *Ges. f. Geburtsh.*, Berlin, Nov. 1904. [2] *Die Oberschenkelvene*, etc., Leipzig, 1871.

experimental investigations in showing that the risk of gangrene is very slight (only three cases are known), although it is, of course, much greater if the common femoral artery is also tied.

When both the artery and vein are wounded, an attempt must be made to close the vessels by suture, as has been done successfully by Schede. When the vein only is wounded, no ill effects are, as a rule, to be expected from ligature, although suture is a safer method.

102. Ligature of Tributaries of the Femoral and Internal Iliac Veins. There is no particular interest attached to the exposure and ligature of the veins of the lower extremity and gluteal region, as each vein is exposed in the same way as for the corresponding artery. In the case of infective thrombosis and thrombo-

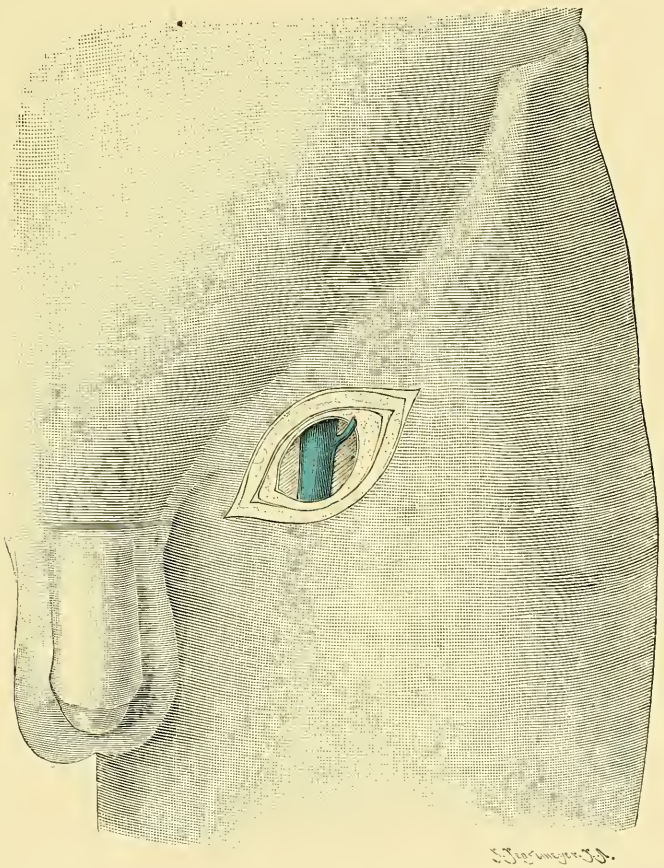

FIG. 75.—Ligature of the long saphenous vein, below where it opens into the femoral vein.

phlebitis, which is so often met with in the deep veins of the calf, more attention should be given to the question of ligaturing the vein high up (*e.g.* the popliteal vein) so as to prevent infective embolism. The long saphenous, and to a less extent the short saphenous vein differs from the other veins in the lower extremity in that it is superficial and does not accompany any artery.

103. Ligature of the Long Saphenous Vein. Of all the veins, the long saphenous is the one most frequently ligatured at the present time. Ligature is undertaken for varix, as a result of the results published by Trendelenburg in 1891.

In the milder forms of varicose veins a complete cure can be obtained by ligature, although in very advanced cases this is not possible. Goerlich[1] obtained permanent

[1] *Beitr. z. klin. Chir.* Bd. 44.

cure in only 27 per cent of his cases; while in 79 per cent improvement or disappearance of the symptoms was noticed.

In the more aggravated cases total excision of the varicose veins (Madelung) gives excellent results. Partial excision of the main convolution, an operation we have performed several times, is also satisfactory. According to Stein, Müller obtained only 50 per cent of good results with Trendelenburg's operation, but 86 per cent with Madelung's.

In very aggravated cases, Tavel[1] has secured satisfactory effects by producing artificial thrombosis in the veins after ligature by means of injections of 5 per cent carbolic (from 1 to 39 injections).

The risk of thrombosis and embolism must never be forgotten, and the operation must be avoided in patients who are the subject of other diseases, or who are debilitated or elderly. We have known a patient to die suddenly from pulmonary embolism the day he was allowed out of bed three weeks after partial excision of a bunch of veins and ligation of the vein above.

The long saphenous vein may with advantage be ligatured for the cure of phlebitis, the upward extension of the thrombosis being thus prevented.

The vein is ligatured immediately above the thrombosed part, when it is opened and the clot removed. Muller of Rostock[2] has reported 20 cases of this description.

In the case of a varix, on the other hand, the operation aims at relieving the hydrostatic pressure. The indication here is to ligature the vein high up, in order to prevent the transmission of the pressure by side branches.

Procedure. (*a*) *Above.* The position of the common femoral artery having been determined by its pulsation, the femoral vein is found, lying to its inner side. An incision is made over the vein parallel to the inner part of Poupart's ligament (Fig. 75). The long saphenous vein pierces the thin cribriform fascia, covering the saphenous opening, to open into the common femoral vein. The lower falciform edge of the fascia lata over which the vein runs should be defined. Care must be taken to see whether the vein is not double, in which case a second ligature is required.

The old operation of percutaneous or subcutaneous ligature is unsatisfactory, for one cannot then tell if the vein is not double, and the ligature cannot also be applied sufficiently high.

(*b*) *At the knee* (see Fig. 65). To expose the vein an oblique incision is made below the internal tuberosity of the tibia on the antero-internal aspect of the limb. The saphenous nerve accompanies the vein. As the position of the vein is not always constant, an oblique incision is more advisable than the longitudinal one shown in Fig. 65.

104. Ligature of the Short Saphenous Vein. Where there are communicating branches between the short saphenous and the long saphenous veins, the former may have to be tied immediately below the point at which it enters the popliteal vein. It is also ligatured in acute infective conditions of the area which it drains.

A vertical incision is made in the popliteal space similar to that for ligature of the popliteal artery (Fig. 62). The vein is found lying on the fascia between the two heads of the gastrocnemius accompanied by the communicans tibialis nerve.

105. Ligature in the Portal Area. As the portal vein is only ligatured for wounds during the course of a laparotomy, no special description of the technique need be given here. Whether more active measures than have hitherto been taken should be adopted in cases of thrombosis, and above all of infective thrombosis, further experience alone can tell.

Ligature of the portal vein is, according to Ito and Omi, fatal, unless a collateral circulation has been previously provided by such measures as omentofixation or Eck's fistula, in which an anastomosis is made with the inferior vena cava. Ligature of the portal vein gives rise to degenerative processes in the liver, which are, of course, capable of compensation.

106. Ligature of the Superior Mesenteric Vein. Mayo Robson (according to Goldmann) has successfully ligatured the superior mesenteric vein for injury. As a rule, however, serious disturbances in the intestinal area follow ligature of the vein.

[1] Dissertation by Stein, 1902. [2] *Ibid.*

SECTION III

SURGERY OF THE NERVOUS SYSTEM

Introduction

The surgery of the nervous system has now become to a large extent the work of specialists, and requires a long course of careful study. There are, however, certain operations with which every practitioner, not to say every surgeon, ought to be thoroughly familiar, and it is the duty of a text-book on surgery such as this to deal with the technique necessary for such cases.

In a recent article by Harvey Cushing,[1] the present position of the surgery of the nervous system was made the subject of review, and it was shown that the pessimistic attitude adopted by many neurologists towards the surgical treatment of nervous diseases no longer holds good. It is quite unjustifiable nowadays that a patient, who is suffering from increased cerebral pressure with headache, vomiting, and initial blindness, should be left to his miserable fate merely because the physician cannot assure himself regarding the localisation of the original lesion. The effect of intracranial tension must be relieved by operative measures before the stage of blindness commences, if the patient's lot is to be appreciably ameliorated.

A special protest must be lodged against the old routine method of treating every case in which the question of syphilis arose with a prolonged course of iodides, as by this procedure valuable time is only wasted. Cushing recounts the case of a patient who died suddenly under this treatment, and in whom the cause of death was found to be an easily accessible gumma in the situation in which it had been originally diagnosed.

The worst symptoms of disease of the central nervous system are attributable purely to physical and mechanical conditions, as increased tension within the rigid walls of the cranial cavity exerts an injurious and paralysing effect on the central nerve apparatus. Surgery is able, however, to interfere in various ways and reduce this so-called cerebral pressure. It is reprehensible, therefore, not to avail oneself of operative measures immediately the symptoms of pressure make their appearance. Increase of intracranial pressure is readily recognised, and is described in detail in every text-book, both in its chronic and acute form, while every practitioner ought to be familiar with its symptoms. It can be demonstrated by means of puncture, and Albert Kocher has described the very simple procedure that is used in our clinic for this purpose. Quincke has further proved the great advantages of lumbar puncture in regard to the diagnosis and treatment of cerebro-spinal diseases.

In the following pages we shall consider the methods of operating for the relief of tension in the brain and spinal cord.

[1] "The Special Field of Neurological Surgery," March 1905, *Bulletin of Johns Hopkins Hospital, Baltimore.*

A. METHODS OF EXPLORATION AND RELIEF OF CEREBRAL TENSION

1. Puncture of the Skull and Brain. (*a*) *General Remarks.* Neisser and Pollack[1] deserve great credit for their excellent work on puncture of the brain in the diagnosis and treatment of nervous conditions. The authors have drawn attention to the insufficient notice that is taken of these important diagnostic aids in text-books on medicine and neuropathology. House physicians, on the other hand, make extensive use of the procedure, and we know of one medical teacher who systematically punctures with a needle every abdominal effusion, and recommends the advisability of the method to his students. Puncture of the abdomen is, however, much more dangerous than puncture of the brain, as in the former there is the risk of the operator wounding the intestines or other viscera, whereas in the latter there is little fear of him producing any injury if the operation is properly performed.

It is advantageous to adopt a correct method of procedure. Neisser and Pollack attribute the introduction of cerebral puncture for collections of fluid, to Middeldorpf and Maas. Middeldorpf published his investigations on the subject in 1856, and Maas advocated puncture, especially in cases of abscess, as a preliminary to further operative measures. Gibier and Spitzka were the first to make injections into the brain through drill-holes in the skull, while Souchon[2] as a result of numerous experiments laid down the technique in 1899. Schmidt,[3] as a neurologist, deserves the credit for having called attention to the advantages to be derived from surgical exploration, especially in connection with cerebral abscesses originating in otitis media. Schmidt regards the dangers of exploratory puncture as of the slightest description. On the other hand, v. Bergmann has issued a warning as to the risk of puncture with aspiration, while Payr,[4] again, pins his faith to the use of large instruments to puncture with in cases of tumour. It is obvious, therefore, from this discrepancy of opinion that definite restrictions must be established. We shall first, however, consider the technique of exploratory puncture.

Albert Kocher[5] has described the method usually employed in our clinic. The patient is prepared as if for trephining, the scalp being shaved, and thoroughly purified with soap and hot water, and afterwards with ether and alcohol. Fifteen to thirty minims of a 1 per cent solution of novocain, to which two drops of a solution of adrenalin have been added, are injected underneath the epicranial aponeurosis down to the bone, and a sterilised drill is then applied at the desired point, which has been previously determined by a craniometer or by other landmarks, and is driven through the skin down to the bone. The bone is then gently bored through, the operator employing less force according to the depth reached by the instrument. In this way there is no risk of the drill being plunged into the dura after the inner table of the skull has been penetrated.

Once the drill has been applied, it must be kept strictly in the line in which the needle is to be inserted. It must also be withdrawn in the same direction as it was introduced, so that the skin will not occlude the opening. The needle of an exploring syringe, 7 cm. long, is then pushed through the dura in a similar direction. The best instrument to employ is a sterilised "record" syringe fitted with a metal piston, and holding 15 or at most 30 minims. If Schimmelbusch's metal syringe is used, a glass connection must be attached to it in front in order to ascertain if the fluid escapes.

Pignaud's case, which is quoted by v. Beck and instanced as a warning by v. Bergmann, has demonstrated that the fluid must never be forcibly withdrawn, as otherwise dangerous bleeding may result. The object of exploratory puncture is simply to prove the presence of fluid; and only the smallest amount should be

[1] "Die Hirnpunktion," *Grenzgebiete der Medizin u. Chirurgie*, Bd. 13, 1904.
[2] Souchon, *New Orleans Med. and Surg. Journal.*
[3] Schmidt, *Arch. f. klin. Chir.* Bd. 45, 1893.
[4] *Centralbl. f. Chir.*, 1896, No. 31.
[5] *Centralbl. f. Chir.*, 1899, No. 22.

withdrawn. Absolute asepsis is also essential, while the needle must be fine and the syringe well fitting, forcible or excessive aspiration being avoided, if puncture is to be free from danger.

Neisser and Pollack employ an electric drill which they also use for boring through the soft parts, finding that it is no more dangerous than the hand-drill in regard to injury of the dura, and post-mortems on cases which they treated have revealed as little injury as we have found in those which came under our own observation. There is certainly nothing to contraindicate the use of a drill driven by an electromotor, although the fact that Neisser found splinters on the cortex of the brain in three cases would seem to defend the employment of the less rapidly acting hand-drill. The latter has the advantage of being always available, and with a little care the risk of its sudden penetration of the brain can be entirely avoided.

The limit to which exploratory puncture can be carried will be observed from the following brief description of the technique. If the nature of the case cannot be determined by the withdrawal of ½-1 c.cm. of fluid through a fine needle, a larger opening in the skull must be obtained. It is only after exposure of the surface of the brain that large exploring instruments can be safely employed, or that an injury can be immediately rectified if it occurs deep down in the wound. Trephining is so safe and so simple an operation, if a small trephine or Doyen's burr is used, that it is only the greater inconvenience entailed on the patient by the preliminary preparation, and the fact that an anæsthetic is required, that influences an operator in favour of the boring operation we have described. Those who are not satisfied unless large scoops, exploring needles, or spoons are used, must take advantage of a larger drill-hole.

Our method of procedure is eminently suitable, and does not necessitate an incision, when it is desired to make an injection into the brain or lateral ventricles, as, for instance, in the Roux-Borrell treatment of tetanus, in which anti-tetanic serum is injected directly into the brain. A fine needle is required, as the injection must be given as slowly as possible.

(*b*) *Special Indications for, and Technique of, Puncture of the Brain.* A surgeon who has once had the experience in the post-mortem room of finding that his patient succumbed from a collection of blood, pus, or other fluid in a perfectly accessible part of the skull, will never again fail to puncture the brain if there is the slightest suspicion of the conditions we have referred to being present, no matter whether the symptoms are localising or merely those of general cerebral pressure (acting at a distance on vital centres). Paresis, fits, disturbances of sensation, with irritability or apathy, slow or irregular and accelerated pulse, respiratory disturbances of the Cheynes-Stoke or of some similar type, and choked disc with or without symptoms of a definite focus, are all signs which suggest a collection of fluid and which render it imperative to employ cerebral puncture for diagnostic purposes.

Neisser and Pollack refer to their own experiences in a dozen cases, in some of which an unexpected diagnosis of extra- and intra-dural hæmorrhage was arrived at, while in others great relief was obtained by simple puncture followed by aspiration. Further, it is in patients in the advanced stage of cerebral compression, who have severe pressure symptoms, that puncture is especially indicated, for in their case the ordinary trephining operation is too severe, and at the same time relief may be so urgently called for that the delay necessary for the preparation for a larger operation might prove fatal. An operator need then have no hesitation in deciding to perform cerebral puncture, which can be completed in the course of a few minutes with a drill and exploring syringe.

In such cases the exploratory opening of the skull may be undertaken with Doyen's burrs, or in the simple form suggested by us and practised by Neisser and Pollack. As we have already pointed out, whenever there is a risk of puncturing large vessels or where more information is required than mere confirmation of the presence of fluid, a large instrument must be employed for opening the skull. The drill is the classical instrument for this purpose. It never fails, causes no concussion, and enables one to rapidly remove bone, to open the dura, and to examine the surface

of the brain. If it is necessary, the opening can be rapidly enlarged with cutting forceps.

Hæmorrhage from the edges of the bone can always be controlled by means of plugging with wax. The opening itself causes no harm, as, if it is aseptic, it readily closes.

Doyen's drills are well constructed and very serviceable instruments for boring a small hole down to the inner table, after which the opening can be rapidly enlarged with the spherical burr depicted in Fig. 77 (the point of which is blunt) without risk of injury to the vessels in the dura. With a small spoon, sharp only at the sides, the opening in the inner table can be enlarged to the same size as that in the outer table.

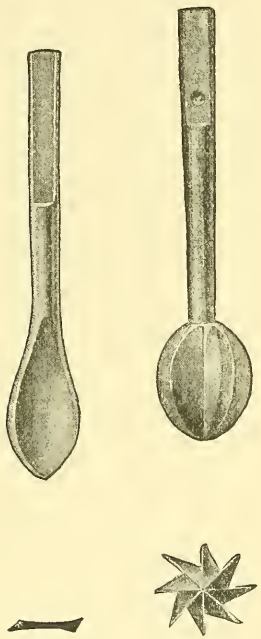

FIG. 76. FIG. 77.

Doyen's burrs. That represented in Fig. 76 is used for drilling the hole into the vitreous, while the opening is enlarged with the instrument shown in Fig. 77.

Having removed sufficient bone, if no extra-dural lesion is found, the operator picks up the dura with fine, sharp hooks and a crucial opening is made in it with the knife. The surface of the brain can then be investigated, or, if necessary, examined more deeply with a large exploring needle or grooved director, without danger to the large vessels. In this way it is easy to prevent the occurrence of small extravasations (size of a hazel nut) which Neisser and Pollack observed occasionally after simple puncture. The advantages of the simple operation, in which the drill is inserted through the thicker tissues, are undoubted, *e.g.* in puncture of the posterior cerebral fossa, a procedure which has proved thoroughly successful in the hands of Neisser.

On the other hand, if there is reason to suspect the presence of a tumour, the second operation is more advisable, although Neisser and Pollack localised a frontal tumour by simple puncture, the diagnosis of which would otherwise have been impossible. It must be admitted that if simple puncture or the modification which we recommend for tumours is sufficient to establish the nature of the case, either is of a trifling description in comparison with the osteoplastic operation, and further the truth of Neisser and Pollack's views will be confirmed that even repeated puncture is justified if the approximate position of the tumour can thereby be determined. In Neisser's historic case puncture was performed nine times, in the course of which the tumour was disclosed twice.

To avoid repetition, the reader is referred to the chapter on cranial topography, in which the correct points for puncturing the brain for suspected collections of blood and pus are considered. In the diagram which will be found on page 201, the points recommended by Neisser and Pollack for accurate puncture are depicted. They vary to a certain extent, however, in different individuals, just as the treatment does in certain cysts.

On the other hand, the points at which the needle should be inserted in order to reach collections of fluid in the ventricles are quite definite. It is specially useful to ascertain at what points the lateral ventricle can be reached without the necessity of performing an extensive preliminary operation.

When there is an accumulation of fluid under increased pressure in the ventricle, the withdrawal of this is an established procedure, and some striking results have been recorded from simple puncture of the ventricle. The methods of penetrating the ventricle are very differently described. This may arise from the fact that the puncture of a sound ventricle with its minimum contents is very difficult, because the needle may easily wound the walls, so that it is not easy under normal conditions to establish experimentally the best method. It is easy, however, to enter the

ventricle from various places when it contains a collection of fluid. Authorities are agreed that puncture from the lateral aspect should be performed by passing in from behind and above the ear, over a point corresponding to the posterior end of the temporal line, by which route the floor of the ventricle can be readily reached. In this situation (about 3 cm. behind and above the external auditory meatus) Keen, at a depth of 5 cm., could not merely puncture the ventricle but, by an opening on both sides, could even wash it out. He pierces directly towards the summit of the opposite auricle. Mayo Robson, following Frazier, punctures at the posterior part of the first temporal convolution. In a case on which we operated, in June 1891, we made a puncture directly inwards from the posterior extremity of the temporal crest. We were able to withdraw a drachm of bloody serous fluid, but we did not afterwards succeed in introducing a drainage tube, although the needle was very exactly introduced behind the posterior end of the corpus striatum, above the floor of the lateral ventricle, the evacuation of the ventricle being so complete that the walls had fallen together. It appeared to us, therefore, desirable to puncture parallel to the direction of the sagittal diameter of the ventricle, because when the ventricle contains very little fluid the risk is not run of puncturing the opposite wall, as is the case when the puncture is directed transversely. The ventricle in the sagittal direction is of considerable extent. One can puncture in the sagittal plane, which corresponds with the main portion of the ventricle, from the front, from above, and from behind; but in order to avoid the centres of known function, it is best to pass in obliquely from above and in front, or from above and behind.

Puncture of the ventricle from above. We have as a rule made the puncture in a direction downwards and backwards, somewhat in front of the bregma, 2 cm. from the middle line. The needle must penetrate for a depth of from 5 cm. (2 ins.) before it reaches the ventricle, which it will certainly enter if the latter be distended with fluid. In our experience, too, the drainage from above has proved satisfactory, as the drain in this direction runs the least risk of injuring the opposite wall of the ventricle, so long as it is allowed merely to enter the upper portion of the ventricle, its further entrance being prevented by a ring or flange on the surface of the skull.

Neisser and Pollack also speak favourably of the results of puncture at Kocher's point, and have been able on many occasions to reach the ventricle with accuracy where the latter has been either full or empty.

The points Neisser and Pollack recommend for reaching special parts of the brain are considered in the section dealing with cerebral topography.

2. Trephining for Exploration and for Relief of Cranial Tension (Decompression). These two indications for opening the skull are best considered in conjunction, as they both require a similar exposure of the brain. The method of using the simple burr, by which an opening 1 cm. in diameter can be obtained, has already been considered under cerebral puncture, of which the technique practically is similar. Here we refer only to the formation of larger openings such as were exclusively made in former days even for exploration.

Opening into the cranial cavity is one of the oldest of operations, and fairly correct notions as to the indications for it were entertained at an early date, though associated with fantastic ideas. From history we learn that these indications were at one time regarded as very frequent and at another as very rare. To explain why it was thought at certain periods that trephining could not be done too often, while at others it was believed that a surgeon must himself be "off his head" to trephine a head injury, one has simply to refer to the methods of wound treatment. At the time when infection was prevented, though unconsciously, by all sorts of antiseptic balsams and alcoholic dressings there was as much enthusiasm over the success of trephining as there was despair at other times over the unfortunate result of every injury to the brain and its membranes when wound infection was a daily occurrence. Since the introduction of the recognised anti-bacterial wound treatment, and since its complete development in the form of asepsis, trephining, so far as the danger of infection is concerned, has become just as safe as any other form of operation. Trephining, as performed in the old accepted sense, is now regarded as an operation

free from danger; but when the conception of trephining becomes widened to that of craniotomy and craniectomy we are no longer justified in speaking so confidently.

The diploë of the skull bones differs from other bone marrow in the great number of its blood-vessels. There is a copious supply from the abundant small arterial vessels from without and from within, and a still fuller one through the communications between the external and internal veins, which unite with wide and sometimes sinus-like venous spaces in the bone itself. The diploic veins possess even a less degree of contractility than in other bones. Cushing has shown that the diploë can readily be filled by injections introduced into the sinuses of the dura mater. The diploic veins can, on this account, give rise to very severe loss of blood, especially when there is any increased pressure inside the skull which leads to their increased distension with blood.

It can be confidently asserted that, provided asepsis is guaranteed, there should never be any hesitation about trephining in any case of cerebral pressure. We have regretted many sins of omission in this respect, but very seldom have we had occasion to repent the performance of an operation. Every precaution must, however, be taken to prevent severe hæmorrhage and consequent shock.

(*a*) *Arrest of Hæmorrhage during Trephining.* The arrest of hæmorrhage is influenced to a considerable extent by the selection of the anæsthetic. In excitable and restless patients the venous bleeding is increased by forcible expiration. A suitable local anæsthetic has therefore advantages when dealing with intelligent patients, and when only a limited operation is proposed. Otherwise, one must procure deep narcosis with a general anæsthetic.

Braun, in his excellent work,[1] describes a case in which a recurrent tumour of the brain was removed under local anæsthesia only. According to his testimony, even the dura can be rendered insensitive, by infiltrating the tissues down to the bone (Hackenbruch's method). Heidenhain supports the statement that even the bone and dura become quite insensitive within half an hour after the injection of Braun's solution under the epicranium. He has also removed a cerebral tumour painlessly under local anæsthesia.

In small trephining operations we have always found the dura to be insensitive after local infiltration, while the bleeding from the soft parts as well as from the bone is also diminished.

In this connection Braun has demonstrated that when cocain and suprarenin are employed, the hæmostatic effects of the latter constituent are very considerable, although not, however, sufficient in the case of an extensive operation.

Where local anæsthesia cannot be employed, most surgeons of experience regard chloroform-morphia narcosis as the most advantageous, Horsley in particular drawing attention to the disadvantages of ether. As described elsewhere, a cup of hot tea with brandy and sugar is given an hour before operation, a precaution against post-operative collapse and pneumonia which Heidenhain regards as of great importance. Half an hour before operation $\frac{1}{6}$ to $\frac{1}{4}$ gr. of morphia is injected hypodermically, while subsequently the minimum of chloroform is given by the drop method. Cocain or novocain and suprarenin injected at the site of operation accelerates the anæsthesia. They are administered most effectively ten minutes after the injection of morphia. It must also be remembered that chloroform diminishes the hæmorrhage by reducing the blood-pressure, and that there is therefore always the danger of collapse, to avoid which risk ether may be employed, as recommended by Cushing.

Hæmorrhage from the soft parts can be readily controlled, and it is surprising that the simple and effective measures which can be employed for its arrest are not taken advantage of more regularly.

Heidenhain[2] and v. Hacker[3] insert deep overlapping loop sutures through the entire thickness of the divided scalp. But although this checks the hæmorrhage very effectively, it is a method which is by no means easy to adopt. Strong needles are required to transfix all the tissues of the scalp down to the bone, and if a large flap is

[1] *Local Anæsthesia.* Leipzig, 1904. [2] Heidenhain, *Centralbl. f. Chir.*, 1904, No. 9.
[3] v. Hacker, *Centralbl. f. Chir.*, 1904, No. 29.

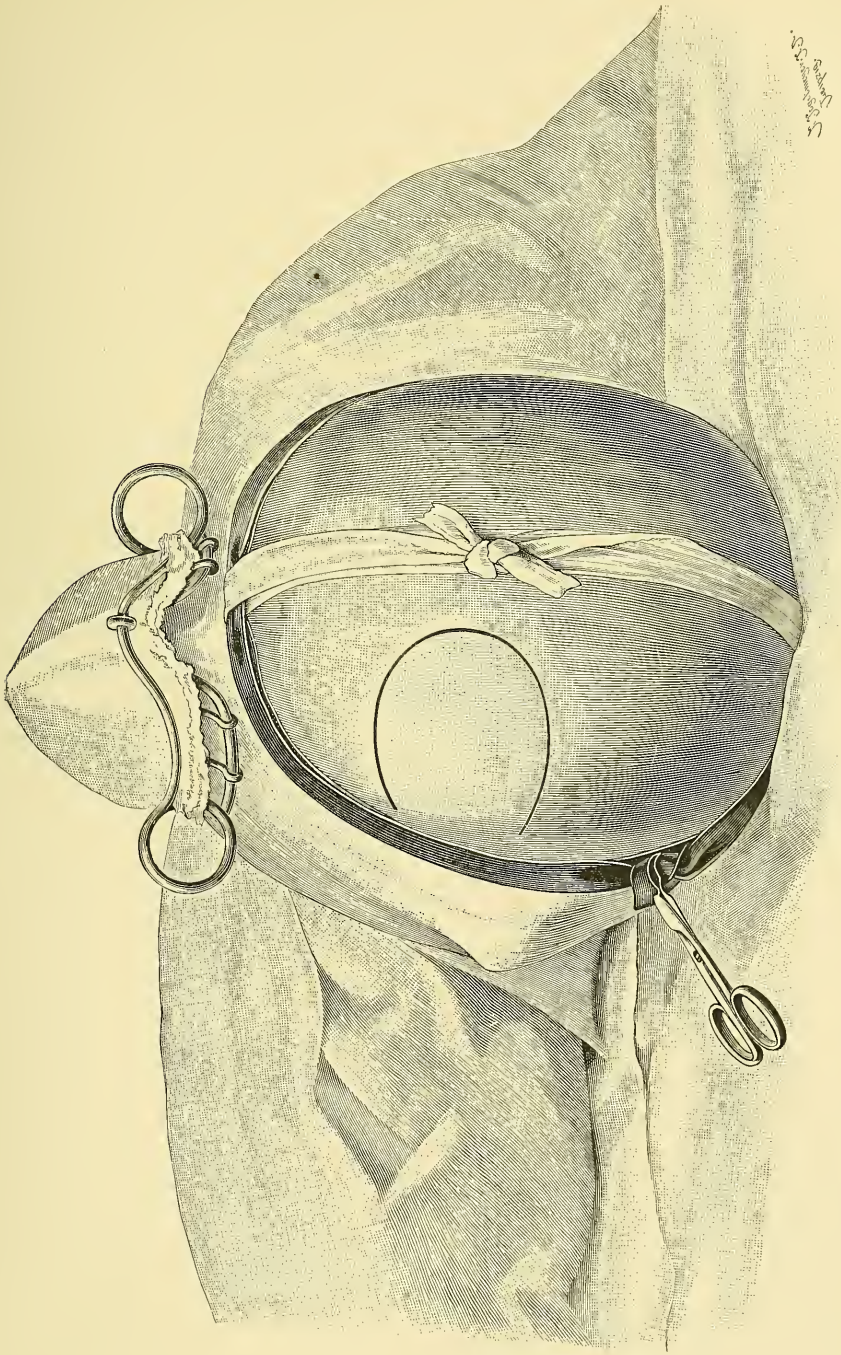

FIG. 78.—Elastic band applied round the skull, at the same time holding the sterilised sheets in position.

turned down, a considerable number of stitch-holes are made and no small amount of strong thread is necessary for this continuous suture.

We have found the method of service in exposure of the cerebellum, when an occipital flap is turned down, but like Hacker we only insert the sutures on the convex (upper) side of the incision, as it is easy to control the bleeding from the flap by pressure on its base and the application of a few artery forceps. Like Heidenhain, we have found that the constriction suture can be retained without any harmful results, even till the wound is healed.

It is quite unnecessary to adopt these measures in the event of the incision being placed above a line joining the glabella to the occipital protuberance, through the attachment of the auricle. The application of Esmarch's elastic band round the greatest circumference of the skull (as practised by Corning and Matas) is much simpler and more effective.

Cushing[1] has described a pneumatic tourniquet which is applied round the head and then inflated, although he has abandoned its use since November .1905, as he found that it could not be submitted to repeated sterilization. He now employs a rubber band, and, to prevent it slipping downwards, he secures it with a bandage passing from the glabella to the external occipital protuberance.

We invariably make use of a strong elastic band about 3 cm. broad, which when stretched is of course of narrower dimensions and which should be knotted at the back of the head, secured with a clamp, and held in position by a gauze bandage reaching from the glabella to the occiput.

The above are the measures to be adopted for the control of hæmorrhage from the scalp during operation. The permanent arrest, however, requires further consideration. At the close of the operation Cushing simply stitches the wound with interrupted sutures and applies pressure by means of a firm bandage. We prefer to close the wound with a continuous suture of strong silk thread including the whole thickness of the scalp. This entirely prevents the possibility of hæmorrhage and does away with the necessity of firm compression, which is not only difficult to apply but in many cases proves unreliable.

Bleeding from the edges of the bone may be more troublesome to control. In our experience we have found that adrenalin injected twenty minutes before the operation (along with novocain) materially diminishes the bleeding even from bone. In any case, it is the large veins which bleed to the greatest extent. According to Frazier of Philadelphia, who has had excellent results in the surgery of cerebral tumours, in operations on the occipital region the emissary veins are sometimes very numerous and present great variations. They may often give rise to great trouble.

No method has yet been discovered by which the hæmorrhage from these veins can be controlled, as they frequently drain off highly congested blood from the interior of the skull. The bleeding is most effectively controlled by plugging the diploë with wax as Horsley recommends. According to Heidenhain[2] the bleeding is materially diminished by the use of rapidly rotating sawing instruments, especially the Cryer-Sudeck burr.

If, as occasionally happens, the bleeding from the bone is so brisk as to be dangerous to life, we have no other choice but to compress (or temporarily ligature) one or both carotids, as Frazier recommends in extreme cases. For this purpose we advise the use of Halsted's metal clamps, instead of circular constriction, as with a metal clamp, the grip of which can be graduated, the large vessels are only partially obstructed, and the danger of severe cerebral anæmia is avoided. We employ small clamps and attach a piece of string to them which enables us to effect their removal even if the wound is practically closed.

The arrest of hæmorrhage from vessels on the dura and the surface of the brain is dealt with in a later chapter.

(*b*) *Partial Circumscribed Craniectomy.* Just as every surgeon ought to be familiar with the method of performing cranial and cerebral puncture, so ought he to

[1] *Med. News*, New York, March 1904.

[2] "Exstirpation von Hirngeschwulsten," *Arch. v. Langenbeck*, Bd. 64.

possess a thorough knowledge of the operation of circumscribed trephining, for in the latter case the indications are generally of an urgent nature, as, for example, in a case of cerebral hæmorrhage with rapidly increasing intracranial pressure.

The appliances already mentioned for the prophylactic arrest of hæmorrhage must always be at hand. (Rubber bandages are best kept in 5 per cent carbolic solution.) It is also advisable to be provided with Braun's novocain and adrenalin tablets, for the production of local anæsthesia, under which limited openings in the skull can be readily effected, and which have a strong influence on the extent of the bleeding.

The old trephine (with a crown about 2-3 cm. in diameter) is still the best instrument when a circumscribed opening in the skull is desired. There is no risk of dangerous hæmorrhage when an opening of this size is made, the wound, if aseptic, ultimately cicatrising very firmly, and ossification taking place to such an extent that one need have no hesitation in entirely removing the disc of bone. On the other hand, the disc may be kept in sterile solution till the completion of the operation when it may be replaced (Cushing).

A longitudinal incision in the soft parts is sufficient for the removal of a small disc of bone, and the bleeding from the edges of the scalp can be completely controlled by forcible traction with sharp hooks. When the inner table has been penetrated the disc of bone is removed with a strong elevator, and the edges are trimmed with a sharp spoon or forceps. Any extra-dural effusion can be reached by pushing a blunt dissector underneath the bone, should evidence of such not be manifest in the circumference of the trephine opening. To open the dura, it should be seized with fine sharp hooks and incised with a delicate knife through both layers (which are easily recognised), parallel to the vessels, and after it has been raised up as much as possible, the blade of a blunt-pointed pair of scissors can be inserted and the opening enlarged to the desired extent, a second incision being then made in it transversely to the first. Any large vessels in the flaps of dura thus formed can easily be caught and tied with catgut, care being taken not to injure the pia mater.

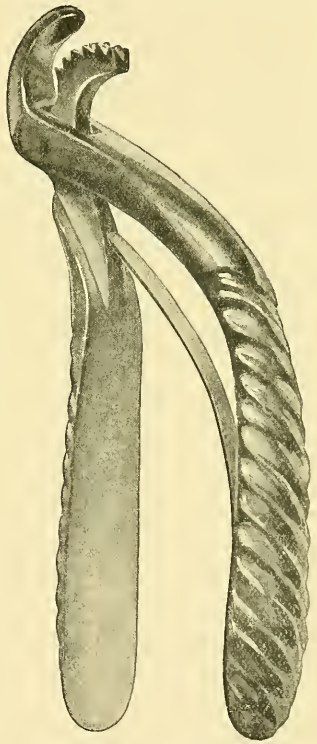

Fig. 79.—Lane's forceps.

The brain can now be probed with a large needle or, if necessary, incised without fear of injuring the vessels on the surface. If more room is required, or if the situation of the trephine opening is not quite accurate, it is easy to enlarge the opening in any direction.

Luer's forceps are the best for this purpose, as they do not cause any concussion or splintering of the bone. In an emergency, or if the skull is particularly hard, the opening can be rapidly enlarged with Lane's powerful skull forceps.

(*c*) *Extensive Resection of the Skull.* Although the above method (limited resection) is still employed for exploratory operations, a more extensive resection of the skull is particularly indicated in the operation of decompression. Here it is necessary to remove a large portion of the skull in order to make room for the cranial contents. The indications for this operation are twofold: (1) To relieve the symptoms of general and local pressure in the case of epilepsy (originally suggested by us and made the subject of careful research in 1893). (2) To diminish the intracranial pressure in cases of new growth.

Two important works have recently appeared, one by Friedrich of Greifswald[1]

[1] Friedrich, "Die operative Beeinflussbarkeit des Epileptikergehirns," *Arch. f. klin. Chir.* Bd. 77.

and the other by Cushing of Baltimore,[1] which afford excellent testimony to the value of operation in the above conditions. Following our advice, Friedrich attacks the bone and dura over the motor area, while Cushing devised an original method (intermuscular method) in which he provides for the expansion of the brain by trephining over the temporal region. Both methods have their own indications. Whenever a large portion of the skull is to be removed, a general anæsthetic is essential. At the same time a local anæsthetic may be also used, while all prophylactic measures for the arrest of hæmorrhage must be efficiently arranged so that the incision in the soft parts can be made without the operator being encumbered by any bleeding. When a straight incision will suffice, it is the simpler method, but a curved or flap incision must be made in cases where a considerable amount of bone is to be removed. Friedrich makes a large skin flap similar to that adopted in Wagner's osteoplastic method. The skin incision must always be made 1 cm. or

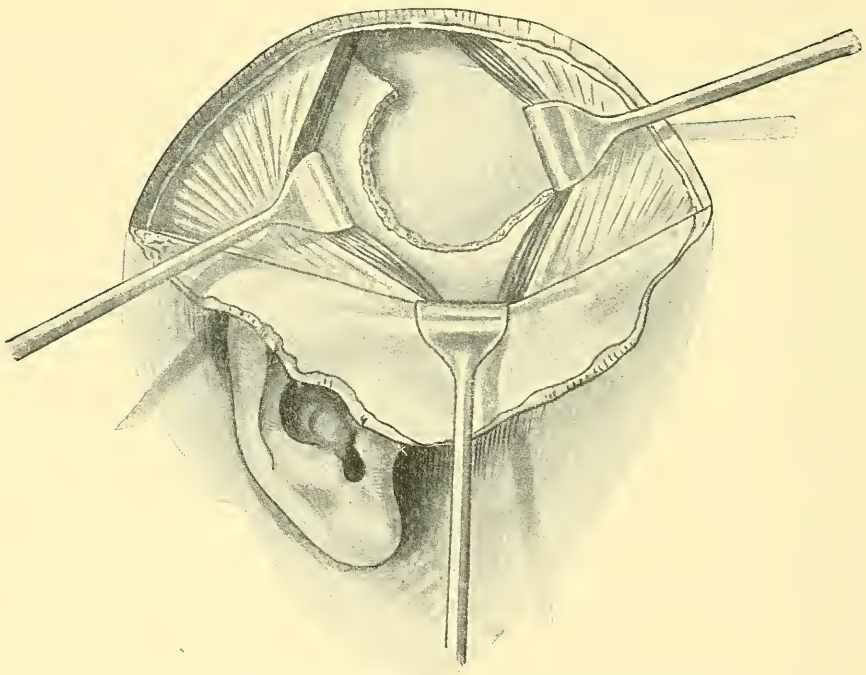

Fig. 80.—Trephining for decompression (Cushing's temporal method).

more outside the circumference of the bone to be removed, and this is still more important when recourse is had to a curved incision (Cushing). The stitches in the skin must never be placed so as to lie over the edges of the bone.

The incision is carried right down to the bone, and the soft parts are raised along with the periosteum with a sharp elevator down to the base of the flap. The layer of muscle must not be injured in any way as it forms an excellent cushion when the soft parts are replaced.

The preservation of the muscles is an important factor in the formation of artificial cerebral herniæ, and is the essence of Cushing's temporal operation (intermuscular) for dealing with cerebral tumours (Fig. 80).

In the latter operation the curved incision only divides skin and fascia which are turned down off the outer surface of the thin temporal fascia. The temporal muscle is incised parallel to its fibres down to the periosteum, the edges are retracted, and

[1] Harvey Cushing, *The Establishment of Cerebral Hernia, etc., Surgery, etc.*, Chicago, Oct. 1905.

the periosteum is separated and removed. Cushing has obtained brilliant results by this method in inoperable tumours of the brain, and enormous cerebral herniæ have been tolerated without giving rise to subsequent ill effects.

When there is no question of replacing them, large portions of bone may be resected in various ways. It may be said on principle that the simplest method is that in which a small opening is first made and enlarged as required (*vide* the previous section). This is the procedure adopted by experienced cerebral surgeons, such as Horsley, Frazier, and Cushing. The initial opening is made with a trephine, although Friedrich uses the Collin-Doyen spherical drill. Whatever instrument is used for making the original opening, suitable forceps must be employed for its enlargement.

Horsley enlarges the opening with a large-sized Liston's cutting forceps which allow of the rapid removal of large pieces of bone. Lane's forceps are equally satisfactory, but if such instruments are used, the primary trephine opening must not be too small. On the other hand, gouge forceps or Dahlgren's forceps (used by Cushing and Krause) or the Cryer-Sudeck burr (used by Friedrich and Frazier) require merely a small drill-hole to begin with.

Sudeck's rotatory burr, which, according to Frazier, had been previously described by Cryer, and other electromotor drills is very convenient and causes less bleeding from the bone than cutting instruments are responsible for. It occasionally fails or proves very troublesome when employed on a hard thick skull. Dahlgren's and de Vilbis's forceps work admirably for thin bones, such as the temporal (in Cushing's operation), but for dense thick bone strong forceps are more reliable. Krause uses an extra strong pair of Dahlgren's forceps. It is advisable, therefore, to have gouge and Lane's forceps at hand as well as the ordinary bone forceps.

Fig. 81.

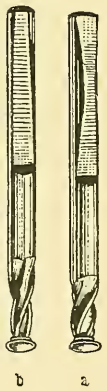

Fig. 82.

Cryer-Sudeck burrs.

To relieve the intracranial pressure, the dura must be removed as well. It is first incised in the manner described for exploration, *i.e.* in the line of the larger vessels, after which it is divided transversely, and the vessels are ligatured. The pointed flaps of dura so formed are then raised and divided round the periphery of the opening, a procedure which affords less risk of injury to the bulging brain underneath it. Friedrich makes an opening in the bone from 4 up to 8 cm. in diameter, and that in the dura from 3 up to 7 cm. Cushing maintains that for the relief of tension and the formation of artificial cerebral herniæ, the dura should be cut away almost to the edges of the bone. As has already been stated, the pia mater must be carefully preserved while removing the dura. Cushing as a rule makes the opening in the bone from 6 to 8 cm. in diameter. With regard to the closure of the wound, Cushing first unites the temporal muscle with interrupted stitches of fine silk and then closes the soft parts over it. The larger the wound, the more essential it is, in our opinion, to use a deep continuous silk suture which includes all the bleeding vessels.

As the exposure of the cerebellum will be considered in a later chapter, the reader is here simply referred to Fig. 83, taken from Cushing's work, illustrating the occipital decompression operation. The incision is made in the form of a crossbow, the arch of the curve being made high up in order to preserve the collateral anastomosis between the occipital and temporal vessels. The vertical limb of the incision reaches down to the spine of the second cervical vertebra, and soft parts and muscles are turned down as far as the foramen magnum.

After removal of the periosteum the thinnest part of the posterior fossa is opened

on both sides, and the opening is enlarged first laterally and then upwards to the lateral sinus and downwards to the foramen magnum. If enlarged towards the middle line, the emissary veins described by Frazier will be encountered and give rise to severe bleeding. The latter are only dealt with when the median bridge of bone is to be removed for the purpose of exposing and ligaturing the occipital sinus.

Cushing also removes the whole of the exposed dura, but expressly states that the

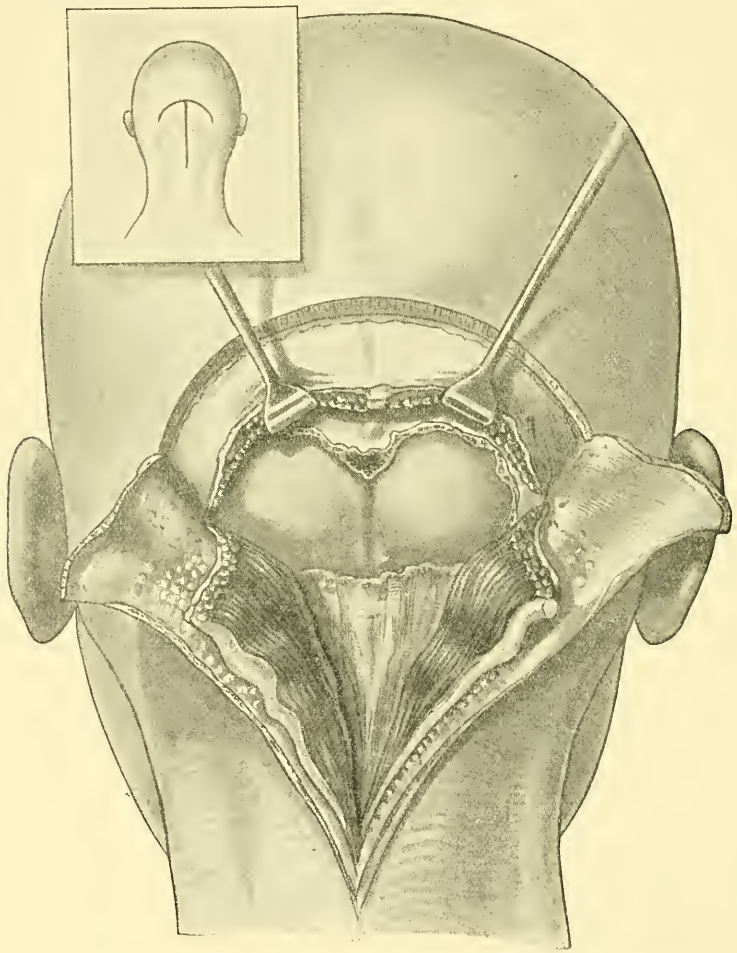

FIG. 83.—Trephining for decompression. Cushing's cerebellar operation.

occipital operation is only to be preferred to the temporal one when there is a prospect of removing a tumour or exposing and removing the original cause of the increased cerebral pressure.

B. OSTEOPLASTIC TREPHINING

3. Osteoplastic Resection of the Skull with the formation of a Flap. Osteoplastic trephining is most commonly undertaken as a preliminary step to operations on the brain itself, be it simply for the application of a ligature or for the removal of a

tumour, etc. The special indications for its use will be discussed subsequently under special heads ; here only the steps of the operation need be described.

Introduced by Wagner, the original method consists in the removal, by means of a horseshoe-shaped or omega-shaped (Ω) incision, of a large flap, placed, as a rule, with its base downwards, and in the formation, with hammer and chisel, of a correspondingly shaped bony flap. This is cut across at its base, and is then turned down, being connected with the rest of the skull merely by the soft tissues, namely, the scalp and the pericranium.

Wagner (Wiemann) preferred flaps measuring on an average 8 cm. (3 inches) high, 7 cm. broad, and 5 cm. (2 inches) wide at the base. Wiemann has recommended for this purpose an angular double-length chisel, bent in the form of a bayonet.

Fig. 84.

The instruments for osteoplastic resection have been perfected by Doyen, special attention being given to those for hemicraniotomy. Doyen forms very large flaps with the base above the ear, bores the bone rapidly in several places with special burrs, and then follows the incision with a circular saw (driven by electricity), possessing a guard which prevents injury to the dura. In this way he is able to turn down an osteoplastic flap in a few minutes. A similarly shaped flap of dura is turned down.

A chisel is now seldom employed except for cutting through the base of the flap, and even then it should be provided with a guard so as to protect the dura from injury. The curved portion of the bony flap is fashioned by drilling a series of holes and dividing the intervening bridges with a chisel, which, of course, should be done expeditiously, as bleeding must be controlled. The hæmorrhage from the drill-holes is slight and may be easily arrested by plugging.

The division of the bone should be carried out rapidly, for the bleeding is greatest at this stage of the operation, and may be so severe as to make the continuation of the operation impossible.

As an osteoplastic resection is as a rule a preliminary step to further operative interference within the cranium, the arrest of hæmorrhage is even more important here than in purely exploratory operations or those performed for relief of tension.

The use of Doyen's electric saw ensures rapidity, but as the dura cannot be sufficiently well protected while handling it, severe bleeding is apt to occur. The method Krause and Cushing recommend may be followed with advantage. By this method a small trephine opening is first made, and the bone, if not too thick, is rapidly cut through with Dahlgren's forceps. Gigli's saw should be used when the bone is thick (Cushing). The saw is passed from one opening to another on a director to protect the dura, or, to follow Frazier's advice, a special opening may be made with the Cryer-Sudeck burr.

Gigli's wire saw, which was modelled on the earlier and more clumsy chain saw, cuts very quickly but is liable to break, so that it is advisable to have a few of the wire saws at hand. The Cryer-Sudeck burrs are much more convenient (Figs. 81 and 82), but require, of course, an electromotor.

The following are the steps of the operation. After a rubber band has been applied round the head, a curved incision of the desired size is made, and the periosteum is divided and separated for a short distance. At one or other extremity of the incision a hole is bored with a trephine or Doyen's burr, and the bone is divided along a line which falls a little inside the incision in the soft parts. The saw line should be made obliquely through the bone so that there may be no subsequent sinking in. The base of the bony flap is then cut through with a guarded chisel.

After the osteoplastic flap has been turned down it is not necessary to incise the dura in a similar way. The latter is so richly supplied with blood that no attempt need be made to preserve the large vessels entering the base of the flap. On the contrary, when the convex border of the bony flap is situated near the middle line

of the head, the dural flap may be inverted *i.e.* the base being placed upwards and the convexity downwards, the large veins in the base of the dural flap being divided.

It is important that the line of incision in the dura should not coincide with the edge of the divided bone. Further, if the bone is to be replaced on the surface of the brain the dura must be retained,—the opposite to what is done in the decompression operation.

The results of osteoplastic trephining in skilled hands are shown in a communication by Cushing (Nov. 1905), in which he stated that out of 100 cases he had not had a single fatality. This shows that, if the proper case is selected, and the technique is good, one need not be so diffident in undertaking it as our experience led us to state in the fourth edition of our work. The indications for operation must, however, be absolutely clear. The fact that half the skull may be turned down with impunity is no excuse for an incomplete or careless diagnosis. Osteoplastic hemicraniotomy must not be undertaken simply for diagnostic purposes. It must be restricted to operations on the brain, particularly the removal of tumours, which require plenty of room.

It cannot be denied, however, that the osteoplastic operation, in which the flaps are much larger, possesses advantages over simple trephining, because in the latter it is much more difficult to obtain proper subsequent access if the trephine opening is not exactly over the desired spot, or if the deeper part of the wound has to be enlarged.

4. Circular Craniotomy. Lannelongue has put forward the theory that some of the cases of microcephaly and idiocy depend on the fact that the sutures are too soon ossified, and that the box of the skull having become rigid, the development of the brain has been interfered with. He has therefore cut out long strips of bone, and thereby formed artificial sutures. The advantages of this procedure have, rightly, been very much disputed. The best method of procedure is the circular craniotomy, as was first carried out by Dumont, and described by him after conversing with the author about idiocy and microcephaly. It is relatively a less severe operation than hemicraniotomy, and it is attended with less hæmorrhage. We perform it in the following manner: A sagittal incision is made over the middle line of the skull from the forehead to a point above the external occipital protuberance; it divides the skin and occipito-frontalis, which are stripped downwards as a flap with the hand, just as is done in the post-mortem room. The periosteum, which has remained intact upon the bone, is divided horizontally at the level of the bases of the reflected flaps, and the skull is then sawn all round, just as at a post-mortem, but not at such a low level.

Fig. 85.

One place is drilled through with a Sudeck-Kümmel spherical burr, and a hole, about 2 cm. in diameter, is made down to the dura, which is then carefully separated from the bone. The dura is more adherent to the bone at the situation of the sutures, and to some extent also where the vessels lie. A strip of bone, $\frac{1}{2}$ cm. broad, is rapidly removed with cutting forceps. Opposite the longitudinal sinus, in front and behind, one must be especially careful in separating the dura from the bone; but even here it can be easily accomplished.

In this way the roof of the skull becomes quite movable; but it is necessary to divide the dura to prevent ossification proceeding from it, the importance of which, as we have already mentioned, has recently been pointed out by Beresowsky in connection with the process of healing of trephine openings. The main meningeal vessels are not divided, but, as recommended by Beresowsky, are left *in situ* as bridges.

The operation is attended with very slight hæmorrhage in children. Should the bleeding be severe, it is recommended to postpone the division of the dura for two days. The skin flaps are simply folded back into position and united by a

continuous suture. We have performed the operation at one sitting without causing any shock, and have used merely a collodion dressing; but where there is any bleeding of importance it is better to apply pressure of bandage.

5. Craniotomy for the Covering in of Osseous Defects in the Skull. The question as to how defects of the skull may best be covered in has occupied surgeons of late years more than is necessary, and has exercised their inventive faculties. Doubtless the peculiarity of the cerebral circulation is dependent on the presence of a capsule which is essentially tense. Small defects are, thanks partly to the osteoplastic properties of the outer layer of the dura, as a rule, eventually closed. Sometimes, however, the deficiency becomes filled with such a firm scar that no injury to the circulation in the skull accrues. For this to occur a very large defect is requisite. The covering in of such defects has, however, distinct disadvantages, especially when the contents are pathological.

In this connection the case described by Depage is very interesting, where, on account of a lesion of the lateral sinus following a comminuted fracture, an extensive trephining was performed with resulting hernia cerebri. The slight intellectual disturbances, especially affecting speech and intelligence, were very distinctly improved as soon as a firm plate was applied, but led repeatedly to epileptiform attacks from the pressure connected with its use.

It has to be proved, therefore, especially in regard to post-traumatic epilepsy, whether, when a large defect in the skull is associated with intellectual disturbances, a firm closure with pressure produces real benefit, and whether this is attainable without injury. If this is so, then an endeavour should be made to obtain a covering.

The best means of securing a good bony covering is that of the Müller-König autoplastic method. The flap, as in other plastic operations, is pedunculated, with its base directed towards the vessels supplying the scalp, and is taken from the immediate neighbourhood. Instead of merely raising the pericranium and skin from the bone, the outer table of the bone is taken along with them by means of the chisel or a fine saw (Nicoladoni). The distinctive feature of this operation is that not only is an excellent bony plate obtained, but, as we shall point out later in speaking of resections and amputations in general, the osteoplastic layer of the surface of the bone, *i.e.* the deep layer of the pericranium, is retained quite intact. The fact that the bone breaks into splinters has no disadvantage whatever. The layer of bone which is laid bare in the neighbourhood of the flap is covered by transplanted skin.

If one wishes to obtain a really solid closure, it is desirable that the transposed bony layer be firmly connected with the sound bone. This applies in particular to all methods of covering, whether by applying bone from other portions of the body or by applying other materials. Martens has recently, on Eiselsberg's suggestion, studied the behaviour of transplanted bone in defects of the skull, and has come to the following conclusions: Decalcified bone, recommended by Neuber, Senn, and Kümmel, delays the healing, because it must first be absorbed. Burnt bone, recommended by Landerer and Barth, and proved to be of value by the latter from numerous investigations, in that it brings about healing of bony defects solely on account of the introduction of lime salts, causes a very slow healing, because it opposes little resistance to the penetration of the granulations. The best material for this purpose is a firmly-placed boiled layer of bone, as recommended by Westermann and David.

According to Barth, the implanted material itself disappears, but into this solid layer of boiled bone granulation tissue grows from the diploë, from the dura, and from the pericranium in the well-known fashion, and rapidly takes on the form of the absorbed implanted material. Cancellous bone is more easily grown into than compact cortical bone. Instead of taking the substitute, as Czerny does, from the inner surface of the tibia, it is better to saw out a slightly curved layer of bone of the necessary shape from the epiphysis of the tibia by means of a fine double-edged saw (similar to that used for opening the spinal canal in the post-mortem room), and to place it securely in position. If dead bone be employed it must be boiled.

In the strictly heteroplastic method, the celluloid plates of A. Fränkel have advantages over the others, as they are readily disinfected and easily obtainable.

Fränkel very rightly starts with the idea that it is not desirable that adhesion should take place between the implanted portion and the cerebral membranes, as is unavoidable in the granulation formation to which the implanted bone gives rise. But it should be mentioned that these adhesions between dura and skull bring about no real disadvantages, and that, according to Beresowsky, it is only in defects of the dura that adhesion with the inner membranes of the brain is to be feared. Further, it is only an intact pia which can afford protection against cicatrical processes extending to the cerebral cortex.

It is well, therefore, when the pia-arachnoid is laid bare, to follow Fränkel's advice and to interpose a layer which does not lead to adhesion with the subjacent membrane, either his celluloid plate, as a permanent heterogeneous layer, securely introduced without drainage, with suture of the skin; or (as we have elsewhere mentioned, on the grounds of Beresowsky's investigations) we may employ auto- or hetero-plastic bone, one of the serous membranes (for example, a piece of tunica vaginalis) being introduced as a smooth under-layer to protect the pia against the growing granulations.

Schifone[1] (Durante's clinic) has published the results of thirty-two trephining operations on dogs, in which he found that large defects in the skull and dura were replaced by dense connective tissue which ultimately became adherent to the cerebral cortex, and led to partial disappearance of the nerve elements (ganglion cells) and the substitution of neuroglia. No motor or sensory disturbances (epilepsy or prolapse of the brain) were observed.

C. SPECIAL INDICATIONS FOR TREPHINING

There can be no service rendered in considering at this stage the numerous conditions in which trephining may be indicated, so that only a few necessary indications will be discussed, from which the technique of the operation can be readily deduced.

6. Trephining over the Sinuses of the Dura Mater. The superior longitudinal, occipital, and lateral sinuses can all be easily exposed, and, if necessary, ligatured, being exposed in certain injuries to the skull, and ligatured if the lesion is extensive. When the sinus is only slightly injured, as happened, for example, in a case of gun-shot injury which recently came under our observation, plugging is the simplest remedy; but when an infective thrombosis has to be faced, a condition most common in the lateral sinus secondary to inflammation of the middle ear and mastoid cells, the question of opening and clearing out the sinus and subsequently plugging it has to be taken into careful consideration.

(*a*) *Trephining over the Superior Longitudinal Sinus.* Ligature of the superior longitudinal sinus has been recently recommended by Delagenière in the treatment of epilepsy, a suggestion made as the result of an accidental discovery. The circulatory disturbance produced by ligature is of the slightest description, as the large veins on the surface of the brain which open into it ramify in various directions and form quite a sufficient collateral anastomosis.

Similarly, interference with the cerebral circulation is seldom to be expected, except in the sense that from the sudden obstruction produced in the sinus by the application of the ligature, the blood contained in it cannot find its way directly into the veins in the anterior portion of the brain. The ligature should therefore be applied on the central side of the point at which the veins proceeding from the affected zone of the cortex enter the sinus. In our opinion this method of treatment should not be attempted without due consideration, as we have known a hemiplegia to result.

The superior longitudinal sinus lies, according to Horsley, entirely to the right of the mesial plane, but this is disputed by Dana. It is very broad (1 cm. according to Poirier) and, including its lacunæ, measures as much as 3 cm., so that at a distance

[1] *Deutsche Zeitschr. f. Chir.* Bd. 75.

of $1\frac{1}{2}$ cm. from the middle line the bone must be cautiously divided and the dura carefully separated. The thin walls of the lacunæ are more readily torn than the walls of the sinus itself.

When it is necessary to wound the dura in the neighbourhood of the sinus, it is well to provide sufficient space, in order to be prepared for all emergencies, for there are communications here with the diploic veins (spheno-parietal sinus), and

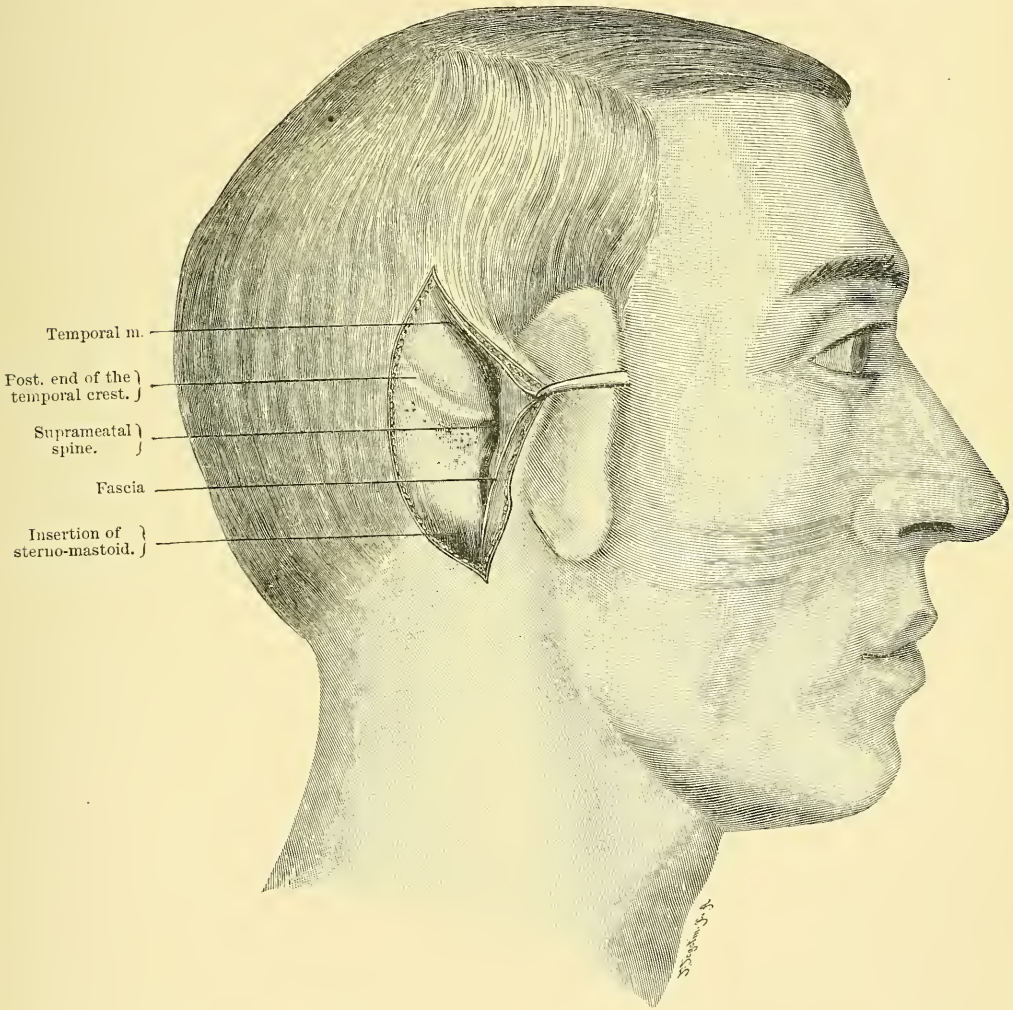

FIG. 86.—Post-auricular incision for opening the mastoid antrum, the lateral sinus, and the descending cornu of the lateral ventricle.

the large central veins arising from the surface of the brain open into the sinus and the lacunæ. Bleeding from these can only be properly controlled by careful ligature.

Ligature of the sinus is not an easy operation to perform, as the needle (aneurysm or sharp) may readily injure lacunæ or the entering veins. After the bone has been raised from the sinus and removed, it is more advisable to open the dura on both sides of the sinus, and pass the needle which carries the ligature from the one opening to the other.

(*b*) *Trephining over the Occipital Sinus.* The occipital sinus is formed by the

downward continuation of the superior longitudinal sinus below the level of the external occipital protuberance. It is ligatured in providing relief for cerebral tension as well as for the removal of cerebellar tumours. As already mentioned, when trephining is undertaken for decompression, it is often difficult to arrest the hæmorrhage which arises from the division of emissary veins near the middle line during the exposure and ligature of the sinus.

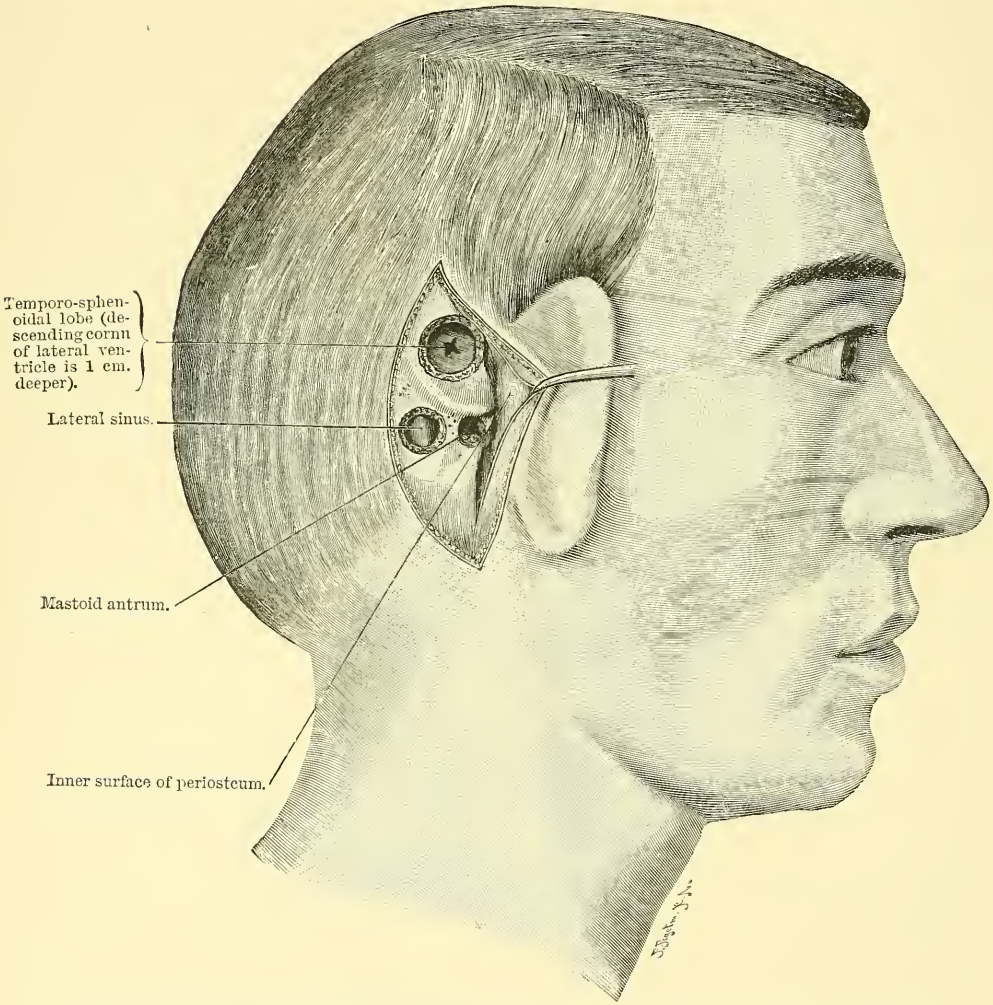

FIG. 87.—Opening the mastoid antrum and the lateral sinus. Exposure of the temporo-sphenoidal lobe and puncture of the descending horn of the lateral ventricle.

(*c*) *Trephining over the Lateral Sinus* (Figs. 86 and 87). This is a comparatively frequent operation, because thrombosis and suppuration occur most frequently in this sinus in consequence of its implication in inflammation of the middle ear. It is especially the descending limb of the sinus with which we are concerned in this operation. The point for trephining is determined by feeling for the most prominent part of the base of the mastoid process, which forms a projection behind the attached margin of the auricle. There is a ridge, a finger's-breadth higher, which passes obliquely backwards and upwards, and corresponds to the posterior extremity of the

temporal crest. Between this ridge and the above-mentioned prominence, on the inner surface of the bone, is the lateral sinus. It corresponds to the posterior part of the middle third of the mastoid process, and can be followed a little farther downwards beyond it. With the auricle applied to the skull, an incision is made corresponding to its posterior free border (Fig. 86). Superiorly, the incision divides some fibres of the temporal muscle. The periosteum is divided at the same time, and the flap is separated forwards, the attachment of the sterno-mastoid being detached with the knife and the posterior margin of the wound retracted backwards. On chiselling through the bone the wall of the sinus is exposed. The emissary mastoid vein traverses the bone opposite the middle third of the mastoid process.

Death followed injury to the lateral sinus in all the eight cases collated by Gargolphe and Picry. Depage, in February 1900, had a recovery by plugging, in a patient in whom a splinter of bone had wounded the sinus. Much more frequently, however, we desire to avoid opening the sinus in operations in this situation, especially in opening the mastoid cells.

On the other hand, we have to open the sinus in cases of infective thrombosis resulting from mastoid disease. Before opening it, we do well to partially detach the wall of the sinus from the groove in the bone in which it lies, so that, after the thrombus has been removed, the hæmorrhage may be effectively checked by packing between the bone and the sinus wall.

7. Trephining for Intracranial Hæmorrhage. (*a*) *Trephining in Intracerebral and Subdural Hæmorrhage.* Trephining is not only indicated in meningeal hæmorrhage, especially from the middle meningeal artery, but more recently surgeons have gone a step farther and endeavoured, in cases in which the hæmorrhage is more deep-seated, to relieve the general cerebral pressure and the local damage produced by the extravasated blood.

But the indications for operation in such cases are not so definite as they are in extradural hæmatomata, the result of laceration of the middle meningeal artery. Schulz[1] reports a case (trephined by Henle in the clinic at Breslau) in which $6\frac{1}{4}$ ounces of blood were extravasated beneath the dura in the frontal region. The indications for operation were found in descending neuritis of the right optic nerve with amblyopia, injury to the right oculomotor, with ptosis, and some interference with the movements of the eyeball, anosmia, and, particularly, in paresis of the opposite (left) leg, with increased reflexes, and paresis of the left lower branches of the facial nerve.

These multiple focal symptoms, as well as the affection of the leg without the arm, Schulz considers of special importance as pointing to the diagnosis of an intradural, rather than an extradural, hæmatoma, because the blood in the former may have a wider and more unequal distribution. Multiple nerve lesions at the base of the skull, so far as they are not to be explained by fissured fractures, may, if other circumstances point in that direction, lead to a diagnosis of intradural hæmorrhage, because the dura is with difficulty stripped off in that region. Simultaneous paralysis of the optic and oculomotor nerves alone, as also choked disc on the same side, are by no means unusual, even with extradural hæmatomata.

We may direct special attention to a further peculiarity, namely, that in subdural hæmatomata it occasionally happens that the paralysis is not "crossed," and is therefore liable to suggest an extradural, or a central, lesion of the opposite side.

Stabel reports a case of right subdural hæmatoma (90 c.c.), operated on by Hahn, in which there was deviation of the head and eyes to the right, complete paralysis of the right lower facial region and of both right extremities, while on the left side there was merely spasm, with increased reflexes in the leg and arm. We cannot accept Stabel's explanation of an anomalous course of the nerve tracts, but, as shown in discussing local cranial pressure, we regard the right-sided paralysis as due only to displacement of the falx cerebri. We have published a case, after personal observation, which proves that, in intradural extravasation, the local pressure is much less than the general or conducted pressure, because the blood distributes

[1] *Inaug. Diss.*, Breslau, 1897.

itself more, and may cause a lesion of the opposite cortical centres (in Hahn's case there was great tension of the dura on the opposite side), or may interrupt the conduction along the fibres of the corona radiata.

By trephining, not only may the blood extravasated under the dura be removed, but the source of the blood may be discovered and the hæmorrhage successfully arrested by ligaturing the bleeding artery on the surface of the brain. Schneider[1] of Königsberg, for example, in a case of punctured wound in the left temporal region, with aphasia and increasing right-sided paresis, trephined, divided the dura, cleared out the extravasated blood, ligatured a spurting branch of the middle meningeal artery, and sutured the dura with catgut. The hemiplegia improved on the second day after the operation and the aphasia on the third day.

Mention must be made of the aid to the diagnosis of subdural hæmorrhage afforded by the presence of blood in the cerebro-spinal fluid drawn off by means of Quincke's lumbar puncture.

Intracerebral hæmorrhages which have given rise to hemiplegia have also been successfully treated by trephining and opening into the extravasation so as to let out the blood.

Horsley insists on the necessity of surgical interference in contusions of the brain, and in extravasations of blood into the substance of the brain. In his communication to the International Medical Congress in Berlin, 1890, he stated that he could not recollect a single case where he would not have interfered in complicated cases of laceration of the brain, whether recent or of old standing. Further, he also advises active measures in all cases of simple laceration of the brain, in order to prevent the occurrence of epilepsy sooner or later. He referred, in this connection, to a case which was saved by operation, and contrasted it with a similar one with expectant treatment in which death occurred (with coma and convulsions) within eight days. The successful case was that of a medical man with extensive laceration of the frontal, parietal, and temporal lobes, in whom hemiplegia and unconsciousness had existed for ten days and was followed by coma and Cheyne-Stokes respiration. By means of extensive trephining and washing out of the blood-clot, which occupied the entire left subdural space, complete recovery resulted, so that the patient was able to resume the practice of his profession.

Cushing[2] has also reported a number of interesting cases of fracture of the base of the skull in which he removed and washed away subdural effusions of blood. He trephined over the temporal bone (intermuscular method) and the patient recovered without further disturbance. He further holds that where bulbar symptoms develop after a head injury, the occipital bone should be trephined on both sides of the middle line.

By his advocacy of trephining in the new-born, Cushing has opened up an important range of possibilities, which the obstetrician must take into careful consideration. In a paper published by him[3] dealing with subdural hæmorrhages in the new-born, he states that he found in still-born children and in children who died soon after birth, that the cause of death was most frequently due to hæmorrhage on the surface of the brain.

The hæmorrhage most commonly arises from the large mid-cerebral veins, which tear at their upper end during the over-riding of the parietal bones. In this situation they are most easily torn, as in traversing the subdural space they are least supported. Hence the thickest deposit of blood is found over the upper end of the motor cortex in the region of the centre for the lower extremity. It is here also that the lesions are chiefly found in spastic cerebral palsy (Little's Disease). In fractures of the base, the basal ganglia chiefly suffer, and cases of athetosis are attributed by Cushing to this cause.

When the symptoms all tend to the presence of a subdural hæmorrhage, *i.e.* when there are bulging of the fontanelle, slow pulse and respiration, dilated pupils, and convulsions, and moreover when blood is found mixed with the spinal fluid after lumbar puncture, the brain should be exposed and the clot removed by turning down

[1] *Arch. für klin. Chir.*, 1886, Bd. xxxiv. [2] *Loc. cit.*

[3] "Intracranial Hæmorrhages of the New Born," *Amer. Jour. of Med. Sc.*, Oct. 1905.

an osteoplastic flap of the parietal bones. Cushing has effected this with success on both sides.

Subsequent spastic paralysis can thus be prevented, as well as the epileptic and other mental disturbances associated with changes in the brain following a hæmorrhage.

Trephining may also be performed with benefit in non-traumatic hæmorrhage, as was proved by the brilliant cure of a case recently under the care of Khol of Chur. In the cases described by A. Fränkel, and correctly differentiated by him from pachymeningitis hæmorrhagica interna, there was found upon the brain at one time 200 c.c., and at another 140 c.c. of fluid blood. These cases clearly show that at any rate immediate death from cerebral compression is to be avoided by relieving cerebral pressure. The presence of spasms amounting to a tetanic condition, and of unilateral nystagmus along with other symptoms of cerebral pressure (fixation of the pupils, etc.), allows the diagnosis to be made with sufficient certainty.

Abernethy long ago drew attention to the bloodlessness of the bone overlapping large subdural hæmorrhages, a fact which we were able to confirm in December 1897 in the case of an old man. For further information we must refer the reader to the author's work on cerebral compression and concussion in Nothnagel's *Pathology*.

(*b*) *Trephining for Supradural Hæmorrhage.* We agree entirely with Krönlein that the first object of the trephining, even in hæmorrhage of the cerebral meninges, must be to find the hæmatoma, or, more correctly, the hæmatomata. The removal of 50 c.c. of blood-clot may not be sufficient where there are signs of obvious cerebral compression. According to Wiesmann, pressure symptoms may be entirely absent even with 75 c.c., and this is in agreement with experimental observation; on the other hand, hæmorrhages have been seen to amount to 250 c.c. before death occurred, *i.e.* over $\frac{1}{6}$ of the normal weight of a man's brain (1430 grams), or exactly $\frac{1}{6}$ of the normal volume of the skull (1500 c.c.). When, therefore, the escape of blood at the site trephined is too small to account for the symptoms, it is advisable to search in another place.

It is only after the blood has been removed that the question of ligature of the bleeding artery arises. Most frequently we have to deal with the middle meningeal artery. Bleeding from this vessel terminates fatally, according to Wiesmann, in 90 per cent of the cases in which no operation is performed, while 67 per cent are cured by operation. The middle meningeal artery supplies the membranes of the brain. Jacobson gives the point for ligaturing it as 5 cm. (2 ins.) behind, and 1·2 cm. above, the external angular process of the frontal bone. As a rule Vogt's point is chosen. This point lies two fingers'-breadth above the zygomatic arch, and a thumb's-breadth behind the external angular process of the frontal bone; but it strikes only the anterior branch of the artery.[1] In order to expose the posterior branch at the same time, the trephine must be applied immediately above the middle of the zygomatic arch. In addition to the integuments and the periosteum, some vertical fibres of the temporal muscle are divided. A vertical incision extending below the zygomatic arch cannot be made on account of the distribution of the facial nerve. We employ an incision extending obliquely from the external angular process of the frontal bone,[2] downwards and backwards, to the posterior extremity of the zygomatic arch, and from thence, upwards and backwards, to above the auricle. After we have divided the skin and the strong temporal fascia, and ligatured the superficial temporal artery, the incision is carried down to the bone at the posterior border of the temporal muscle, and this muscle along with the periosteum is detached forwards. In this way hæmorrhage from the deep temporal arteries is avoided, and the anterior part of the squamous temporal, under which the meningeal arteries lie, is exposed. The bone here is very thin. Poirier (and we agree with him) recommends trephining 5 cm. (2 ins.) above a point midway between the external auditory meatus and the frontal process of the malar. The temporal bone is exposed and a portion, 3 cm. in diameter, chiselled out above the zygoma. The middle meningeal artery lies on the superficial surface of the dura, being occasionally imbedded in it.

[1] Cf. Merkel's *Anatomie*, S. 65.

[2] In Fig. 90 the anterior incision is drawn too deep in its anterior half.

Krönlein, who has had great experience of bleeding from the middle meningeal, has determined the two points at which the extravasation from the anterior and posterior branches of the artery is most likely to be met with. These two points of Krönlein lie in a line drawn horizontally backwards from the supraorbital margin, that for the anterior branch being 3 to 4 cm. behind the external angular process of the frontal bone, while that for the posterior is where the above line intersects a line drawn vertically upwards from the posterior border of the mastoid process. For

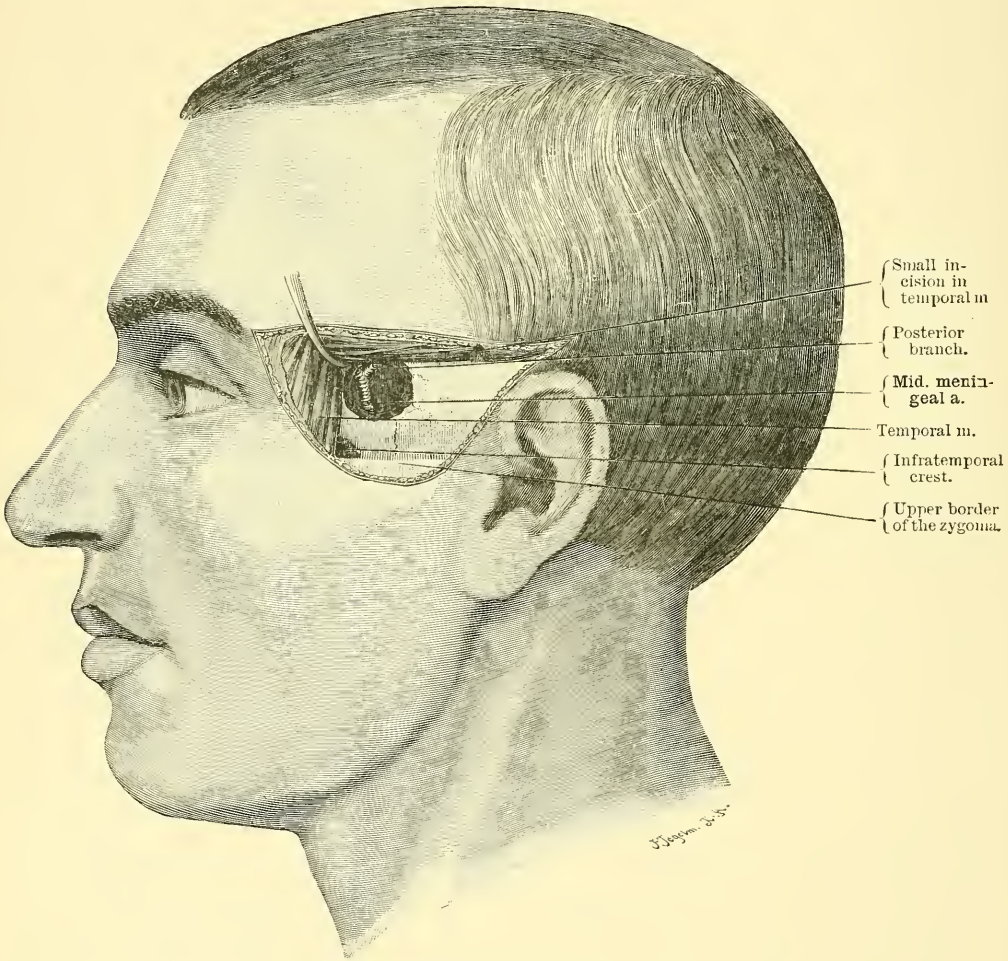

FIG. 88.—Ligature of the middle meningeal artery.

extravasations (as he once observed), which reach almost as far as the foramen magnum, Krönlein gives a third point for trephining, viz. below the middle of the right or left half of the superior curved line of the occipital bone.

Steiner, after investigating a hundred skulls, has found the anterior branch invariably at the crossing point of a vertical line drawn from the mid point between the middle of the glabella and the apex of the mastoid process, with a horizontal line drawn from the middle of the glabella around the skull. The posterior branch, in 90 per cent of the cases, is at the crossing point of the above-mentioned horizontal line, with a vertical line drawn upwards in front of the mastoid process.

8. Trephining for Abscess of the Brain. — Cerebral abscesses, like subdural abscesses, most frequently arise from an extension of the inflammatory process in the coverings of the brain (skull and soft parts), the inflammation either originating in an external injury (complicated fractures) or in a cavity lined by mucous membrane (nose, frontal sinus, and particularly the middle ear). The abscess may further be metastatic in origin (*e.g.* in osteomyelitis staphylomycotica).

When due to an injury, a cerebral abscess may occur in any situation, usually, however, on the convex surface of the brain, the antiseptic treatment of the wound having prevented the outbreak of a diffuse meningitis. The skull in such cases is trephined over the seat of the injury.

In regard to the method in which trephining is performed, it is most important, when once suppurative inflammation has occurred in the region of the brain, to provide absolutely free drainage by extensive removal of bone. An osteoplastic operation is, of course, not to be considered.

If there is an existing defect in the bone, *e.g.* a depressed fracture, the latter must be enlarged with cutting forceps, or with Lane's forceps if the bone is very hard. The extent of the subdural collection of pus must then be determined, and the bone completely removed for a corresponding distance. The dura is then thoroughly cleansed and opened, the size of the opening depending on the extent of discoloration present. Occasionally the dura in the region of an abscess appears markedly pale. The position of the abscess having been determined by means of cerebral puncture, the larger vessels on the surface of the dura are ligatured, after which the dura is incised, and the abscess freely opened.

Unless the opening has been made sufficiently large, it is apt to become occluded by prolapsed brain, with the result that the pus spreads laterally, and in a few days has to be evacuated at the sides of the trephine opening.

We lately operated on a patient in whom a cerebral abscess had ruptured into the lateral ventricle (posterior horn). For some days the pus escaped so freely through a drain that we had hope of his recovery. The drainage, however, was not sufficiently complete, and at the autopsy we learned that we might have prevented the fatal extension to the other ventricle had we trephined over the posterior horn originally affected.

In contrast to the traumatic cases, there are definite situations in which cerebral abscesses develop, when extension has occurred from the nasal cavities (especially the frontal sinuses) and from the tympanic cavity and its annexes (otitis media and mastoid disease), in which cases the trephine must be applied over the original source of the infection.

Frontal abscesses originate from the nose and frontal sinus, temporo-sphenoidal abscesses from the middle ear, and cerebellar abscesses from the mastoid process. In these cases it is advisable to follow the golden rule and invariably attack the abscess through its origin in the skull itself. For an abscess in the frontal lobe, the frontal sinus and roof of the nose must first be opened. When the source of infection is in the tympanic cavity the mastoid antrum is attacked, and after the latter has been opened the track by which the suppurative process has extended is followed out. Macewen laid down this rule in his classical work, on which the specialist's knowledge was originally based. Müller (Trautmann) has recently urged in strong terms that the middle ear should always be opened into before an attack is made on a cerebral abscess of aural origin. Krause has opened abscesses on the posterior surface of the petrous-temporal with success, subsequently plugging them.

In many cases, even when an examination by an aural specialist has failed to reveal anything abnormal in the ear, by opening the antrum and mastoid cells the presence of pus can be demonstrated and the direct route of infection followed out.

It would be mere repetition to describe the steps of the operation at this stage, as they are dealt with under trephining of the frontal sinus and mastoid antrum. It should be noted, however, that as in every case where there is the smallest suspicion of intracranial suppuration, the essential feature of the operation consists, as in the case of injuries, in a thorough exposure of the area of suppuration. This means that the early stages of the operation must be devoted to providing efficient access.

9. Trephining for Cerebral Tumours. — In trephining for cerebral tumours Wagner's osteoplastic operation is the one commonly used, and except in those cases in which the tumour can be very exactly localised, the flap turned down must be of considerable size (cf. arrest of hæmorrhage, p. 178). As already stated, the osteoplastic operation is more difficult to perform than is simple trephining, and in dealing with a cerebral tumour this difficulty is even more marked. No operator should therefore attempt the removal of a cerebral tumour unless he has obtained a large amount of experience in trephining.

Severe venous bleeding must always be expected, on account of the increased intracranial pressure. We agree with the views Cushing has evolved as a result of his brilliant experiments, that the increase in the intracranial pressure initially produces a state of venous congestion, but that the consequent obstruction to the passage of blood through the brain (dysdiæmorrhysis cerebri) is overcome by a rise of blood-pressure resulting from irritation of the vasomotor centre.

Frazier has very properly observed that the latter rise in blood-pressure will suddenly fall whenever the intracranial pressure is reduced. This both Cushing and the author have confirmed, while Frazier attributed the shock and collapse that frequently follow operations on cerebral tumours to this cause. In addition, the loss of blood, and possibly the action of the anæsthetic, tend to aggravate the condition.

One is therefore inclined to follow the clear instructions Frazier has given in connection with the two-stage operation, namely, first to estimate the blood-pressure with a sphygmomanometer and observe whether a sudden or significant fall occurs after opening the skull and turning down a flap of dura, as in the event of a marked fall in the blood-pressure a few days should be allowed to elapse before completion of the operation. Horsley always operates for cerebral tumours in two stages (a method also adopted by v. Bergmann in cases of large tumours), in which case the wound must be very securely closed before the second part of the operation is undertaken.

After reflecting the flap of dura, the operator encounters another complication which, as Frazier has shown, proves very troublesome, viz. an enormous bulging of the brain. The prolapse of the brain may be either "initial" or "consecutive," the former caused by the increased intracranial pressure; the latter, which may be very serious, by a local œdema of the brain following thermal or mechanical injury (Canon). The surgeon must therefore rapidly decide by inspection, palpation, puncture, and incision, whether the operation should be continued. If not, the wound must be instantly closed. In a case on which Keen and Frazier operated, the opening could only be closed by means of inserting a flap of pericranium between the edges of the dura.

If these operative dangers are kept in mind and steps are adopted to combat them, in many cases it will be found that the tumour is situated superficially, that it proceeds from the dura, and that it only causes death mechanically, first giving rise[1] to severe headache, vomiting, epileptic attacks, and mental disturbances. It is a great injustice to persevere in the medical treatment of a case when a patient exhibits the symptoms we have mentioned, and is becoming blind and mentally disordered, simply because one has too little faith in the aid of surgery. Because, as has been already stated, the consolation in all these operations is that even if it is impossible to remove the tumour, one can always be assured of the certainty of relieving the cerebral pressure.

After this description of the attendant dangers, we find the operation performed as follows:[2] The patient is carefully prepared, stimulants and morphia being administered, with ether as the anæsthetic. The skin is cleansed with the strictest antiseptic precautions and should be thoroughly protected even during the operation by means of sterile cloths attached to the wound-edges with skin clips. A preliminary injection of novocain and adrenalin may be administered ten minutes before the incision is made.

[1] According to Cushing, Blackburn found twenty-eight tumours, most of them operable, as the original source of disease in patients in his asylum.

[2] We partly follow Heidenhain's excellent description. He has successfully operated on three successive cases of cerebral tumour (*Arch. f. klin. Chir.* Bd. 64).

A rubber band is fastened round the skull, the patient's head and shoulders are elevated, and care is taken to have the operating table heated. A large curved incision is then made through the soft parts down to the bone, and the flap of bone (Wagner), the base of which is below, is mapped out with a drill and the Cryer-Sudeck burr or Gigli saw (*vide supra*). The base of the flap is then broken by raising it up on a strong elevator, the hæmorrhage being arrested by means of Horsley's wax. A horseshoe incision is made in the dura (base of flap upwards) or it may be opened by a crucial incision.

The position of the tumour is then determined, and, provided that the patient's blood-pressure permits of proceeding with the operation, the brain is incised, after double ligature of the vessels in the pia mater. The edges of the wound in the brain are held apart with a gauze-covered spatula or suitable retractors, and the tumour is isolated, not too close to it, however, on account of the greater bleeding that is encountered.

If the tumour is separated with the fingers, sterilised gloves must always be worn, as it is of the greatest importance to avoid even the slightest risk of infection. The wound must not be irrigated but should be carefully mopped with gauze swabs wrung out of lotion. Our goitre spoon will be found very useful for raising up the tumour. The wound is then packed with strips of iodoform gauze wrung out of carbolic lotion, and the dura is accurately sutured, the vessels being ligatured with fine silk, after which the skin incision is closed with deep sutures, including all the layers of the scalp, and the dressings are applied.

The gauze packing should not be removed for five or six days, by which time it has become somewhat loosened by the formation of granulation tissue. The superficial dressings must be changed whenever any discharge soaks through, and antiseptic gauze must be reapplied.

(*b*) *Trephining for Cerebellar Tumours.* At the present time, even when one is confident of the presence of a cerebellar tumour, it is often impossible to decide in which lobe of the cerebellum it is situated, *i.e.* it is more difficult to localise exactly a tumour in the cerebellum than one in the cerebrum. Cerebellar ataxy (disturbances of equilibrium in standing and walking, without actual motor ataxy), giddiness, marked pressure symptoms (choked disc, headache, vomiting), and also rigidity of the neck, are symptoms common to tumours in various positions. It is only when the tumour invades the base of the brain and involves special centres and nerve-roots on one side, that one can definitely locate the side on which the tumour is situated. In exposing the cerebellum, therefore, an operator must employ a method which enables him to examine the whole posterior surface of the cerebellum, *i.e.* both right and left lobes. This is all the more indicated by the fact that the incision to expose both sides of the posterior fossa inflicts less injury than the exposition of one side only.

The incision passes vertically upwards behind the mastoid process on one side and is carried a finger's-breadth above the superior curved line of the occiput and over the external occipital protuberance to a corresponding point on the other side. Ten to fifteen minutes before the operation, $2\frac{1}{2}$ drachms of a $\frac{1}{2}$ per cent solution of novocain and adrenalin may be injected with advantage. A continuous or a series of interrupted loop sutures may also be inserted above the convexity of the incision in order to control the hæmorrhage from above (Heidenhain and Hacker). The bleeding from the edges of the flap can be easily arrested by compressing the flap between the fingers of the left hand and clamping the branches of the main artery (occipital) and vein with forceps.

The periosteum is now detached with a knife and elevator from the occipital bone along with the attachments of the neck muscles as far down as the foramen magnum, after which the posterior fossa is opened and the dura freely separated all round, which must be done carefully in the region of the sinuses, especially the occipital sinus, although the bone covering the lateral sinus may be more freely removed. The opening is then enlarged in all directions till the dura covering the cerebellum is exposed in its whole extent (Fig. 89).

The freer the exposure, the less will the brain be injured in looking for the

tumour. The dura is not opened till one is certain that a large part of both cerebellar hemispheres and the vermiform process can be directly examined. A flap incision, convex upwards, is then made with a fine knife and the edges of the dura are retracted with small sharp hooks, after which the occipital sinus is clamped with our artery forceps and ligatured above and below.

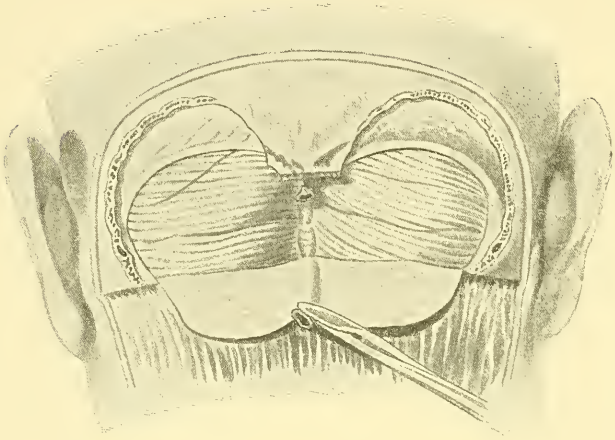

FIG. 89.—Exposure of both cerebellar lobes. The figure also shows the ligatured ends of the occipital sinus; the mastoid processes; a large and constant sinus in the bone transmitting a tributary of the lateral sinus; the lateral sinus; the external occipital protuberance.

If there is marked intracranial pressure, the cerebellum now bulges prominently outwards, and if the tumour is not at once observed, the cerebellum must be carefully palpated with gloved fingers. In one of the most recent cases on which we operated we located (from symptoms of marked ataxy and giddiness) the tumour as probably situated in the vermiform process, or, at any rate, rising from the upper or posterior and not from the inferior surface, as no nerve-roots were involved. We expected to find the tumour on the right side as the disc on this side was the more congested, and our diagnosis proved correct except with regard to the last point. The tumour was situated on the left side, and at first could only be detected as a firm area under the surface the size of a cherry. The tumour, however, was found to measure 5 cm. long and $2\frac{1}{2}$ cm. broad, and extended towards the middle line and into the superior vermiform process. It was successfully removed by blunt dissection, the copious venous bleeding that occurred at the moment of removal being arrested by plugging.

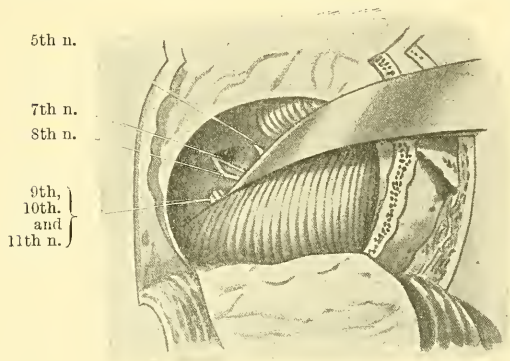

FIG. 90.—Unilateral exposure of the cerebellum for the removal of a tumour in the region of the cerebello-pontine angle.

After all bleeding vessels have been ligatured, the wound should be completely closed except for the insertion of two short glass tubes, one in each angle of the wound. There is no risk of a cavity forming underneath the flap owing to the increased cerebral pressure. If any oozing continues xeroform gauze packing may be inserted. The accompanying two figures are reproduced from Frazier's excellent work on cerebellar tumours.[1] In Fig. 89 the entire posterior surface of the cerebellum has been exposed by turning down a flap of dura, while the occipital sinus has been ligatured and cut across, the lateral sinus being well seen. It should be noted that more bone may have to be removed higher up, but it is very desirable to preserve the external occipital protuberance as a protection for the underlying sinuses.

[1] *New York and Philadelphia Med. Journ.*, 11th and 18th February 1905.

In Fig. 90 the cerebello-pontine angle is shown exposed from above, the cerebellum being retracted downwards and inwards. The posterior surface of the petrous temporal and the 5th, 7th, 8th, 9th, 10th, and 11th nerves are also exposed.

Krause [1] exposes the cerebello-pontine angle (Henneberg and Koch) [2] and posterior surface of the petrous temporal in tumours of the auditory nerve through an osteoplastic flap (base below) by means of an incision in the middle line between the cervical muscles down to the back of the head; but he is also of opinion that the bone should

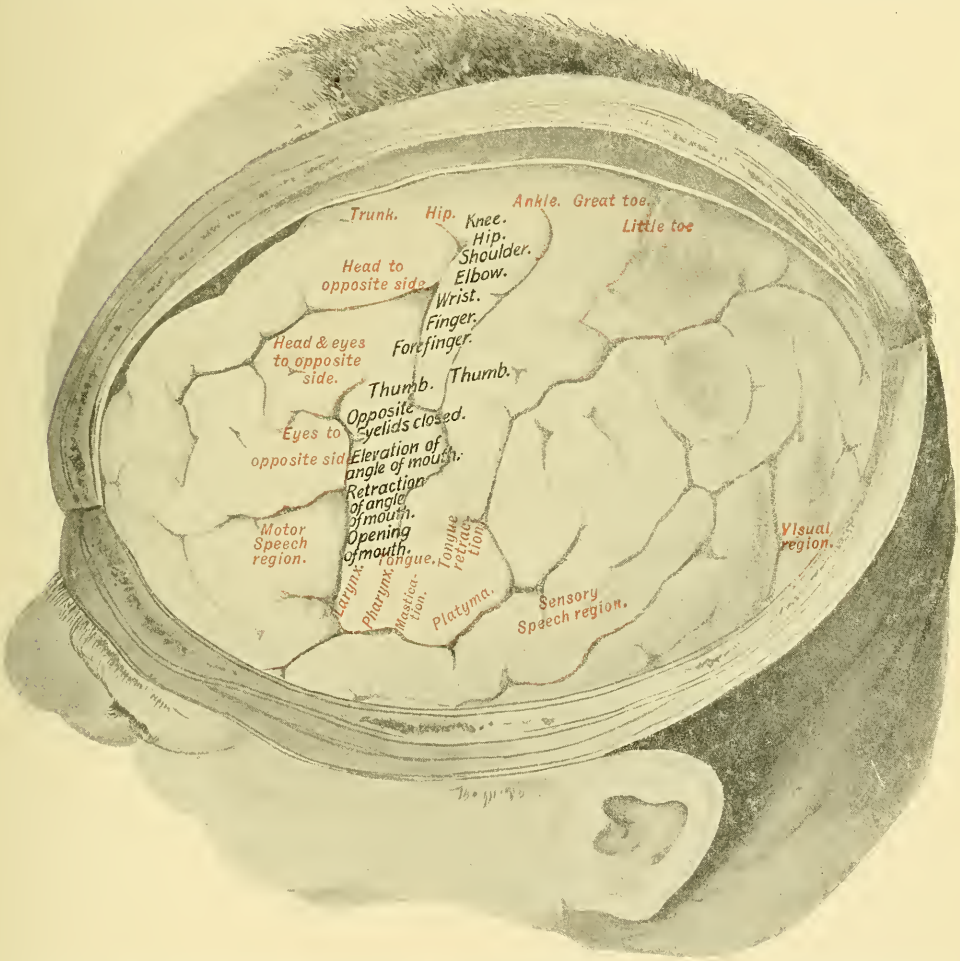

FIG. 91.—The black type shows the cortical areas in man which are definitely known (Horsley), the red type those less definitely known. The importance of the relations of the precentral line to the areas is well seen.

be entirely removed and both sides of the cerebellum exposed. According to Picqué and Mauclaire [3] Willems of Gand employs an osteoplastic flap.

[1] *Beiträge z. klin. Chir.* Bd. 37, 1903. [2] *Arch. f. Psychiatrie,* Bd. 36.
[3] Twelfth Congress of Surgery in Paris.

D. CRANIO-CEREBRAL TOPOGRAPHY

In order to avoid having to make unnecessarily large trephine openings, *e.g.* of the nature of Doyen's hemicraniotomy, one must be in a position to locate, from the nature of the symptoms, the situation of a hæmorrhage, abscess, or tumour. The more precisely this is effected (especially in the early stages) the smaller is the opening required. But if the situation of the tumour cannot be accurately localised, then of course there must be no hesitation in turning down a large osteoplastic flap.

In previous editions of this work we mentioned that it is a mistake to consider that those cortical areas, whose functions are known, are indicated by the Rolandic fissure, while the methods which depend on the recognition of the fissure are not the most reliable. More recent researches by Sherrington and Grünbaum [1] have afforded abundant proof that the motor centres are contained exclusively in the precentral gyrus. They do not extend backward across the fissure of Rolando, but reach forward to the precentral sulcus.

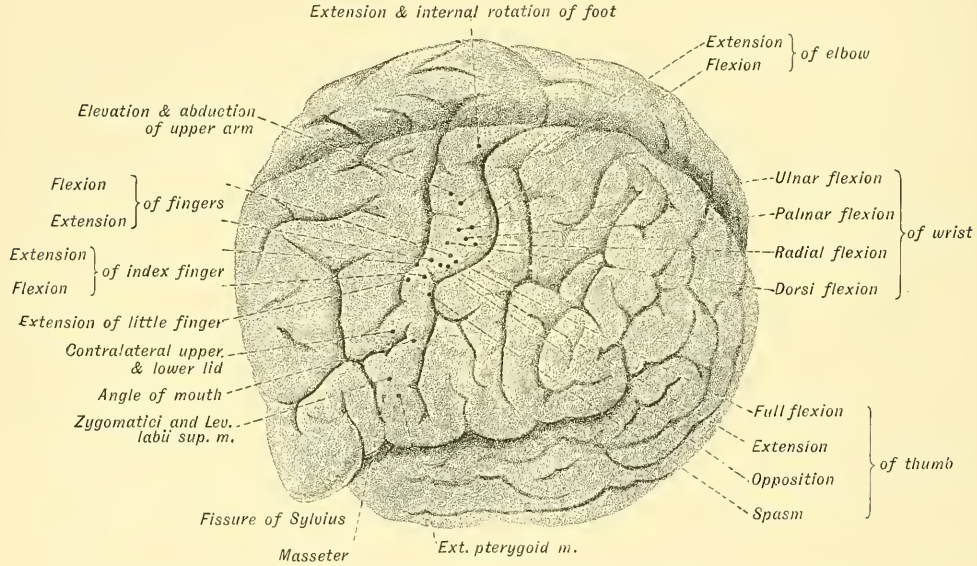

FIG. 92.—Position of the motor areas in man (Krause). Note, they are all situated in the precentral gyrus.

The experimental results of these observers in the case of the ape have been confirmed by Krause in man by means of unipolar stimulation of the brain. Krause used a small induction coil, fitted with two Leclanche cells. One large flat platinum electrode was placed on the body, while the other, a small spherical platinum point, insulated and sterilised, was applied to the brain, the latter being stimulated with a weak current. Fig. 92, taken from his work, illustrates the position of the various centres which he was able to determine by this method.

We reproduce, mapped out in the figure of the left hemisphere (Fig. 91), those areas with whose localisation we are most exactly acquainted. The lettering is so arranged that those areas which in man may be regarded as fully settled are indicated in black. The remaining centres, on the other hand, about which there may be a doubt, or which are not exactly delineated, are indicated in red.

It will be clearly seen from this figure, the cerebral surface of which is drawn from nature, that the majority of the known centres are grouped round the precentral

[1] *Proceedings of the Royal Soc.*, vol. 69, and *Transactions of the Path. Soc. of London*, vol. 53, 1902.

sulcus, *i.e.* in the whole length of the gyrus centralis anterior and in the foot of the third frontal convolution. The precentral sulcus is therefore a much better guide for the exact localisation of the motor cortical centres than the sulcus of Rolando, all the more so since the upper and middle frontal sulci open into it, and furnish two very exact points by which the level of the various centres may be identified. From the point of view, therefore, of cranio-cerebral topography it is of the first importance to define exactly the position of the precentral sulcus.

It will be readily observed, from a comparison of Fig. 91 with Fig. 92 (the latter illustrating the position of the centres as determined in man by Krause) that all the cortical motor areas lie exclusively in the gyrus centralis anterior.

The Sylvian fissure has a great significance, as anteriorly it limits the lower end of the precentral gyrus, in which lie a number of centres; and it also forms the upper limit of the first temporal convolution, which is the main seat of the sensory speech area.

Less importance is at present to be attached to the fact that the prolongation of the precentral sulcus upon the mesial surface of the hemisphere indicates the approxi-

FIG. 93.—Centres upon the inner surface of the hemisphere, according to Horsley.

mate position of the cortical area for the muscles of the trunk, and that the temporo-sphenoidal lobe has its tip determined by the Sylvian fissure, as the centres for smell and taste, and in part also the tactile centre, are situated upon the mesial surface. Fig. 93 gives a sufficient idea of the relations. We have also to define the visual region, because disturbances of vision, especially in the form of hemianopsia, frequently furnish very good data for determining the site of a cerebral lesion. The mechanism of sight is very extensively represented in the cortex of the occipital lobes, both upon their outer and mesial surfaces, and it is sufficient to be able to map out the limits of the occipital lobe with a fair amount of precision. The occipital lobe is separated from the parietal by the parieto-occipital fissure, which lies 1 cm. in front of the lambda. Its posterior extremity lies a little above the external occipital protuberance, while, below and anteriorly, it joins the temporo-sphenoidal lobe.

All these points can be defined with sufficient accuracy by means of the craniometer, such as we now employ (Fig. 94). This consists of two nickel-plated flexible steel bands, graduated in millimetres, one of which is placed horizontally above the attachment of the auricles, and embraces the equator of the head from the glabella to the external occipital protuberance. It is kept in position by means of screws. A

second band, fixed firmly at right angles to the above, is stretched sagittally in the middle line from the external occipital protuberance to the glabella. A third band is made to slide upon this, and is so arranged that it can be placed at any desired angle to the sagittal band.

When one end of this band is fixed over the lambdoidal suture and the other carried round to the glabella, a line is obtained which corresponds to the Sylvian line of Poirier, but which, however, does not quite indicate the Sylvian fissure. We have termed it the *linea temporalis* 1, because, while it corresponds, anteriorly, to the upper part of the first temporal convolution (and therefore also to the anterior part of the Sylvian fissure), posteriorly, it overlies its lower part.

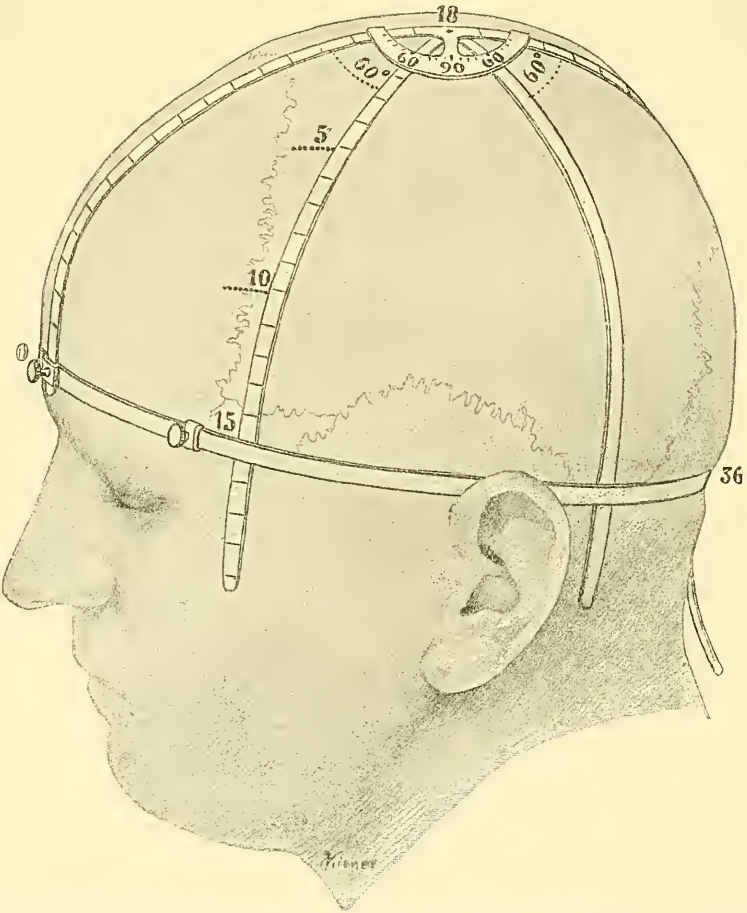

FIG. 94.—Kocher's craniometer, showing the equatorial, sagittal, and movable bands in position, the latter of which determines the precentral and Sylvian fissures.

In Fig. 95 the lines are indicated which can be rapidly and easily mapped out on any head by employing our apparatus. If the movable meridian band is placed midway between the glabella and the external occipital protuberance, and at an angle of 60° to the sagittal band, it will overlie the precentral sulcus. We have therefore named this the *linea precentralis*. By trisecting the part of this line, which reaches from the mesial line of the vertex to the equatorial line, we can exactly define the origins of the superior and inferior frontal sulci.

In this way, as may be seen by comparing Figs. 95 and 91, the linea pre-

centralis, and the two points which trisect it, suffice to localise, with sufficient accuracy, the centres in the precentral gyrus and at the base of the third frontal gyrus. It is satisfactory to note that authorities like Neisser and Polack, who have employed our craniometer, state that they have always found the localisation to be very accurate.

If the band be rotated backwards so that it forms an angle of 60° with the sagittal one, a line is obtained which is termed by us the *linea limitans*, because it denotes pretty exactly, below the point where it crosses the linea temporalis 1, the boundary between the temporal and occipital lobes, while above the crossing it corresponds to the junction of the supra-marginal and angular convolutions. The naso-lambdoid line is determined by sliding the movable clasp back to a point 1 cm.

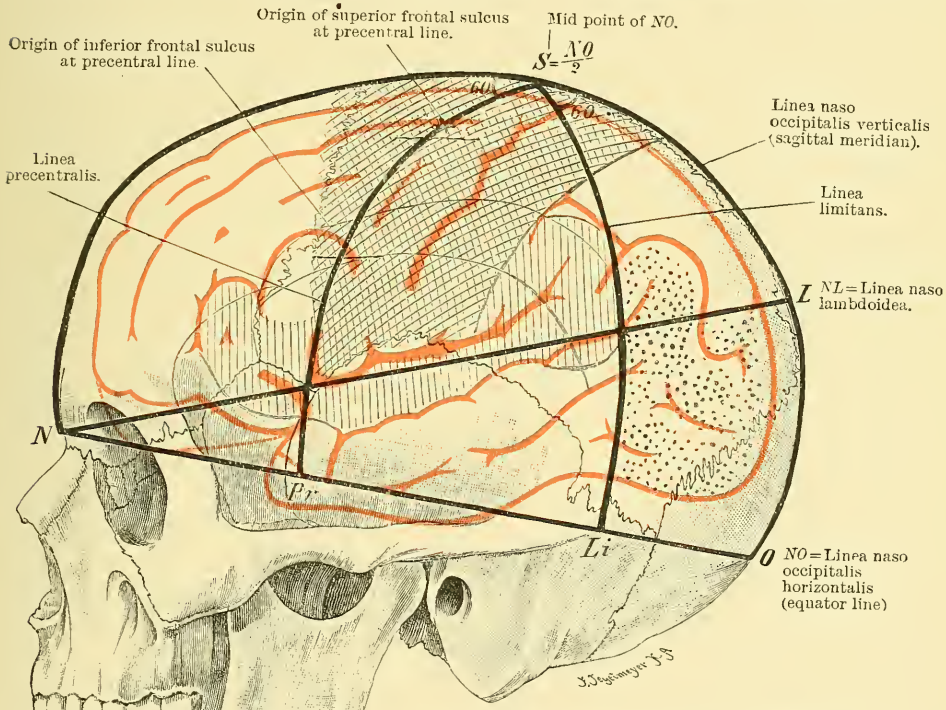

FIG. 95 shows the lines on the skull determined by our apparatus, with the corresponding convolutions. *NO*, from the nasion to the external occipital protuberance, represents the horizontal equatorial line and the sagittal meridian line. *Pr*, precentral line. *Li*, linea limitans, between the angular and supra-marginal lobes above and the temporal and occipital below. *NL*, between nasion and lambda, gives the first temporal convolution between *S. Pr* and *S. Li*. The motor cortex is cross-shaded, the speech centre is shaded with vertical lines, the visual region is dotted.

above the apex of the lambdoidal suture, and then by carrying the band round to the glabella. This line corresponds, between the precentral line and the linea limitans, to the first temporal convolution, and, where it crosses the precentral line, it corresponds to the anterior end of the Sylvian fissure. The posterior end of the linea temporalis 1 indicates the parieto-occipital fissure, and therefore the boundary between the occipital and parietal lobes. A glance at the figure affords a better explanation than it is possible to give in words. As will be seen, we have adhered to the method of percentage measurements which was introduced by Hare, and fully worked out by Müller. Compared with absolute distances the method has the advantage that it can be applied to any form of skull.

We cannot, therefore, understand how Krause, who has fully recognised the significance of the precentral sulcus, still prefers to be guided by the determination of the fissure of Rolando.

E. SURGERY OF THE SPINAL CORD AND ITS COVERINGS

(a) Puncture of the Subarachnoid Space. Lumbar puncture, which was introduced by Quincke, has now become a very important therapeutic as well as diagnostic measure.

As we have already stated in the chapter on anæsthesia, Bier utilised it for producing anæsthesia of the spinal cord, or cauda equina, and since less toxic substances are now used for the injection, and their effect is rendered more local by a combination with adrenalin (Braun), the method has been rescued from the disrepute into which it had been brought by the alarming accidents that occasionally followed. We have found the results of novocain injections (Merck) most satisfactory.

The method of puncture has been explained in the chapter on anæsthesia. The chief indication for lumbar puncture, as it is badly termed, is for diagnostic purposes. Not only can the presence of effusion of blood and of inflammatory exudations in the subarachnoid space be revealed, but the nature of the inflammatory process can also be established by bacterial examination. This may be of considerable value, and should never be omitted in doubtful cases.

A further indication for its use is the determination of the pressure existing in the subarachnoid space of the spinal cord and brain, and the nature of the effusion into these spaces. Very special care must be exercised if cerebrospinal fluid is to be withdrawn for therapeutic purposes by lumbar puncture. Lumbar puncture does not give any very certain measure of the pressure inside the skull, as the pressure may fall very quickly in the spinal cavity, and remain high in the cranial cavity. Further, the fluid in the lumbar region (Volke) may be richer in albumen than it is in the ventricles. The transudates in cases of tumour, for example, are richer in albumen than they are in cases of hydrocephalus. Lastly, cases of sudden death have occurred from lumbar puncture, because where there has been a high intracranial pressure sudden diminution of the pressure in the canal has caused the cerebellum to be forced down into the spinal canal, with the result that paralysis of respiration has occurred from pressure on the medulla. Gumprecht has collected no less than seventeen such cases.

(b) Extensive Exposure of the Spinal Cord. Exposure of the spinal cord is undertaken when the function of the cord as a conducting structure (rather than as a central organ) is endangered by pressure, as the result of an inflammatory process, the growth of a tumour, or an injury of the vertebræ. The most usual conditions, which indicate exposure of the cord, are :—

(1) Fractures of the vertebræ when the cord is compressed either as a result of a dislocation or by a fragment of bone, which cannot otherwise be replaced or removed.

(2) Inflammatory conditions, which are rarely due to osteomyelitis staphylomycotica, but are generally of a tuberculous nature, the cord becoming compressed and damaged by the spread of the disease.

(3) Tumours, which interfere with the conduction in the cord by their growth, and which may either be extra- or intra-dural.

The presence of a tumour urgently calls for operation, and a number of brilliant results have been reported, in both extra- and intra-medullary growths. According to Lloyd's records, out of 51 operations on tumours of the spinal cord 31 per cent of cures were obtained, the mortality being 10 per cent. The cause of death is shock, generally from hæmorrhage. McCosh,[1] however, operated on 6 cases without a fatality. Harte[2] records a mortality of 47 per cent in 92 cases, 30 deaths resulting from the operation.

The chief reason why surgical interference has hitherto failed is, that it is under-

[1] *The Journal of American Medical Association*, Aug. 1901.
[2] *Annals of Surgery*, Oct. 1901.

taken at too late a stage, and further, that the patient's health has deteriorated as a result of the long-continued anti-syphilitic treatment followed so zealously by the physician. If every physician would, like Oppenheim, make an early diagnosis and call in the surgeon at the proper time, much better results would be obtained. Auerbach and Brodnitz have recently published particulars of a brilliant case in which a tumour in the cervical portion of the cord extending up to the atlas was successfully removed.

It is a case of more difficulty to decide when one ought to operate in inflammatory conditions, more especially in tubercular disease of the vertebræ, as in these cases delay is not injurious to life, and indeed the impairment of the spinal cord is not infrequently removed by appropriate orthopædic and general treatment.

It may be regarded as an axiom that operation is indicated when, after some weeks of correct mechanical and general treatment, the paralysis and other evidences of pressure show no material improvement, or do not disappear altogether within a few months.

Trendelenburg's advice is to operate after the tuberculous disease is healed, if there is still pressure on the cord from the destruction or displacement of the bones. His results have proved entirely satisfactory.

It is still more difficult to know when to operate in the case of fracture of the spine. Naturally when the injury has not given rise to complete interruption of conduction, and when after continued treatment and observation no improvement can be recognised in the paralysis and sensory disturbances, a decision can be more easily arrived at. One must not, however, unduly delay in relieving the pressure, although excellent results have been obtained by laminectomy even after a long interval has elapsed (McCosh, Munro, and others). In two cases Munro found only a circumscribed collection of fluid, the evacuation of which produced the desired effect.

Sultan[1] has recorded the results obtained by Trendelenburg, who has had a wide experience of spinal surgery. In children, when the cause of the paralysis was due to an epidural abscess, granulation tissue, or narrowing of the spinal canal, especially in the lower part of the spine, very gratifying results were obtained by laminectomy.

The question of operation in recent severe lesions of the cord due to fractures and dislocations of the vertebræ is also surrounded with uncertainty. If one is influenced by the experience of Munro,[2] who found that during a period of ten years, only in one of thirty cases of injury in the upper dorsal and cervical region did restoration of function occur without operative interference, while in the same period there were three complete recoveries after operation, one naturally leans towards surgical intervention in every case. The cases must, however, be very carefully selected, and if the temperature is very low (as often occurs early with high lesions of the cord) the question of operation should not be considered. In all Munro's cases, where there was severe crushing of the cervical cord, the patients succumbed. If there is sudden, complete cessation of mobility and sensation, with immediate total loss of the tendon reflexes, we must conclude that there is an irreparable total transverse lesion of the cord; but if, on the other hand, evidences of incomplete division of the cord become apparent in a few hours or days, if not at once (*i.e.* slight sensation remaining), then the prognosis is much more favourable.

Many cases have been described (McCosh) in which, at first, although all the signs of a total transverse lesion were present, improvement and recovery followed operation. On the strength, therefore, of this evidence, surgical interference would seem to be indicated, even in the most desperate cases.

Mixter and Chase have shown that in spite of the loss of conduction, normal fibres may still exist in the crushed area of the cord.

The question whether the actual conductivity of the cord can be re-established by early suture in cases where it has been completely divided (as has been attempted by Fowler and Stewart)[3] cannot be determined with certainty from the cases that have been published.

[1] Sultan, *D. Zeitschr. f. Chir.* Bd. 78.

[2] Munro, *55th Report of the American Medical Association.*

[3] *Annals of Surgery*, Oct. 1905.

10. Technique of Laminectomy. The technique[1] is simple in ordinary, *i.e.* not osteoplastic, laminectomy. Experience has shown that the removal of three or four vertebral arches does not materially impair the supporting power of the spinal column. Osteoplastic methods, therefore, have not come into general use. Marion,[2] however,

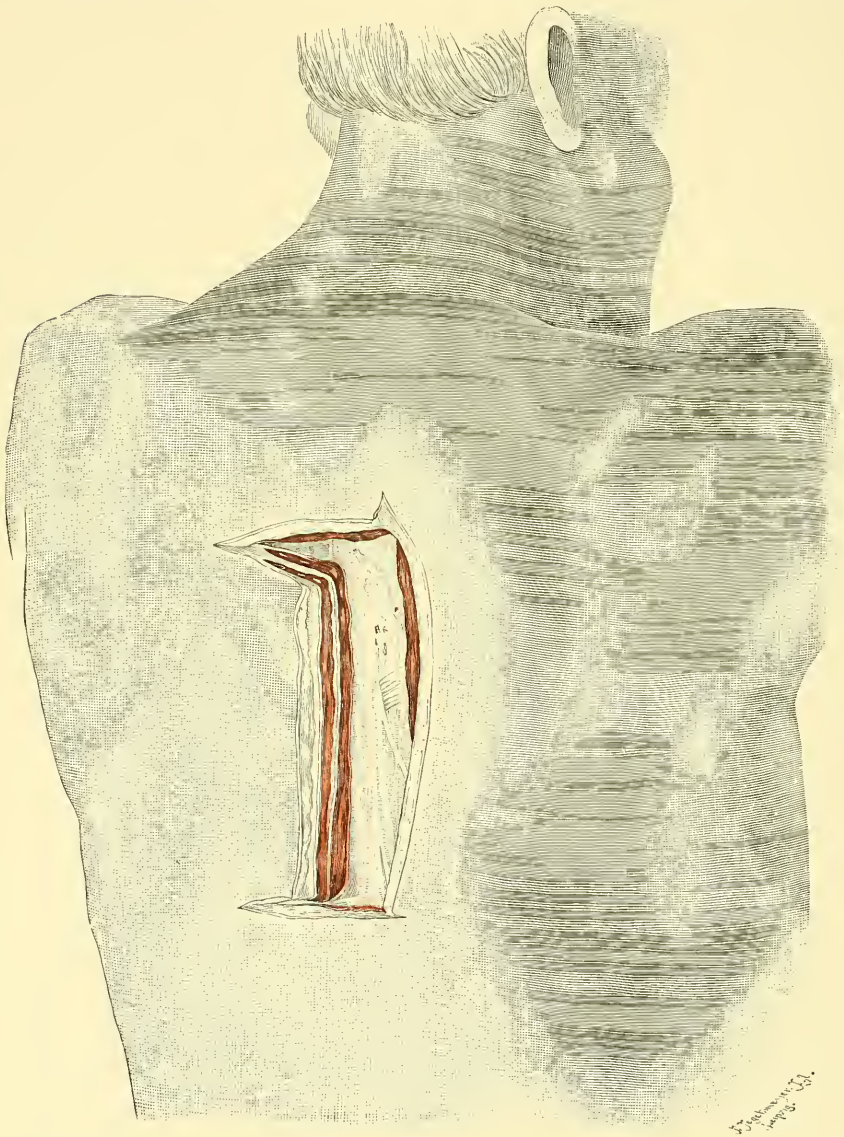

FIG. 96.—Incision for osteoplastic laminectomy. The muscles of the back have been detached from the transverse processes on the right side, and cut across above and below.

speaks in high terms of the osteoplastic operation, especially of the method introduced by Cavicchia and performed by Durante, a method which we also regard with favour.

It is performed as follows: A curved, or preferably an angled incision (see Fig. 96)

[1] Cf. detailed accounts by Chipault, *Étude de chirurgie médullaire*, Paris, 1904, and Marion, *Chir. du système nerveux*, Paris, 1905.

[2] *Chir. du système nerveux*, Paris, 1905.

is made over four or five vertebral spines, dividing skin, fascia, and superficial muscles (above, the trapezius, and the fascia covering the rhomboids, splenius capitis and colli, and the serratus posticus superior; below, the latissimus dorsi and serratus posticus inferior). The large muscles of the back are incised transversely above

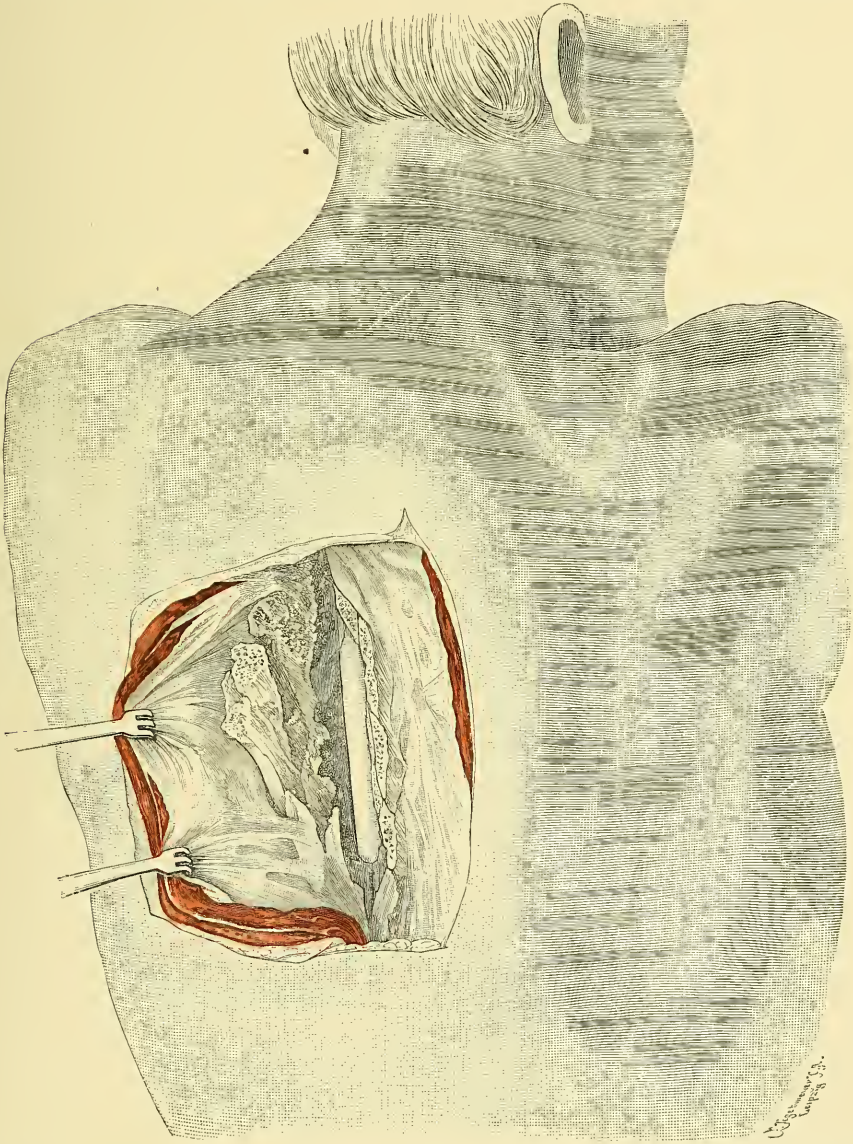

FIG. 97.—Osteoplastic laminectomy, 2nd stage. The spinous processes have been chiselled through at their bases and turned over to the left. The laminæ have been cut across with bone-forceps, exposing the spinal dura.

and below as far as is necessary, namely the longissimus dorsi, with the iliocostalis and the accessorius farther out. The longissimus dorsi is raised and retracted towards the middle line, and, without detachment of the muscles (semi-spinalis, multifidus) which are in direct contact with the arches, a broad chisel is applied

to the roots of the spines, which are then divided, and forcibly retracted to the other side with strong hooks. Hæmorrhage is considerably lessened by avoiding excessive dissection of muscle off the bones. The vertebral arches are now sufficiently exposed and a pair of forceps is inserted under them on each side, after which they are cut across and removed. The dura then lies exposed.

The osteoplastic exposure of the cord is shown in Figs. 96 and 97.

Bickham[1] also advocates an osteoplastic operation, employing, however, the method described by Urban in 1902.

The normal operation, as practised by most experienced surgeons and recommended by Harte, who collected a series of 92 cases, is performed as follows: A long mesial incision is made over four or five vertebral spines. It is important to carry the incision sufficiently high up, as the lesion of the cord is frequently at a higher level than is expected. The muscles are rapidly separated with the knife on both sides from the spinous processes and retracted with strong hooks covered with gauze, through which pressure can be applied and the bleeding, which is often considerable, controlled.

There is no advantage in trying to separate the muscles subperiosteally, as the periosteum can be more easily detached from the roots of the spines and from the posterior surfaces of the arches. The most important point, according to McCosh, is to effect the separation as rapidly as possible without stopping to secure vessels, by which means the bleeding is most effectively reduced.

Having examined the extent of the injury, the operator then proceeds to divide the bases of one, two, or three spines with strong specially-curved cutting forceps (Horsley), after which the laminæ on either side are removed with Luer's gouge forceps.

The bleeding, even before removal of the bone (or immediately after exposure of the fatty tissue and the venous arches between the dura and the bone) may be so severe that it is advisable to plug the wound and delay, for a day or two, the completion of the operation. The two-stage operation has proved most successful in Auerbach's and Brodnitz's hands, and is specially to be recommended in difficult cases.

The extradural fatty tissue and veins are then incised in the middle line, after which the further procedure will depend on the nature and extent of the lesion. If the tumour is situated within the dura, or if the dura is implicated in the inflammatory process, and caseous or granulation tissue has been deposited on its inner surface, or if it is thickened and adherent, the dura must then be split open in the middle line with scissors.

On opening it the escape of cerebrospinal fluid may be excessive, so that it is advisable, first of all, to lower the head and shoulders, as is recommended by Auerbach and Brodnitz.

The spinal cord is now exposed. If the tumour or diseased focus is situated on its anterior aspect, or if the operator wishes to divide the nerve-roots, the cord must be lifted up on an aneurysm needle. If necessary the nerves may even be divided in the dorsal and lumbar regions where their loss does not involve any material disturbance. When the spinal cord is found to be cut across, the question of suture may be considered, but only if the cut edges are not bruised.

The dura is finally closed with interrupted sutures without drainage, but if the bleeding has not been entirely arrested a drain must be inserted.

F. SURGERY OF NERVE-ROOTS

(a) Intracranial and Intraspinal Nerves

There is this similarity between the surgery of the brain and the surgery of the intracranial and spinal nerves, that in both cases preliminary trephining is necessary.

[1] *Annals of Surgery*, 3, 1905.

Operative measures take the form either of division of the sensory nerve-roots or of extirpation of the ganglia with which they are associated. Apart from the peripherally situated ganglia of the sympathetic, ganglion extirpation is limited to the trigeminal nerve. On the other hand, division of sensory nerve-roots is undertaken in connection with spinal as well as cranial nerves.

11. Extirpation of the Gasserian Ganglion, Division of its Root and Intracranial Branches (Figs. 98, 99, 100). (*a*) *Extirpation of the Gasserian Ganglion.* Although the removal of the Gasserian ganglion is an operation of comparatively recent date, it has occasioned a considerable amount of literature, partly from the fact that brilliant results have been obtained by its means[1] in the treatment of trigeminal neuralgia, and partly because of the almost insuperable difficulties which are occasionally encountered and for which a large number of operative suggestions have been devised.

Those alone who have frequent opportunities of performing the operation can really hope to master the difficulties in technique associated with it, and can expect to obtain the gratifying results which may be procured even in the most obstinate cases of neuralgia, without causing injury to the neighbouring structures.

In the last edition of this work reference was made to the statistics collected by Tiffany, who, in a series of 102 cases, estimates the mortality at 22 per cent. Up to the end of the year 1905 Cushing of Baltimore had excised the ganglion entire in 34 cases (partially in three) with only one fatal result, *i.e.* a mortality of 2.75 per cent). In another series of 100 cases collected by Carson, the death-rate is given as 11 per cent, while Cushing further mentions 50 cases operated on by Lexer and himself in which the mortality was only 5 per cent. Krause had previously operated on 49 cases, but his results do not appear to have been published.

These figures show the advances which have been made in technique since the year 1889, when the operation was unsuccessfully attempted by Macewen and Horsley, and since 1890, when the first successful case was intimated by Rose, with a second case in 1891. Rose employed the pterygoid route which was originally suggested by J. E. Mears in 1884, but this method, although simplified by Novaro in 1891, has now been abandoned. It is to Horsley that the credit is mainly due for having brought into general recognition the "temporal," or, as Cushing terms it, the "high temporal" operation, to distinguish it from the most recent "low temporal" or "temporo-sphenoidal" method. Horsley used it originally simply for the section of the main divisions of the trigeminal nerve, performing his first successful operation in 1888, although subsequently he utilised the same procedure for excision of the ganglion.

The method has been named after Hartley and Krause, because these two surgeons, particularly Krause (Hartley and Krause, 1891), first devised it for the intracranial section of the divisions of the trigeminal. In 1897 Krause produced 14 cases, in 13 of which the operation was successful. Andrews, MacBurney, and J. Roberts, Keen, Tiffany, and others, all reported cases shortly after that of Krause. It is interesting to observe that Krause still adheres to the "high temporal" method which he has performed on 49 occasions.

The latest process of reaching the ganglion, viz. by the temporo-sphenoidal route with division of the zygoma, was, according to Peyrand,[2] originated by Doyen in 1893, and was carried out in a cumbrous form by Poirier, till it was finally perfected by Quénu in 1894. Since then it has found many adherents and has provided the most satisfactory statistics. In our fourth edition we alluded to this method as Cushing's operation. Cushing himself states that Coelho first suggested the modified resection of the zygoma, which Lexer has lately still further simplified. From the statistics already given the "low temporal," or temporo-sphenoidal route should be selected, and since we adopted it our results have been considerably improved.

[1] As far as we can judge from our own experience, and from the literature published on the subject, excision of the ganglion gives most certain end-results as soon as the immediate risks have been removed.

[2] Thèse de Bordeaux, 1902.

We always use the same incision as that described and illustrated under section of the root of the third division of the trigeminal nerve, as we consider that the branches of the facial nerve are least injured by this method (a point also recognised by Lexer), and further because it entails no division of muscle. For the direction of the skin incision, division of the fascia, resection of the zygoma and the method of raising the periosteum together with the muscle, the reader is referred to Fig. 108, p. 225.

As the photograph (Fig. 98) shows, practically no disfigurement is produced.

Cushing and Lexer turn down a temporal flap similar to that in the Hartley-Krause method, but not extending so high up on the skull.

They endeavour to avoid injury to the branches of the facial nerve by paying special attention to the direction of the skin incision where it begins and terminates. Lexer places the base of his flap almost exactly in the direction we have recommended for avoiding the facial nerve, viz. along a line corresponding to the lower part of our angled incision (*vide* Fig. 99), *i.e.* the posterior extremity of his incision on the root of the zygoma lies a finger's-breadth in front of the ear, while the anterior end is placed over the body of the malar bone a little behind its frontal process. The convexity of the flap does not extend above a horizontal line through the tip of the auricle.



Fig. 98.

Cushing does not carry the anterior limb of his incision far forward, so as to avoid the frontal branch of the facial nerve, and dissects the skin and temporal fascia downwards and forwards, before he divides the temporal muscle.

The flap is turned down together with the periosteum, and the anterior and posterior extremities of the zygoma are exposed and divided with a Gigli's saw, chisel, or strong bone-forceps. Posteriorly, the zygoma is divided at its root, while anteriorly it is cut across at the body of the malar so that sufficient room may be obtained. Cushing removes the entire zygomatic arch subperiosteally, and maintains that this method is advantageous even from the point of view of disfigurement, as with the subsequent sinking-in that occurs, the atrophy of the muscles of mastication is less noticeable. Removal of the zygoma complicates the operation to a considerable extent, while there is a further risk of the facial nerve being torn when the bone is forcibly depressed with a hook, which may result in facial paralysis. Possibly the case reported by Anschutz might be explained in the same way. The fascia and pad of fat lying under the arch must be carefully preserved.

The lowest part of the temporal fossa is now exposed, down to the infratemporal crest, and the periosteum and soft parts are carefully separated from the base of the skull (*i.e.* from the great wing of the sphenoid), till the sharp border of the pterygoid process behind which the foramen ovale lies, is observed. Hæmorrhage from the

pterygoid plexus of veins is arrested by forcible depression of the soft tissues with a blunt hook covered with gauze and by the application of pressure, when the foramen ovale through which the third division of the nerve passes can be either seen or felt.

The skull is then opened a thumb's-breadth above the infratemporal crest with a chisel or Doyen's burr, and the opening is enlarged in front and behind with gouge forceps, the dura at the same time being raised off the bone as far as the foramen

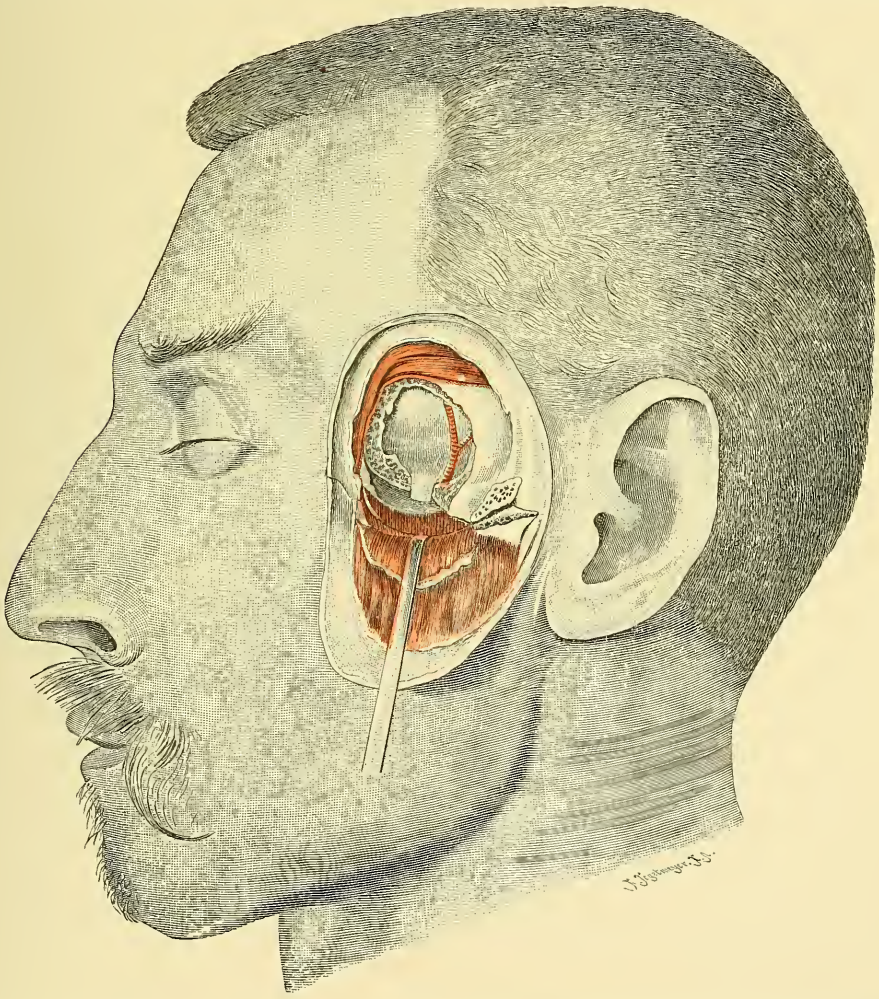

FIG. 99.—Exposure of the Gasserian ganglion by the temporo-sphenoidal route. The Lexer-Cushing incision has been made, and the zygoma divided. The base of the skull has been chiselled away to expose the third division at the foramen ovale. The middle meningeal artery is seen on the dura, which has not yet been incised.

ovale and foramen rotundum. The low position and limited size of the opening required have, according to Cushing, the advantage over Krause's higher method that the groove (often a canal) in the parietal bone, in which the middle meningeal artery lies, is avoided; the bleeding from the injured artery in this position is very difficult to control.

With the low temporal opening (reaching at most 3 cm. in height) there is, further, less chance of the brain being injured when it is held out of the way by means of a retractor. According to Cushing, Krause, who employs the higher opening, has reported superficial bruising of the brain at eight autopsies, and Poppert has described a case of hemiplegia (and death) as a result of pressure by the retractor during Krause's operation (*Deutsch. med. Wochenschrift*, No. 22, 1906).

The dura is then rapidly separated from the bone with the finger or with forceps covered with gauze (or a blunt dissector) as far as the foramen spinosum, ovale and rotundum. Lexer, like Krause, now ties the exposed middle meningeal artery, so that the dura may be more freely raised towards the root of the ganglion, at the same time avoiding the risk of accidentally tearing the artery.[1]

A number of surgeons, following v. Bergmann, regard it as very important that the patient should sit upright before the dura is opened in order to limit the venous hæmorrhage and the loss of cerebrospinal fluid, while at the same time the lowering of the pressure permits of the brain being retracted.

The dura is now incised by cutting on to the bone in the interval between the second and third divisions of the nerve, and detached backwards along the outer and upper surfaces of the ganglion as far as the root. The root is then elevated from its bed by passing a long slender spatula underneath it, and if possible it should be raised up with a hook or small aneurysm needle to ensure that it is thoroughly isolated.

The root is grasped with a pair of Kocher's long artery forceps, and the ganglion is raised and freed as much as possible, after which the second and third divisions are divided at their exit from the skull. Traction is then made on the ganglion by pulling on the third division, thus stretching and facilitating the section of the first division of the nerve. Finally the root is torn away.[2]

Very free hæmorrhage is encountered, and attempts to control it by plugging are apt to produce severe shock similar to that caused by retraction of the dura by a spatula. It is for this reason that Cushing carefully observes not only the pulse but also the blood-pressure during the operation in order that any fall of blood-pressure due to interference with the vasomotor centre may be at once recognised.

The after-treatment is carried out on general lines, the wound being completely closed as soon as one is convinced the hæmorrhage has been arrested. Should some oozing still continue, a drain or strip of iodoform gauze should be inserted.

12. Summary of the Technique which we regard as best. Excision of the

[1] Krause grasps the vessel with artery forceps, where it lies exposed between the dura and the foramen spinosum for a distance of about 1 cm., and ligatures it on the proximal side, after which the forceps are removed. He then separates the dura as far as the upper border of the petrous temporal, arrests the hæmorrhage, and by blunt dissection frees the ganglion from its bed and grasps the root with forceps.

Cushing, on the other hand, finds on separating the dura that the artery runs a straight course between the two fixed points, viz. the foramen spinosum and the groove in the parietal bone, and that, as it is not abnormally stretched, it can be easily avoided. Lexer has shown that when the bone has been removed down to the base of the skull, as described above, the artery can be quite readily ligatured extracranially.

In certain circumstances the best method of arresting the hæmorrhage is by means of temporary occlusion of the common carotid.

[2] All surgeons are agreed in regard to restricting the hæmorrhage that occurs on freeing the inner surface of the ganglion. Lexer avoids freeing the ganglion there, while Cushing postpones it to the last, and only separates it just before dividing the branches and the root, as does Krause also. Lexer begins by raising up the third division on a hook, and then passes a loop of thread round it, so that by pulling on it the ganglion will be put on the stretch. He then separates the dura on the upper surface of the ganglion until the ophthalmic division in front and the root posteriorly are exposed. The latter is then pulled upon by means of a hook. He now divides the second division and the root, after which the first division is exposed by drawing down the ganglion, and is cut across, leaving the ganglion only connected with the third division.

Krause first of all divides the second and third divisions, and after having freed the ganglion grasps it in forceps and twists out the first division and the root. Cushing, who has published excellent statistics, divides the branches first, then frees the ganglion thoroughly by blunt dissection and tears out the root. The risk of injuring the cavernous sinus is thus greatly diminished. The bleeding following accidental tearing of the sinus is very copious.

Gasserian ganglion is an operation necessarily associated with unusual difficulties, and every surgeon who operates on his first case must be prepared to cope with a situation which in some cases may be exceedingly embarrassing. Before undertaking the operation he will do well to practise it several times on the cadaver, and take every opportunity of seeing it performed by those who specialise in surgical neurology.

In many of the cases on which one is called upon to operate, medical treatment and surgical measures of a less drastic nature have already been tried in vain. Of the latter neurexeresis is the most effectual. It is in such cases, however, that excision of

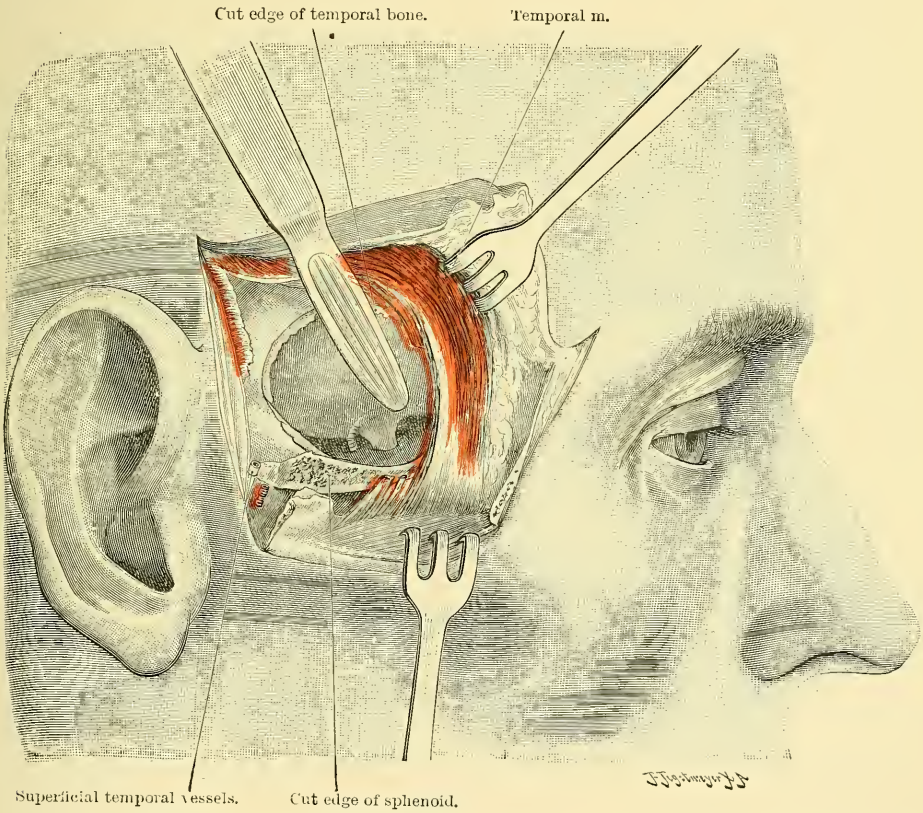

FIG. 100.—Excision of Gasserian ganglion through an angular incision. The zygoma is divided in front and behind and turned downwards, the temporal muscle being freed and drawn forwards. The skull is opened, and the bone at the base of the skull removed. The dura is raised up, exposing the middle meningeal artery at the foramen spinosum and the third division of the trigeminal nerve.

the ganglion is especially indicated, as it affords the most certain cure of facial neuralgia. The operator must be prepared for these cases, the difficulties of which may be to a large extent overcome by attention to the following points.

In the first place, ligature of the external carotid (Friedrich) is of real advantage as it limits the bleeding, although it may be dispensed with by an experienced surgeon. It is easily performed and might also be combined with temporary compression of the internal carotid.

The position of the patient is of great importance. The half-sitting posture (advocated by Villar and Ricard) is to be recommended. The head must, however, hang well back over the end of the table, so that the blood and cerebrospinal fluid

may escape freely instead of collecting at the base of the skull, and so that the brain may fall back into the cranial cavity.

It is of no great consequence whether the skin and fascia be divided by an incision convex downwards (as in our method) or be horseshoe-shaped, with the convexity upwards (Hartley-Krause). The branches of the facial nerve (zygomatico-temporales) which supply the orbicularis and occipito-frontalis muscles must, however, be avoided where they cross the malar bone (as in our method and in Cushing's). The incision we employ is shown in Fig. 100, the superficial temporal vessels being ligatured where they cross the zygoma, and the temporal fascia raised along with the periosteum from the upper border of the zygomatic arch, after which the latter is divided subperiosteally in front and behind.

Surgeons who have had little experience of the operation will find that a subfascial division of the zygoma (Doyen) as far in front and behind as possible is an advantage, as by turning it downwards considerably more room is obtained. Further, it is easier when trephining to remove the bone (as Horsley invariably does) instead of insisting on an osteoplastic operation. The reposition of the bone is of no real advantage when one considers the small size of the defect that is left. It is also advisable to raise the periosteum and soft parts not only on the temporal side but also on the base of the skull, and to remove the bone to within a finger's-breadth of the foramen spinosum, ovale, and rotundum, a procedure which makes the determination of the ganglion more easy and entails less removal of bone on the temporal side. We detach the periosteum and soft parts on the temporal side for a distance of 3 cm. and for an equal distance on the under surface of the skull, and then with a few strokes of the chisel above and at the sides, rapidly remove as large a piece of bone as possible from this area. On raising the flap of bone it breaks easily at its lower border.

After the foramen ovale has been exposed and the dura elevated, the latter is then incised over the third division of the nerve (which is 6 mm. long), and is dissected backwards from this point off the upper surface of the ganglion. On account of firm adhesions this must be effected by means of a fine knife or a delicate dissector with comparatively sharp edges. The middle meningeal artery which ascends on the dura can easily be traced to the foramen spinosum, and when the dura is raised up it can be readily reached and ligatured. If a preliminary ligation of the carotid has been performed, the artery can be simply cut across at the foramen spinosum, thus avoiding further trouble in detaching the dura from the base. The dura should be raised by means of a slender flexible spatula, and the portion covering the upper surface of the ganglion (6 mm. in length) which is always firmly adherent, should be dissected off from before backwards as far as possible. The adhesions here are very firm, and in freeing them the operator must cut down on to the ganglion until, according to Prat, the smooth cavity in which the root of the ganglion lies is suddenly entered.

This "portion retrogasserienne" or plexus triangularis is entirely free from adhesions with the dura for a length of 9 mm., according to Peyraud, so that the root can therefore be most easily isolated in this space with less risk of injury, and after it has been raised up on a hook, it is grasped with suitable forceps (without including the dura) and *very gradually* twisted out. Of course on the inner side, where the petrosal sinuses open into the cavernous sinus, it is necessary to keep close to the root.

If the root has been thoroughly isolated and grasped with forceps, one need not make a point of removing the ganglion. We have never met with a case in which neuralgia recurred after the root of the ganglion had been torn away.

Surgeons who have had considerable experience of the operation raise the ganglion from its bed by blunt dissection, and, after incising the dura in a forward direction, cut through the second and third divisions just in front of their respective foramina, after which the ganglion is torn out by the root, and the first division twisted, or better, simply cut with the knife. This entails, however, very severe bleeding, owing to the tearing of the veins which accompany the nerves and those which enter the bone on the under surface of the ganglion, and for the arrest of which plugging is necessary.

The wound is closed with deep sutures, including the skin, muscle, and fascia, no drain being inserted if the bleeding has been completely arrested.

(*b*) *Division of the Root of the Gasserian Ganglion (the Operation of Spiller and Frazier after Van Gehuchten).* This operation was first performed unsuccessfully by Horsley in 1890—before excision of the ganglion had been attempted,—and has been raised to the status of a recognised method by Spiller and Frazier, after whom it is named. Spiller[1] originally suggested it as a substitute for excision of the ganglion. Both authors jointly published their experimental researches, while no little credit is to be assigned to Van Gehuchten. Frazier performed the first successful operation on man. He and Spiller describe the method as "Physiological Extirpation of the Gasserian Ganglion" (Van Gehuchten).[2]

Simple division of the root, which constitutes a preliminary stage of the more severe and bloody operation of excision of the ganglion possesses undoubted advantages. The most severe bleeding follows separation of the ganglion on its under and inner aspect (sinus cavernosus), especially if there are firm adhesions. This does not occur, however, in section of the root.

Injury to the nerves in the wall of the sinus is avoided (oculomotor, trochlear, and abducent), while the duration of the operation is shortened and shock is diminished. The only question is whether the operation fulfils its real object, *i.e.* whether by division of the root a permanent degeneration of the fibres running centrally from the ganglion is obtained, with the result of a radical cure. Frazier, Spiller, and Van Gehuchten are of one opinion that degeneration occurs down to the bulbospinal root, while, according to the last-named author, the fibres remain permanently atrophied.

If this is the case, simple section of the root has certainly advantages over extirpation of the ganglion, not only in regard to the dangers of hæmorrhage and injury to neighbouring parts, but also in regard to the conditions of the eye. Without any precautions being taken, no ill effects are noticed on the eye, and the so-called trophic changes are absent.

Frazier and Spiller look for the explanation of this in the fact that, according to Kreuzfuch's researches, sympathetic nerve-fibres are contained in the first division of the trigeminal just as Budge had previously demonstrated the existence of pupil-dilating fibres in the Gasserian ganglion and in the fibres of the trigeminal (especially the first division) peripheral to the ganglion.

Frazier points out the further advantage that the motor root, which runs internal to the sensory root and on the under surface of the ganglion, may be preserved while the sensory root is divided, by which means atrophy of the muscles of mastication can be avoided.

In four cases operated on by Frazier, there was no repetition of the pain, while we have also found brilliant immediate results with, up to the present, no recurrence.

In our opinion there is a future before this operation; and we consider that it should replace extirpation of the ganglion, at any rate in difficult cases associated with continuous bleeding, or when the ganglion is firmly adherent.

The technique of the operation has already been described in detail under excision of the ganglion. If the root cannot be satisfactorily exposed and cut across low down, it may be divided at its junction with the ganglion. In tumours of the ganglion, the ganglion must, of course, be removed.

(*c*) *Intracranial Section of the Divisions of the Trigeminal.* This operation has been occasionally resorted to in difficult cases. Horsley performed it in 1888 (the first intracranial operation on the trigeminal nerve), and also in 1891, both times with success, while it was also undertaken in 1891 by Hartley and in 1892 by Krause. We have resorted to it in cases where excision of the ganglion was impracticable on account of incessant bleeding. According to Van Gehuchten, in 1881 Blum performed the operation, which was subsequently repeated by Doyen.

Abbé considers the method as effective as excision of the ganglion and recommends its general adoption.

In this operation only the second and third divisions are divided, so that it is not to be undertaken when the neuralgia also affects the first division. In comparison

[1] *American Journ. of Med. Sc.*, Nov. 1898.
[2] *Bull. acad. royale de méd. belgique*, Aug. 1903.

with the method described in (*a*) and (*b*) the difficulties are considerably less as it is relatively easy to isolate the second and third divisions; and the only question in the technique is whether the nerves should be cut across or torn out in the manner practised by Thiersch for the peripheral branches of the trigeminal.

Van Gehuchten [1] contends, and Spiller confirms his view, that when the branches are divided on the distal side of the ganglion the cells in the latter do not atrophy, but that when the nerves are torn out, a degeneration, not only of the nerve-fibres but of the corresponding ganglion cells, takes place right up to the bulbospinal root.

Van Gehuchten, from his experiments, recommends extracranial avulsion of the principal branches; while Chipault [2] maintains that complete peripheral resection of all three divisions of the nerve in most cases gives as good results as the much more serious resection of the ganglion. Incomplete peripheral resection is less satisfactory. Dege has recorded the results of resection of the peripheral nerves (Krause) in 55 patients, whose subsequent history he was able to trace. Only 11 were free from recurrence, while of the others the average period of freedom was two years and two months. In 77 resections he had three deaths. The immediate results, which we have observed after intracranial section, have been entirely satisfactory, but have not always been permanent. According to Van Gehuchten's and Spiller's experiments, exeresis with Thiersch's forceps is preferable to simple division. It is essential, however, to isolate thoroughly the branches before twisting them.[3]

Abbé has recorded satisfactory results from the method he adopts for preventing the reunion of the nerves after division, viz. by the interposition of gutta-percha tissue between the dura and the respective foramina.

We agree with Bockenheimer that it is just as difficult to expose the branches of the trigeminal at the base of the skull extracranially as it is to attempt intracranial exposure, especially of the second division.

There is still another procedure, which is considered in a later chapter, for the cure of trigeminal neuralgia, viz. resection of the sympathetic.

13. Division of the Posterior Roots in the Spinal Canal. The performance of intradural resection of the posterior nerve-roots at the point where they leave the cord is only to be considered when the pain is caused by affections of the meninges and cannot be relieved by any other means, as also in the case of neuralgia when all other methods of treatment have failed.

The results of this operation have hitherto been far from encouraging. Not only does Chipault record two fatalities in 7 cases, but it is certain that the recoveries in other reported instances (McCosh, Munro) were incomplete, local pain persisting and even motor paralysis being observed, so that the operations should be restricted to cases of extreme necessity.

In regard to the technique, the reader is referred to the description of laminectomy. After the dura has been opened, the nerve-roots may with comparative ease be lifted up and divided, either close to the cord or at the point where they pierce the dura.

If severe bleeding is encountered either before or after the dura has been opened, the operation may with advantage be performed in two stages.

G. SURGERY OF INDIVIDUAL PERIPHERAL NERVES

(a) General Remarks on Surgery of Nerves

Exposure of peripheral nerves is, as a rule, undertaken with the object of either temporarily or permanently interrupting conduction to the nerve-centres in painful conditions of the nerve, *i.e.* neuralgia. Permanent abolition of conduction is obtained

[1] *Bull. acad. royale belgique*, Aug. 1903.

[2] *Indépendance médicale*, No. 25, 1901.

[3] Laplace (*New York Med. Journal*, Dec. 1905) reports 4 successful cases in which, in the course of twenty minutes, he twisted the peripheral branches on a pair of forceps.

by avulsion or tearing out of the nerve (Thiersch's Neurexeresis). Simple section, neurotomy and neurectomy, afford much less reliable results.

On the other hand, motor nerves are also cut down upon in order to restore their function, especially when the nerve is adherent to, or is compressed by, some adjacent structure. Removal of the pressure and the separation of the adhesions often effect a permanent cure in neuralgia, while nerve-stretching is employed for the same purpose. By simply freeing the nerve motor symptoms can also be cured, and there is no doubt that surgery lags behind in regard to the treatment of traumatic lesions of nerves, *e.g.* by removing an effusion of blood either in or around a nerve, the function of the nerve can be restored even if it has been impaired for a considerable time. Tumours and cicatrices in the course of a nerve may be excised and conduction re-established by suture. The ends of the nerve must be sutured soon after division, otherwise they retract and become surrounded by a mass of connective tissue.

It is essential that healthy nerve-fibres should be brought into accurate contact and be supported in loose connective tissue.

Tubulisation of nerves has been employed with advantage in order to prevent the formation of adhesions at the site of suture, and to ensure the outgrowth of nerve-fibres from the central into the peripheral end. Foraminti[1] wraps up the nerve in an artery removed fresh from an animal or in one that has been hardened. If a fresh artery is utilised only delicate adhesions are formed with the intima; if a hardened artery is employed, it is first of all drawn over a glass tube, then fixed in formalin, washed, and boiled.

When the ends of the nerve cannot be approximated, portions of fresh animal nerve may be made use of to fill up the gap in order to aid the downgrowth of nerve-fibres from the central end.

A form of nerve-grafting which is of special interest in connection with the cure of paralysis (facial) consists in the union of a divided nerve with one still in normal connection with its centre. We shall deal more fully with nerve-grafting in considering the surgery of the nerve, only mentioning here that it has also been employed in the extremities in cases of infantile paralysis. Hackenbruch[2] records a case in which a very satisfactory result was obtained by implanting the posterior tibial nerve into the paralysed arterior tibial nerve. He exposes the nerves in the lower third of the thigh where they are deeply situated. The posterior tibial nerve is divided for one-third of its thickness, split longitudinally upwards, and the freed portion grafted into a slit in the anterior tibial nerve. As an alternative, one might endeavour by cutting the nerves almost completely across, to approximate them end to end, so that the sutures may be inserted laterally away from the cut surface.

(b) Cranial Nerves

In the chapter on trigeminal neuralgia we have already encroached on the surgery of individual cranial nerves. We shall now consider the subject methodically.

As far as we are aware, there is an entire absence of operations on the olfactory nerve.

14. Surgery of the Optic Nerve. The optic nerve is exposed in excising tumours situated in the orbit which are in contact with or growing from the nerve. An incision carried horizontally outwards from the external canthus affords good access to the space behind the eyeball. By detaching the orbital periosteum upwards and downwards, and removing a wedge of bone with a chisel from the outer wall of the orbit, the outer and posterior surface of the eyeball can be readily exposed without entailing any injury.

Krönlein's osteoplastic resection is the operation generally employed. We practise it in the modified form recommended by Franke (Fig. 101).

An incision is made below the eyebrow on the outer half of the supraorbital margin and is prolonged downwards to the junction with the infraorbital margin, from which point it is then carried backwards over the malar bone to the middle third of

[1] Langenbeck's *Archiv*, Bd. 73. [2] *Deutsche med. Wochenschr.*, 1905, No. 25.

the zygoma. The zygoma is divided subperiosteally, and the zygomatic (external angular) process of the frontal bone, which forms a distinct crest, and which, along with the sphenoid, helps to form the postero-lateral wall of the orbit, is chiselled through subperiosteally as far as the spheno-maxillary fissure. The malar bone is then divided through the antero-inferior angle of the incision, the line of division extending backwards into the spheno-maxillary fissure and outwards as far as the attachment of the masseter, after which it is forcibly dislocated out of the wound. The rest of the crest-like projection of the sphenoid, which forms the lateral wall of the orbit, is clipped away, thus exposing the orbital fat in which the nerve is embedded and the lachrymal gland (Fig. 101).

Our incision has the advantage over that recommended by Krönlein in that (as Bockenheimer has shown) it causes no injury to the branches of the facial nerve either to the upper or the lower lid. The disfigurement is in consequence less; while

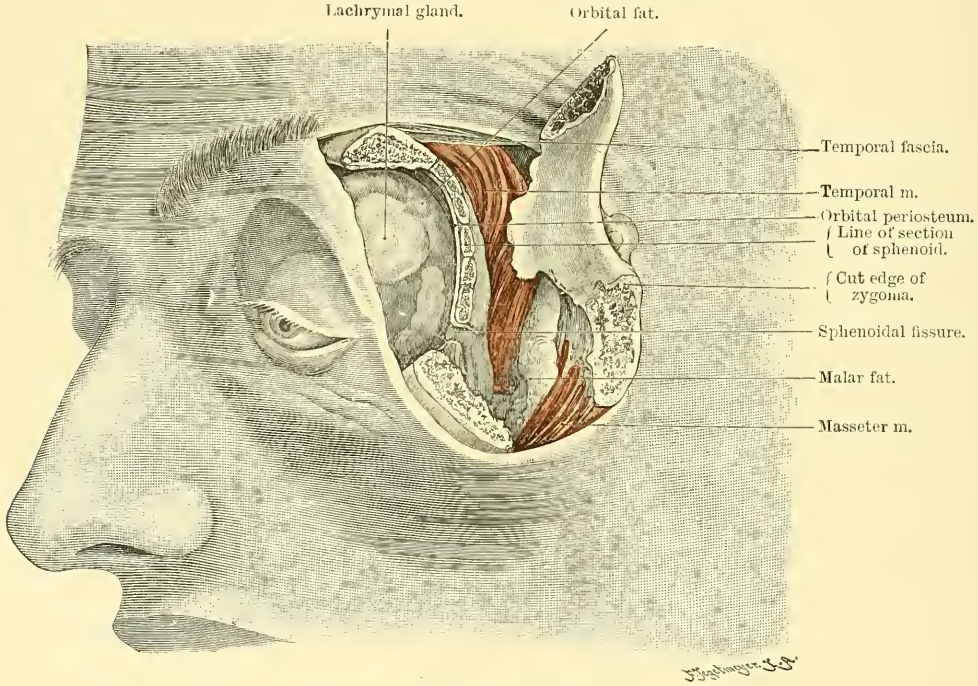

FIG. 101.—Osteoplastic exposure of the orbit.

it has the further advantage of giving more room, especially above, as it enables the operator to divide the bone more easily and more freely. The importance of this is observed from Heilbron's statistics of 120 cases, in which it is shown that after Krönlein's operation for the removal of tumours of the orbit, the mobility of the eye was frequently impaired, as the muscles and their nerves could not be sufficiently preserved. The better the access the less liable is the optic nerve to be injured.

Occasionally even more room may be required than is given by our modification of Krönlein's operation. Czermak has recommended in cases where Krönlein's operation gives insufficient room, the removal not only of the lateral border of the orbit, but of the whole malar bone as well, the latter being divided at its articulation with the superior maxilla and the zygoma. The disarticulation of the superior maxilla should be undertaken through a special incision.

According to Heilbron,[1] Becker performs a still more thorough operation, while

[1] See details of Krönlein's operation, Domela and Heilbron, Berlin, 1905.

Rollet's operation, in which the skin incisions correspond to the line at which the bone is divided, is also an excellent method as regards the direction of the skin incision.

Tumours in the upper and inner parts of the orbit must be approached by a different route if the eyeball is to be preserved, namely, by our normal incision for exposing the upper part of the nasal cavity. An incision is made from the eyebrow on to the bridge of the nose. The nasal bone and the nasal process of the superior maxilla are divided, while the ethmoid may perhaps also be removed (*vide* Operation to expose the nasal cavity).

Our method permits of the bone being replaced without causing subsequent deformity, and as the branches of the facial (ramus maximus, and rami zygomatico-temporales Bockenheimer) remain uninjured, the movements of the lids are in no way impaired.

The osteoplastic method of exposing the orbit, which was originally proposed by

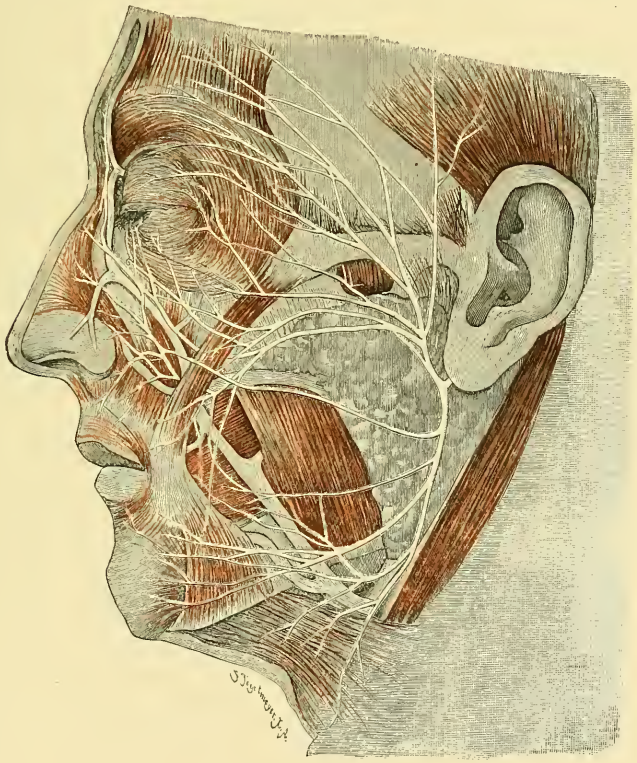

FIG. 102.—Ramifications of the facial nerve (after Bockenheimer), to illustrate the proper direction of incision on the face. The figure shows the three large branches which ascend over the zygoma, the subzygomatic branches, and the division which is distributed to the neck and lower lip.

Krönlein, has given satisfactory results in dealing with tumours of the optic nerve, as well as with single tumours in the orbital fat. According to Heilbron, it is unsuitable for the extraction of foreign bodies. Not long ago we successfully extracted a bullet by means of temporal resection. In inflammatory conditions of the orbit an osteoplastic operation is not indicated.

We are not aware of any operation having been performed on the oculo-motor and trochlear nerves. On the other hand, the **fifth cranial nerve (trigeminal) and its branches** are dealt with surgically for the treatment of neuralgia.

Before the introduction of the intracranial operation of excision of the Gasserian ganglion or its root, the divisions of the trigeminal nerve were severed as near as

possible to the base of the skull. But although the second and third divisions could be divided in this way, section of the first division was impracticable.

Division of the peripheral branches of the trigeminal is at the present time practised more frequently than the intracranial operation, because in neurexeresis (Thiersch) a much more effective method of treatment has been found than that of simple neurotomy. It was devised as a result of van Gehuchten's histological and

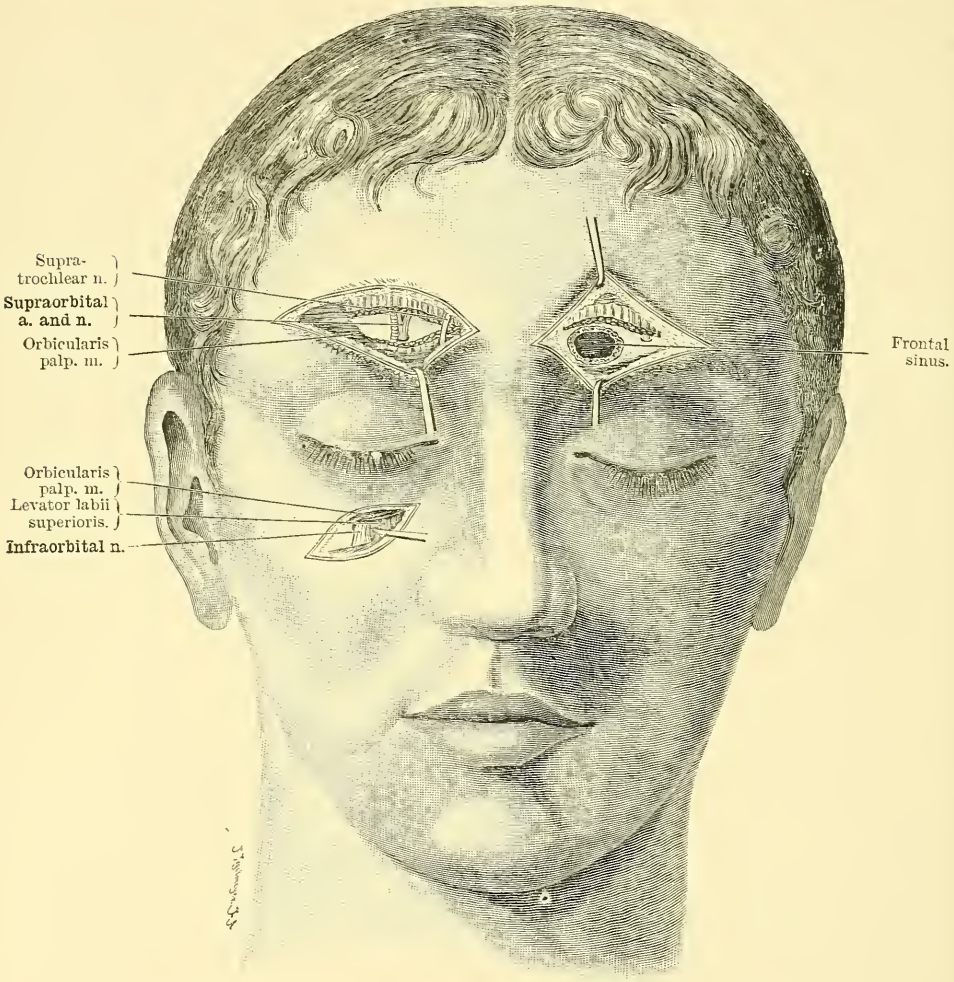

FIG. 103.—Ligature of the supraorbital artery. Exposure of the supraorbital nerve. Infraorbital nerve. Opening of the frontal sinus.

experimental work. Only a limited portion of a nerve requires to be exposed, after which it is seized with strong forceps, twisted, and torn out both from its central and peripheral connections. According to van Gehuchten, when the nerve is partly torn out instead of being simply divided, a greater effect is produced on the central ganglion cells, more especially on those in the Gasserian ganglion, and in the sensory root to the bulbospinal centres. The method which Blum first practised on the infra-orbital nerve gives the greatest certainty of success, while, as no extensive preliminary dissection is required, the operation is greatly simplified. In the following sections

we therefore describe typical operations by which definite portions of the nerve are most easily and most safely exposed, and begin with the operations to expose the main trunks at the base of the skull.

(*a*) *First* (*Ophthalmic*) *Division of the Trigeminal Nerve.*—Of the three branches of the ophthalmic nerve, the lachrymal, which supplies the lachrymal gland, is of no surgical interest. Only the nasal and frontal branches require consideration.

(1) Frontal Nerve (Fig. 103). In the accompanying figure (Fig. 103) both branches of this nerve are shown exposed, the larger supraorbital nerve lying external and the smaller supratrochlear internal. The supraorbital notch (frequently a foramen), which can be readily felt through the skin on the orbital margin, transmits the nerve as it passes from the orbital cavity on to the forehead, the artery of the same name occupying a superficial position. The supratrochlear branch lies 1½-2 cm. to its inner side, and ascends vertically over the inner canthus.

To expose these nerves an incision is made along the lower border of the eyebrow down to the supraorbital margin, thus avoiding the zygomatico-temporal branches of the facial nerve which pass horizontally forwards, as well as those branches which ascend from below to supply the pyramidalis nasi and corrugator supercilli muscles (Fig. 102). The terminal branches of the frontal and supraorbital arteries are divided and ligatured.

By depressing the eyeball and freeing the artery (which has been already tied) both nerves are followed backwards under the periosteum of the roof of the orbit till the parent stem is exposed. The latter is then seized and twisted out with Kocher's artery forceps.

If the smaller supratrochlear nerve can be isolated by itself, each nerve may be twisted out individually. The so-called supraorbital neuralgia, which is met with in malaria, and in disease of the frontal sinus, etc., will practically always yield to this treatment.

(2) Nasal Nerve. The nasal nerve gives off the long root to the ciliary ganglion and the two long ciliary nerves (which may be the seat of ciliary neuralgia) and then divides into the ethmoidal branch which supplies the inner surface and tip of the nose, and the infratrochlear branch which is distributed to the eyelids and root of the nose.

The nerve is exposed by an incision extending from the middle third of the eyebrow downwards towards the bridge of the nose, *i.e.* the upper portion of our normal nasal incision. The periosteum and periorbital tissues are carefully raised off the roof and inner wall of the orbit, until the nerve is observed running transversely towards the anterior ethmoidal foramen. If possible, the periosteum should be separated farther back and the nerve traced back to the origin of the infratrochlear, so that the main root can be torn out. Otherwise one must twist out the ethmoidal branch above, and search for the infratrochlear branch close to the inner canthus, and then twist or at least stretch it where it is embedded in the soft parts.

(*b*) *Second* (*Superior Maxillary*) *Division of the Trigeminal Nerve.*—(1) Exposure of the Superior Maxillary Nerve at the Base of the Skull. When the superior maxillary nerve is exposed at the foramen rotundum (Figs. 104 and 105) the only branch which escapes is the middle meningeal nerve to the dura mater. On the other hand the central operation has the disadvantage that branches of the facial nerve, which pass by way of the Vidian nerve into Meckel's ganglion and into the palatine nerves for the muscles of the palate, are paralysed.

The dissection to reach the foramen rotundum is difficult. Langenbeck introduced a tenotomy knife at the outer margin of the orbit below the external tarsal ligament. This puncture method is now given up, as one can never be sure of avoiding injury to neighbouring structures. The infraorbital artery is liable to injury.

Poirier, without resecting any bone, reaches it by dissecting down to the pterygo-maxillary fissure through a vertical incision behind the frontal process of the malar and extending down to the zygomatic arch. This method, however, gives very little room. The rule now, therefore, is to perform a temporary resection of the malar according to the method of Brüns, and according to Lücke's procedure in the modifica-

tion of Lossen-Braun's operation, which preserves the attachment of the masseter, or according to that of Krönlein. All these methods possess the disadvantage that in consequence of the direction of the incision the branches of the facial nerve are not avoided with certainty.[1] Gussenbauer's method is one which gives very good access, but has the same fault. Friedländer, for the second as well as for the third division of the fifth nerve, has employed that portion of our incision for the third division of the fifth which runs from the eyebrow along the posterior border of the malar and the upper border of the zygomatic arch in combination with the method

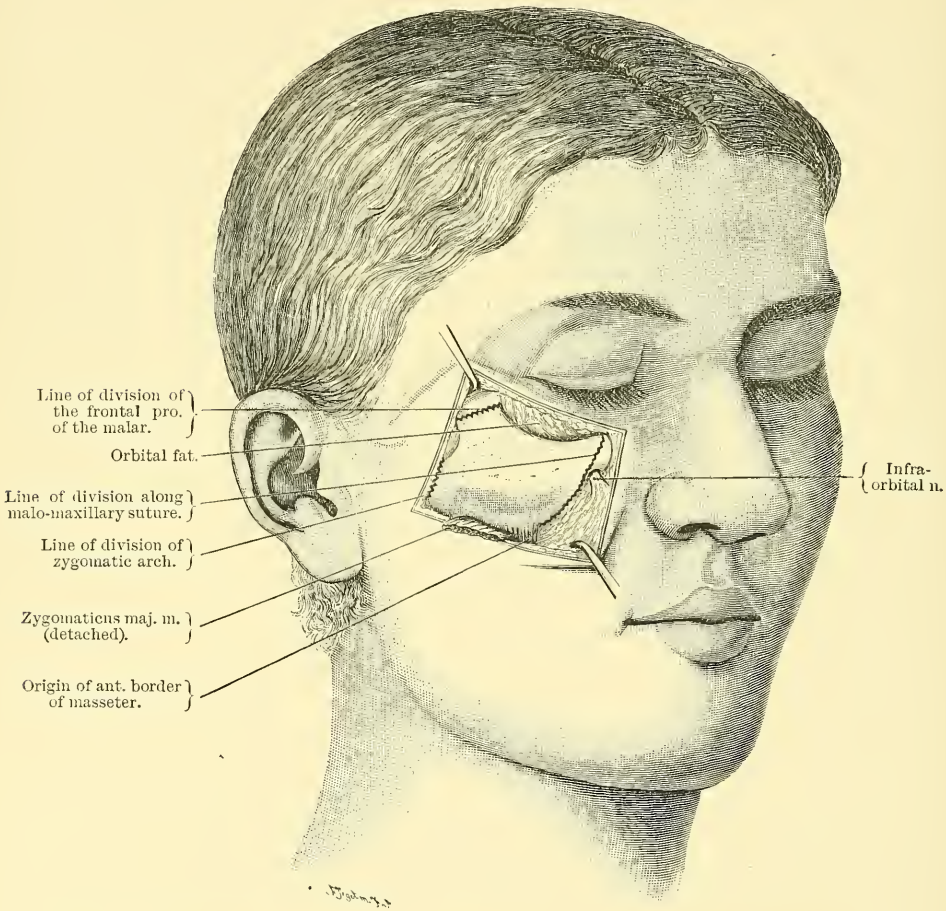

FIG. 104.—Resection of the second (superior maxillary) division of the trigeminal nerve.

described by us for resecting the malar bone. He merely divides the zygomatic arch farther back.

On the grounds of our principle, therefore, of regarding all incisions with disfavour which run at right angles to the branches of the facial nerve, we carry out our method as follows:—The incision is the same as that for exposing the infraorbital nerve, but longer, *i.e.* beginning over the infraorbital foramen and at the inner end of the infraorbital margin, and this is carried horizontally outwards over the lower part of the body of the malar bone to the zygoma. The angular artery is drawn aside or ligatured at the inner end of the incision, whilst Stenson's duct and the greater

[1] Compare Bockenheimer, Langenbeck's *Archiv*, Bd. 72.

branch of the facial nerve lie below it. At its inner end the incision passes down to the bone between the lowest fibres of the orbicularis palpebrarum and above the origin of the levator labii superioris. The former muscle, along with the periosteum, is dissected up as far as the orbit, the latter is separated subperiosteally only so far downwards as that the infraorbital nerve may be exposed at the infraorbital foramen and secured with a tenaculum.

The outer part of the incision passes above the origins of the zygomatic muscles,

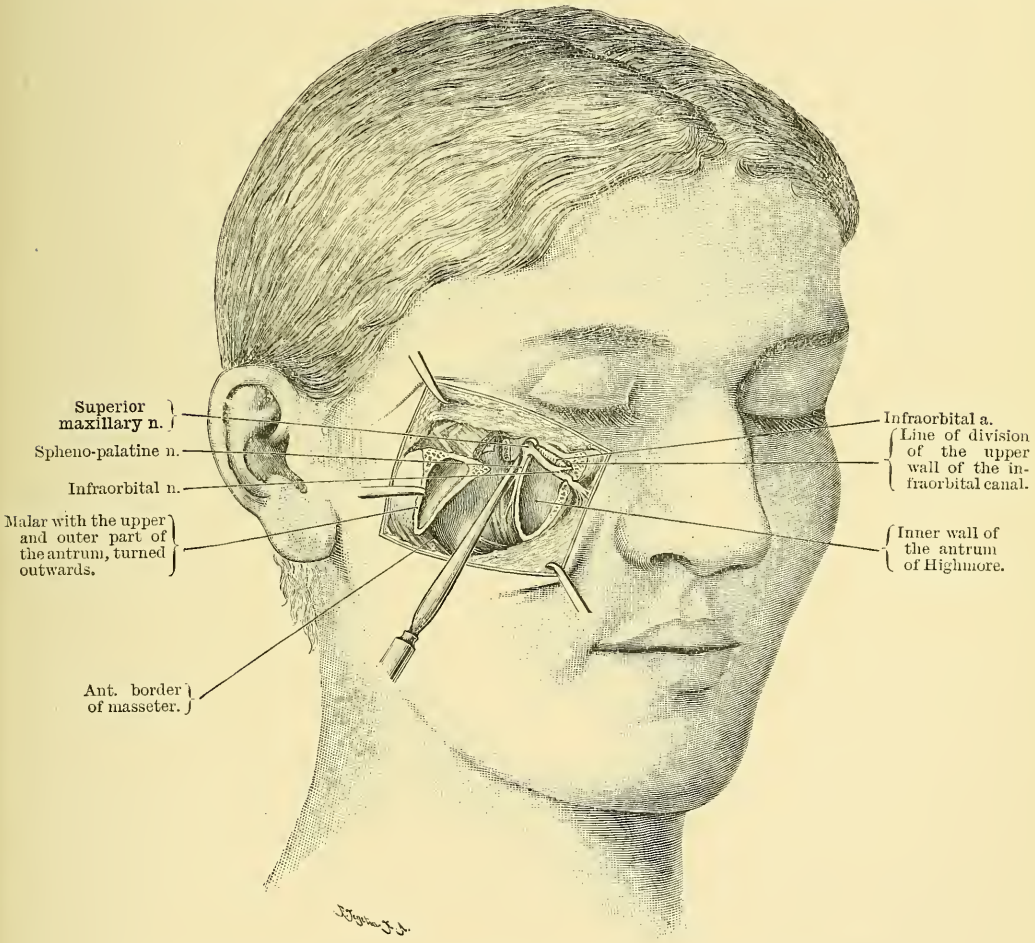

FIG. 105.—Exposure of the second (superior maxillary) division of the trigeminal nerve at the foramen ovale.

which are separated subperiosteally downwards, and the anterior fibres of the masseter are detached from the lower and inner part of the malar bone. The outer and inner surfaces of the malar are laid bare by means of a periosteum detacher (Fig. 104), previous to chiselling it through. The malar process of the upper jaw is bared, upon its anterior surface up to the infraorbital foramen, and upon its upper surface as far back as the spheno-maxillary fissure, and is then detached with the chisel in such a way that the roof of the infraorbital canal is carried with it. Anteriorly, the process is chiselled through from above the infraorbital nerve, downwards and outwards, to just below the anterior end of the origin of the masseter, and then upwards

through the outer wall of the antrum until it meets posteriorly the section through the orbital plate. In this way the outer part of the orbital plate and the superior-external wall of the antrum, together with its hinder angle, remain in connection with the malar bone, and are levered out along with it.

Before this can be done, however, the upper edge of the wound must be drawn upwards to expose the fronto-malar suture (Fig. 104), which is so chiselled through towards the posterior part of the spheno-maxillary fissure that its upper border, along with a portion of the zygomatic crest and of the orbital plate of the sphenoid, is removed along with it. After the zygomatic arch is chiselled through, the malar bone is dislocated upwards and outwards from the large wound with a strong sharp hook, and the orbital fat is carefully raised by a blunt retractor. The infraorbital nerve, which is kept drawn upon, can now readily be followed above the opened-up antral cavity as far as the foramen rotundum. A small hook is now passed behind the descending spheno-palatine nerves around the main trunk which is then caught with fine strong forceps, twisted, and wrenched out (Thiersch). The infraorbital artery, which accompanies the infraorbital nerve, is either avoided or ligatured. According to Potterat, the nerve lies immediately to the inner side of the insertion of the external pterygoid muscle, covered by a ridge of the great wing of the sphenoid which must be cut away with the chisel. The operation is completed by putting the malar bone back into position (fixation sutures being unnecessary) and closing the wound with sutures. The resulting scar is not disfiguring.

We have seen no bad results follow opening of the antrum. It is obvious from the above description that our procedure differs from the Lossen-Braun method, not merely in the more suitable skin incision (to avoid the branches of the facial nerve), but in the fact that the malar, together with the soft parts, is thrown upwards and outwards, thus giving much freer and easier access.

Alexander Fränkel, in resecting the second division of the fifth nerve, discards all external incisions. By an osteoplastic method he throws the anterior wall of the antrum upwards and outwards, and by opening the upper and posterior wall of the antrum, after the manner of Langenbeck's operation for division of the superior dental branches, he exposes the nerve from below, aided by an artificial light.

(2) Exposure of the Zygomatic (Orbital) Nerve. An incision 1 cm. long is carried down to the bone, beginning close to the outer commissure of the eyelids and passing obliquely outwards and somewhat downwards. The periosteum is detached from the outer wall of the orbit, and both branches of the nerve are torn across at their entrance into the foramen at the orbital surface of the malar bone.

(3) The sphenopalatine nerves cannot be divided individually. They are seen in exposing the main trunk of the superior maxillary division at the foramen rotundum (*vide* No. B. 1 and Fig. 106).

(4) The superior dental nerves may be divided alone (v. Langenbeck) by everting the upper lip and making a large incision down to the bone, above the level of the teeth, and then sawing or chiselling through the outer wall of the antrum (and its mucous membrane) from the osseous anterior nares as far back as the pterygoid process.

(5) The Infraorbital Nerve (Fig. 107). The infraorbital nerve is the branch which is most frequently the seat of neuralgia. This nerve may be stretched or avulsed through an incision from the mouth which divides the mucous membrane and periosteum along the line of reflection from the upper lip to the canine fossa. The soft parts, including the periosteum, are separated upwards as far as the infra-orbital foramen, through which the nerve makes its exit half an inch below the middle of the infraorbital margin. The nerve is raised on an aneurysm needle, grasped with artery forceps, twisted, and finally torn out in the manner recommended by Thiersch.

A very good method, but one requiring an external incision, is the following:— An incision, 3 cm. long, is made in the line of our normal incision for the upper jaw beginning at the centre of the infraorbital margin and passing horizontally outwards to the upper extremity of the malar bone. This incision is preferable to the curved

incision Wagner uses, because the branches of the facial nerve to the muscles below are avoided, as well as those to the orbicularis palpebrarum. The incision is then carried down to the bone above the origin of the levator labii superioris. The periosteum is now separated downwards as far as the exit of the nerve from the infraorbital canal, where, after being isolated from the infraorbital artery, an aneurysm needle is passed under it. The periosteum is next separated backwards over the infraorbital margin and along the floor of the orbit until the entrance to the infraorbital canal

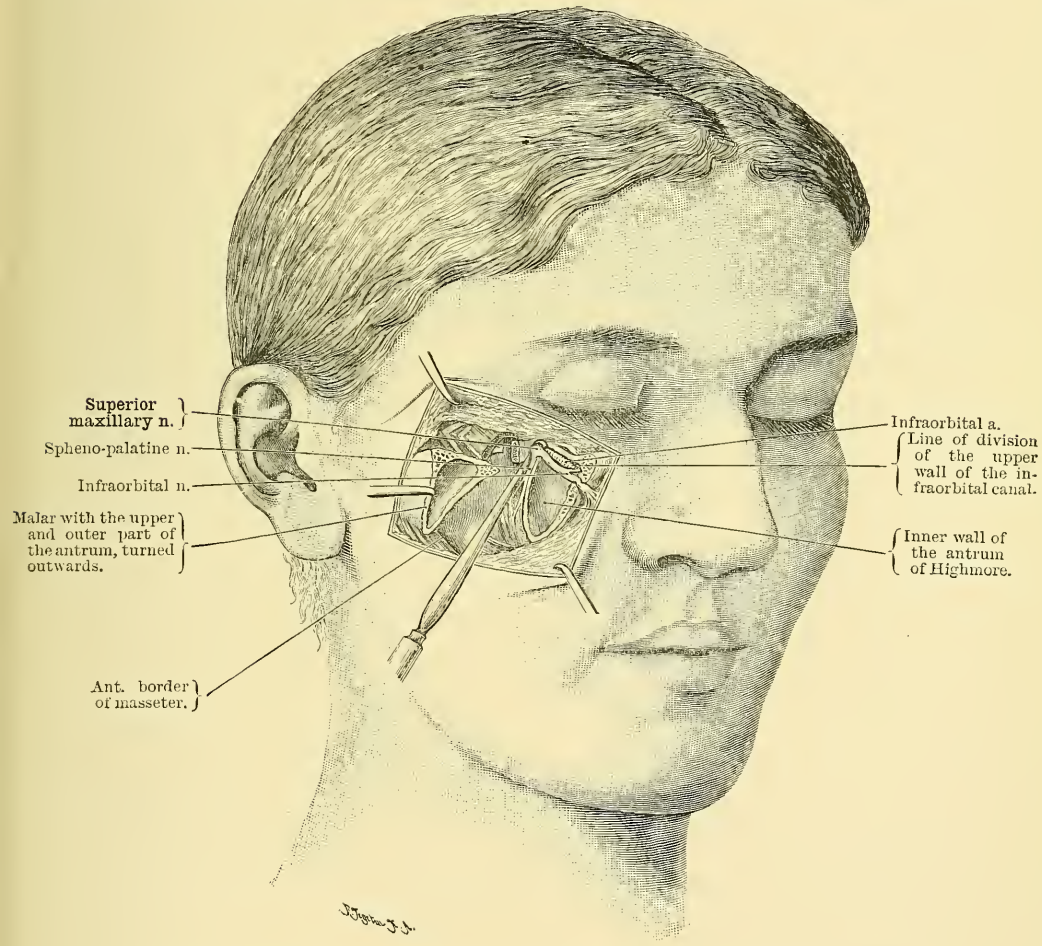

FIG. 106.—Exposure of the second (superior maxillary) division of the trigeminal nerve at the foramen ovale.

is felt or seen (Wagner). The thick anterior part of the roof of the canal is then removed with the hammer and chisel. In this way a considerable extent of the nerve is exposed and can be either stretched or removed. If the antrum has not been opened the wound heals by first intention without leaving any deformity; indeed this is the rule even when the antrum has been opened.

(6) Of the branches of the spheno-palatine ganglion only the palatine nerves can be attacked separately. They may be injected in the neighbourhood of the larger palatine foramen in order to produce anæsthesia in front and to the inner side of the hamular process.

(*c*) *Third* (*Inferior Maxillary*) *Division of the Trigeminal Nerve.* (Fig. 108.) The third division of the trigeminal nerve consists, at the foramen ovale, of motor (posteriorly and externally) and sensory portions so intimately united that they cannot be separated. Central division of the nerve, therefore, has the evil effect of producing a severe concomitant injury which is not intended, namely, unilateral paralysis and atrophy of the muscles of mastication. Happily experience shows (also in our own

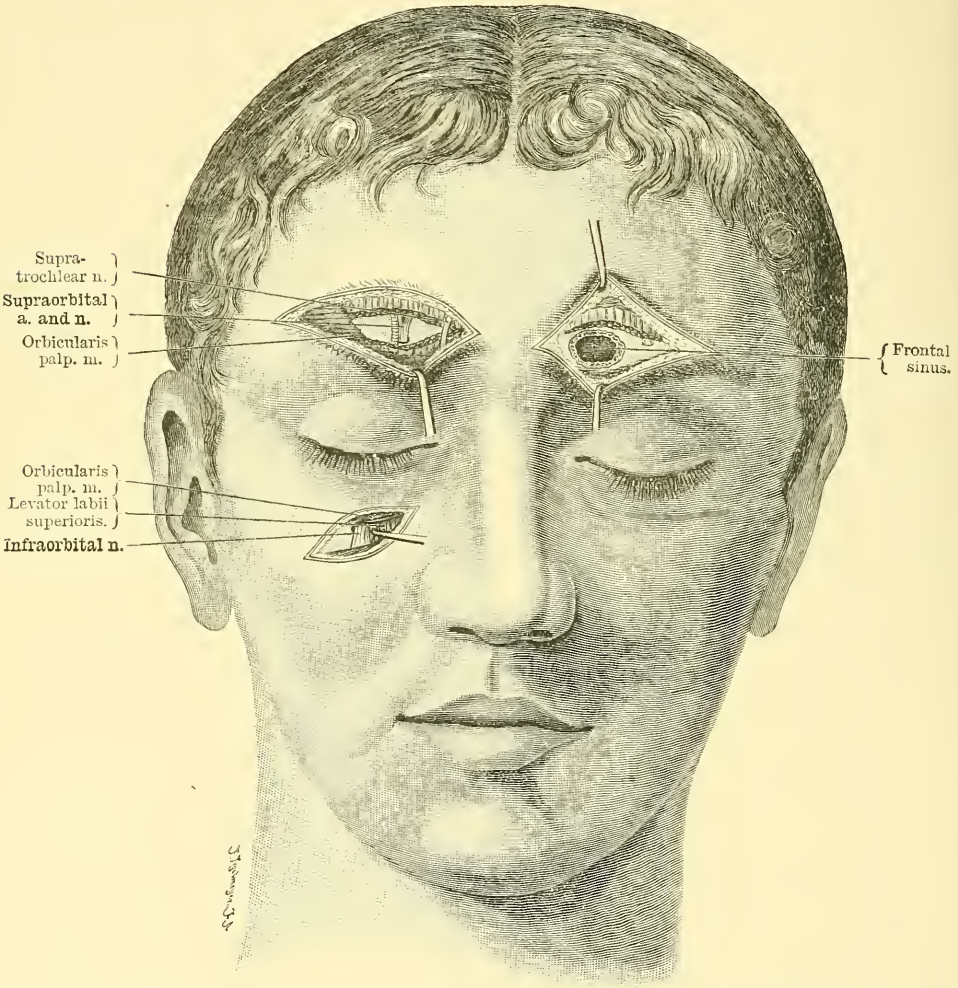

FIG. 107.—Ligature of the supraorbital artery. Exposure of the supraorbital nerve. Infraorbital nerve. Opening of the frontal sinus.

patients) that this unilateral paralysis of the muscles of mastication does not interfere greatly *per se* with the function of the jaw. It merely diminishes the firmness of closure of the jaw and the lateral movement towards the opposite side. These undesirable results of division of the trunk of the nerve at the foramen ovale make it justifiable to attempt a cure by stretching or dividing individual peripheral branches, in spite of the uncertainty of the result.

Operations on the *branches* of the third division of the fifth nerve are so often followed by recurrence of the neuralgia that nothing remains but to expose the trunk

of the nerve at the foramen ovale (Fig. 108). The most certain method of performing this operation is by resecting the zygomatic arch (Lücke, Bruns, Braun, Lossen, Krönlein).

We are firmly of the opinion that here also only those incisions are to be employed which avoid injuring the branches of the facial nerve.

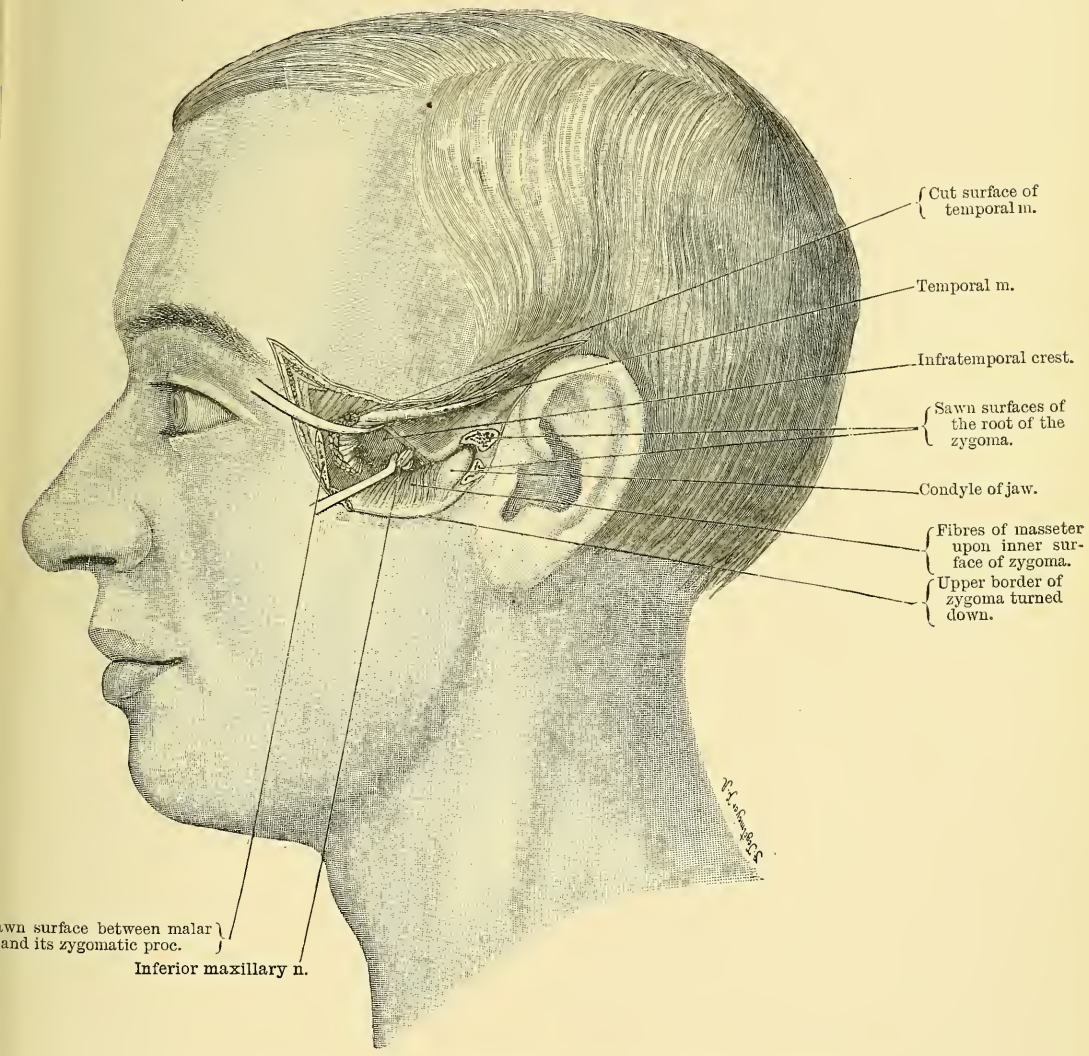

FIG. 108.—Exposure of the third (inferior maxillary) division of the trigeminal nerve at the foramen ovale.

The incision (Fig. 109)[1] begins a finger's-breadth behind the frontal process of the malar, and is carried obliquely downwards and backwards to the posterior extremity of the zygomatic arch, and from thence upwards and backwards in front of the ear at right angles to the first part of the incision. This second part of the incision is carried down to the bone, the superficial temporal vessels being ligatured. The

[1] O. Hildebrand has described as a new method this lower incision with a slight modification, an praises the cosmetic result.

incision divides the skin, and the strong temporal fascia is cut through a finger's-breadth above the zygoma. The malar is now exposed subperiosteally immediately behind its frontal process, and is chiselled through vertically. The zygoma is divided posteriorly close to its root, and the whole zygomatic arch is then carefully drawn down with a hook. The outer surface of the temporal muscle is now exposed covered with fat, and its posterior and lower border is separated from the skull and drawn well forwards with a blunt hook over the infra-temporal crest, at the same time detaching the periosteum and soft parts from the under surface of the skull (sphenoid).

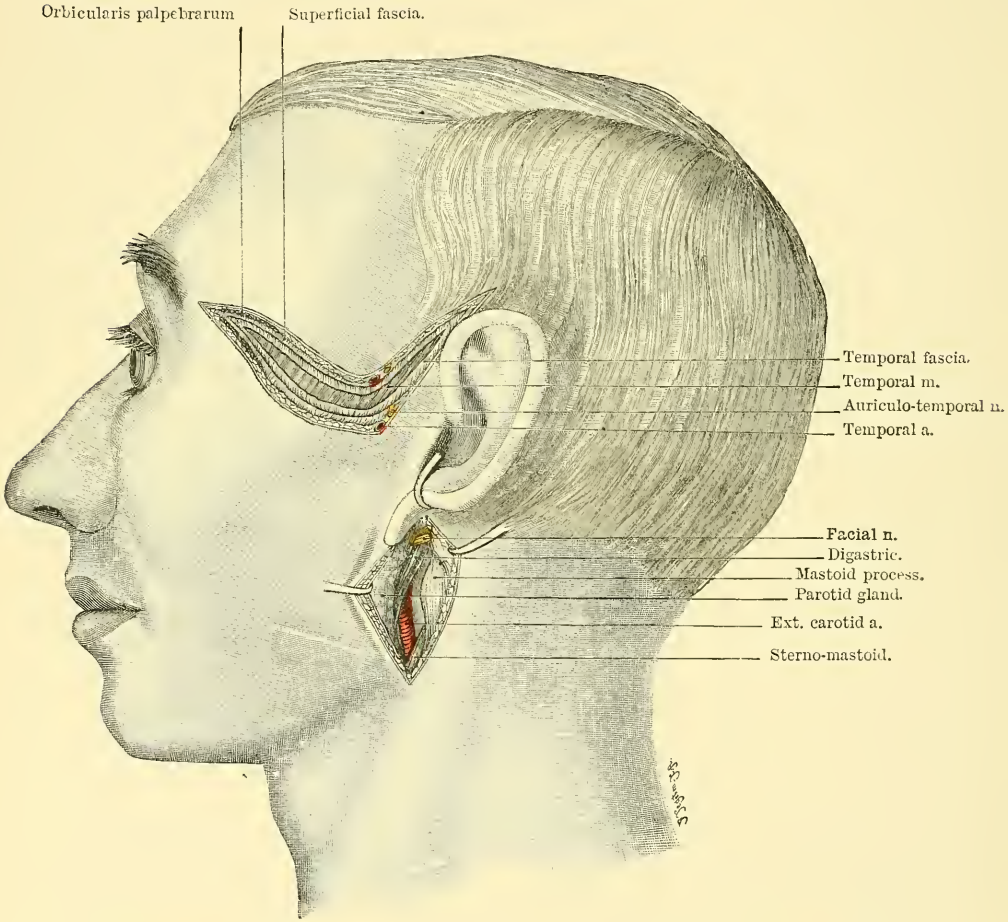

FIG. 109.—Incision for resecting the third (inferior maxillary) division of the trigeminal nerve at the foramen ovale. Exposure of the facial nerve.

This method has the great advantage that all the structures in the retromaxillary fossa can be pushed aside at once, which is not the case if the muscle be detached from below. If the access is not free enough, the insertion of the muscle into the coronoid process may be divided, or the process itself, after being thoroughly isolated, may be nipped off with bone pliers as in Pancoast's and Krönlein's method. There is no special reason for sparing the muscle; but its separation does less injury than its division, and gives a cleaner field for operating.

In this way the entire soft parts along with the periosteum are detached inwards from the under surface of the skull, thus exposing without any further dissection the

outer aspect of the base of the pterygoid process, behind the sharp edge of which the foramen ovale is easily palpable, about 3 cm. deeper than the zygomatic process of the malar. Occasionally there are two openings from which the nerve emerges. The somewhat severe hæmorrhage can be easily arrested by plugging. The larger vessels, branches of the maxillary, lie in the parts which have been drawn downwards, with the exception of the middle meningeal, which lies posteriorly. The trunk of the nerve can now be seized with a strong but small blunt hook and drawn into view: the best plan is to grasp it with a small strong pair of forceps and draw it out entire. If the hæmorrhage has ceased the wound can be closed at once; but if not, or when it is not quite certain that the entire inferior maxillary nerve has been divided (because it is difficult to decide, when the patient is under the anæsthetic), the wound should be stuffed with iodoform gauze, and after one or two days secondary ligatures introduced. The zygoma is replaced and sutured, anteriorly and posteriorly, to fix it in position. The resulting scar is hardly visible.

Lexer has incorrectly described our method as a mere "simplification" of Krönlein's operation, from which it really differs. He does not simplify our method to advantage by merely making an incision over the zygoma, as this necessarily involves injury to the frontal branches of the facial nerve.

It is generally unnecessary to resect the malar either at its orbital plate or at its junction with the upper jaw, except when the second trigeminal branch is to be resected at the foramen rotundum. Krönlein has quite recently (*Arch. f. kl. Chir.* Bd. xlii.) described a *retrobuccal method*; he splits the cheek along with two-thirds of the masseter, and by removing the whole of the coronoid process of the mandible he is able to trace the individual branches up to the base of the skull. If the cheek and the anterior two-thirds of the masseter be divided transversely as far as 1 cm. anterior to the lobule of the ear, one cannot be certain that no branches of the facial are injured. This method has already been employed, in a modified form, by Mikulicz, who saws through the lower jaw. The advantage of Mikulicz's method is that by turning up the entire ascending ramus of the jaw free access is obtained, but the operation is rendered much more serious. Bruns and Sonnenburg go still deeper, down from the angle of the jaw on the nerves.

Simultaneous exposure of the second and third divisions, as already mentioned, cannot safely be performed except by total resection of the zygoma. Even then it is not a convenient operation to perform, and the intracranial route is to be preferred, if one is not content with exposure and avulsion of the main peripheral branches.

(1) Buccinator Nerve. The buccinator nerve is the only sensory twig of the anterior branches of the inferior maxillary nerve, the others are purely motor and call for surgical interference chiefly in cases of unilateral trismus.

It is the sensory nerve for the region of the angle of the mouth. Lying to the inner side of the coronoid process of the lower jaw, on the insertion of the temporal muscle, it is to be secured at the anterior border of the process, whether the operation be performed from without or from within.

The operation from within (Holl) is the simpler. After opening the mouth widely, and feeling for the ridge at the anterior border of the ramus of the jaw, we make an incision down upon it through the mucous membrane and the fibres of the buccinator muscle on the outer surface of which the nerve runs. The nerve will be exposed passing transversely forwards upon the process. Panas was the first to employ this method.

Zuckerkandl's incision for exposing the nerve from the outside which runs horizontally below the malar bone and zygoma immediately above Stenson's duct, involves the serious risk of injuring the ramus maximus of the facial nerve. Preference must be given to Bockenheimer's incision, which is 4 cm. long, and extends from the angle of the mouth to the incisura intertragica, the centre being placed over the anterior border of the masseter. After the pad of fat in the cheek is exposed, the nerve will be found lying on the outer surface of the buccinator muscle. It may be necessary to split the fibres of the muscle and reach the nerve at the inner surface of the coronoid process.

(2) Auriculo-Temporal Nerve. The auriculo-temporal nerve (Fig. 110) is exposed by an incision extending vertically upwards from the root of the zygoma through the skin and fascia. This exposes the temporal artery, behind and under cover of which is the nerve.

(3) Inferior Dental Nerve (Fig. 110). (*a*) By trephining the ascending ramus through an incision along the angle of the jaw. Velpeau and Linhardt advocate a

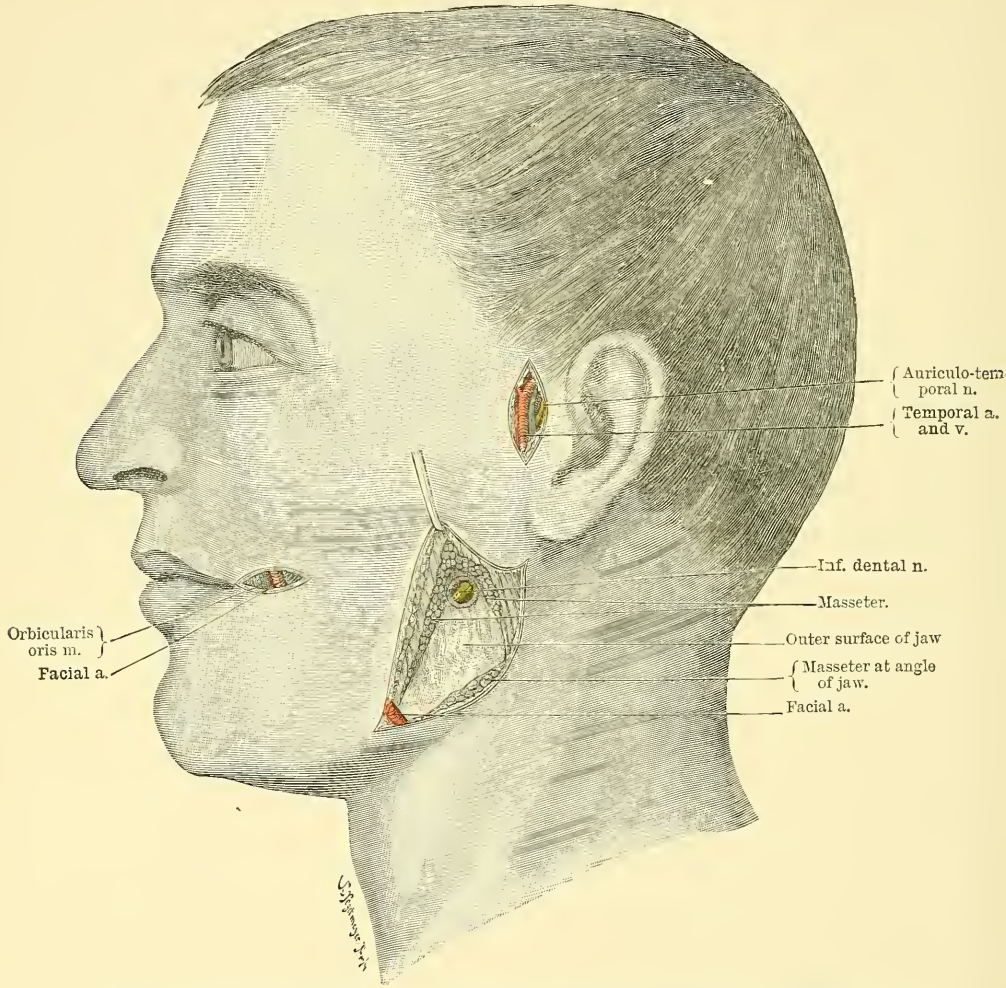

FIG. 110.—Ligature of the facial artery. Ligature of the temporal artery. Trephining the ascending ramus of the jaw to expose the inferior dental nerve.

method, which is preferable to that of Kühn and Bruns, in which the angle of the jaw is chiselled through. The incision in "the middle line of the ascending ramus," however, is not such a good one as that described by us. It is just in this position that the branches of the facial nerve supplying the muscles of the chin and lower lip ramify. After making a curved incision along the angle of the jaw, the dissection must be continued cautiously, and care must be taken to draw downwards the supra-maxillary branch of the facial nerve (compare the posterior part of the normal incision for the anterior triangle). The tendinous fibres of the masseter are separated

upwards from the jaw with the knife and periosteum elevator, the muscle is retracted upwards as far as the upper edge of the wound, and a piece of bone is chiselled out from exactly the centre of the ascending ramus (Velpeau and Linhardt). In this way the nerve is exposed as it enters the inferior dental canal. This method is a very precise one, and is sure to strike the nerve. It is less severe than Bruns' method of chiselling out a piece of bone from the posterior border of the ramus; and it is easier than the Sonnenburg-Lücke operation, which consists in detaching the periosteum along with the internal pterygoid muscle from the inner surface of the ramus as far as the lingula. If primary healing occurs there is no interference with the function of the jaw.

(*b*) Paravicini's method. The mouth having been widely opened by means of a White's gag, the sharp inner edge of the anterior border of the ascending ramus is felt for, and an incision made along it through mucous membrane and periosteum down to the bone. The inner edge of the wound is now separated subperiosteally from the inner surface of the ramus by a blunt instrument until the spine is felt at the inner edge of the opening into the inferior dental canal. The nerve is found with certainty behind the spine. The operation is exceedingly simple, and does much less injury than operations from the outside, but has the disadvantage of producing a wound in the mouth from which infection may proceed. Moreover, the slower healing of an infected wound, combined with the fact that the internal lateral ligament is attached to the spine, entails a longer hindrance to the opening of the mouth.

(4) Mental Branch of the Inferior Dental Nerve. The terminal portion of the above nerve, namely, the mental nerve, is exposed by drawing the lower lip well down from the jaw and dividing vertically the mucous membrane at its line of reflection opposite the interval between the first and second bicuspid teeth: the periosteum is then divided, when the nerve will be found emerging from the mental foramen. Generally, however, the seat of neuralgia is more proximal—in connection with the teeth—so that the nerve must be exposed before it enters the inferior dental canal.

(5) The Mylohyoid Branch. This twig may be exposed from below where it lies between the lower jaw and the insertion of the mylohyoid muscle on the inferior surface of the latter.

(6) The Lingual Nerve. The lingual nerve may also be exposed by Paravicini's intrabuccal method (cf. No. 3*b*). The following method, however, is simpler, because the nerve as it passes forwards between the anterior pillar of the fauces and the root of the tongue lies very superficially, indeed just under the mucous membrane. All that is required to expose the nerve is to make a small longitudinal incision through the mucous membrane, but not too near the tongue. The transverse splitting of the cheek by Roser's method is not a necessary preliminary. The disadvantage of the operation is that the wound is inside the mouth.

To avoid this drawback we have sought to expose the nerve from the outside and from below, namely, where it passes above the submaxillary gland. The incision is a part of our normal incision for the superior triangle of the neck. It exposes the lower border of the submaxillary gland, which is turned upwards, and the nerve is then secured where it is connected through the submaxillary ganglion with the submaxillary gland immediately in front of the internal pterygoid muscle. The operation is considerably more difficult than that previously mentioned, but it possesses the advantage that primary healing is obtained with certainty.

Lastly, the nerve may also be secured by trephining the ramus of the lower jaw in the same way as for the inferior dental nerve, or from below (Sonnenburg-Lücke).

Division and avulsion of the nerve may be indicated in lingual neuralgia, especially in connection with cancer of the tongue.

So far as we are aware, there are no special operations connected with the abducens, although the question of nerve-grafting might be considered.

15. Facial Nerve (Figs. 109 and 111). The facial nerve is liable to be injured in any operative interference behind the angle of the jaw (removal of glandular and other tumours) as well as in operations on the parotid (excision of parotid tumours,

and in incision of a phlegmonous parotitis). The nerve is deeply placed and is partly covered by the parotid. In the case of simple tumours it can generally be preserved, but in malignant tumours the nerve has frequently to be sacrificed.

In nerve-grafting, we now possess a means of repairing a nerve injury, and it is especially in connection with the facial nerve that this operation has been most successful.

The results are infinitely better than after the facial nerve is stretched in cases of facial spasm, although the latter operation proves in many cases successful.

We have frequently stretched the facial nerve and would always try its effect before resorting, like Kennedy, to division and nerve anatomosis. We therefore reproduce our description of the operation to expose the facial nerve.

Operation: In partial agreement with Heuter, Löbker, and Kaufmann, we make an incision behind the angle of the jaw along the anterior border of the sterno-mastoid as far as its attachment to the mastoid process: the attachment of the lobule of the ear is then divided by extending the incision upwards in front of the tragus. The tissues to be divided are somewhat dense, consisting of processes of the parotideo-masseteric fascia passing to the cartilage of the ear.

The knife is used cautiously until the lobules of the parotid gland come into view. A blunt hook is inserted, and the lobules are detached forwards with a tissue dissector. The small bleeding vessels must be secured with forceps, otherwise the view is obscured. The tendinous anterior border of the sterno-mastoid is recognised in the floor of the wound, the anterior border of the mastoid process is felt for, and then each strand which passes forwards is irritated mechanically to see if the facial muscles contract. The nerve runs from behind forwards over the posterior border of the digastric, and slightly downwards under the parotid as a fine cord 2 cm. in thickness. It lies at a distance of 2·5 cm. (1 in.) from the surface, fully 1 cm. deeper than the anterior border of the sterno-mastoid and the mastoid process, about midway between the angle of the jaw and the zygoma. (In Fig. 109 it is drawn rather too high.) The posterior auricular artery lies posterior to the wound, while the external carotid lies under the digastric muscle.

In exposing the nerve for the purpose of stretching it in facial spasm a general anæsthetic must not be employed, because the stretching must be so measured that it produces a distinct, but not a total paresis, which can readily be brought about by slight traction with an aneurysm needle. Even if at first some spasm continues this soon completely disappears. An old lady operated on by us in this way recovered completely within fourteen days after having complained of the spasm for six years. The paresis gradually disappears.

Important contributions to the subject of nerve-grafting or nerve-anastomosis have been made by Harvey Cushing,[1] Frazier and Spiller,[2] and Destelle,[3] while Manasse and Barrago have studied it from the experimental point of view.

Up to 1905 the facial nerve had been grafted on twenty-two occasions (Destelle), the anastomosis being made with the posterior branch of the spinal accessory fifteen times, and seven times with the hypoglossal. Although very different opinions are held regarding His's view that every nerve is an outgrowth of a nerve-cell, and that regeneration only takes place by a downgrowth of fibres from the central into the peripheral end, and also regarding the views held by Bethe and Nissl, Ballance and Stewart and other investigators, that regeneration can take place in the peripheral portion of the nerve, the fact remains that nerve impulses can be re-established by anastomosing two different divided nerves. According to Cushing, the credit of having demonstrated experimentally the truth of this nerve-crossing is due to Langley.

Cushing maintains that one must assume from Harrison's researches that there is in the central end of a divided nerve an inherent tendency to re-establish its peripheral connection by some sort of chemiotactic influence, so long as all mechanical obstruction has been removed, irrespective of whether the peripheral portion con-

[1] *Annals of Surgery*, 1903; *vide* also *Cleveland Med. Journ.*, Jan. 1905.
[2] *Univ. of Pennsylvania, Med. Bull.*, 1903.
[3] *Thèse de Bordeaux*, 1905; *vide* also Bréaroisse, *Thèse de Paris*, 1901.

tributes to the process by autoregeneration or not. We have therefore to aid this natural tendency by the removal of all obstructions. We know that when the edges of a wound are accurately sutured, divided nerves heal of their own accord, and also that it is difficult in the case of sensory nerves to prevent regeneration occurring, if there is no obstacle to the subsequent outgrowth in the case of sensory nerves, *e.g.* the trigeminal.

Union of the distal end of the nerve (or as in Lynn Thomas's case, of the main branches) with the spinal accessory or hypoglossal nerve, has been introduced as a method for the relief of facial paralysis. Ballance and Stewart first performed the operation on man in 1895. The effects of the anastomosis are that the nerve-ends unite and there is re-establishment of muscular tone and voluntary muscle power even if the paralysis has existed for a long time, provided the muscles are not quite

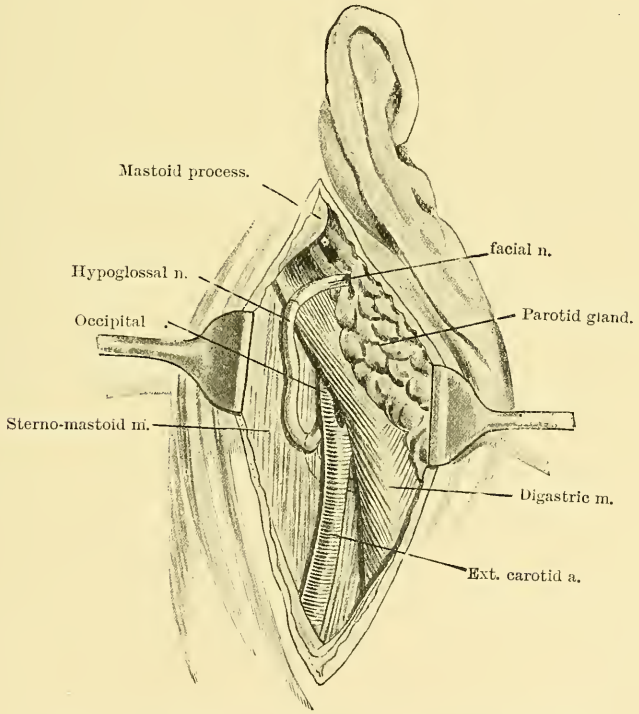

FIG. 111.—Facio-hypoglossal anastomosis. Frazier's operation.

atrophied. In facio-accessory anastomosis an active and independent innervation of the muscles of the face is obtained, but the face twitches with every voluntary movement of the shoulder.

Ballance, Körte, and Frazier therefore prefer to utilise the hypoglossal, because, firstly, the nerve-centres are closer to one another, and secondly, because it is easier to improve the effect by educative methods.

As regards the method of anastomosis to be employed, it has been proved that end-to-end, and end-to-side union afford equally satisfactory results. The former appears to be more certain, and is applicable to extreme cases where everything depends on conduction through the new union; end-to-side union, on the other hand, is reserved for those cases where, in the case of failure, one is unwilling to risk paralysis of the healthy nerve used for grafting.

Technique: An incision, 10 cm. long (*i.e.* longer than that required for simple exposure of the facial nerve), is made along the anterior border of the sterno-mastoid

extending up on to the mastoid process. The posterior border of the parotid is exposed and displaced forwards. According to Frazier, the nerve enters the gland by passing forwards on the outer surface of the styloid process and the digastric muscle 1 cm. above and the same distance internal to the tip of the mastoid process. When the lesion is situated higher up, as is the case in diseases of the middle ear, and in chills in which degenerative neuritis has been proved to exist right up to the geniculate ganglion (Spiller), the nerve must be followed to the styloid foramen and divided as close to it as possible.

The hypoglossal nerve is then isolated at the point where it hooks round the commencement of the external carotid artery. If the spinal accessory nerve is selected, it must be followed from the front of the transverse process of the atlas (which is always easily felt) to the under surface of the sterno-mastoid. By drawing the muscle outwards the nerve can be rendered distinctly visible.

The distal end of the facial nerve is now either implanted in a lateral slit in the hypoglossal or the spinal accessory nerve, or the latter nerve is cut across and its central end united to the peripheral end of the facial nerve, with fine sutures including as far as possible only the nerve-sheaths. By division of the nerve obliquely, a broader surface of contact is obtained. Fine catgut should always be used, so that as little cicatricial tissue as possible may be produced from the long-continued presence of a foreign body.

16. Acoustic Nerve. Tumours not infrequently occur in connection with the eighth cranial nerve and give rise to serious pressure symptoms although they are generally small and easily removed. The question is merely one of correct diagnosis.

The dissection to expose the auditory nerve at the base of the skull is an extensive and severe undertaking, and is the same as that for exposure of the cerebello-pontine angle.

In describing the surgery of the cerebellum, we gave an illustration from Frazier's work (Fig. 90) which shows how the posterior aspect of the petrous temporal with the entering auditory nerve can be exposed by trephining the occipital bone and depressing the cerebellum downwards and inwards.

The glosso-pharyngeal nerve has not yet been made the object of surgical interference.

17. Vagus Nerve. The surgery of the tenth cranial nerve is important firstly on account of its laryngeal branches and secondly on account of its cardiac and pulmonary branches.

In the removal of malignant tumours in the neck, it is not uncommon to be under the necessity of resecting the vagus on one side. As this, however, produces paralysis of the recurrent laryngeal it is desirable that the nerve-ends should be united. This may require a plastic operation, *e.g.* lengthening the nerve, and if the gap between the ends is extensive an anastomosis may be found necessary, *e.g.* with the spinal accessory, provided the latter is available.

(*a*) *Superior Laryngeal Nerve.* This branch of the vagus, which is essentially the sensory nerve for the larynx, is exposed by drawing downward the lower edge of the hyoid portion of our normal incision. At the point of origin of the facial artery it passes deeply behind the external carotid, then forwards parallel to the great cornu of the hyoid bone across the middle constrictor of the pharynx, and upon the outer surface of the thyro-hyoid membrane, and disappears under the posterior border of the thyro-hyoid muscle. It is of very great importance to bear in mind the course of this nerve, as its injury causes insensibility of the larynx, in consequence of which, in operations upon the larynx and the mouth, the patient is specially liable to die of septic pneumonia (*Schluck pneumonie*).

If the nerve is divided, implantation of its peripheral end into the vagus or a cutaneous sensory nerve is to be considered.

The author has stretched the nerve with permanent benefit in a case of acute neuralgia limited to the superior laryngeal nerve.

(*b*) *Inferior Laryngeal Nerve.* Paralysis of the inferior laryngeal nerve is a common complication in goitre, and occurs still more frequently after excision of the

thyroid, specially if the operation has been performed by a surgeon who has no great experience of this branch of surgery. Fortunately the hoarseness which results from unilateral paralysis of the laryngeal muscles is generally only temporary, since the other vocal cord comes in contact with the paralysed cord across the middle line in phonation.

Still in some cases the hoarseness may prove persistent, when the question has to be considered of implanting the peripheral end into the trunk of the vagus or of uniting it to the central part of the spinal accessory after the latter has been divided.

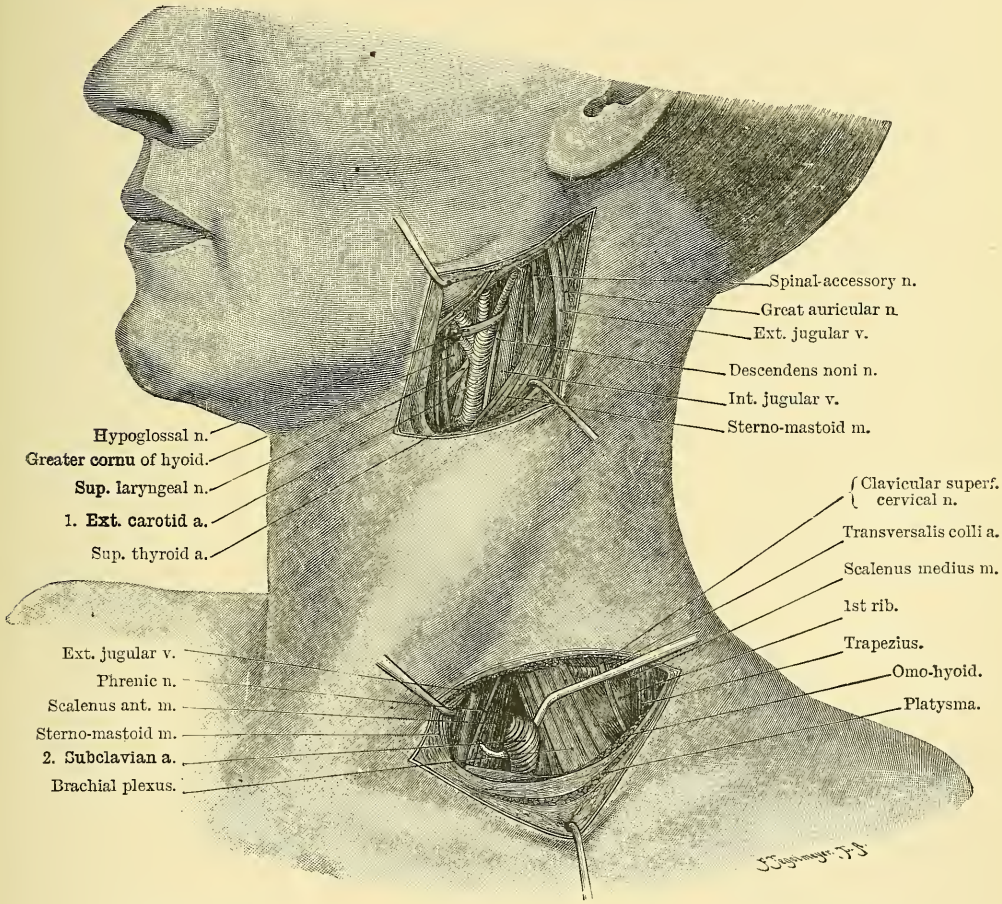

FIG. 112.—Ligature of the external carotid with the origins of the lingual, facial, and occipital arteries. Ligature of the subclavian artery.

18. Spinal Accessory Nerve (Figs. 112, 113). The eleventh cranial nerve supplies through its posterior branch the sterno-mastoid and trapezius. It is very liable to be injured in the removal of tumours in the neck, and is intentionally exposed and divided in facio-accessory anastomosis, since its division, beyond causing drooping of the shoulder and atrophy of the trapezius, results in no serious loss of function. Even after section of the spinal accessory the head can be rotated and the arm can be raised to the horizontal position.

The spinal-accessory nerve (Fig. 112) passes downwards and backwards in front of the internal jugular vein, beneath the upper third of the sterno-cleido-mastoid muscle.

It gives branches to the sterno-cleido-mastoid and trapezius muscles. In spasmodic conditions which are limited to these two muscles, the stretching or tearing out of the nerve gives good results. The nerve is to be avoided, however, in operations in the neighbourhood of the upper end of the sterno-mastoid, especially in excising the lymphatic glands in this region. To expose the nerve we employ the mastoid portion of our normal incision, viz. from the apex of the mastoid process to below the angle of the jaw. The external jugular vein and the great auricular nerve having been freed, the sterno-mastoid muscle is drawn forcibly backwards. The spinal-accessory nerve

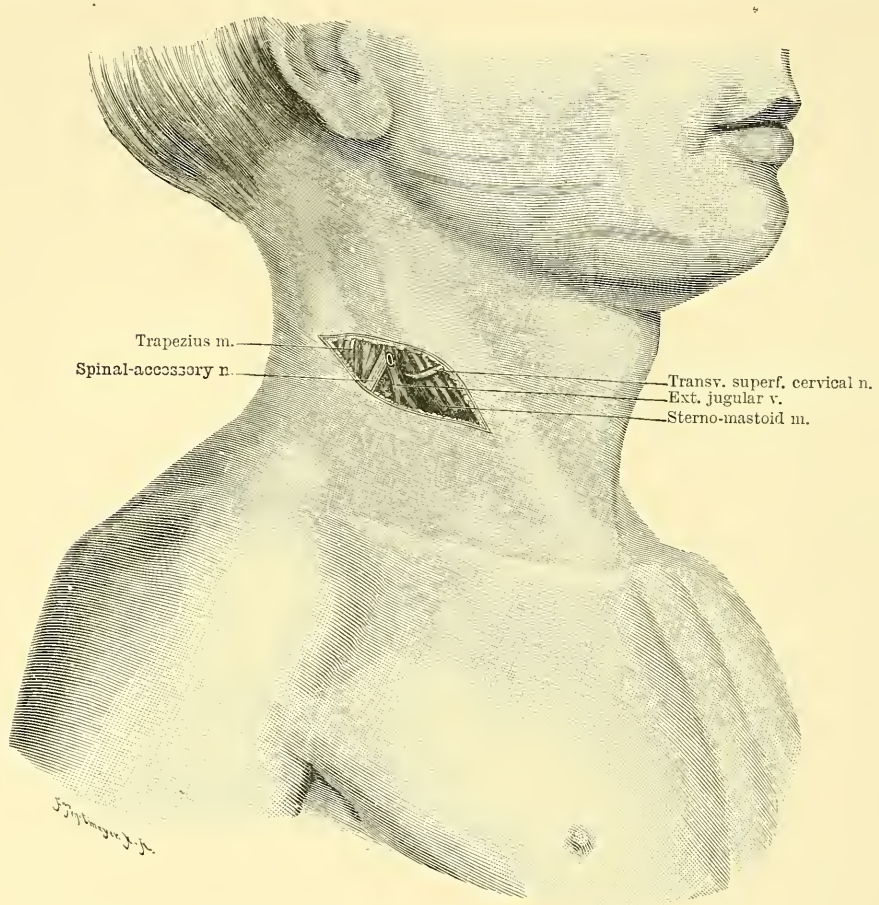

FIG. 113.—Exposure of the spinal-accessory nerve in the middle of the neck.

has a definite course downwards and backwards under the sterno-mastoid in front of the prominent transverse process of the atlas. It lies close to the under surface of the muscle. The occipital artery passes backwards over the nerve. The lowest branch of the facial nerve to the muscles of the chin may come into view at the upper edge of the wound, and is to be avoided. Higher up, the nerve is covered by the posterior belly of the digastric muscle. Anteriorly it is accompanied by the artery to the sterno-cleido-mastoid muscle from the external carotid.

It is easier to expose the nerve lower down, *i.e.* at the posterior border of the sterno-mastoid. Fig. 113 shows the transverse incision made through skin and platysma, rather below the middle of the sterno-mastoid. The external jugular vein,

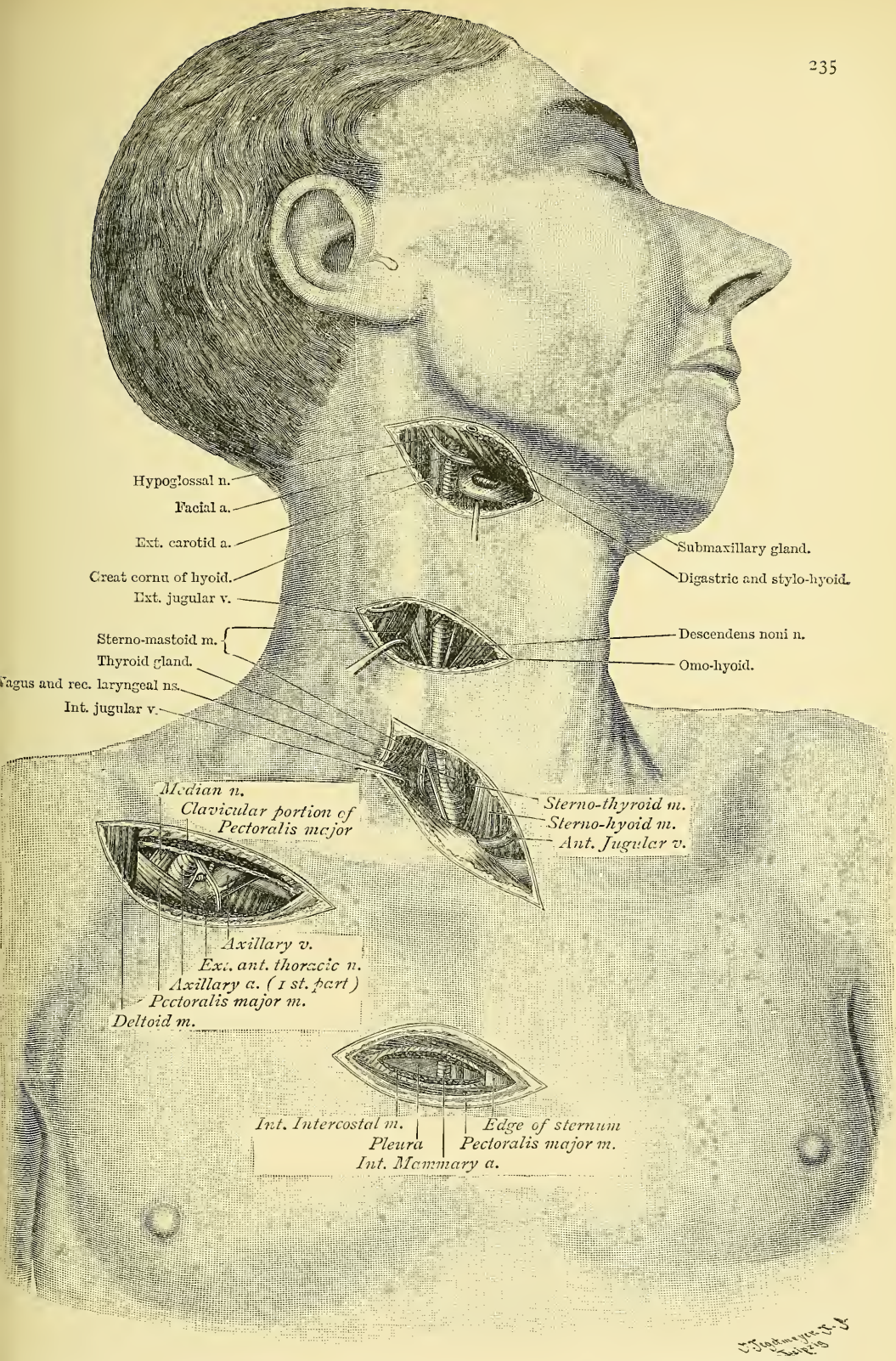

FIG. 114.—Ligature of the lingual artery above the greater cornu of the hyoid. Ligature of the common carotid at the level of the cricoid cartilage. Ligature of the innominate artery. Ligature of the first part of the axillary artery. Ligature of the internal mammary artery.

which descends across it, is drawn forward and the superficial cervical nerve, which crosses the sterno-mastoid muscle, is not interfered with. After division of the fascia, the nerve is seen passing obliquely backwards from the posterior border of the sterno-mastoid to beneath the anterior border of the trapezius.

19. Hypoglossal Nerve (Fig. 114). As already mentioned, the hypoglossal nerve has recently been preferred for nerve-anastomosis in facial palsy.

It is looked for at the outer side of the commencement of the external carotid artery (round which it hooks), from which point it should be followed up and dissected out, if there is danger of its being injured during the removal of a tumour.

The incision to expose it corresponds to the middle third of our normal incision for the superior triangle of the neck, and is the same as that made for ligature of the external carotid (Fig. 114). After we have divided the skin, platysma, and fascia, the anterior border of the sterno-mastoid is freed and retracted backwards, care being taken to avoid the external jugular vein and the great auricular nerve. The common facial vein is drawn backwards and the external carotid exposed. The hypoglossal nerve will be found hooking round the outer side of the artery from behind, before the latter gives off its branches (the superior thyroid artery alone is below the nerve), and then passes underneath the digastric and stylohyoid to reach the anterior surface of the hyoglossus muscle.

H. SPINAL NERVES

(a) The Upper Four Cervical Nerves (Fig. 115)

The upper four cervical nerves may have to be divided in spasmodic contractions of the cervical muscles, particularly spasmodic wry neck, and also in occipital neuralgia. We have described (see p. 443) the method we employ for the treatment of spasmodic torticollis, viz. myotomy, which serves the same purpose as division of the nerve without leaving the muscles of the neck permanently paralysed.

Radical cure in severe cases of muscular spasm or obstinate neuralgia which cannot be localised to the area of one individual nerve, can only be obtained by dividing the nerves where they emerge from the spinal canal. Krause recommends the following operation :—

An incision, beginning below the external occipital protuberance, is carried transversely outwards to the insertion of the sterno-mastoid, from which point it descends along the posterior border of the muscle to the level of a line drawn horizontally through the hyoid bone. In the upper portion of the incision the trapezius, splenius, and complexus are divided at their attachment to the skull, the bleeding at this stage being very considerable. The great and third occipital nerves are also cut across.

This musculo-cutaneous flap is retracted and the deep muscles of the suboccipital triangle are exposed, viz. the rectus capitis anticus major, and obliquus capitis superior and inferior muscles, with the trachelo-mastoid at the outer limit of the wound running obliquely forwards and upwards.

The first cervical (suboccipital) nerve will be found in the suboccipital triangle between the occiput and the atlas lying behind the vertebral artery which runs transversely inwards to the foramen magnum. It is essentially a motor nerve, and has to be divided mainly for spasmodic conditions. According to Krause, its ganglion lies outside the spinal canal.

The great occipital (the posterior primary division of the second cervical nerve) lies below the inferior oblique muscle and furnishes the sensory supply to the whole of the back of the scalp. It is easily recognised by the course it pursues over the posterior surface of the inferior oblique muscle. According to Krause, the ganglion of this nerve also lies extra-vertebral, *i.e.* after the nerve has passed out between the atlas and the axis.

The third cervical nerve runs backwards between the axis and the third cervical vertebra vertically below the second nerve. Internally it gives off the third occipital nerve as its main cutaneous branch, and gives off the small occipital upwards and externally.

The sensory branches of the fourth cervical nerve run downwards and play no part in occipital neuralgia. In spasmodic conditions of the neck the nerve exerts only an indirect action on the cervical vertebra through the longus colli and scalene muscles.

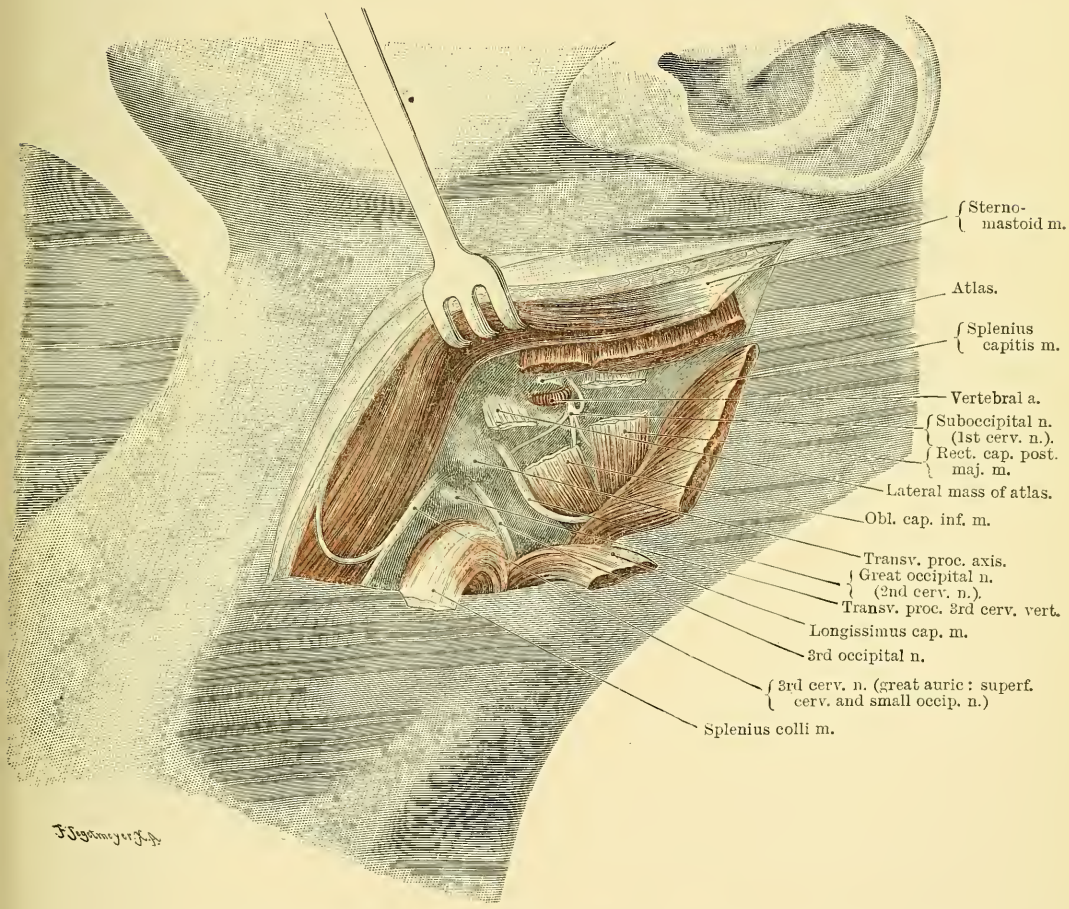

FIG. 115.—Exposure of the upper three cervical nerves through an incision along the posterior border of the sterno-mastoid. The transverse processes of the cervical vertebræ are seen, with the attachments of the muscles.

We regard Krause's operation as difficult and severe. Further, in occipital neuralgia, it is uncommon for all three upper cervical nerves to be involved. The posterior as well as the anterior portion of the suboccipital is purely motor. As a rule, therefore, only the second and third cervical nerves need be exposed. The posterior primary division of the second nerve is the great occipital, and its anterior division takes part in forming the small occipital. The posterior primary division of the third nerve is the third occipital, while the anterior division helps to form the small occipital as well as the great auricular and superficial cervical nerves.

The second and third cervical nerves are exposed as follows:—Incision through

skin and fascia from the mastoid process along the posterior border of the sterno-mastoid muscle from under which various small cutaneous branches emerge. The sterno-mastoid is retracted forwards and the fibres of the splenius capitis and colli which pass obliquely upwards and forwards, are cut across along with the trachelo-mastoid. The strong complexus muscle is drawn backwards and it and the levator anguli scapulæ remain posterior.

By following the nerve-branches already mentioned the trunk of the third cervical nerve is now observed emerging from beneath the projecting transverse process of the axis, and sending its anterior branch downwards over the scalenus medius, and the posterior (small occipital) backwards.

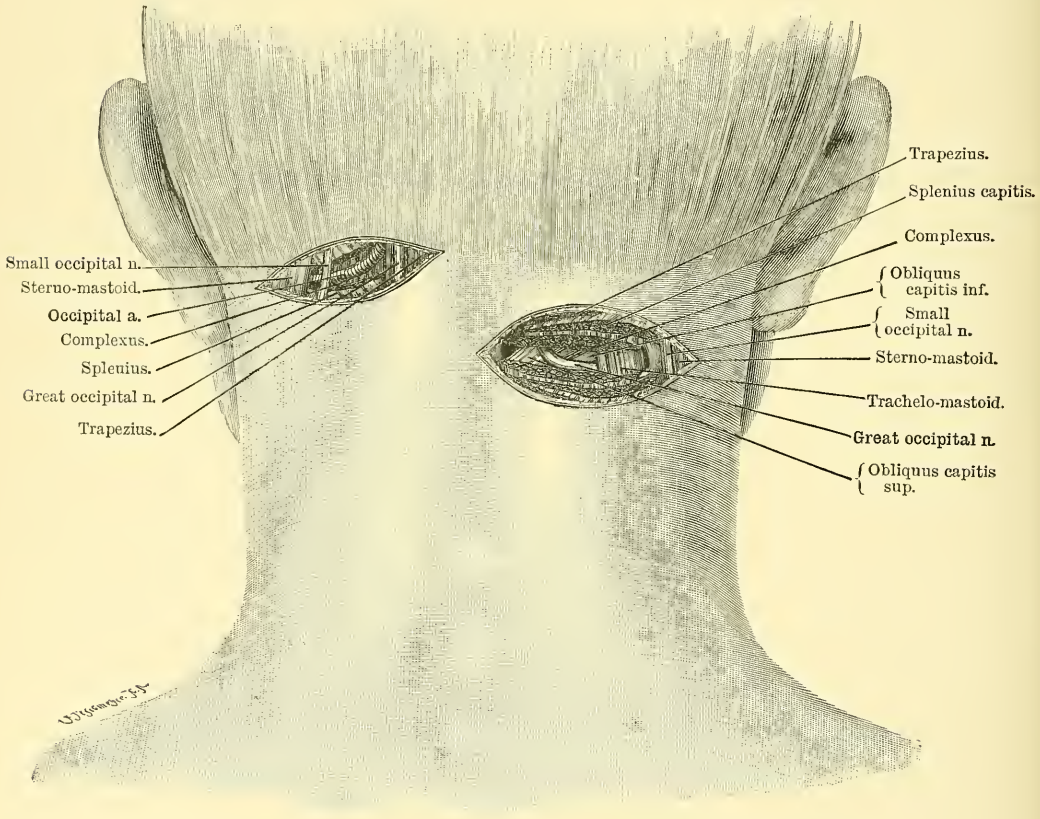

FIG. 116.—Ligature of the occipital artery and exposure of the small occipital nerve. Great occipital nerve.

After dividing the attachments of the levator anguli scapulæ to the transverse processes (and drawing the muscle forwards) we see the short strong belly of the obliquus capitis inferior, round the outer border of which the great occipital nerve hooks. Following up the nerve we find its exit above and behind the transverse process of the axis. The muscle may have to be divided.

If the obliquus capitis superior is also divided, the exit of the first cervical nerve (or suboccipital, the posterior primary division) may be exposed between the arch of the atlas, which can be plainly felt, and the occiput. This, however, is very rarely necessary.

20. **Great Occipital Nerve** (Figs. 115 and 116). Being the sensory nerve to the

back of the neck and head the great occipital is frequently the seat of neuralgia, for which treatment by isolation and avulsion is justified.

The great occipital nerve (posterior division of second cervical) becomes superficial at the outer border of the trapezius after piercing the complexus muscle. The nerve is found internal to the occipital artery, both structures converging towards one another.

If, for neuralgia, one wishes to find and stretch the nerve *nearer its origin*, the incision must be made deeper (Fig. 116). A transverse incision is carried outwards from the middle line opposite the projecting bifid spine of the axis. At the outer angle of the incision the posterior edge of the sterno-mastoid muscle and the small occipital nerve appear. The comparatively thin trapezius is divided, as also are the fibres of the strong splenius capitis, which ascend obliquely upwards and outwards underneath it; and, lastly, the vertical fibres of the powerful complexus muscle having been divided, the deeply placed fibres of the superior and inferior oblique muscles are exposed. The large nerve curves round the lower border of the latter muscle and passes upwards and inwards across its surface. Here the nerve gives off motor branches to the muscles at the nape of the neck, and is thereafter purely sensory. The trachelo-mastoid muscle extending obliquely downwards at the outer border of the complexus can be spared.

The operation described in the previous section (H, *a*) for exposure of the three upper cervical nerves is, however, preferable.

21. Small Occipital Nerve (Great Auricular, Superficial Cervical Nerves) (Fig. 113). These nerves appear close together from under the posterior border of the sterno-mastoid and radiate upwards and forwards on the side of the neck. They are easily exposed by dividing the skin, platysma and fascia along the middle third of the posterior border of the sterno-mastoid, and defining the border of the muscle. It is here that they are injected in producing "conduction" anæsthesia, and may also be stretched one after the other, as they are purely sensory nerves supplying the whole of the side of the neck.

By drawing forwards the sterno-mastoid and the large underlying vessels, and dissecting deeply at the anterior border of the splenius, trachelo-mastoid, and levator anguli scapulæ, we reach the exit of the third cervical nerve below the attachment of the scalenus medius to the transverse process of the axis. This nerve really belongs to the three branches named, and may thus, along with the third occipital, be made accessible for operation (*vide* description in H, *a*).

The small occipital nerve can also be exposed along with the occipital artery on the occiput as shown in Fig. 116.

22. The Fourth Cervical Nerve (Supraclavicular Nerves and Phrenic Nerve). The fourth cervical nerve (like the third) may call for surgical interference, as it is not infrequently the seat of neuralgia in malignant tumours of the neck, *e.g.* in malignant goitre. Along with the third it contributes largely to the formation of the phrenic nerve, and care must therefore be taken to guard against injury.

The fourth cervical nerve is of chief interest in that it provides an excellent guide to the phrenic nerve, which must be exposed and avoided in operations on the neck.

Fortunately the phrenic pursues a very definite course which makes it possible to isolate it and to deal only with the main sensory branches of the fourth cervical nerve. It runs vertically downwards on the anterior surface of the scalenus anticus (which can easily be felt), and enters the thorax by crossing the insertion of the muscle into the first rib.

The phrenic nerve can be readily exposed, and may be stimulated in cases of arrested respiration with a faradic current. In collapse during long severe operations we have been able to maintain strong enough respiration for twenty minutes by alternate faradic stimulation with a strong current of first one phrenic then the other, till natural breathing was restored, at the same time raising the blood-pressure by saline injections.

(b) The Lower Four Cervical Nerves (Brachial Plexus)

The brachial plexus, which is formed by the lower four cervical nerves (five to eight) and the large first dorsal nerve with twigs from the fourth cervical and second dorsal nerve, occupies a characteristic position and can be readily exposed by an incision in the supraclavicular fossa. The dissection to expose it is the same as that for ligature of the subclavian artery above the clavicle (Fig. 117).

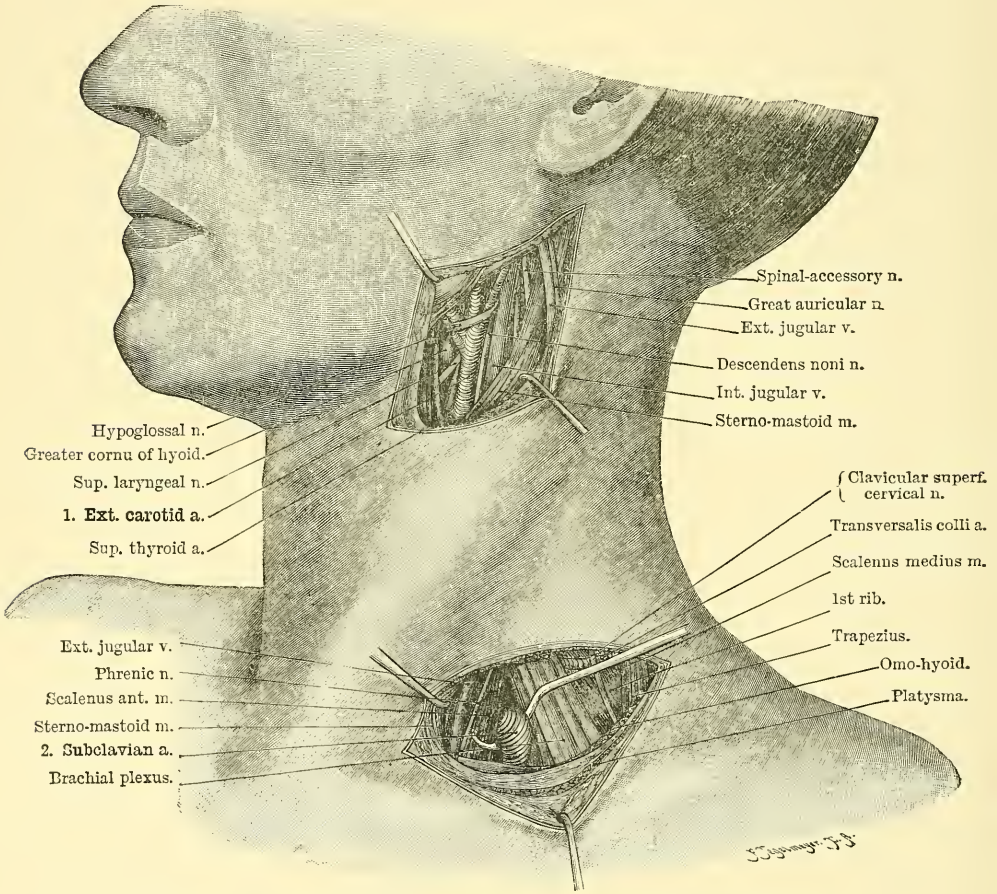

FIG. 117.—Ligature of the external carotid with the origins of the lingual, facial, and occipital arteries. Ligature of the subclavian artery.

Like the subclavian artery, it appears between the scalenus anticus and medius, being situated for the most part above the artery, although the lowest brachial nerve trunk may pass behind it on the first rib. Here the plexus can be stretched for spasmodic conditions in the arm. It was on the brachial plexus that the first experiments in nerve-stretching were made by Nussbaum and Billroth.

The omohyoid muscle lies in front of the plexus, and in the fatty tissue in front of it run the superficial cervical and the suprascapular arteries. The large transversalis colli artery passes between the cords of the plexus.

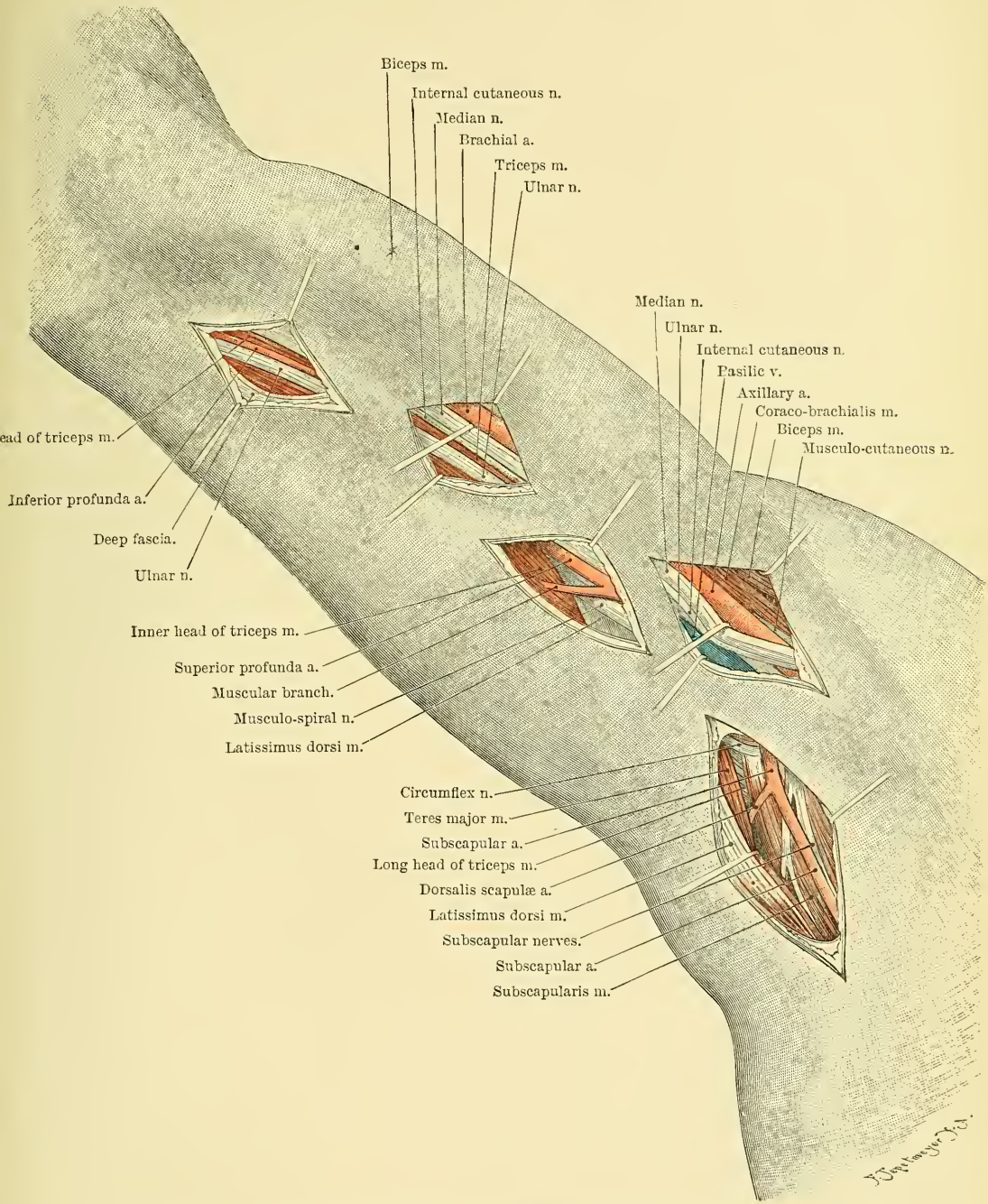

FIG. 118.—Axillary artery, brachial artery, superior profunda artery, subscapular artery, median, subscapular, musculo-spiral, and circumflex nerves.

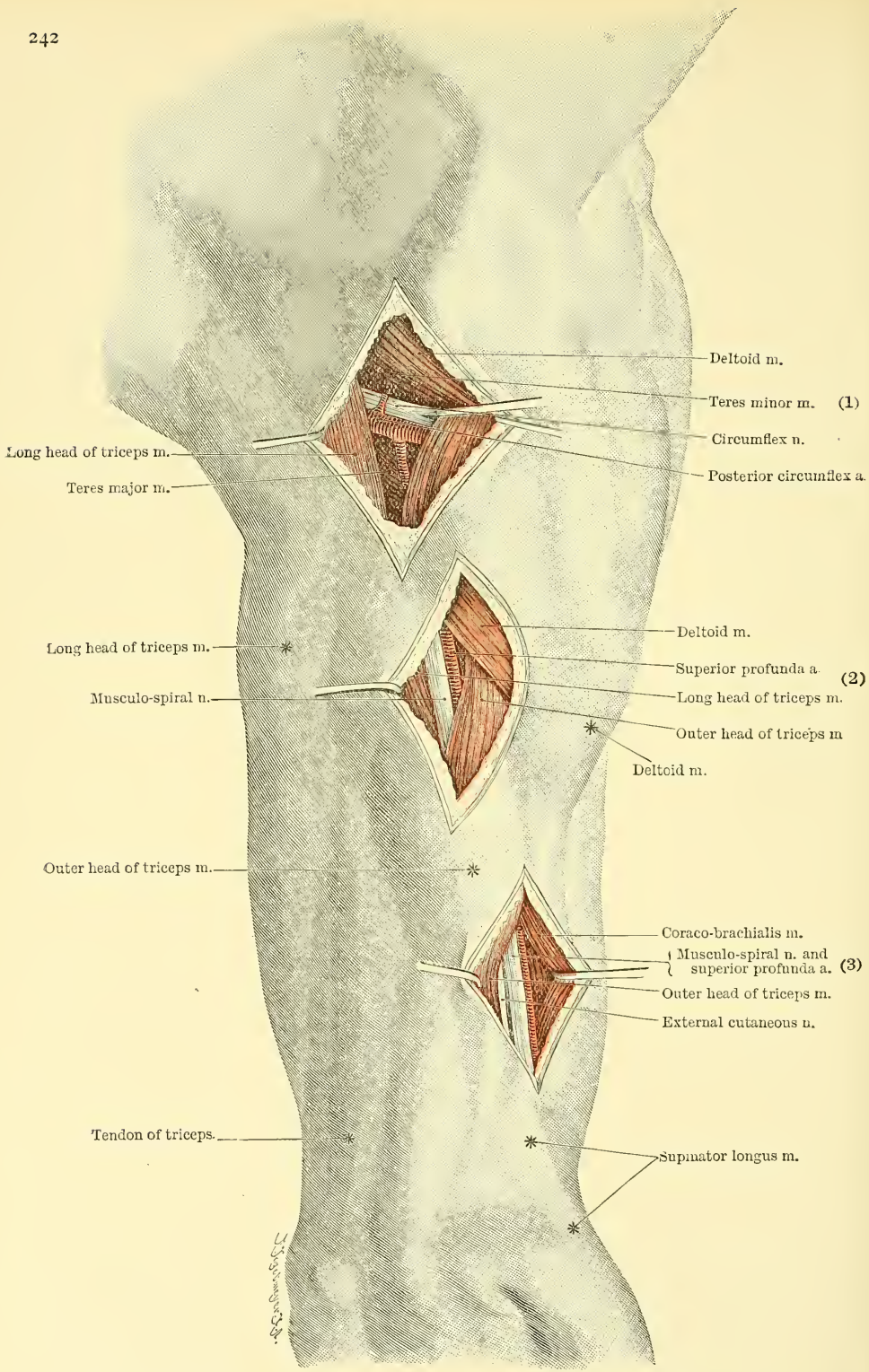

FIG. 119.—(1) Ligature of posterior circumflex artery, circumflex nerve. (2) and (3) Musculo-spiral nerve and superior profunda artery.

The numerous short muscular twigs to the scaleni, levator anguli scapulæ, serratus magnus and subclavius muscles are of no surgical interest, as only those branches which can be separated and recognised are worthy of mention.

23. Anterior Thoracic Nerves. These nerves which supply the pectoralis major and minor must be remembered by the operator when ligaturing the axillary artery immediately below the clavicle, as they cross the artery at this point (*vide* Ligature of the Axillary Artery).

24. Short and Long Subscapular Nerves. Supplying the subscapular and latissimus dorsi muscles, these nerves must be borne in mind when clearing the axilla of malignant glands. Their relations are shown in Fig. 118, and they are exposed by a similar method to that for the arteries of the same name which they accompany.

25. Long Thoracic Nerve. The nerve to the serratus magnus is seen in exposure of the long thoracic artery. It runs vertically downwards on the serratus magnus, and is to be avoided in the removal of axillary tumours (*vide* Ligature of the Long Thoracic Artery).

26. The Circumflex Nerve (N. Axillaris). The circumflex nerve is of importance because from its position it is specially exposed to damage when the arm is abducted and forcibly stretched. It may also be injured from pressure in the axilla (*e.g.* from a crutch or in a case of dislocation of the head of the humerus). Injury to it gives rise to paralysis of the deltoid and may also produce neuralgia from involvement of the lateral cutaneous branch behind and on the outer side of the deltoid.

The reader is referred to the description of ligature of the axillary artery and of the posterior circumflex artery, the illustrations in connection with which we here reproduce. The main branch of the circumflex nerve may be exposed for neuralgia or for local anæsthesia at the middle of the posterior border of the deltoid muscle (*vide* chapter on Local Anæsthesia).

27. Suprascapular Nerve. The suprascapular nerve is liable to injury in the supraspinous fossa where it passes under the suprascapular ligament (lig. transversum scapulæ superius) and especially where it enters the infraspinous fossa behind the neck of the scapula beneath the spinoglenoid ligament (lig. transversum scapulæ inferius). The nerve is exposed by an incision along the outer third of the spine of the scapula, dividing the tendon of the trapezius, and dissecting up the supraspinatus muscle.

The nerve is to be avoided in our posterior osteoplastic resection of the shoulder-joint.

28. Nerve to the Rhomboids (Dorsalis Scapulæ). The nerve to the levator anguli scapulæ and the rhomboid muscles is closely associated with the dorsalis scapulæ artery (*vide* Ligature of this Artery).

The long cutaneous branches of the brachial plexus to the arm are frequently the seat of neuralgia.

29. Lesser Internal Cutaneous Nerve (N. Cutaneus Brachii Medialis). In disease of the axillary glands, etc., this nerve is frequently the seat of a neuralgia which radiates down to the internal condyle of the humerus, for it has a series of connections with the upper intercostal nerves which specially expose it to irritation. In the description of ligature of the axillary artery it is recognised as the smallest nerve in the neuro-vascular bundle.

30. Internal Cutaneous Nerve (N. Cutaneus Antebrachii Medialis). This nerve, which is larger than, and in close apposition with, the lesser internal cutaneous, is also exposed in ligaturing the axillary artery at its termination. It pierces the fascia at the point in the middle of the arm where the basilic vein dips into the internal bicipital sulcus (*vide* Fig. 4, p. 19), and supplies the skin on the palmar and ulnar side of the forearm.

31. Musculo-Cutaneous Nerve. In the exposure of the terminations of the axillary artery (Fig. 118) the musculo-cutaneous nerve will be found in the antero-external bundle of nerves in front of the artery, behind, and external to the median nerve. It is easily recognised by its relatively-small size, and is reached with accuracy between the biceps and the brachialis anticus in the middle of the arm.

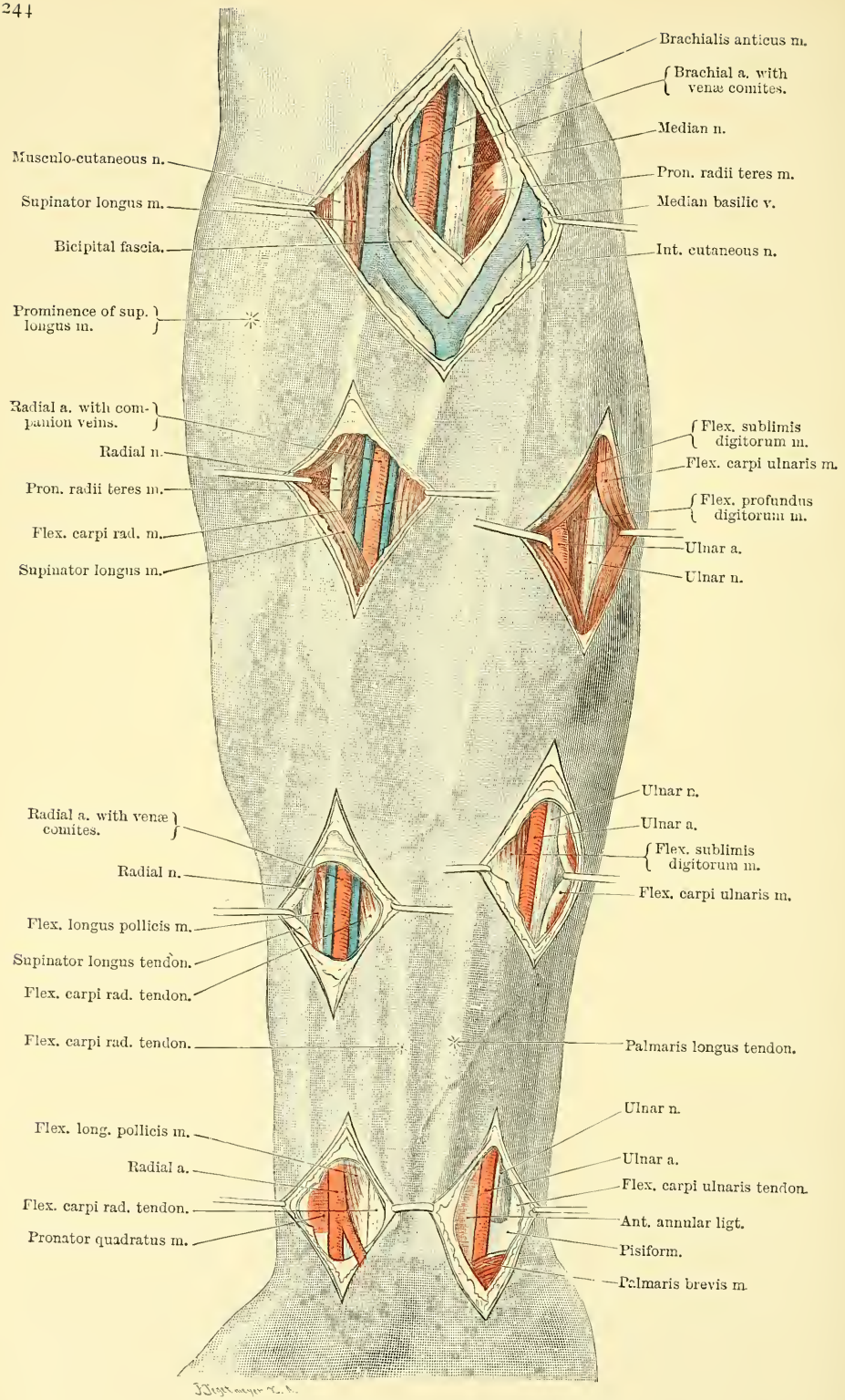

FIG. 120.—Brachial artery. Radial and ulnar arteries.

Above the middle of the upper arm. The incision descends along the internal bicipital sulcus from the lower part of the prominence of the coraco-brachialis. The muscular fibres of the biceps are exposed, and the muscle drawn outwards. The nerve lies, covered by the biceps, upon the outer border of the coraco-brachialis muscle, through which it penetrates in order to reach the anterior surface of the brachialis anticus muscle.

Higher up, the nerve may be found by making an incision over the prominence of the coraco-brachialis, and passing between this muscle and the short head of the biceps.

Below the middle of the upper arm. An incision is made along the outer edge of the biceps a finger's-breadth in front of the external bicipital sulcus; it is carried through the fascia down to the muscular fibres. The cephalic vein is avoided. After raising the biceps from the brachialis anticus, the finger is introduced between them and the nerve found towards the middle of the brachialis anticus lying under the thin fascia covering it. Care must be taken that the outer border of the brachialis anticus is not exposed instead of the biceps.

The cutaneous branch (N. cutaneus antibrachii lateralis) of the musculo-cutaneous which supplies the radial side of the forearm as far as the base of the thumb is reached with certainty at the point where it pierces the fascia (Fig. 120). An incision is made between the cephalic vein and the tendon of the biceps, the latter being easily felt in the fold of the elbow.

32. Median Nerve. The median nerve can be readily exposed in its whole length. In the axilla it lies to the outer side of the axillary artery (*vide* Ligature of the Axillary Artery).

It can also be easily exposed in the middle of the upper arm, where it lies in the internal bicipital sulcus, and crosses from without inwards in front of the brachial artery (Fig. 118). The nerve accompanies the brachial artery in its whole length, lying external to the artery above, and internal to it below.

In the bend of the elbow the nerve lies considerably to the inner side of the artery.

The median nerve (Fig. 120) lies half a centimetre internal to the brachial artery at the outer edge of the pronator teres muscle. The vessels and nerve are supported posteriorly by the brachialis anticus muscle. In this operation it is to be borne in mind that the artery and nerve descend from the internal bicipital sulcus, and therefore one must not pass to the outer side of the biceps tendon. The *musculo-cutaneous nerve* pierces the fascia external to the biceps tendon in the groove between it and the supinator longus.

On the front of the forearm the nerve lies between the flexor sublimus and flexor profundus digitorum muscles (Fig. 122).

In the upper third. Incision in the interval between the supinator longus and flexors, as in ligature of the radial artery. The pronator radii teres, which here covers the nerve, is divided internal to the above vessel. In the upper third of the incision the tendinous arch of the flexor sublimis digitorum is seen with the nerve descending behind it: it must be divided when the nerve is to be exposed farther down. At first the ulnar artery lies to the radial side of the nerve, and then passes almost at once under it as it arches downwards and inwards towards the ulnar side of the forearm. The interosseous artery passes directly downwards to lie deeply upon the interosseous membrane.

Below the middle. Incision in the middle of the forearm between the flexor carpi radialis and the palmaris longus. The muscular fibres of the flexor sublimis appear in the interval between these tendons, and its radial border having been exposed, the muscle is drawn inwards. The large nerve lies upon the flexor profundus digitorum muscle, accompanied by the median artery.

Above the wrist-joint. Incision through the skin and fascia along the radial side of the palmaris longus tendon.

On the radial side of the palmaris longus, farther down, the nerve becomes superficial between the tendons of the flexor digitorum sublimis.

Of the branches of the median the following are to be considered :—

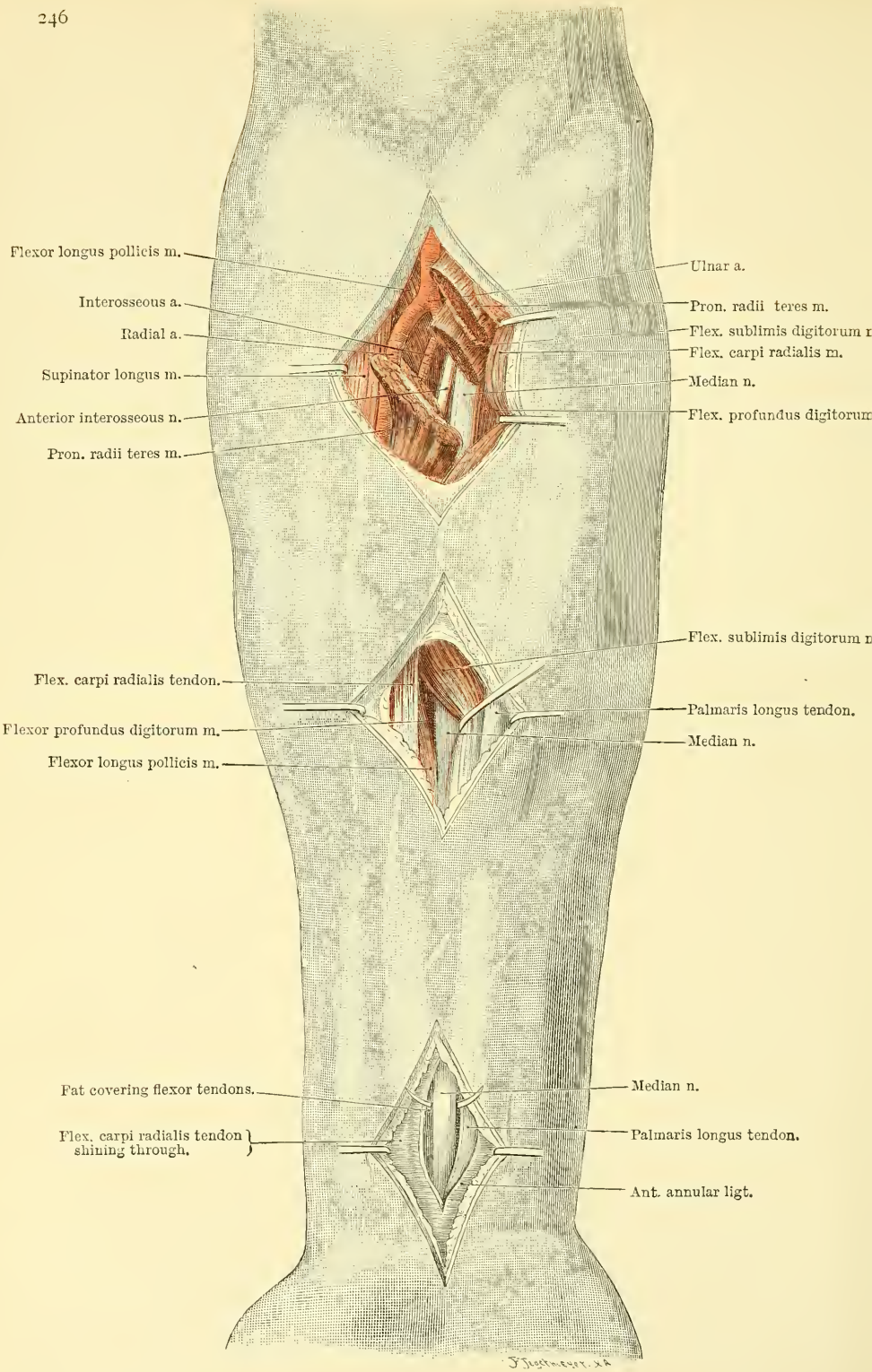

FIG. 121.—Median nerve, anterior interosseous nerve, interosseous artery.

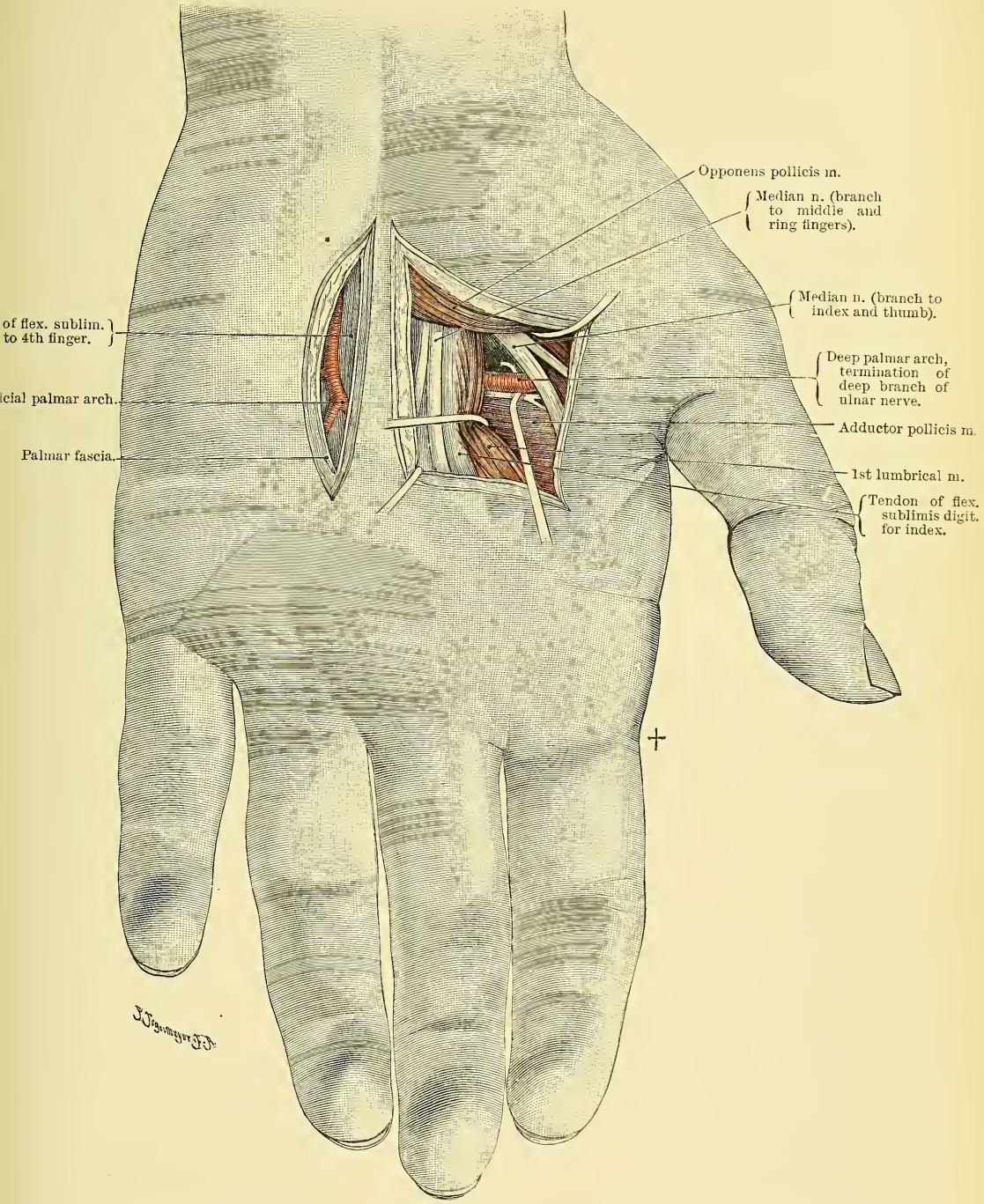

FIG. 122.—Superficial palmar arch (left). Deep palmar arch (right), with two branches of median nerve.

(c) Common Palmar Digital Branches

In the palm the branches of the median nerve lie on the flexor tendons immediately underneath the strong palmar fascia. The two divisions of the nerve, which are distributed to the first four fingers, may be exposed by the same incision as that for the deep palmar arch.

An incision is carried through the skin and the strong anterior annular ligament at the junction of the thenar and hypo-thenar eminences. The large nerve lies upon the common flexor sheath and divides into two divisions, the outer supplying the thenar muscles (with the exception of the adductor), both sides of the thumb, and the outer side of the index finger; the inner supplying the two outer lumbricals, the ulnar side of the index, both sides of the middle and the radial side of the ring finger (Fig. 122).

(d) Anterior Interosseous Nerve

The Anterior Interosseous Branch of the Median Nerve (Fig. 121) is seen passing outwards from the median in exposing the latter in its upper third. The

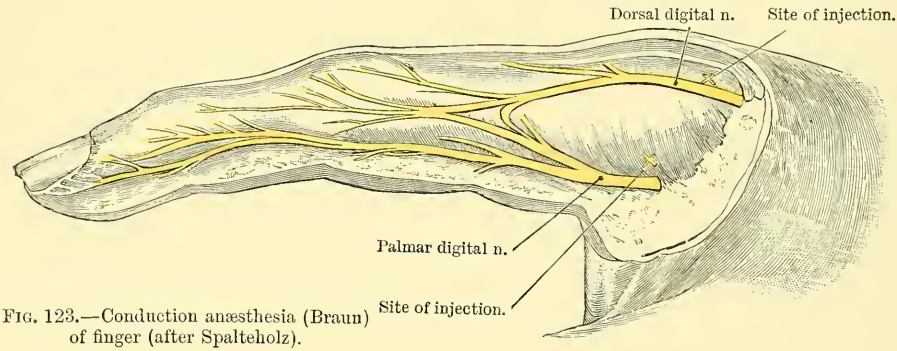

FIG. 123.—Conduction anæsthesia (Braun) of finger (after Spalteholz).

anterior interosseous nerve (with the artery) is exposed in exactly the same manner as the median nerve in the middle third of the forearm. After the median has been exposed, the anterior interosseous branch may be seen upon its outer side passing deeply between the flexor longus pollicis and the flexor profundus digitorum to reach the interosseous membrane.

(e) Palmar Cutaneous Branch of the Median

The palmar cutaneous branch of the median nerve may be exposed by the same incision as that for the median itself above the wrist-joint, where it pierces the fascia and descends to the palm.

(f) Palmar Digital Branches

Reference has already been made to the common palmar digital branches in exposing the median nerve in the palm of the hand. The digital branches of the median are the largest sensory nerves of the fingers. They are shown exposed in Fig. 123.

33. Ulnar Nerve. At the point where the axillary artery is tied in the arm, the ulnar nerve lies on the artery in the antero-internal nerve-bundle along with the two internal cutaneous nerves and the inner head of the median nerve, at which point it is easily found.

Lower down in the arm it lies in the internal bicipital sulcus.

Incision over the inner head of the triceps along a line ascending vertically from the internal epicondyle. The strong fascia is divided behind the white line corresponding to the internal intermuscular septum. This exposes the muscular substance of the inner head of the triceps, in the most superficial fibres of which lie the ulnar nerve and the inferior profunda artery.

Behind the internal condyle of the humerus at the elbow, the ulnar nerve again occupies an absolutely definite position (Fig. 124).

Incision through skin and fascia upon the posterior surface of the base of the internal epicondyle. The nerve lies close to the bone along the inner edge of the triceps, disappears below between the two heads of origin of the flexor carpi ulnaris which spring from the epicondyle and the olecranon respectively, and rests upon the flexor profundus digitorum. The terminal branch of the inferior profunda artery lies alongside the nerve.

In the upper third of the forearm the ulnar nerve furnishes the guide to the ulnar

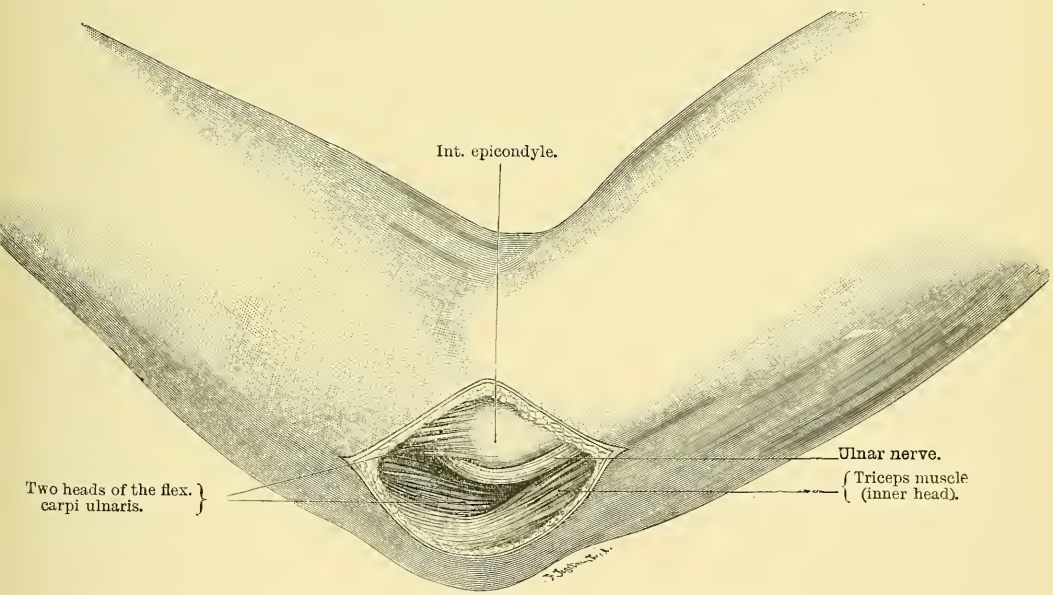

FIG. 124.—Ulnar nerve at the internal epicondyle.

artery between the flexor sublimis and profundus (*vide* Ligature of Ulnar Artery, Fig. 120).

The ulnar nerve is exposed in the same way as the artery in the lower third of the forearm and at the pisiform bone.

Branches of the Ulnar Nerve

(*a*) The palmar cutaneous branch to the ball of the little finger is only of importance in regard to the production of local anæsthesia.

(*b*) The dorsal cutaneous branch which supplies sensation on the back of two and a half fingers passes on to the dorsum of the hand a finger's-breadth below the styloid process of the ulna, which is easily felt through the skin.

(*c*) The palmar branch divides in the palm of the hand a finger's-breadth below the pisiform, above and to the ulnar side of the hook of the unciform (which can be distinctly felt) into a superficial branch which passes beneath the palmar fascia on the muscles of the hypothenar eminence to give digital branches to one and a half fingers

and into a deep branch which dips down on to the interossei, which it supplies along with the lumbricals and the adductor pollicis.

These branches can be exposed at the point mentioned above, and to the ulnar side of the hook of the unciform. The terminal branch of the deep division is seen in ligature of the deep palmar arch (*vide* Fig. 122).

34. Musculo-spiral Nerve (N. Radialis). In the axilla, at the point where the terminal portion of the axillary artery is ligatured, the musculo-spiral nerve lies along with the circumflex nerve posterior to the artery.

In the upper third of the arm. The musculo-spiral nerve in the upper third of the arm is exposed in the same manner as for ligature of the superior profunda artery on the inner side of the arm (Fig. 118). The nerve lies behind the artery, descending on the tendon of the latissimus dorsi and then passing towards the back of the humerus between the inner and long heads of the triceps. In looking for it care must be taken not to go too far back, as otherwise one gets behind the nerve and artery which are here in relation to the bone in the internal bicipital sulcus. The nerve is recognised by its characteristic position on the latissimus dorsi.

Above the middle of the posterior surface of the arm (Fig. 125). As a guide to the incision, a line is drawn along the posterior surface of the upper arm from a point a finger's-breadth behind the posterior border of the deltoid and close to the long head of the triceps down to the tip of the olecranon. The incision begins below the level of the posterior axillary fold, and passes downwards along this line in the interval between the long and outer heads of the triceps, which are separated from one another down to the bone. The nerve lies between the inner and outer heads of the triceps after having passed under the long head at the lower border of the latissimus dorsi. Parallel to and in front of the nerve lies the superior profunda artery, which is also in contact with the inner surface of the humerus.

At the bend of the elbow the musculo-spiral nerve, together with its bifurcation into radial and posterior interosseous nerves, lies in the interval between the supinator longus and brachialis anticus muscles.

An incision is made at the bend of the elbow in a line prolonged from the external bicipital sulcus along the anterior edge of the supinator longus muscle. The median cephalic vein is drawn aside, and after division of the fascia, the musculo-cutaneous nerve appears at the lower part of the incision beside the biceps tendon. The latter nerve pierces the fascia to supply the skin upon the radial side of the anterior aspect of the forearm. By passing towards the bone at the outer border of the brachialis anticus muscle, we find the radial and posterior interosseous nerves, the one in front of the other, and beneath them the terminal branch of the superior profunda artery.

Branches of the Musculo-Spiral Nerve

(*a*) *The upper external cutaneous branch* (*n. cutaneus brachii posterior*) which supplies the skin on the posterior surface of the upper arm is looked for at the point where the musculo-spiral nerve crosses the tendon of the latissimus dorsi (*vide* ligature of the superior profunda artery in the upper third).

(*b*) *The lower external cutaneous branch* (*n. cutaneus antebrachii dorsalis*) which is distributed on the back of the forearm pierces the fascia in the external bicipital sulcus below the middle of the arm (*vide* Fig. 5).

(*c*) *The posterior interosseous nerve* (*ramus profundus*). (Fig. 126.) The posterior interosseous nerve is the motor nerve to the supinators and extensors in the forearm. To expose it an incision is carried vertically downwards from the head of the radius, along the radial aspect of the posterior surface of the forearm, in the interval between the radial extensors and the tendinous extensor communis digitorum. The fascia is divided between the glistening tendinous origin of the extensor communis digitorum and the muscular fibres of the radial extensors, the latter being drawn forwards with blunt hooks. The supinator brevis muscle now appears, the fibres of which pass in a characteristic manner obliquely downwards and forwards. The nerve

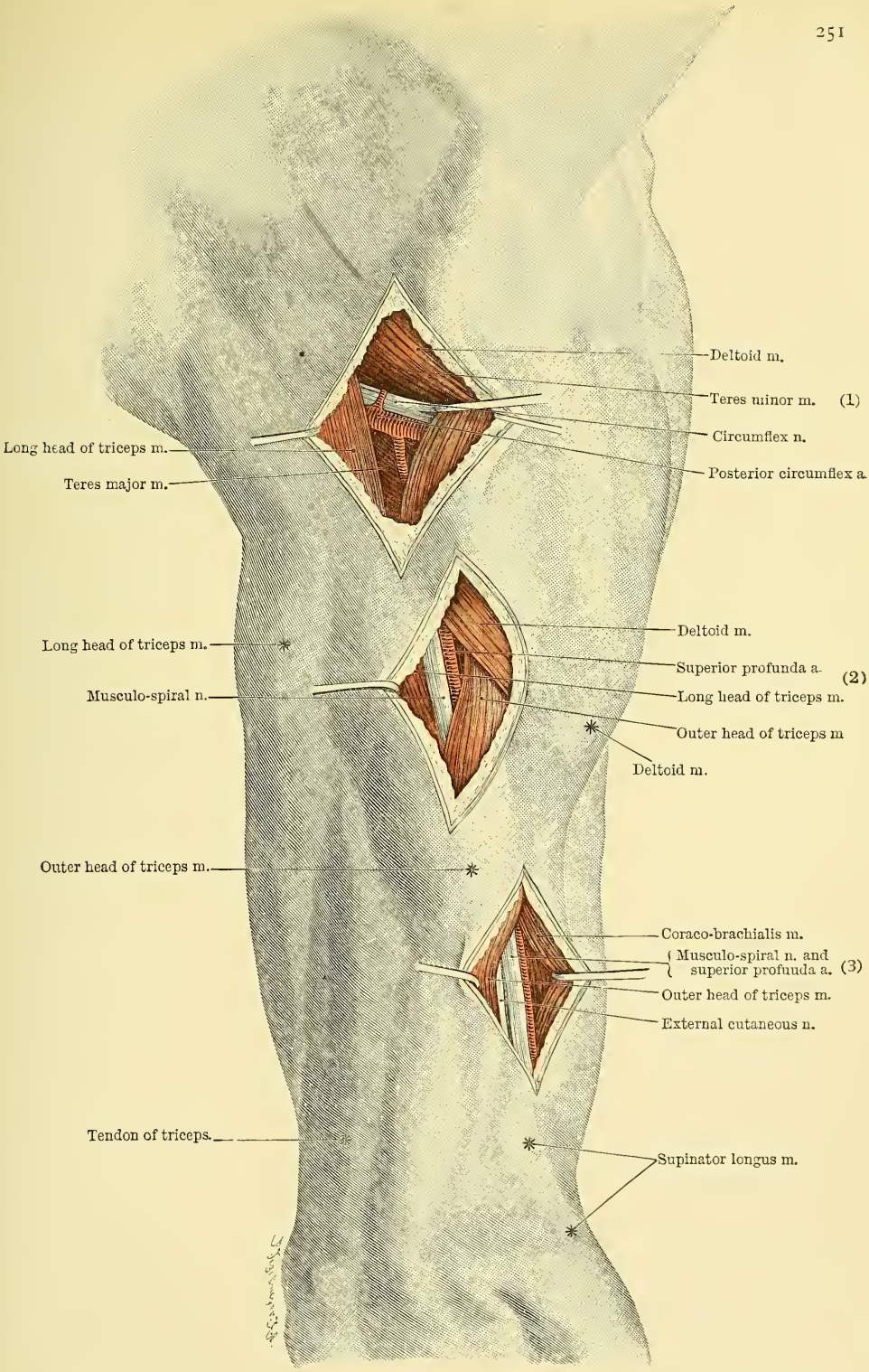

FIG. 125.—(1) Ligature of posterior circumflex artery, circumflex nerve. (2) and (3) Musculo-spiral nerve and superior profunda artery.

issues from the muscle about 5 cm. (2 in.) below the head of the radius, and at once breaks up into several branches. To expose the trunk of the nerve for a greater extent, the supinator brevis muscle is divided in an upward direction. The forearm is flexed and held in a position midway between pronation and supination. Longer branches of the nerve pass between the extensor communis and radial extensors to the extensors of the thumb and index finger, which lie upon the posterior surface of the radius. In the lower third of the arm the terminal branch passes on to the interosseous membrane and ends upon the ligaments of the wrist-joint.

The *posterior interosseous artery* passes backwards above the upper border of the interosseous membrane, appears upon the posterior aspect of the forearm at the lower border of the supinator brevis muscle, and descends between the superficial and deep layers of extensor muscles.

(*d*) *The radial nerve* (*ramus superficialis*). This sensory branch descends on the outer side of the radial artery (*vide* Fig. 120) as far as the lower third of the forearm, where it passes backwards underneath the supinator longus, and pierces the deep fascia. It is distributed to the adjacent margins of the outer four digits. The nerve can be felt through the skin on the back of the lower end of the radius.

(g) Thoracic Nerves

35. Intercostal Nerves. Of the twelve thoracic nerves, eleven are termed intercostal and one subcostal. They run close to the lower border of the rib, below the artery of the same name, and, except at their commencement and termination, lie under cover of the fibres of the external intercostal muscles.

They supply sensation to the whole of the skin of the thorax (including the mamma and the abdomen) through their lateral cutaneous branches (which are given off vertically between the axillary and mammary lines), and their anterior cutaneous branches, which are found in the anterior ends of the intercostal spaces and on the rectus abdominis.

By exposing the intercostal nerves on the posterior surface of the thorax, and stretching or dividing them in cases of neuralgia (in the thorax or abdomen) all the branches are affected with the exception of the posterior primary divisions, which can only be reached by dissecting the muscles of the back off the posterior surfaces of the vertebral arches and transverse processes.

The intercostal nerve lies between the intercostal muscles below the artery. It may be exposed in the same way as the artery—for the purpose of stretching it in intercostal neuralgia (Fig. 127). If one has only to do with a single nerve, the incision is made from the prominence of the erector spinæ muscle along the rib and down to the bone. The external intercostal muscle is separated from the lower border of the rib, and the nerve is pulled forwards by a blunt hook from beneath the overhanging rib above. Where more than one nerve is involved, a vertical incision is made over several ribs.

(h) The Lumbar Plexus

The lumbar plexus is formed by the first, second, third, and part of the fourth lumbar nerves, receiving also a twig of communication from the twelfth dorsal nerve.

The sensory branches derived from it are distributed not to the abdomen, but to the inguinal region, the outer, inner, and anterior aspects of the thigh, and the upper part of the pudenda. Pain in these regions may therefore be dealt with surgically.

36 and 37. Ilio-hypogastric and Ilio-inguinal Nerves. Both these nerves are encountered in exposing the kidney from behind; they lie on the anterior surface of the quadratus lumborum, at the outer border of which they pass between the internal oblique and transversalis. (The continuations of the intercostal nerves also lie in this layer.) They can be easily exposed in this situation (*vide* chapter on Nephrotomy).

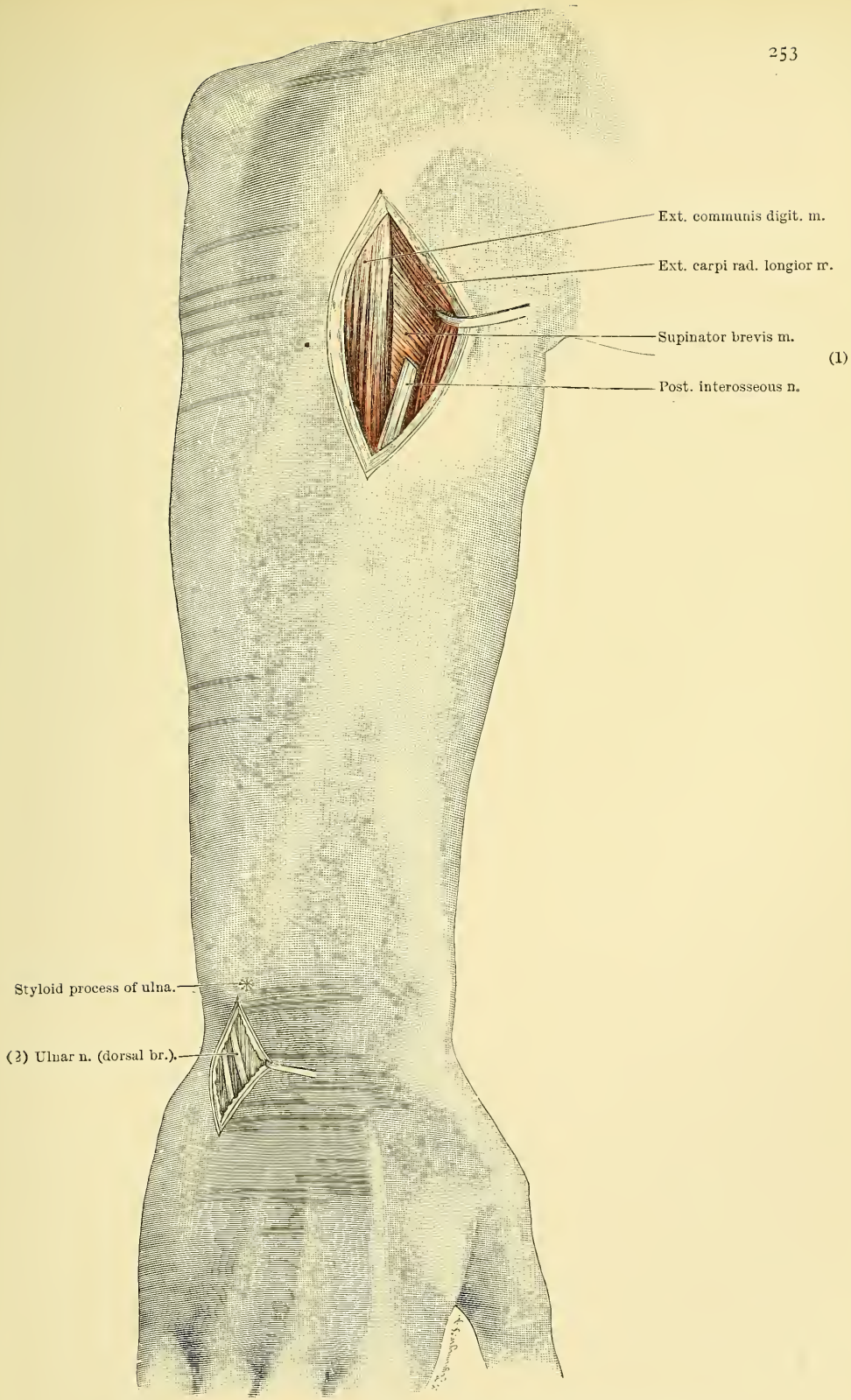

Fig. 126.—(1) Posterior interosseous nerve, below the head of the radius.
(2) Dorsal branch of ulnar nerve at the wrist.

The ilio-hypogastric nerve runs above, and the ilio-inguinal through the external abdominal ring to the mons veneris and the upper part of the pudenda. The ilio-

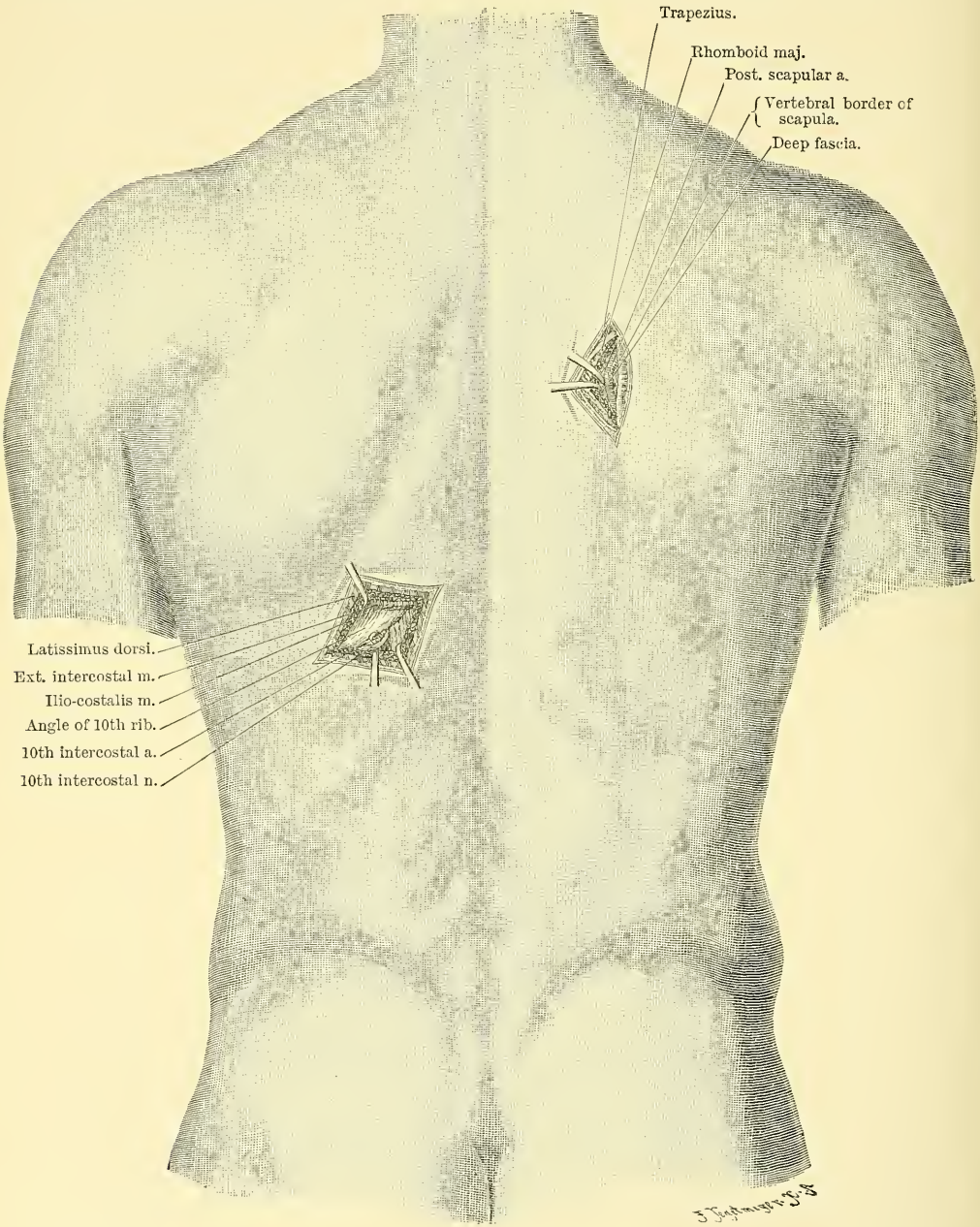

FIG. 127.—Exposure of the 10th rib and the 10th intercostal artery and nerve. Ligature of the posterior scapular artery.

inguinal is more easy to recognise and can be injected for the production of local anæsthesia in operations on the spermatic cord or round ligament.

The ilio-hypogastric supplies the upper and outer part of the skin of the thigh, the ilio-inguinal the upper part of the inner side of the thigh.

38. External Cutaneous Nerve (N. Cutaneus Femoralis Lateralis). This nerve supplies the skin on the outer side of the thigh as far as the knee. In the iliac fossa it lies on the iliacus muscle (*vide* Fig. 53, Ligature of the Common Iliac Artery), when it is readily seen and may be exposed after it has crossed the circumflex iliac artery on to the origin of the sartorius, at which point it pierces the deep fascia.

Incision (Fig. 128) through skin and fascia parallel to Poupart's ligament a finger's-breadth below the anterior superior iliac spine. The nerve lies under the fascia, 2 cm. ($\frac{3}{4}$ in.) below the spine, and descends obliquely downwards and outwards either at the outer edge of the origin of the sartorius, or over its anterior surface. The operation may be indicated in Bernhardt's meralgia paræsthetica.

39. Genito-crural Nerve (N. Genito-femoralis). This nerve divides into a crural and a genital branch, the former of which descends on the outer side of the femoral artery to supply the skin on the anterior surface of the thigh, while the latter enters the internal abdominal ring and is distributed to the spermatic cord, the dartos and the scrotum (or labium). Both branches can be readily injected during operations in the region of the femoral vessels (*vide* Fig. 128), or on the spermatic cord in the inguinal canal for the production of local anæsthesia.

40. Anterior Crural Nerve (N. Femoralis). This, the principal nerve for the thigh, receives fibres from all the four nerves of the lumbar plexus. It is often cut down upon and injected for the production of conduction anæsthesia, or in order to block the nerve in tetanus.

The nerve supplies the lower part of the front of the thigh with common sensation, and also the region below the patella through the long saphenous nerve.

To expose the nerve at Poupart's ligament (Fig. 128) a transverse incision is made below and parallel to the middle third of Poupart's ligament. The superficial epigastric artery is ligatured and the superficial layer of the fascia lata, which forms the sheath of the ilio-psoas, is opened. The nerve lies immediately under this to the inner side of the muscle, having already broken up into several branches, and being separated from the artery by the deep layer of the ilio-psoas fascia which divides off the vascular from the muscular compartment.

Exposure in the upper third of the thigh (*vide* Ligature of the External Circumflex Artery). A vertical incision is made 1 cm. external to the middle of Poupart's ligament, beginning two fingers'-breadth below the ligament, the centre of the incision corresponding to the level of the root of the great trochanter. After dividing the skin and dense fascia lata, the inner border of the sartorius is exposed and retracted outwards. The inner border of the rectus femoris is then recognised and the nerve is found in the fatty tissue covering the lower end of the ilio-psoas.

Branches of the Anterior Crural Nerve

(*a*) *Anterior Cutaneous Nerves.* The points at which these nerves pierce the fascia and at which they can be injected to produce local anæsthesia are shown in the illustrations in the chapter on local anæsthesia.

(*b*) *The Long Saphenous Nerve.* This sensory branch is distributed to the skin on the inner side of the thigh: by one terminal branch (ramus infrapatellaris) it supplies the area in front of and below the patella, by the other it supplies the inner side of the leg and foot.

The nerve accompanies the femoral artery as far as the opening in the adductor magnus, and follows the course of the internal saphenous vein at the knee and in the leg.

Exposure in the thigh. *Vide* ligature of the femoral artery in the upper third of the thigh and in Hunter's canal (Fig. 128).

To expose the nerve *above the internal condyle of the femur* an incision is made in front of the sartorius, under which the nerve passes downwards and backwards; the nerve lies at the edge of the tendon of the adductor magnus.

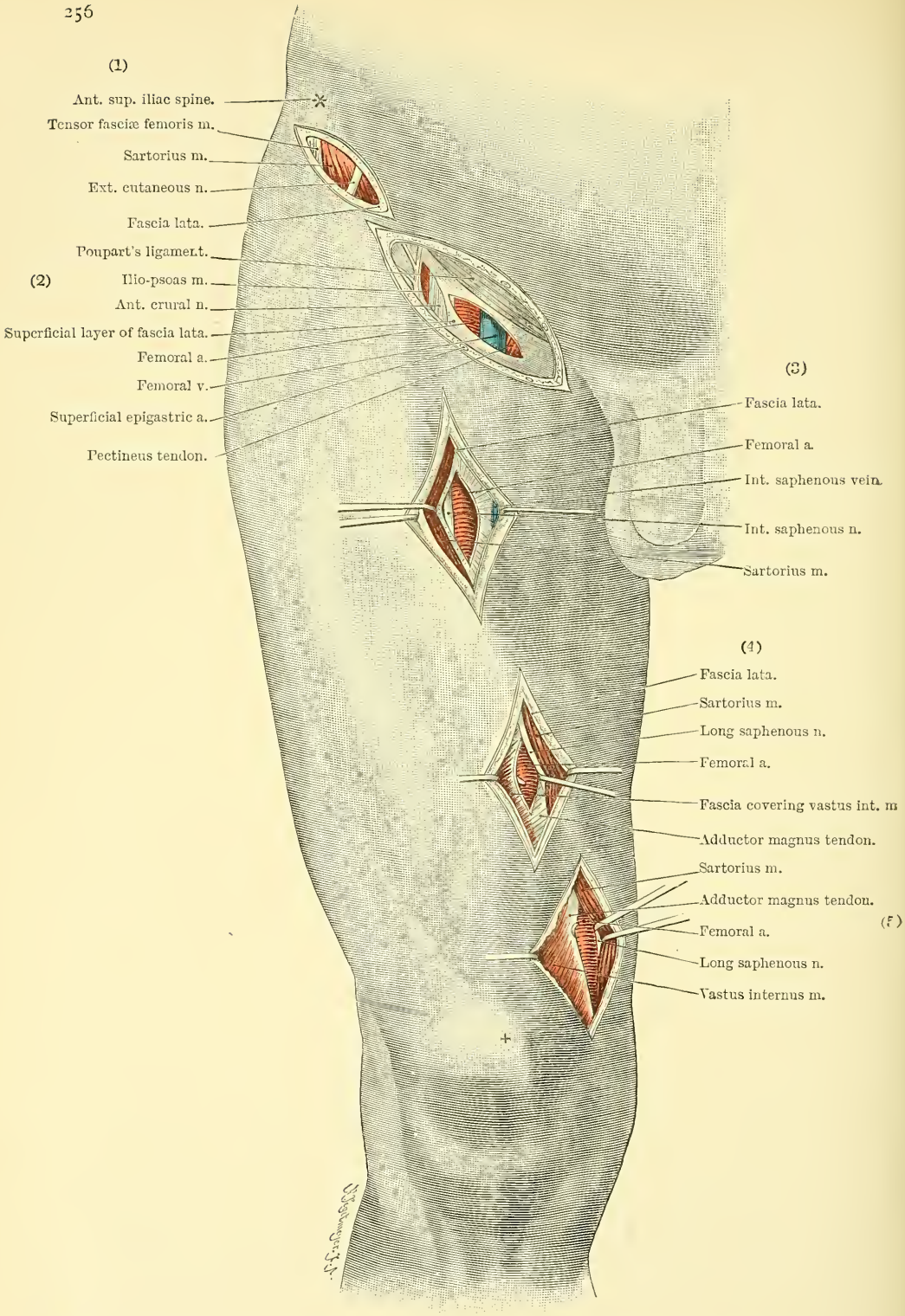

FIG. 128.—(1) External cutaneous nerve. (2) Common femoral artery. (3) Femoral artery. (4) Femoral artery at the opening in the adductor magnus. (5) Femoral artery at the lower end of the femur.

At the knee. An incision is made immediately behind the inner tuberosity of the tibia at the posterior edge of the sartorius, beneath which the nerve descends, in the groove between it and the tendon of the gracilis. The internal saphenous vein, which can be felt through the skin, lies upon the fascia in front of the nerve.

In the leg. The nerve, accompanied by the internal saphenous vein, runs for its whole length along the inner border of the tibia, and in the line of the incisions for ligaturing the posterior tibial artery. Cf. Ligature of posterior tibial artery.

At the ankle-joint. The nerve along with the internal saphenous vein can be felt at the anterior border of the internal malleolus.

41. Obturator Nerve. The lowest nerve of the lumbar plexus crosses over the brim of the pelvis and reaches the inner side of the thigh by passing through the obturator groove of the thyroid foramen, where it gives off branches to the strong adductor muscles. Its sensory portion is of importance in the diagnosis of obturator hernia, giving rise to neuralgic pain on the inner side of the thigh.

The incision—the same as for ligature of the internal circumflex branch of the profunda femoris—descends vertically from a point a finger's-breadth internal to the middle of Poupart's ligament. The skin, superficial fascia, and superficial layer of the fascia lata are divided. The internal saphenous vein which lies upon the fascia is drawn outwards. The strong pectineal fascia is divided just internal to the femoral vein. After defining the outer border of the pectineus muscle, the latter is separated from the os pubis and fascia over the obturator externus, and is drawn well inwards. The strong transversely-striated fascia over the obturator externus muscle is now divided, and the finger, passed above the upper border of the muscle, feels for the under surface of the horizontal ramus of the pubis, below which the artery leaves the obturator foramen on the anterior surface of the external obturator muscle accompanied by the obturator nerve, which lies above it.

(i) Sacral Plexus

The sacral plexus is formed by the greater part of the fourth lumbar nerve, the fifth lumbar, and the first three sacral nerves. Lying on the postero-lateral wall of the pelvis (in front of the pyriformis and behind the pelvic fascia and peritoneum, to the side of the rectum and the contents of Douglas's pouch), it is not infrequently involved in diseases of the pelvic organs. There is no doubt that in many cases of pelvic neuralgia and sciatica, surgeons fail to discover the source of the mischief in the pelvis itself and are too backward in undertaking freeing of the nerve-roots and the plexus from pressure and adhesions.

In operations of this sort, it must be remembered that the internal iliac artery lies in front of the upper part of the plexus and gives off the gluteal artery, which runs backwards between the lumbo-sacral cord and the first sacral root, and the sciatic artery between the second and third sacral roots.

42 and 43. Superior and Inferior Gluteal Nerves. These are the motor nerves to the muscles of the buttock, and accompany the corresponding arteries (gluteal and sciatic), *q.v.*

44. Small Sciatic Nerve. This nerve can be easily exposed. It accompanies the sciatic artery and the great sciatic nerve in the buttock, and through its gluteal and perineal branches supplies the lower part of the buttock and perineum, while its main division is distributed on the posterior aspect of the thigh.

In the buttock it is exposed by the method described for ligature of the sciatic artery (*q.v.*). In the thigh the small sciatic nerve is reached by the same incision as serves to expose the great sciatic nerve (see Fig. 129). The nerve lies underneath the fascia but much more superficial than the great sciatic nerve.

45. Great Sciatic Nerve. From its position and size the great sciatic ranks next to the trigeminal nerve in surgical importance. It is often the seat of neuralgia, which may be either traumatic in origin or more often due to pelvic and spinal disease.

It is the largest branch of the plexus, and leaves the pelvis through the great

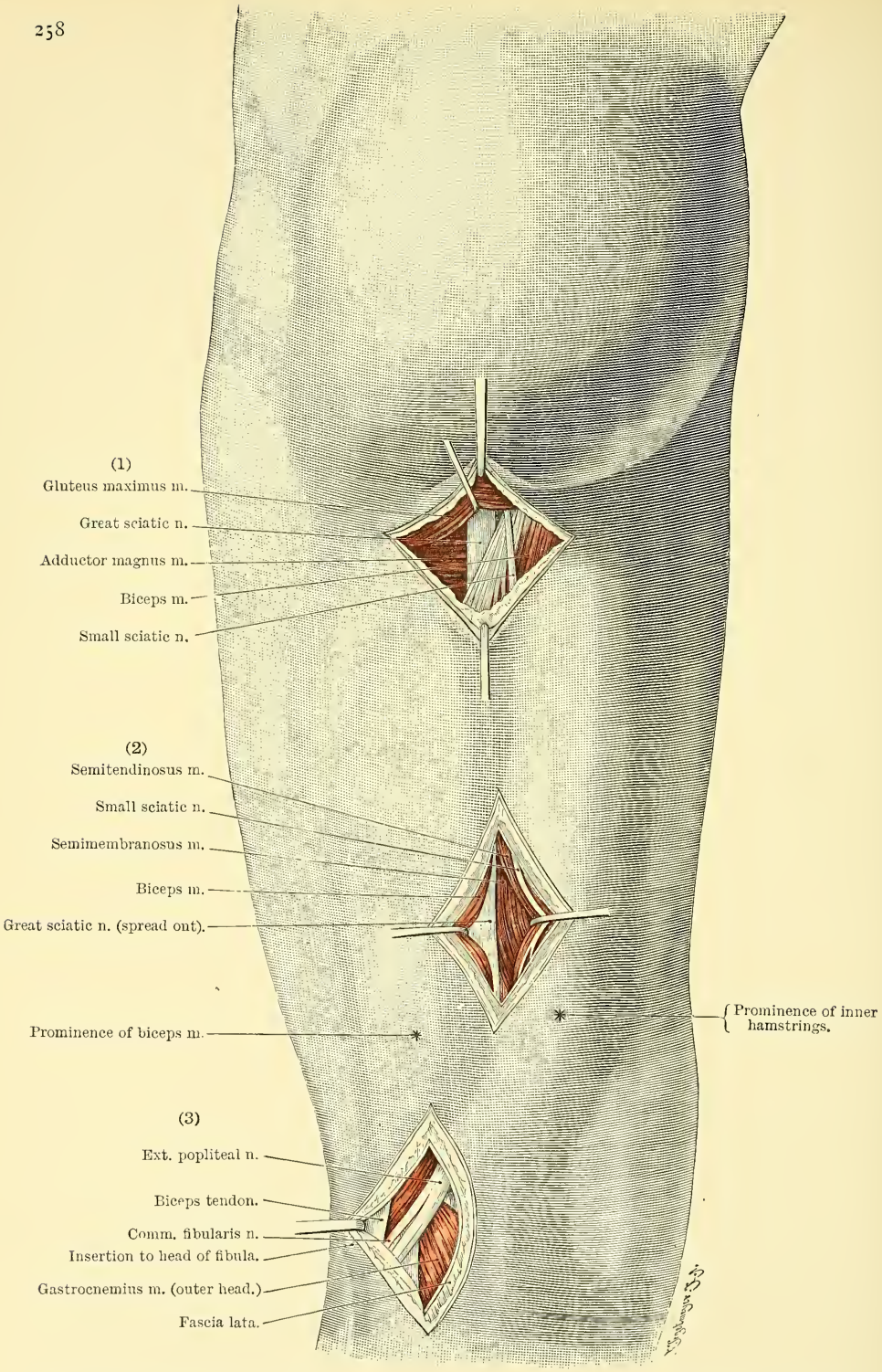

FIG. 129.—(1) Great sciatic nerve at the fold of the buttock. (2) The same in the midd'e of the thigh. (3) External popliteal and musculo-cutaneous nerves.

sacro-sciatic notch, at the lower border of the pyriformis, at which point it is easily accessible for surgical interference.

In the buttock the trunk of the great sciatic nerve is exposed in the same way as the sciatic artery. Even in the rare cases in which it divides high up, the external and internal popliteal nerves lie close to one another as far as the lower third of the thigh. The nerve is found midway between the tuber ischii and the great trochanter covered by the gluteus maximus, and lying on the obturator internus and gemelli above, and on the quadratus femoris lower down.

Incision corresponding to the middle two-thirds of a line from the postero-inferior spine of the ilium to the root of the great trochanter, parallel to the incision for ligature of the sciatic artery. The skin, dense subcutaneous fat, and fascia are incised, the fibres of the gluteus maximus are separated by blunt dissection, and the lower border of the pyriformis exposed. The sciatic artery accompanied by the inferior gluteal nerve emerges from below the inner end of the latter muscle, and while both give off large branches to the gluteus maximus, the nerve sends off a branch which joins lower down with the small sciatic nerve. The ischial spine and the small sacro-sciatic ligament, the latter of which passes inwards from the tip of the ischial spine, afford a good guide to the point at which the artery leaves the pelvis. The lower border of the great sacro-sciatic notch over which the artery runs, is felt above the ischial spine.

The course of the small sciatic nerve corresponds to the continuation of the trunk of the artery (Fig. 129). At a deeper level and more external the broad, easily-palpable trunk of the great sciatic nerve can be felt running downwards on the bone over the base of the ischial spine and the obturator internus muscle (Fig. 129).

In the thigh. The trunk (*i.e.* before it divides into internal and external popliteal nerves) extends only to the lower third of the thigh, in which position it can be readily exposed (Fig. 129).

To expose it in the *upper part of the thigh*, a vertical incision is made descending from the fold of the buttock from a point midway between the tuber ischii and the posterior border of the great trochanter. After division of the skin and fascia, the lower border of the gluteus maximus is exposed and drawn upwards so as to expose the outer edge of the biceps, which runs obliquely downwards and outwards. Between the fascia lata and the biceps is the small sciatic nerve. The large trunk of the great sciatic nerve lies deeper under the outer edge of the biceps, which is to be drawn inwards. In the same region, but deeper and more internal, is a branch of the sciatic artery, which may be ligatured where it lies upon the adductor magnus muscle.

Below the middle of the thigh. Incision upon the posterior aspect of the thigh midway between the semitendinosus and semimembranosus internally and the biceps externally. On the skin being divided, the small sciatic nerve appears either upon or under the fascia. On passing deeply between the above muscles we find the great sciatic nerve lying upon the posterior surface of the bone, having already frequently divided into its two main branches.

(a) The Internal Popliteal Nerve with its Branches. The internal popliteal nerve is the continuation of the trunk of the great sciatic and runs vertically down the middle of the popliteal space.

In the popliteal space. A vertical incision is made over the middle of the popliteal space opposite the knee-joint. The short saphenous vein is to be avoided at the lower part of the incision. It ascends between the two heads of the gastrocnemius and opens into the popliteal vein. To its outer side is the nervus communicans tibialis. The dissection is continued through the fat to the inner side of these structures and between the heads of the gastrocnemius. The internal popliteal nerve is the first structure to appear. When this is drawn outwards the popliteal vein comes into view, closely bound down by a strong sheath to the subjacent popliteal artery, which lies above upon the fat covering the femoral trigone, and below upon the popliteus muscle.

In the leg. The posterior tibial nerve lies close to the outer side of the posterior tibial artery: it is therefore exposed in the same way as the artery (Fig. 131).

(*a*) *Ramus Communicans Tibialis* (*N. Cutaneus Surœ Medialis*). This nerve

has a very definite course and accompanies the short saphenous vein. It lies on the outer side of the vein in the middle of the calf of the leg between the two heads of the gastrocnemius and under cover of the deep fascia which it pierces below the prominence of the calf (Fig. 130).

Behind the external malleolus the short saphenous nerve, which is formed by the union of the nervus communicans tibialis with the nervus communicans fibularis, lies

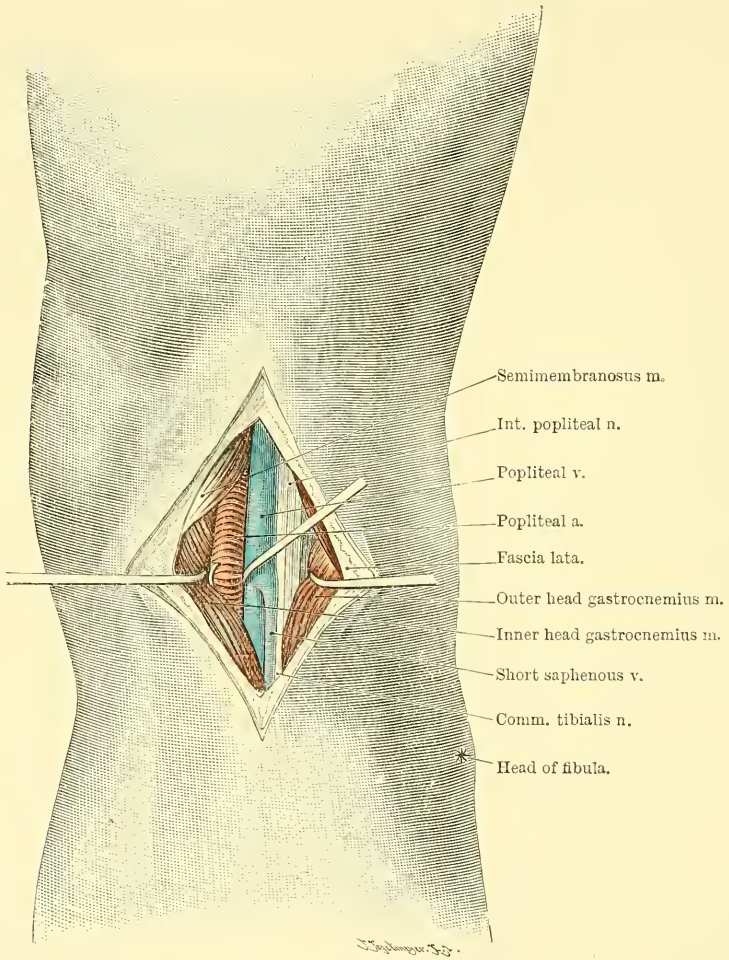

FIG. 130.—Ligature of popliteal artery.

on the fascia close to the vein midway between the tendo Achillis and the malleolus. It is distributed to the outer border of the foot.

(*b*) *Internal Plantar Nerve. At the inner border of the foot.* An incision beginning a finger's-breadth below and in front of the sustentaculum tali is carried horizontally backwards along the inner border of the foot above the prominence of the abductor hallucis muscle. After division of the skin and fascia the abductor hallucis is exposed, and separated downwards from the subjacent deep fascia. On dividing the latter we find the plantar vessels opposite a line continued downwards from the posterior border of the internal malleolus. The posterior tibial nerve lies immediately below the artery.

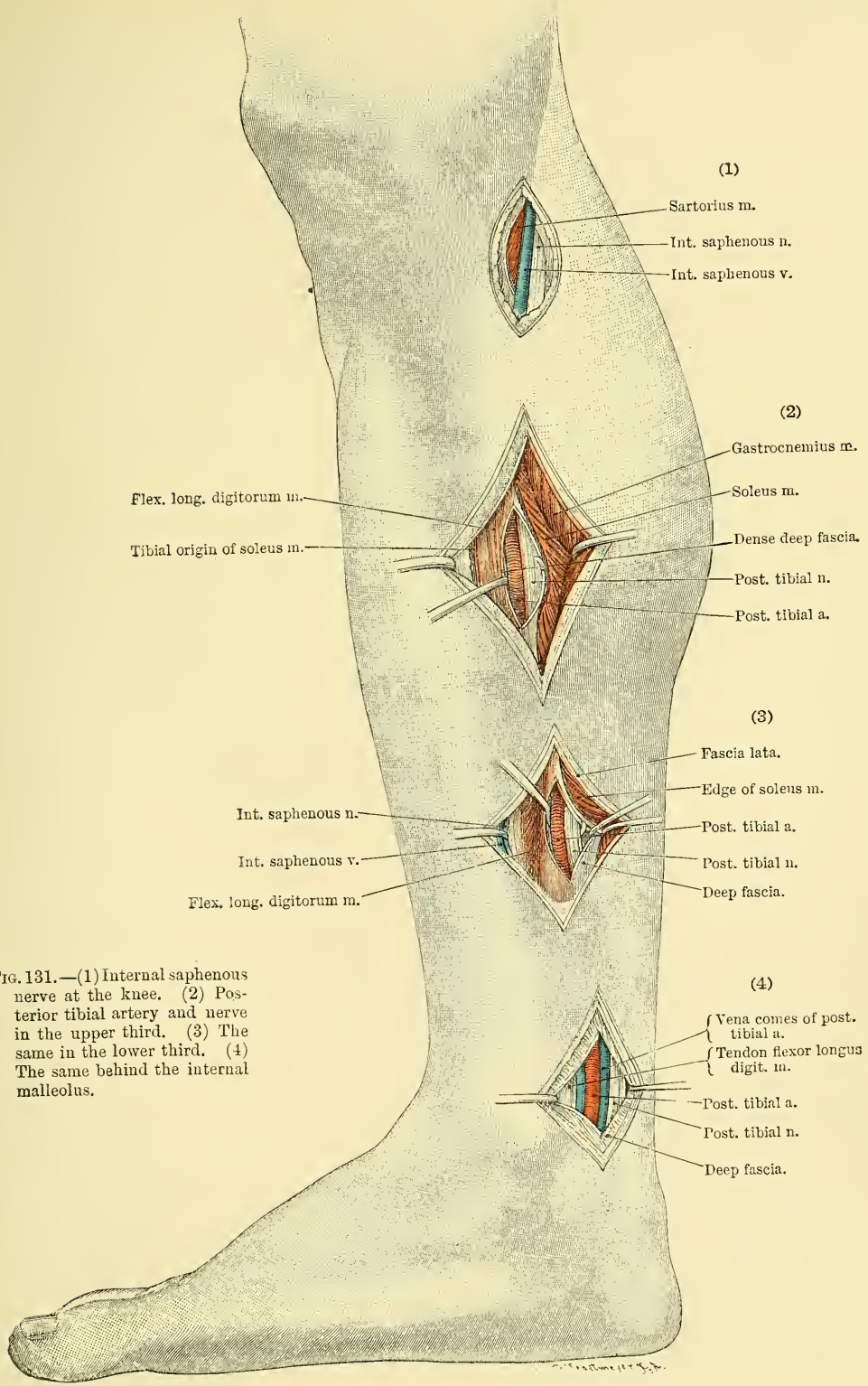

FIG. 131.—(1) Internal saphenous nerve at the knee. (2) Posterior tibial artery and nerve in the upper third. (3) The same in the lower third. (4) The same behind the internal malleolus.

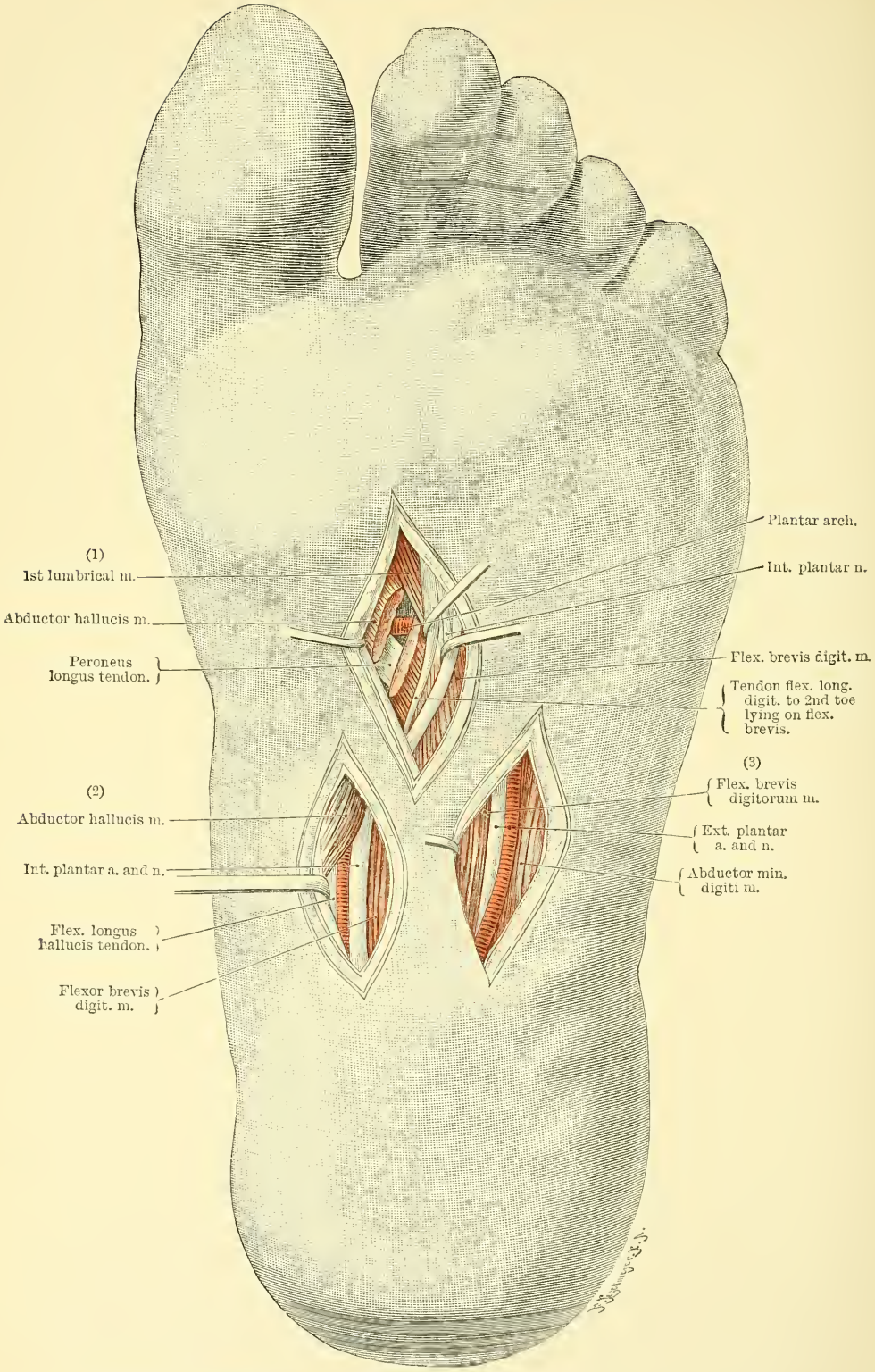

FIG. 132.—(1) Plantar arch. (2) and (3) Internal and external plantar artery and nerve.

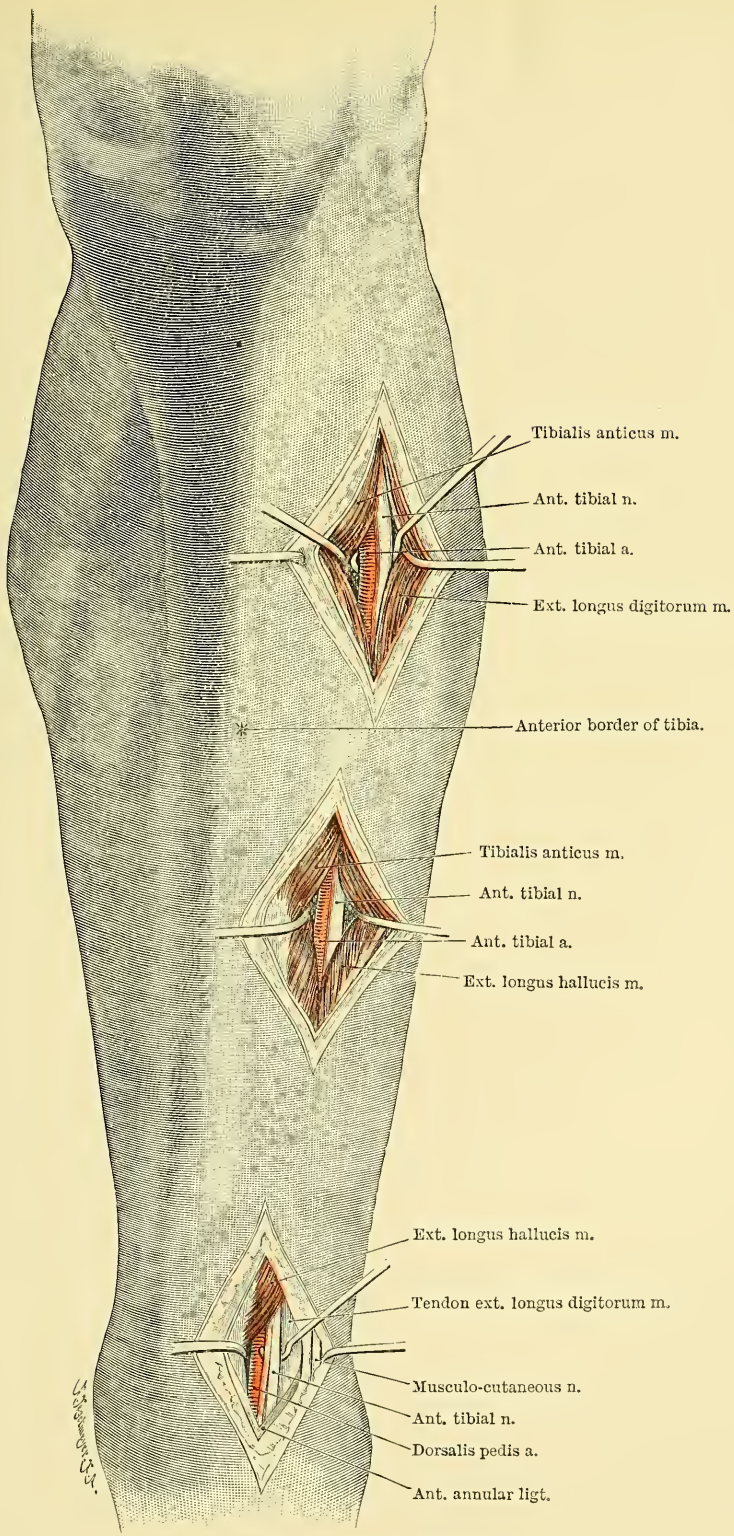

FIG. 133.—Anterior tibial artery and nerve.

In the sole. An incision is made in a line from the point of the heel to the great toe, beginning in front of the ball of the heel and extending forwards. The skin, a thick layer of fat, and the dense logitudinal fibres of the plantar fascia are divided. The muscular substance of the abductor hallucis is exposed, and the artery is found passing under it into the sole. The flexor brevis digitorum lies external to the artery.

The internal plantar nerve accompanies the artery, the latter being of smaller size, while both are covered with a thick layer of fat. The tendon of the flexor longus hallucis lies more deeply.

The nerve is distributed to both sides of the hallux, and of the second and third toes, and also the tibial side of the fourth toe on their plantar aspect.

(*c*) *External Plantar Nerve* (*vide* Fig. 132). Incision from immediately in front of the ball of the heel forwards in the direction of a line from the point of the heel to the fourth toe. On division of the skin, abundant fat, and the strong plantar fascia, the muscular fibres of the adjacent edges of the flexor brevis digitorum and abductor minimi digiti are exposed, and the artery is found lying between them.

The external plantar nerve lies beside the corresponding artery, the former being relatively much smaller than the latter.

(b) Peroneal Nerve (External Popliteal) with Branches. This nerve, which winds from behind forward round the neck of the fibula, is specially liable to injury, and radiating neuralgic pains are produced along its course.

Above and in the popliteal space. The trunk of the nerve can be felt and indeed seen behind the head of the fibula; it is still more distinct on the posterior surface of the external condyle of the femur.

An incision is made along the posterior edge of the tendon of the biceps, superiorly over the palpable prominence of the external condyle, inferiorly along a line extending upwards from the posterior border of the head of the fibula. The nerve lies immediately under the deep fascia at the outer edge of the gastrocnemius, and pierces the peroneus longus muscle below the head of the fibula.

The communicating peroneal nerve is given off from the external popliteal (Fig. 129) above the head of the fibula. This nerve may also be felt through the skin upon the external condyle of the femur.

The nerve is readily exposed behind the head of the fibula by dividing the deep fascia between the head of the fibula and the outer border of the gastrocnemius.

(*a*) *N. Cutaneus Surœ Lateralis* (*N. Communicans Fibularis*). The cutaneous branch to the outer side of the leg, which unites lower down with the n. communicans tibialis, can be felt through the skin on the posterior surface of the external condyle of the femur, and may be exposed in the popliteal space by the same incision as that for the peroneal nerve (*vide* Fig. 129).

(*b*) *The Peroneoùs Profundus* (*Anterior Tibial Nerve*). The anterior tibial nerve accompanies the anterior tibial artery on the interosseous ligament. Its relations above are, however, different.

The Anterior Tibial near its Commencement (Fig. 134). The incision extends downwards through skin and fascia from a point opposite the outermost part of the outer tuberosity of the tibia, a finger's-breadth in front of the head of the fibula. The intermuscular septum is indicated by a white line extending obliquely downwards and forwards, and the dissection is continued along it between the tendinous extensor longus digitorum and the peroneus longus. The anterior tibial nerve lies deeply in the above-mentioned septum, and passes obliquely downwards and inwards below the head of the fibula under cover of the extensor longus digitorum, whilst the musculo-cutaneous nerve extends vertically downwards along the same interval.

In its further course the anterior tibial nerve accompanies the anterior tibial artery in its entire length, and can be exposed by the same incisions. It lies to the outer side of the artery, except below, where it lies upon its anterior and inner aspect.

On the front of the leg. As the nerve here accompanies the artery in its whole length, it is exposed in the same manner as the artery (*q.v.*).

To expose the nerve on the dorsum of the foot, *vide* Fig. 135. It is distributed in the interspace between the first and second toes.

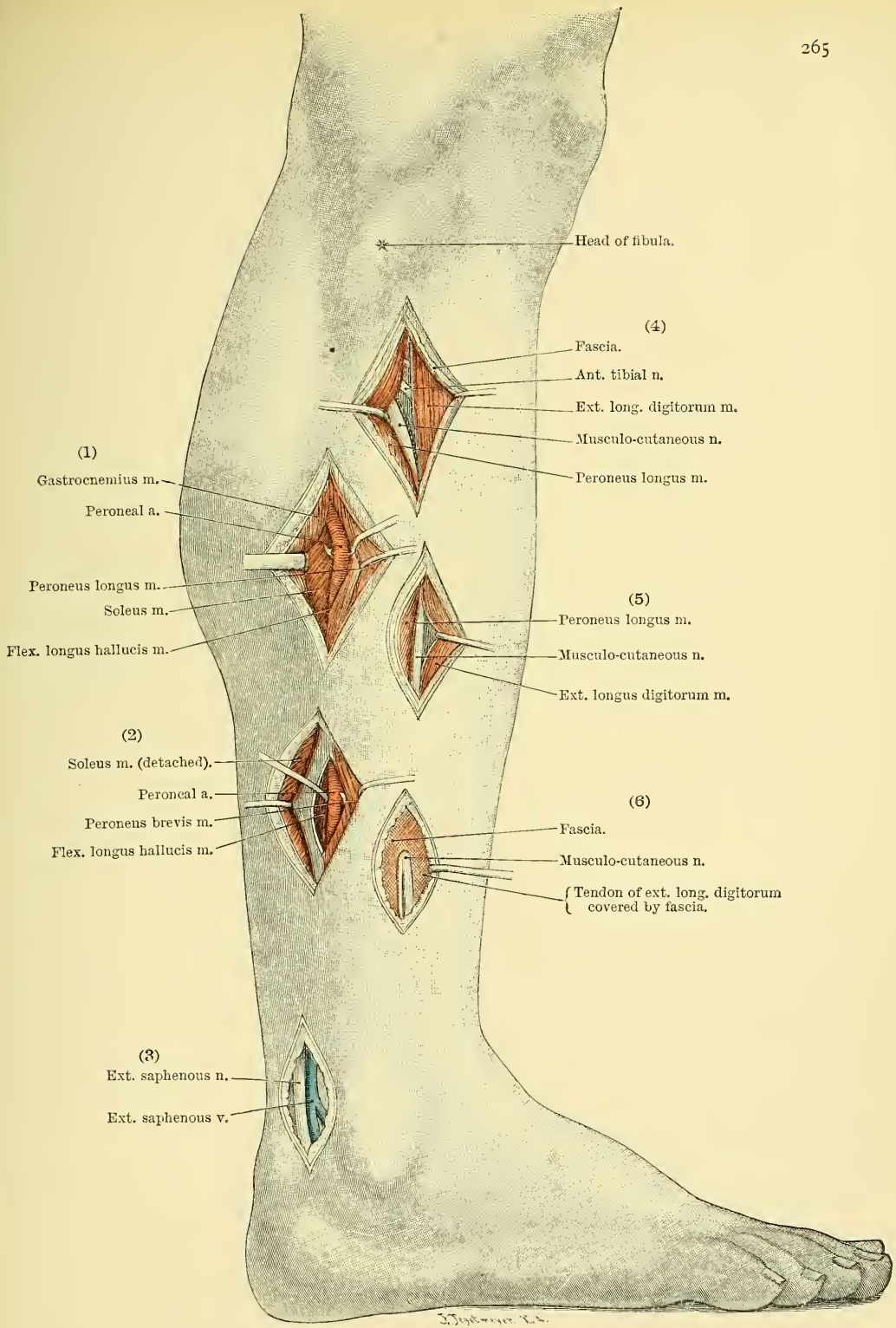

FIG. 134.—(1) Ligature of peroneal artery in its upper part. (2) The same in its lower part. (3) Exposure of external saphenous nerve. (4) Exposure of posterior tibial and musculo-cutaneous nerves below the external condyle of tibia. (5) Exposure of musculo-cutaneous nerve in the middle of the leg. (6) The same in the lower third, where it pierces the fascia.

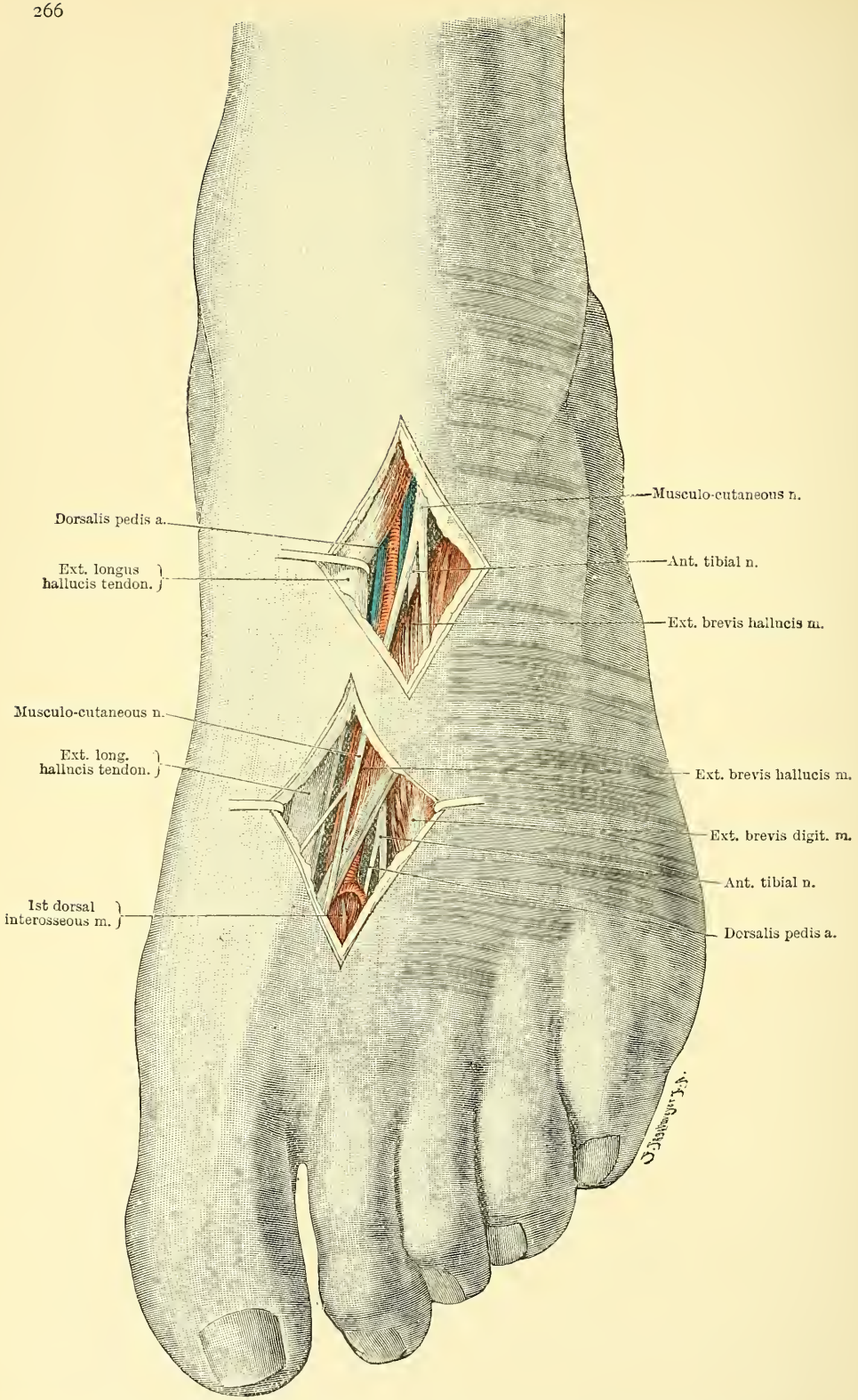

FIG. 135.—Dorsalis pedis artery, with anter or tibial and musculo-cutaneous nerves.

(*c*) *Musculo-cutaneous* (*N. Peroneus Superficialis*). *In front of the head of the fibula.* Compare exposure of the exterior popliteal nerve in front of the head of the fibula, Fig. 134.

On the outer side of the leg (Fig. 134).

In the middle third of the leg. Divide the skin and fascia along the anterior edge of the prominence of the peronei muscles (longus superiorly, brevis inferiorly), and pass in between these muscles and the extensor longus digitorum. On drawing the peroneal muscles outwards, we find the nerve at the bottom of the interspace, becoming more superficial as it descends.

The nerve pierces the fascia *at the junction of the middle and lower thirds of the leg*, where it may be exposed by an incision midway between the anterior border of the tibia and the posterior border of the fibula. The nerve can occasionally be felt through the skin in this situation.

On the dorsum of the foot. Here the nerve supplies all the toes except the adjacent sides of the first and second toes.

The musculo-cutaneous nerve is more superficial than the dorsalis pedis artery which lies underneath the deep fascia accompanied by the anterior tibial nerve.

(j) Pudendal Plexus

The pudendal plexus and its branches is important, in spite of its small size, as it furnishes motor and sensory supply for the perineum, bladder and urethra, rectum and vagina. Neuralgia is also not uncommon in the region supplied by its branches. The plexus is formed by the third sacral nerve with communications from all the other sacral nerves.

(*a*) *The Pudic Nerve.* This is the largest nerve of the plexus, and is occasionally of operative interest. Tavel has made a detailed study of its surgical treatment.

Professor Strasser, who has made careful investigation of its distribution describes the pudic nerve (with the artery) as enclosed in a sheath of fascia (Alcock's canal) which is derived from the fascia covering the obturator internus, and which lies a finger's-breadth below the junction of the obturator fascia with that of the lower part of fascia covering the levator ani at the upper limit of the ischio-rectal fossa.

It is very important that the twigs innervating the anus should be differentiated from the other fibres of the internal pudic, because if they are divided, incontinence is apt to result. Hence, if the nerve is divided on account of neuralgic pain, or spasm in the perineum, the pudenda (vaginismus), urethra, or neck of the bladder, the division must be made below the point at which these nerves are given off.

In the buttock. The dissection to expose the nerve at the point where it emerges from the lower part of the great sacro-sciatic notch along with the sciatic artery, is the same as that described for ligature of the internal pudic artery. It lies on the posterior surface of the ischial spine internal to the sciatic artery and in close relation to the internal pudic artery along with which it again enters the pelvis through the small sacro-sciatic notch.

In the perineum. Hitherto stretching and division of the internal pudic have been confined to the portion of the nerve in the perineum, as we possess other methods of treatment for spasm of the sphincter ani which involve less risk of incontinence. According to Tavel, it was first successfully performed by Simpson in 1861 for vaginismus, and by Albertin and Rochet for cystalgia and painful urethro-cystitis.

Before entering the perineum the pudic nerve gives off the inferior hæmorrhoidal to the lower end of the rectum. Dividing (or stretching) the nerve therefore only affects the branches to the perineum, vagina, urethra, and genitals (perineal and dorsalis penis nerves). Tavel points out that the deep part of the perineal gives off a recurrent branch to the sphincter, which should not be injured.

It is advisable to follow Tavel's suggestion and first expose the nerves in the perineum, after which they are laid across Kocher's dissector and tested, branch by branch, by mechanical stimulation in order to observe the muscles which they supply

(sphincter ani, transversus perinei superficialis and profundus, sphincter vaginæ, sphincter urethræ, ischio-cavernosus, and bulbo-cavernosus muscles).

The inferior hæmorrhoidal nerve supplies the skin behind the anus, the perineal nerve, the skin in front of the anus, the perineum, posterior portions of scrotum and labia, the labia minora, vulva, and the vaginal and urethral mucous membrane. The dorsalis penis (clitoridis) supplies the penis and clitoris, and to some extent the labia minora.

In the lithotomy position, an incision is made in the sagittal direction along the inner border of the tuber ischii (Tavel's incision is 8 to 10 cm. long midway between the tuber ischii and the anus) dividing skin and subcutaneous fat. The origin of the ischio-cavernosus muscle from the anterior part of the tuber ischii is exposed, and behind it the less distinct superficial transverse perineal muscle. The two divisions of the nerve are found passing forwards from under the great sacro-sciatic ligament. The upper, *i.e.* deeper, branch (measuring from the skin) passes forwards under cover of the transversus perinei muscle, and may be divided. Of the branches which are superficial to the transversus perinei, those going to the labia must often be torn across; their course can easily be recognised by putting the nerve on the stretch. The artery can be felt on the inner surface of the obturator internus and after the fascia has been opened the nerves which are superficial to the vessel can be raised with a dissector. As advised by Tavel and the author, the affected branches can then be twisted on artery forceps from the periphery and torn out by Thiersch's method.

(k) Coccygeal Plexus

Neuralgia of the plexus, coccydinia, may require surgical interference.

The plexus, which is mainly formed by the fifth sacral and the coccygeal nerves, is placed on the front of the origin of the coccygeus muscle, through (or below) which the lowest sensory nerves supplying the region of the coccyx are given off.

46. Ano-coccygeal Nerves. Neuralgia of these nerves is cured by excising the coccyx, as this procedure insures their division.

(l) Sympathetic Cord

Recently endeavours have been made to obtain information regarding the function of the sympathetic nerve by operative measures and to influence pathological conditions by its removal, without possessing adequate knowledge of the physiological effects of interference with the nerve.

The cervical sympathetic has been dealt with surgically in the hope that epilepsy, Basedow's disease, and trigeminal neuralgia might be cured by its total or partial excision. These hopes have been so little fulfilled that it does not seem justifiable to perform a complete excision of the cervical sympathetic, and thus destroy at one stroke all the vasomotor nerves of the head and neck, the sympathetic nerves to the eye, and the three cardiac nerves (superior, middle, and inferior, from the corresponding cervical sympathetic ganglia), without having an exact knowledge of the consequent injurious effects of such a procedure.

Till its effects are better known we refrain from describing total excision, and are satisfied with consideration of excision of the superior cervical ganglion or division of the nerves which ascend from it (carotid and jugular sympathetic), since we have demonstrated that the latter measure exerts a favourable influence on exophthalmos and trigeminal neuralgia.

47. Division of the Cervical Sympathetic above the Superior Cervical Ganglion. The neck being fully extended, an incision is carried downwards through skin and fascia from the tip of the mastoid process, the great auricular nerve and the external jugular vein being retracted or divided, and the anterior border of the sterno-mastoid muscle exposed and hooked backwards. The prominent internal jugular vein is freed posteriorly, and the vagus nerve is recognised from its position between the

vein and the carotid artery, the latter lying farther forward and at a deeper level. Care must be taken not to draw the sympathetic forward along with the vessels.

By dissecting deeply on to the anterior surface of the vertebræ in front of the origin of the levator anguli scapulæ and scalene muscles, the characteristic greyish spindle-shaped ganglion, which measures about 2 cm. in length, and which extends from the second to the fourth transverse process, is exposed lying on the prevertebral fascia and muscles. Its cephalic branches, which are mainly associated with the internal carotid, are given off the upper end of the ganglion, and may be raised on a hook and divided.

The twigs to the external carotid and its branches, as well as those to the larynx (and pharynx), and also the superior cardiac nerves, arise from the lower end of the ganglion, and must not be injured. After a few hours, slight ptosis, contraction of the pupil, and swelling of the cheek are distinctly observable.

SECTION IV

SURGERY OF THE EXTREMITIES

(a) General

The surgery of the extremities has been partially considered in the previous sections on the exposure of vessels and nerves. The remaining portion of the subject will be treated in a separate section. It may be stated that this branch of surgery is one which can be best practised on the cadaver as a regular course.

It is a field suited to the work of the practitioner, because the operations can be performed without bleeding, expert assistance is not necessary, and local anæsthesia is generally sufficient. It would be unfortunate if this branch of surgery were to be wrested from the practitioner by the specialist.

Surgery of the extremities is no longer limited, as it was till a comparatively recent date, to the ligature of vessels, to excisions and amputations and to the mechanical correction of curvatures. Its range has been greatly extended, and practitioners have even yet to realise fully the advantages of operative interference in certain types of cases.

We no longer confine ourselves to ligature of a vessel for the arrest or prevention of hæmorrhage, for the treatment of an aneurysm, etc., as vessels are now ligatured to improve the flow of blood in a limb (in cases of lymphatic elephantiasis, and varix), and to prevent the dangers of embolism (a proximal ligature or by incision of the vessel and removal of the thrombus); while suture is undertaken in the case of lateral injuries and in the excision of an aneurysm. One even goes the length of transplanting vessels for existing defects (by inserting a portion of a vein into an artery) when the continuity cannot be repaired by the method devised by Payr—the insertion of a magnesium tube. Further, one does not hesitate in cases where gangrene is imminent after severe arterial lesions to completely reverse the circulation (Carel and Guthrie).

The peripheral nerves now possess a surgical importance of their own. It is acknowledged that it is a mistake not to reunite a divided nerve as quickly as possible by suture, and yet this treatment is not invariably adopted. One trusts too much, especially when a nerve has been crushed or torn, to the comfortable policy of *laissez-aller* to remove subsequent thickenings and adhesions.

It was not only the question of nerve suture that led us to consider each individual nerve, but the knowledge that a thorough acquaintance with the course of even the smaller nerves is essential, if the fullest advantages to be derived from local anæsthesia are to be obtained. "Conduction" anæsthesia (Braun) ought to be more extensively utilised than has hitherto been the case, and doubtless it will be more generally adopted when practitioners make themselves more familiar with the anatomical course of the nerve-trunks.

The treatment of tetanus by exposure and blocking of the nerve-trunks has already

produced excellent results, and it is becoming more manifest that the poison of tetanus reaches the central nervous system through the peripheral axis cylinders, and that it can be arrested by dividing or blocking the nerves.

Further, ever since the first edition of this work was published, we have endeavoured to show how the deeper tissues can be extensively exposed without causing injury to the nerves. The normal incisions which we instituted have since that time been greatly extended (Küstner's and Pfannenstiel's abdominal incisions) so that it is now possible to divide tissues freely without producing the slightest permanent injury.

Cushing has recently drawn attention to the importance of accurate suturing of wounds so that the nerve-ends are brought into contact when their division has proved unavoidable, because, depending perhaps on some chemotactic process, there is a tendency for the central end to send processes to unite with the motor end organ in the peripheral portion, as soon as some degree of contact is restored (even without direct suture).

Cushing mentions as an example the regeneration of cutaneous branches and of the spinal accessory nerve after extensive removal of glands in the neck that follows accurate closure of the wound, arrest of hæmorrhage and asepsis.

(b) On Nerve-anastomosis, Nerve-transplantation, and Nerve-grafting

In the foregoing chapter we have already considered the question of nerve-anastomosis, nerve-transplantation, and nerve-grafting in connection with the surgery of the facial nerve. Numerous authorities have, however, observed that one cannot assume when the peripheral and central ends of a nerve are united that corresponding nerve-fibres reunite, and that on this supposition the union of nerve-ends which do not belong to each other is necessarily forced upon us. Experiment has shown that the central nerve organ after some months again sends undiminished nerve impulses into the corresponding peripheral portion of nerve, as well as into a nerve that has been grafted (*i.e.* to absolutely strange end organs).

The attempt has already been made by surgeons with special experience and enterprise in this field, to undertake anastomoses with healthy nerves in suitable cases of infantile paralysis.

In a case of partial paralysis of all four extremities due to poliomyelitis anterior acuta, Cushing divided the spinal accessory and implanted the proximal end into the fifth root, which was the one chiefly affected. Langley and Anderson successfully united preganglionic fibres of the sympathetic in the neck with the peripheral ends of the recurrent laryngeal, phrenic, and spinal accessory.

(c) Surgery of Muscles

The surgery of muscles and tendons deserves special notice. It should be a rule during all operations to avoid as much as possible division of muscles, because in muscle more than in any other tissue necrosis of the cut surface is more likely to occur, and because healing only takes place by the formation of connective tissue, *i.e.* an artificial tendinous inscription. It is of further importance to guard against atrophy occurring by avoiding injury to the motor nerve, a point which has been specially considered in our remarks on normal incisions.

One can best avoid injury to muscles by using either intermuscular or, in the case of broad muscles where this cannot be performed, permuscular incisions in the direction of the fibres, and in this connection we would draw attention to the method of opening the abdomen employed in operations on the appendix (*vide infra*). Here the layers of the abdominal wall are split (not divided) in the direction of their fibres and the lines of division of the layers cross each other in three directions.

When a muscle has to be divided at right angles to the direction of its fibres, it is very important not to leave a peripheral portion which can undergo atrophy,

i.e. the muscle should be divided as far as possible away from the point of entrance of its nerve. In many incisions that are advocated little attention is paid to this point, *e.g.* in laparotomy many surgeons do not hesitate to employ vertical incisions, especially at the outer border of the rectus, quite regardless of the fact that the nerves pass obliquely downwards and inwards. When a larger incision is required, much less harm is done, and less subsequent disturbance of function results if the rectus is cut right across, than by employing a vertical incision which inevitably divides its nerves of supply.

In the neck we have illustrated the incisions which should be employed for the removal of extensive tumours. Here, again, they show how a large muscle like the sterno-mastoid may be cut across without any subsequent harm, if the division is made at a distance from the point of entrance of its nerve.

The same holds good in myotomy for the relief of spasm, and we refer the reader to the description of the operation for spasmodic torticollis (p. 443). By separating its attachment from a bone a muscle may be thrown out of use, and the spasm effectively cured, without the necessity of producing definite atrophy.

Muscle-transplantation is as a rule effected by transplantation of its tendon, *i.e.* a new insertion for the tendon is provided and the function of the muscle is altered without actually displacing the muscle itself.

Transposition of the fleshy part of a muscle is limited practically to the broad muscles of the abdomen and occasionally of the neck. In the case of inguinal and ventral herniæ, instead of the employment of simple fascial sutures, the muscles may be slid over one another. After the peritoneum and deep fasciæ have been united up, the broad abdominal muscles and also the rectus are slid over the line of sutures and fixed with stitches. Muscles capable of contraction furnish a strong protection against hernia.

In the neck we have on several occasions had to undertake transplantations for cosmetic reasons after a previous operation had left a depressed scar. The latter, especially when situated immediately below the lower jaw, can only be cured by careful suture of the platysma after excising the cicatrix. Very satisfactory results as regards appearance can thus be obtained. It is important, therefore, to unite the platysma separately in all those cases.

(d) Surgery of Tendons

Far greater importance is now attached to the surgery of tendons (tenoplasty) than to the surgery of muscles. It is remarkable what can be accomplished since the introduction of asepsis in the way of dividing and displacing tendons without the risk of necrosis. Formerly one had to be content with a subcutaneous tenotomy, but we are now in a position to obtain any desired amount of elongation without trusting to nature's methods.

Let us take as an example the tendo Achillis, the tendon which one is most commonly called upon to lengthen. Instead of simply cutting it across, we divide it in a Z-shaped manner (Bayer's incision, according to Vulpius), the distance between the two horizontal limbs of the Z corresponding to the amount of lengthening required. The two ends of the tendon are then accurately united by sutures (*vide* Fig. 136).

In regard to the method of suturing the ends of the tendon, we have always found ordinary simple stitches sufficient, provided the needle is inserted at a little distance from the cut edge and that there is no tension. The absence of tension is of much more importance than the actual variety of stitch employed. If tension cannot be avoided, the Wilms-Siever stitch will be found very serviceable. In this form of suture the ends of the tendon are first approximated and are held in position by stitches inserted as in Fig. 137.[1] According to Siever, a strain of 5 kilos (11 lbs.)

[1] Taken from Wilms-Siever's article in the *Centralbl. f. Chir.* Bd. 40, 1905.

can be borne for several days, and active movements can be begun at an early stage without risk, a point to which great importance must be attached.

While we must be careful to avoid any tension, there is no necessity to rush to the other extreme and elongate a tendon unnecessarily. If the amount of elongation is accurately gauged, the function of the muscle is quickly restored, in contrast

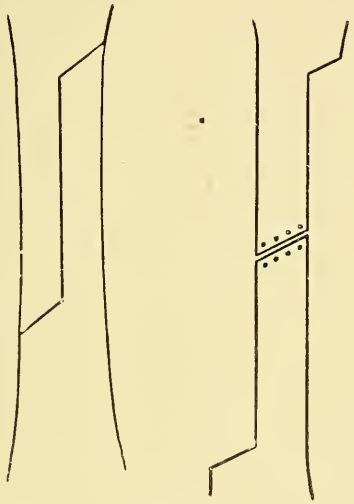

FIG. 136.

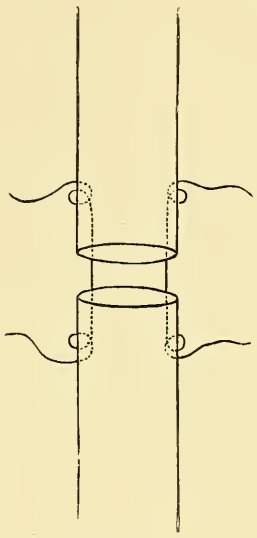

FIG. 137.

to the results obtained after simple tenotomy. We no longer employ rigid dressings in the case of tendo-Achillis, as slight movements produce no harm, and active movements may be permitted with advantage after the first week.

Figs. 136 and 137 illustrate the method of dividing and the method of reuniting the tendon. To expose the tendo-Achillis, a long posterior incision is made. It is then split longitudinally into two lateral halves, which are cut obliquely above and below (by cutting obliquely one gets broader surfaces to suture).

If it is split in the frontal (coronal) plane, the results are not so satisfactory as the split tendon is only half as thick. To attempt the operation subcutaneously entails worse results from inaccuracy.

Besides the tendo-Achillis, contractures in other situations, *e.g.* the forearm, may be successfully dealt with by lengthening one group of tendons and shortening the other, either by excision of portions of the tendons (oblique section) or by simple plication, the latter method, however, proving less satisfactory.

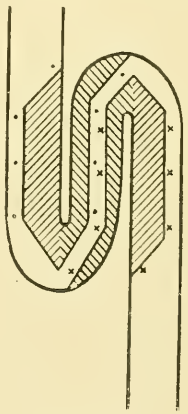

FIG. 138.

To shorten a tendon, the redundant portion may either be simply excised by means of two parallel oblique incisions, and the edges united end to end with fine sutures, or the tendon may be shortened by plication. In the latter case, care must be taken to avoid leaving any thickening which would interfere with the mobility of the tendon. According to Hoffa and Borst, thickening of a tendon interferes considerably with the function, as, for example, in "trigger" finger. It can be avoided by excising portions of the tendon in the manner shown in Fig. 138, where the three layers of tendon are reduced to one-third their diameter. By the inclusion of the three adjacent surfaces in the sutures, firm union is obtained and the thickness of the tendon is not interfered with.

Tendon shortening and elongation give excellent results in spastic cases (cerebral palsy of infants), in Little's disease, and in spastic and paralytic conditions from other causes.

Equally good results are also obtained by transplanting and grafting operations, especially in the case of poliomyelitis anterior acuta, where only individual muscles or groups of muscles are paralysed.

The essential feature of such operations consists in dividing the tendon of an active muscle as close to its insertion as possible, and grafting its upper portion either laterally into a slit in the tendon of the paralysed (or weak) muscle, or dividing the latter tendon and joining them end to end.

Here also the grafted tendon must exert the right degree of tension so that the desired effect may be produced when the muscle contracts. This is best illustrated by an example.

Let us suppose a case in which the invertors of the foot are paralysed while the evertors are normal, the foot occupying the valgus position. The object here is to bring the foot into active inversion and to support and raise the sunken inner side of the foot. The tibialis posticus tendon (as well as the flexor tendons) is first exposed by an incision below the internal malleolus and the sheath is opened. Similarly the peronei tendons are both exposed and their sheath is opened behind the external malleolus. By following them down to the outer border of the foot, the peroneus longus is identified and cut across as low down as possible.

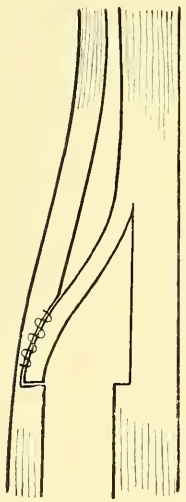

Fig. 139.

The upper end of the latter tendon is separated up to the point where it fuses with the muscular tissue, and is pushed with a long slender pair of catch forceps through to the inner side between the tibia and fibula and the deep muscles, where it is pulled out through the incision for exposing the tibialis posticus. Instead of unduly prolonging the latter incision to attain this, it is better to make a separate small wound through which the tendon is pulled. The foot is then placed in correct position, *i.e.* in the position of normal inversion and at right angles. The tendon of the peroneus longus is pulled upon until a slight amount of tension is produced, and is applied to the tendon of the tibialis posticus, the latter being now only cut across or slit in order to make the anastomosis. If asepsis can be guaranteed it is better to cut the tendons across and unite the two ends with fine sutures, the wound being then stitched up without drainage. The dressings and bandages must retain the foot in proper position for one or two weeks so as to avoid any passive strain on the sutures.

It is very rarely that one has to transplant tendons or muscles which have the same action, for they generally replace each other in time without any operative interference being required. One has more frequently to transplant tendons which are antagonistic in action, and whenever possible we prefer to select those that are doubly represented, *e.g.* one of the two peronei. The results obtained by splitting a normal tendon and uniting only one half into the paralysed muscle are not so satisfactory, and in consequence the operation is rarely performed.

We maintain, in opposition to Vulpius, who insists on a plaster bandage being worn for at least six weeks and then relieves the resulting stiffness by massage, baths, and electricity, that if fine silk has been used as the suture material, active movements should be begun in the course of a week or fortnight. Good stitches of fine silk keep the ends of the tendons together so securely that there is absolutely no need to fear over-stretching of the young tendinous cicatrix.

Equally excellent results are obtained in the case of the hand by tendon anastomoses of this type, and after a few months or years marked improvement or complete restoration of function may be expected.

In the case of a large joint such as the knee an efficient substitute for the powerful quadriceps extensor can be obtained by transplantation of the sartorius, semitendinosus and biceps tendons. Here there is no separate tendon into which the active muscles can be grafted, and one has to fall back upon the fixed point afforded by the insertion of the quadriceps into the patella, *i.e.* the proximal end of the active tendon is inserted into the periosteum and fascia covering the lateral edges of the patella (modified Lange's method). Even contractions at the knee may be permanently relieved according to Codivilla and Heussner by transplanting the flexor tendons into the extensor apparatus.

(e) Surgery of Articular Ligaments

We would merely observe in connection with the ligaments, that the treatment especially of traumatic lesions of joints, should be much more active than it is at the present time. A large number of cases of so-called chronic arthritis might be prevented were the torn ligaments promptly sutured and the loose cartilages removed. Ligaments heal comparatively well, and if persistent interference with movement after injury to a joint is to be prevented, conditions must be established which promote the earliest restoration of movement. Suture is a means to this end, if one knows how to open into the joint without causing damage to its function. The methods of performing arthrotomy are considered in the following chapters.

If operation is carried out promptly one often discovers far more serious lesions than the clinical evidence would suggest, lesions which would readily explain any subsequent and persistent limitation of function. In the elbow-joint in cases of supposed simple sprain (distortion) we have observed complete transverse rupture of the anterior ligament occasionally with separation of the internal condyle (the early stage of a posterior dislocation of the elbow) when the case would otherwise have been regarded as a simple sprain.

In dividing an articular ligament it is preferable to detach it along with a layer of bone, so that solid union will more easily occur. Thus, in old-standing fractures of the patella, v. Bergmann has advised separation of the tubercle of the tibia as a preliminary to wiring the patella.

Similarly, in many cases of arthrotomy, it is advisable to separate the superficial bony attachments of the capsule and ligaments rather than to divide them transversely.

(f) Surgery of Bones

The operative treatment of bones differs according as to whether the formation of new bone is, or is not, desired. The bone marrow, which is so essential a factor in hæmogenesis, may be regarded merely in the light of a foreign body enclosed in a strong bony shell. When it is inflamed or is the seat of a suppurative process it may be entirely removed without causing the least damage to the bone (this applies to the diaphysis).

The formation of new bone proceeds from the periosteum and the superficial osteoplastic layers. These layers must be carefully preserved if new bone is to develop, *e.g.* in many cases of osteotomy, resections of joints, and in certain disarticulations.

Ollier has shown that the regenerative process is to a considerable extent influenced by the manner in which the periosteum is detached. If a blunt elevator is employed for the purpose, practically nothing except the elastic tissue of the periosteum is detached. With the knife, on the other hand, numerous uninjured bone-forming elements are preserved along with the periosteum. With the sharp periosteum elevator (rugine, raspatory) the two bone-forming elements of the inner layer of the periosteum are raised intact, viz. the osteogenetic layer and the superficial bony lamella on its inner surface.

In amputations, on the other hand, new bone formation is as a rule to be avoided, for it has been shown that the stump then retains in a greater degree its original form. (Our assistant, Dr. v. Steiger, has published for us a large number of examples proving this point.) Hence as we shall see in the chapter on amputations, the best stumps are obtained by non-osteoplastic methods.

The question of a substitute for the marrow is of no little importance when the marrow has been removed or when cavities in the bone have been left which will take a considerable time to fill up. After earlier attempts, Mosetig and Moorhof have produced their iodoform bone-filling which has proved the best material for the purpose. It consists of 60 parts of finely powdered iodoform and 40 parts each of spermaceti and sesame oil, the melting-point of the mixture being 50° C. It is shaken up before use and is poured in a fluid state into the cavity, after all the bleeding has been completely stopped, and the cavity has been dried out with an electric hot-air apparatus or a sterile dry cold-air bellows. The cavity must be absolutely clean. Silbermark has shown that the filling slowly becomes replaced by bone tissues which grow from the periosteum and marrow. Mosetig has similarly filled up cavities left in the soft parts, particularly after resections of a joint. In the bone cases, in which he used the filling with success, the cavities were chiefly the results of chronic and tubercular osteomyelitis.

A. ARTHROTOMY, OSTEOTOMY, AND RESECTION

(a) Technique in General

The term "resection," which is used chiefly in connection with surgery of the joints, implies the removal of an intermediate portion of a limb, as distinct from amputation, where a terminal portion is removed. As a resection necessitates the employment of special incisions to expose the joint or bone, arthrotomy and osteotomy must first be the subject of consideration, although they actually comprise only part of a resection.

To Langenbeck belongs the credit of having called attention to a very important point in the excision of a joint or bone, viz. that the incision through the soft parts should be as simple as possible, and that in cleaning the bones we should retain them in their normal continuity with the periosteum. And Ollier must be recognised as having shown, by his experiments and by the excellent results of his operations, the significance of carefully preserving the periosteum in its continuity with the attachments of the capsule, ligaments, and tendons. But, nevertheless, it does not seem to us to be consistent with the spirit in which these masters worked to adhere strictly to their methods. All that is necessary is to adhere to the principles which we owe to their labours and to their genius.

We agree with König in his opinion that the day for typical resections is past, and that arthrotomy and osteotomy, with removal of nothing but the diseased soft parts and bone, should replace the stereotyped excisions that were formerly the rule. Kappeler has applied the term "Atypical" to such resections, but the name conveys an undue impression that there is some irregularity in the methods of performing these operations, whereas most exact rules are prescribed. We consider we have made a still further improvement by selecting for all joint incisions those methods which are specially devised to cause as little injury to the soft parts as possible, and which preserve also the nerve-supply of the muscles by preserving the smaller branches. We must keep in mind the importance of individual muscles and their insertions for the function of the joint. From this point of view some of our methods may well deserve preference.

Lastly, there has been a distinct advance in the mode of preserving the attach-

ments of the ligaments and tendons. König and Tiling introduced the admirable plan of chiselling off these structures along with the bony process or shell of cortical bone to which they are attached. We have to endeavour to spare the cortex of the bone not only for the sake of the epiphysis, but also to save as much of the periosteum as possible, so that now we separate the periosteum along with a superficial layer of bone with a sharp raspatory like the "Rugine" used by Ollier in order to ensure a better preservation of the germinal layer of the periosteum. The preservation of a thin layer of bone leads to more new formation of bone than when the periosteum alone is separated, as is proved by Ollier's researches (see Introduction). We therefore consider that, when it can be conveniently done, the subcortical method of resection is better than Langenbeck's subperiosteal method, or than Ollier's subperiosteo-subcapsular method; and it may also be pointed out that union occurs more rapidly, and attempts at movement may be made sooner, as tendinous and ligamentous attachments are specially sensitive, and therefore delay the early resumption of active movement which is so important to the production of a good functional result.

The modern method for arthrotomy, osteotomy, and typical excisions which is most to be recommended seems to us to be the following:—

(1) To employ as simple an incision as possible (Langenbeck), care being taken to place it in the intervals not merely between the muscles, ligaments, and tendons, but also the smallest vessels and nerves, and in addition to make use of the neutral zones between the muscles supplied by different nerves.

(2) To detach subcortically the capsule, the periosteum, and the ligamentous and tendinous attachments, and to remove all the diseased bone and diseased soft tissues of the joint but only as much of the articular surfaces and healthy adjacent bone as is necessary in order to obtain a better functional result.

The method employed to open a joint and expose a bone should in no way bind the surgeon as to what his next action is to be. The incision should be equally suited for cases where, after the opening of the joint, nothing further needs to be done, or where part or all of the synovial membrane, or the articular ends of the bones, need to be removed. The first incision remains the same. For all the large joints we have come to employ one type of incision which may be termed the "hooked incision," and which will be described under the individual operations in a subsequent chapter.

The following varieties of operations on joints can be differentiated:—

(1) In arthrotomy, for example, in evacuating an effusion, or in removing a loose body, the incision is carried into the joint cavity through skin, aponeurosis, capsule, and synovial membrane.

(2) In performing arthrectomy the incision is only carried down to the diseased and thickened synovial membrane, which is generally tubercular, and the fibrous capsule is stripped off it, so that the synovial membrane, like a tumour, can be removed in one mass after detaching the visceral layer from the bone as far as the cartilage and removing the underlying tubercular granulations.

(3) In osteoarthrotomy the incision is made right down through the periosteum, the soft parts being then separated subcortically in one flap, and the bone removed in the same way as one shells out a simple tumour.

(4) In osteoarthrectomy, which is a combination of arthrectomy and osteoarthrotomy, the capsule is exposed and entirely cut away, but in addition to this the articular ends of the bones are removed.

Another point to which special attention must be directed is the best method of obtaining a good functional result. Two fundamental conditions are necessary. The first is the preservation of muscles which have the power of contracting, an important point, and one which surgeons often lose sight of in the course of operations. No form of treatment is so injurious as the fatal expectant treatment by which, through want of use, the muscles become atrophied, and the soft tissues dense and inelastic from inflammatory changes. The second point is the formation of a joint in which the ends of the bones are well shaped. How can one expect to

obtain proper movement between the ends of two bones if they are simply sawn straight across, as was formerly the practice? One must, on the contrary, carefully imitate the form of the articular ends in order to provide for the mechanical requirements of certain forms of movement.

(b) Indications and Contraindications

If attention be paid to these points, with strict aseptic precautions, arthrotomy can be undertaken with manifest benefit in the early stages of joint disease, which would otherwise become more serious. Whatever statistics may be brought forward at the present time, even in connection with tubercular inflammations of joints, early and complete exposure of the joint, with thorough removal of the tubercular tissues, combined with the rubbing in of iodoform, is the only means of obtaining a rapid and permanent cure.

It is by no means uncommon to find a caseous focus or sequestrum in the articular end of a bone during the earliest stage of tuberculous disease of the joint, when the main extent of the cartilaginous surfaces are still quite smooth, a focus which would have rendered recovery by conservative measures impossible. The existence of such a focus can only be determined by freely incising the joint, although fortunately in radiography we have now an aid most valuable in the diagnosis.

When we consider the distressing and tedious course that follows non-operative treatment in the various types of simple plastic arthritis and in the proliferative, deformative, and adhesive forms, modern surgery is still far too timid, only a few surgeons being distinctly in favour of arthrotomy. The reason of this timidity lies in the fact that the majority of operators persist in adhering to the older methods of excision. The incisions we suggest here are not intended merely for resections, but also for simply opening into a joint (arthrotomy), for excision of the joint-capsule, articular cartilage (arthrectomy), and also for partial osteotomy or osteo-arthrotomy.

It would be a mistake to recommend early arthrotomy, especially in tubercular cases, without alluding to the contraindications. These refer to the later stages, in which, according to some surgeons, operative interference is first indicated.

We again repeat: A well-executed resection is the only safe method by which a permanent and complete radical cure of a tuberculous joint can be obtained in a short space of time. We have never yet resected a joint "cured" by injection, even by the celebrated iodoform injection with or without prolonged fixation, without detecting tuberculous and caseous foci as well as cicatricial processes, often extensive, in the synovial membrane, in the dense tissues with which it is covered, or in the bone. It is all the more necessary to be familiar with the conditions which must be regarded as contraindications to these important operations.

Of the local conditions which may interfere with the success of a resection in a tuberculous case, mixed infection with suppuration and fistulæ is of the first consideration. In every case where there is a sinus, mixed infection (especially staphylococcal) is certain to be present. Resection is only to be recommended in cases in which one is sure of being able to remove all the diseased tissues together. The unfavourable statistics of resection in pre-antiseptic and semi-aseptic days attest the seriousness of the operation under these conditions.

If resection is to be undertaken, the sinus must, first of all, be opened up with the thermo-cautery and irrigated with very hot saline solution (42° C.). The exposed tissues must then be disinfected, a result which is most satisfactorily attained by means of the thermo-cautery. Where this method is not practicable the surfaces of the synovial membrane and of the bone should be swabbed over with 50-85 per cent alcohol, after which the resection can be performed under irrigation with very hot saline lotion. The after-treatment must then, without exception, be carried out by antiseptic packing and secondary suture.

The second great contraindication to resection is afforded by anything which may lead to the production of acute miliary tuberculosis. The latter condition occurs most

commonly in cases of general caseous suppurative inflammation of the joint, where the pus cannot be prevented from coming in contact with the fresh wound surfaces, especially if para- and peri-articular abscesses have to be dealt with simultaneously. Those individuals who show evidence of active tuberculosis in other organs are most susceptible, in which cases there is generally a rise of temperature shortly after the operation quite unconnected with the state of the wound, the pulse being accelerated, with some dyspnœa, a sense of heaviness, irritability, and a slight amount of albuminuria, while death may ensue from serous or tuberculous meningitis.

We might with advantage further mention among the contraindications two dangers associated with arthrotomy and resection, namely, the chance of paralysis from the use of Esmarch's tourniquet, and also the risk connected with spinal analgesia. Paralysis following the use of Esmarch's tourniquet is a by no means uncommon result of over-anxiety regarding the prevention of hæmorrhage. No doubt it is very agreeable to be unembarrassed by bleeding, to be able to determine the exact condition of the soft parts as well as the bone, and to remove deliberately all the disease, and also in the case of tuberculous individuals to avoid hæmorrhage. But great care must be taken to guard against causing paralysis, which is particularly apt to occur if the operation is of a prolonged nature, apart from application of the tourniquet too tightly or at an unsuitable position, *e.g.* the musculo-spiral nerve in the upper arm. Not long ago a case of complete paralysis of the arm after an operation lasting an hour and a half came under our notice, and the surgeon was completely nonplussed by the explanation of the resulting condition.

Esmarch's bandage has the further disadvantage that its use is frequently attended by subsequent hæmorrhage, which retards the healing of the wound even though it be only parenchymatous in its nature. If a tourniquet therefore is used, it must not be applied too soon and should be removed as early as possible, while in many cases its application can be dispensed with altogether.

Spinal analgesia which is frequently recommended for tuberculous disease in the lower extremity is not always free from adverse criticism. We regard Bier's spinal injections as unsuitable for tuberculous cases, and have on two occasions observed tuberculous meningitis follow a recourse to this method of producing anæsthesia. The slightest irritation of the meninges must always be avoided in these cases.

(c) After-Treatment

To obtain the most satisfactory results from arthrotomy the strictest asepsis must be maintained during, as well as after, the operation. The aversion that many surgeons have to opening tubercular joints is to a considerable extent due to inability to secure primary union.

We prefer to wear rubber gloves in operations on joints, although in other cases, *e.g.* in our thyroid operations, we dispense with their use. Notwithstanding the greatest care post-operative oozing cannot be avoided in these cases, and the growth of any organisms which may be introduced into the wound during the operation is thus facilitated.

Every precaution must therefore be taken to prevent decomposition of blood-clot in all cavities left in a bone or joint. This is attained (1) by rubbing in iodoform powder previously disinfected in sublimate lotion, or by filling the cavity with Mosetig's iodoform paste (*vide* Introduction to this section). (2) By preventing the occurrence of further hæmorrhage by fixing the parts in splints or plaster for the first eight days.

We employ plaster bandages very extensively, and always in joints such as the knee and ankle where ankylosis is the object in view after resection. If their application is difficult as in the hip and shoulder, weight extension will prove sufficient. In the case of the elbow and wrist, splints (especially the wire variety) may be used with advantage. The ends of the bones must be securely fixed in position, more especially in the case of the knee and ankle. This can be attained by making the cut end of the

femur convex or angled (Tavel) and the corresponding surface of the tibia concave. In the case of the ankle the tibia and malleoli are fitted in a similar manner into the astragalus or os calcis.

(3) By the thorough removal of wound secretions by employing drainage for a longer time than is necessary in other wounds, drainage tubes being often left in joints for eight days instead of twenty-four hours. This, however, introduces a risk of delayed infection. The drainage openings must therefore be well covered with antiseptic dressings so that decomposition of the blood in the dressings themselves may be prevented.

A thick layer of iodoform gauze, previously disinfected in 5 per cent carbolic lotion, forms the best dressing, and over it several layers of freshly-prepared corrosive sublimate gauze should be placed and changed at first every few hours and later two or three times a day.

In spite of this, drainage of blood from the raw ends of the bone is not always sufficiently complete, and the reparatory processes by which the ends of the bone are smoothed and on which the disappearance of tenderness depends, may be interfered with, while the resumption of movement is also delayed.

To obtain this result with rapidity we have frequently adopted a procedure which may be termed "the dislocation or secondary reposition method." In the elbow and hip, for example, after resecting the ends of the bones we bring them into a dislocated position, so that the sensitive sawn ends of the bones are merely in contact with the soft parts, and after ten to fourteen days, when the skin incision is quite healed, they can be easily replaced in proper position. The patient then begins at once to move the limb, which by the usual method he is quite unable to manage, in spite of every effort and desire. If a movable joint is required, as in the elbow and hip, it is essential, too, that the movements of the muscles should be commenced early, if the function of the joint is to be restored in a short space of time. By means of an apparatus provided with the means of elastic flexion and extension, while the axis of movement is maintained, the treatment is greatly assisted.

If one is sure that the joint cavity is thoroughly dry, and all the recesses have been filled with iodoform paste, the wound may be completely closed by stitching up the capsule, muscles, fascia and skin, primary union being readily obtained.

If arthrotomy or osteoarthrotomy is undertaken for arthrodesis (Albert) *i.e.* to ankylose a loose or flail joint, the joint must be efficiently immobilized from the beginning of the operation with rigid dressings even in the case of the shoulder, elbow, and hip.

With regard to the knee, wrist, or ankle, we do not generally aim in the first place at obtaining a movable joint, but prefer an attempt to secure good solid union, so that the mobility of the peripheral parts may be better maintained. This is of special importance in the case of the foot and still more in that of the hand. With the hand securely fixed on our dorsiflexed splint, the patient recovers the movements of the fingers in the shortest possible time.

After resection of the knee the patient may be allowed to leave his bed in a fortnight, the limb being immobilized in plaster of Paris in the fully extended position.

In regard to obtaining subsequent mobility of a joint mention must be made of the method of preventing adhesions by the interposition of a foreign body between the ends of the joint. A portion of the joint capsule, tendon, or muscle has been utilised for this purpose (the interposition operation).

Arthroplasty has recently been carefully investigated by Murphy,[1] who has come to the conclusion that in order to establish movement in a stiff joint, the best method is to detach and interpose a flap consisting of fascia, muscle, and a superficial layer of fat. For example, in the case of the knee, after the adhesions have been separated, a flap, the free border of which is directed upwards and the base below, is withdrawn from the fascia lata with a subjacent layer of the vastus externus muscle and a superficial layer of fat. The flap is rotated so that the condyles of the femur are covered, after which it is sutured in position. The same process may be repeated at the hip,

[1] *Journal of the Amer. Med. Assoc.*, May, June, 1905.

the results often proving very satisfactory. Hofmann (Graz) has interposed a layer of periosteum over the raw ends of the bone with equally good results. In ankylosis of the elbow-joint a portion of periosteum can be removed from the tibia and applied over the raw end of the bone.

(d) Operations on the Foot

1. Resection of the Phalanges and Metatarsal Bones. *Vide* Fig. 140.

2. Resection for Hallux Valgus. We have invariably obtained satisfactory results by chiselling off the inner half of the head of the first metatarsal bone, the projection which makes adduction of the toe an impossibility. An incision is made down to the head of the bone on the dorsal aspect, the joint capsule is opened, and the projecting portion of the head is chiselled off at the point where the curved articular surface joins the internal condyle of the metatarsal.

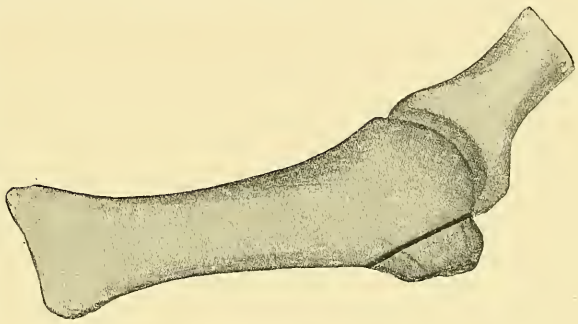

FIG. 140.

We can confirm Riedel's statement that the first metatarsal becomes curved, *i.e.* the anterior portion becomes adducted, owing to the pressure exerted by the outward displaced great toe. If, therefore, a wedge of bone is removed behind the head with its base on the inner aspect as is recommended by Reverdin, this adduction will become more marked.

3. Osteoarthrectomy at the Tarso-Metatarsal Joint and Anterior Tarsectomy. This is a very important operation in infective diseases (especially tuberculous) of the anterior tarsal joints, because the cavities of the majority of the joints are in communication with one another Separate synovial cavities are most frequently found at the joint between the first metatarsal and internal cuneiform, at the anterior and posterior surfaces of the cuboid, between the head of the astragalus and the scaphoid, and lastly between the astragalus and os calcis (Fig. 141). In tubercular ostitis, which frequently begins in the bases of the metatarsal bones, excision of the bases and of the articular surfaces of the adjacent cuneiforms and cuboid is occasionally sufficient (tarso-metatarsal resection). When, however, the tarso-metatarsal joints are involved, it is safer to excise the scaphoid as well as the bones above mentioned. If the disease is still more diffuse the articular surfaces of the astragalus and os calcis must also be removed.

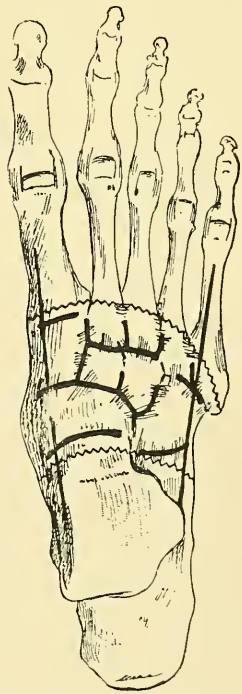

FIG. 141.—Excision of the anterior tarsus (usual arrangement of the synovial cavities).

The excision is performed by means of two dorso-lateral incisions (Fig. 141). The internal incision extends from the posterior third of the first metatarsal backwards as far as the inner aspect of the head of the astragalus, which is brought into view by abducting the foot. The posterior part of the incision divides the skin only, so as to avoid opening the part of the ankle-joint which projects forwards on to the neck of the astragalus. Beginning

internal to the extensor tendons of the great toe, the incision divides the attachment of the tibialis anticus to the first metatarsal and internal cuneiform, and exposes the dorsal surfaces of the cuneiform and scaphoid bones. The under surfaces of those bones are now laid bare, the tendon of the tibialis posticus lying posteriorly and inferiorly.

The external incision, which is placed external to the extensor tendons, extends from the posterior third of the fifth metatarsal to the upper surface of the os calcis in front of the external malleolus. The tendon of the peroneus tertius is separated from its insertion into the base of the fifth metatarsal, and the dorsal aspects of the cuboid and outer metatarsals are exposed. To lay bare the under surfaces of these bones, the tendons of the peroneus brevis and longus must be separated and drawn backwards, the latter from the groove upon the outer and under surfaces of the cuboid.

The bases of the metatarsal bones and the articular surfaces of the astragalus and os calcis are now removed.

In severe cases, especially where abscesses and advanced disease in the soft parts exist on the dorsum of the foot, it is advisable to join the two lateral incisions in front by means of a transverse one, *i.e.* to make a dorsal flap, but only through the skin and fascia so as to preserve the tendons, nerves, and vessels, which can be easily retracted to allow of the bones being dealt with. If the dorsal flap is made down to the bone so as to include the tendons, vessels, and nerves, the operation becomes unnecessarily severe, and the subsequent suturing of the tendons is tedious. It is only done when there is disease of the soft parts. The division of the tendons is not of so much importance as they become too long and must be shortened. In the last case on which we operated by means of a dorsal flap an extremely useful and movable foot was the result.

Obalinski and Catterina, in a modified form, have suggested a new method of performing anterior tarsectomy, by splitting the foot antero-posteriorly through the interspace between the second and third metatarsals, according to Catterina, and drawing asunder its two anterior portions, care being taken not to injure the plantar arch and the external plantar nerve.

The shortened foot is extremely useful both for support and movement.

4. Osteo-Arthrectomy at the Mid-Tarsal Joint. This operation is most frequently performed in the form of a cuneiform excision in talipes varus. This wedge-shaped excision gives excellent results, especially in old-standing club-foot. Indeed, if the resection is sufficiently extensive, the results are better than by any other method of operation.

The incision is begun over the dorsal aspect of the astragalo-scaphoid joint, passing obliquely downwards and backwards towards the outer border of the heel (*vide* Fig. 142). The musculo-cutaneous nerve is seen lying upon the fascia at the upper angle of the wound, while the short saphenous nerve appears at its lower angle: these nerves are drawn aside, and one or two veins are seized and twisted. After division of the fascia, the tendon of the peroneus tertius appears at the upper end of the wound, while at its lower part are the peronei tendons in contact with the outer surface of the os calcis. After their sheaths have been slit up the tendons are drawn aside with blunt hooks. The capsule is divided over the head of the astragalus, and the joint opened. The attachment of the capsule is then separated from the neck of the astragalus as far as the groove on its under surface (*vide* Fig. 143). After exposing and drawing downwards the upper border of the extensor brevis digitorum the calcaneo-cuboid joint is opened (*vide* Fig. 144). The neck of the astragalus and the greater process of the os calcis are now divided with a chisel, and drawn well out of the wound with a sharp double hook, so that they may be completely freed from their ligamentous connections and removed. In order that the foot may be dorsiflexed to less than a right angle by firmly pressing together the osseous surfaces, it is necessary, in aggravated cases of club-foot, to shell out the whole of the scaphoid and to chisel off a portion of the cuboid. The introduction of a drainage tube is not necessary, as there is no cavity remaining, and no secondary hæmorrhage is to be anticipated. The

wound is closed by a continuous suture. The foot is kept dorsiflexed and the knee bent by means of a plaster of Paris bandage, which extends upwards beyond the knee. To ensure a satisfactory result it is generally necessary to elongate the tendo Achillis.

The important points to be attended to in order to attain this end are, to obtain primary healing, to see that the foot is capable of being flexed to less than a right angle, and to prevent any tendency to talipes equinus by tenotomy of the tendo Achillis.

5. Excision of the Scaphoid. Apart from a localised tuberculous affection of the scaphoid which is of rare occurrence, removal of the scaphoid is undertaken in certain forms of flat-foot and talipes valgus. The shape of the foot is greatly improved, and at the same time the arch is reconstructed. The operation, which is not difficult to perform, is carried out by means of a longitudinal incision on the dorsum, followed by subcortical and subcapsular freeing of the bone, which is then removed with a strong elevator.

6. Arthrotomy at Chopart's Joint.

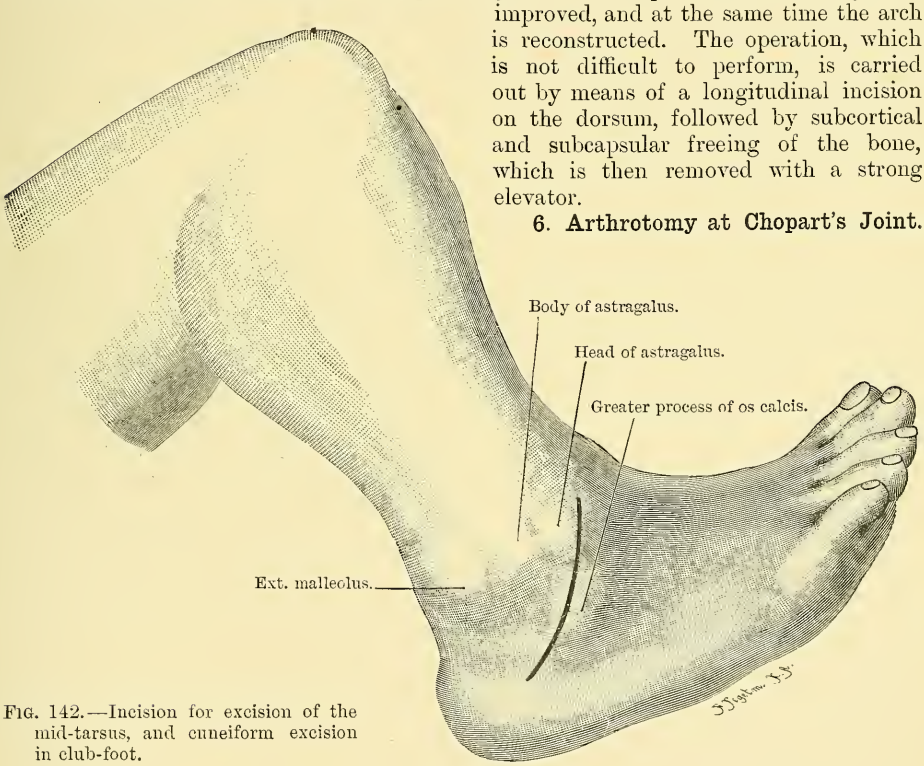

FIG. 142.—Incision for excision of the mid-tarsus, and cuneiform excision in club-foot.

For the correction of club-foot Phelps has recommended transverse division of all the contracted soft parts in the sole down to the bone, the main feature of the operation consisting in the division of the capsule between the head of the astragalus and the navicular, a method, however, more simply undertaken through a longitudinal incision along the inner border of the foot above the abductor hallucis muscle.

7. Excision of the Astragalus. It is unnecessary to give a special description of excision of each of the smaller tarsal bones, as these are operations which are seldom called for. Excision of the astragalus and os calcis, however, is often necessary in tuberculosis, in injury, and in club-foot, the two latter conditions calling especially for excision of the astragalus.

It suffices as a rule to make a free longitudinal incision upon the antero-external aspect of the ankle, as described by Vogt for excision of the ankle-joint. This incision begins a hand-breadth above the ankle at the anterior surface of the fibula, and extends downwards to the outer side of the extensor tendons (peroneus tertius) and the branches of the musculo-cutaneous nerve, over the outer surface of the astragalus to the tuberosity at the base of the fifth metatarsal bone. The incision

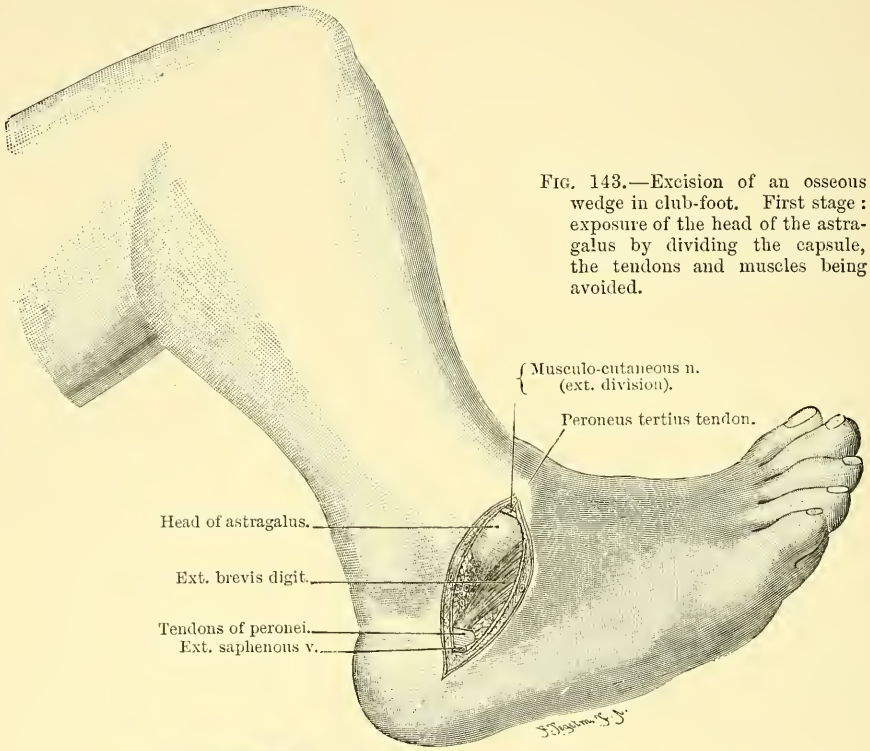

FIG. 143.—Excision of an osseous wedge in club-foot. First stage: exposure of the head of the astragalus by dividing the capsule, the tendons and muscles being avoided.

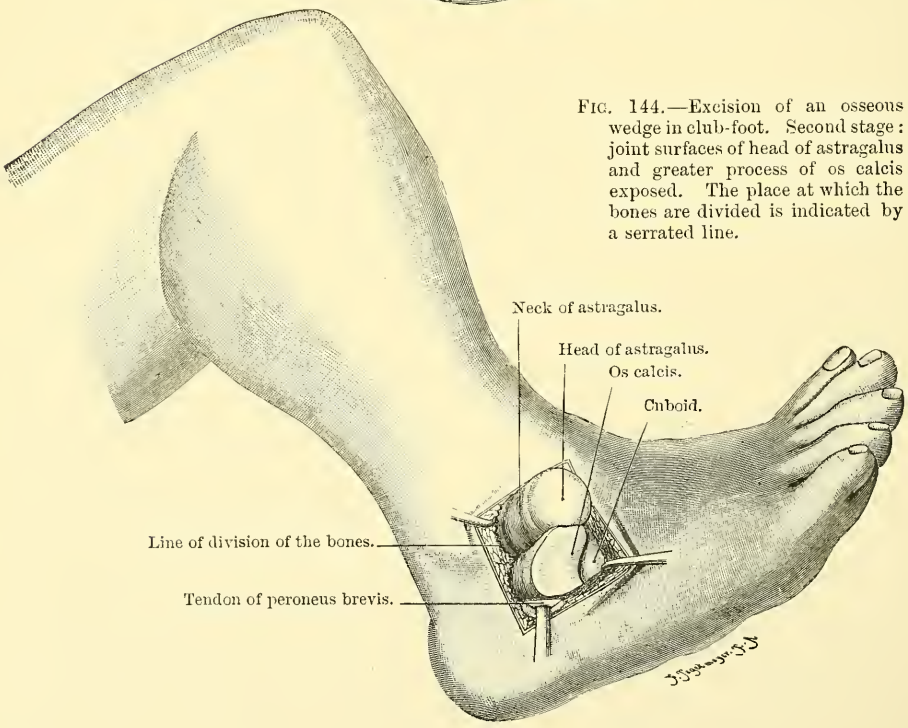

FIG. 144.—Excision of an osseous wedge in club-foot. Second stage: joint surfaces of head of astragalus and greater process of os calcis exposed. The place at which the bones are divided is indicated by a serrated line.

enters the ankle and mid-tarsal (Chopart's) joints, exposing the body and head of the astragalus. The capsule of the joint is thoroughly separated from the neck of the astragalus, and the strong interosseous calcaneo-astragaloid ligament is divided. The capsule is also separated along the anterior borders of the lower ends of the tibia and

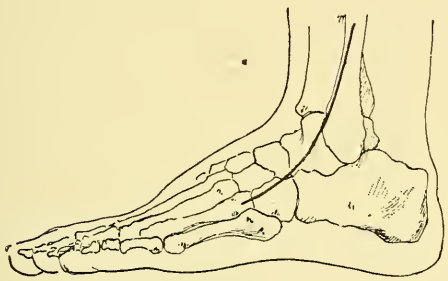

FIG. 145.—Excision of the astragalus (external incision).

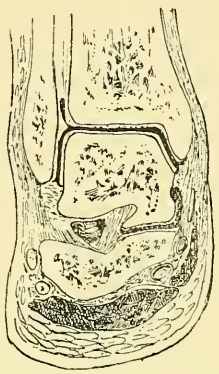

FIG. 146.—Coronal section through the ankle-joint (Henle).

fibula, and the anterior and posterior bands of the external lateral ligament of the ankle-joint are divided at the anterior and posterior surfaces of the body of the astragalus. The ligamentous connection with the os calcis is detached externally and along the posterior border of the astragalus. By forcible inversion of the foot, the astragalus is now raised to such an extent that an elevator can be introduced under it so as to divide the ligamentous attachments upon the inner aspect.

Astragalectomy, which is recommended for club-foot by Bessel-Hagen, ensures an excellent position of the foot if the external malleolus is at the same time shortened. The functional result, however, is not quite satisfactory, owing to the incongruity of the surfaces of the tibia and os calcis.

8. Excision of the Os Calcis. A longitudinal incision is made descending along the inner aspect of the tendo Achillis to the lower and hindermost part of the greater tuberosity of the os calcis, and from thence transversely around the heel, and forwards along its outer aspect to the tuberosity at the base of the fifth metatarsal bone. This gives sufficient room when the soft parts are flexible.

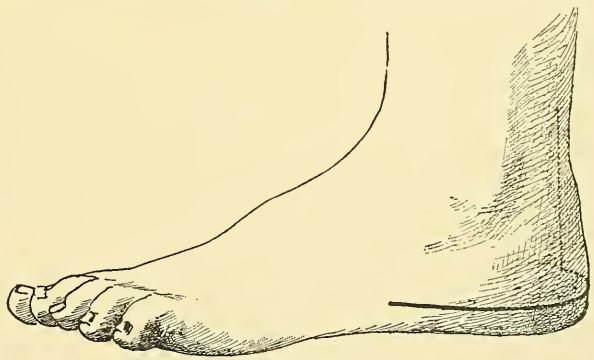

FIG. 147.—Excision of os calcis.

The tendo Achillis is detached from the posterior surface of the tuberosity; and the joint-capsule at the posterior and outer aspect of the os calcis, together with the calcaneo-fibular band of the external lateral ligament, is divided. After the peroneal tendons have been drawn upwards, the interosseous calcaneo-astragaloid ligament is cut across, and the dorsal and plantar calcaneo-cuboid ligaments are detached from the external and plantar aspects of the os calcis. The point of the heel is now well drawn over to the inner side so as to expose the tendon of the tibialis posticus, which is then displaced upwards over the

sustentaculum tali. Lastly, the os calcis is seized with a strong pair of forceps, and the internal lateral ligament of the ankle-joint, the subjacent calcaneo-astragaloid capsule, and (anteriorly) the ligaments connecting the tibia with the scaphoid and os calcis are detached.

Landerer recommends a mesial longitudinal incision extending from the tendo Achillis over the heel into the sole of the foot. By this incision he removes not only the os calcis, but, if necessary, all the other bones of the tarsus. He asserts that the scar does not in any way interfere with walking.

9. Astragalo-Calcanean Arthrectomy and Posterior Tarsectomy. Excision of the joint between the astragalus and os calcis was performed by Annandale by two lateral curved incisions, although it can also be effected by the method above described for excising the os calcis, or by a modification of the following method for excision of the posterior tarsus.

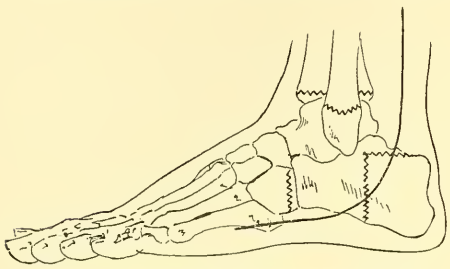

FIG. 148.—Resection of the posterior tarsus (Kocher).

Excision of the posterior tarsus—that is to say, the simultaneous removal of the astragalus and os calcis, and sometimes also of the adjacent articular surfaces—gives good results with the foot maintained in its normal position, because the leg passes down into the defect (Kocher, Kummer).

In the method which we recommend it is a necessary condition that there should be a possibility of preserving the tendons and muscles (peronei, tibialis anticus, and posticus) which move the foot.

The incision beginning upon the outer aspect of the tendo Achillis, a hand-breadth above the ankle-joint, is continued downwards behind the external malleolus and the peronei tendons, and thence forwards to the tuberosity at the base of the fifth metatarsal bone. After we have opened the sheaths of the peronei tendons and displaced the latter forwards, as has been described in excision of the astragalus and os calcis, these two bones are removed, and the articular surfaces of the bones of the leg and of the cuboid and scaphoid are sawn off. It is desirable to retain some of the external malleolus, so that the peroneal tendons may hook round behind it. If the posterior part of the os calcis can be retained, it may be utilised osteoplastically in the same way as in Pirogoff's amputation of the foot, as indicated by the serrated lines in the figure.

10. Arthrotomy and Resection of the Ankle. Excisions of this joint do not always give satisfactory results, on account of the complexity of the joint, and of the presence of disease in the adjacent astragalo-tarsal joints, together with their bones, especially the os calcis. Hence the constant endeavours to improve the technique of the operation. The incisions have been made upon all aspects of the joint, and in every direction.

The incision, to obtain a good result, must give free access to the ankle-joint and to the astragalo-calcanean articulation. It is still better if it affords an opportunity of examining the tendon sheaths, especially of the peronei.

Vogt makes an antero-lateral longitudinal incision; König and Riedel make bilateral incisions with chiselling off of the malleoli; Meinhardt Schmidt makes the same together with a posterior incision; Hüter, an anterior transverse incision, which had been previously employed by Sabatier, Heyfelder, and Hancock; Liebrecht makes a posterior transverse incision; Wackley and Textor make the same combined with a posterior longitudinal incision; Busch, Hahn, Ssabanejeff, an inferior stirrup-shaped incision with separation of the tuberosity of the os calcis; Moreau, Langenbeck, Ollier, Chauvel, Girard, lateral incisions sometimes along with transverse incisions.

We have modified the curved lateral incision, which we introduced along with Reverdin, in that we place it farther back, extend it higher up the limb, and carry the curve down to the level of the astragalo-calcanean joint, thus giving more room

and allowing of the astragalus being excised if, as often happens, the astragalo-calcanean joint is also diseased. Our incision is therefore analogous to the one first recommended by Albanese on Catterina's initiative, and later by Donenstein (Figs. 149, 150).

The skin and fascia are divided, while the external saphenous vein and nerve, which lie immediately behind the incision, are preserved.

The incision terminates at the tendon of the peroneus tertius and avoids the musculo-cutaneous nerve. The sheaths of the peroneus longus and brevis are then exposed and slit upwards behind the fibula as far as the upper end of the wound. The tendons have to be divided in some cases so as to afford more room, but each is

FIG. 149.—Incision for arthrotomy of ankle on right side.

secured with silk in order to be sutured at a later stage. The periosteum is separated from the outer and lower aspect of the external malleolus and the joint opened into in front of it.

The capsule is now detached along the outer surface of the astragalus, exposing it as far as the fibula. The three bands of the external lateral ligament are divided close to their attachment to the tip and inner aspect of the external malleolus.

The capsule, together with the periosteum, is separated from the anterior border of the tibia as far as the internal malleolus, the extensor tendons being hooked upwards, a similar method being adopted at the posterior surface of the fibula so as to leave the tendon sheath of the peronei in relation to the periosteum.

The foot is forcibly dislocated inwards over the internal malleolus, so that the upper surface of the astragalus looks downwards and the sole of the foot upwards, as

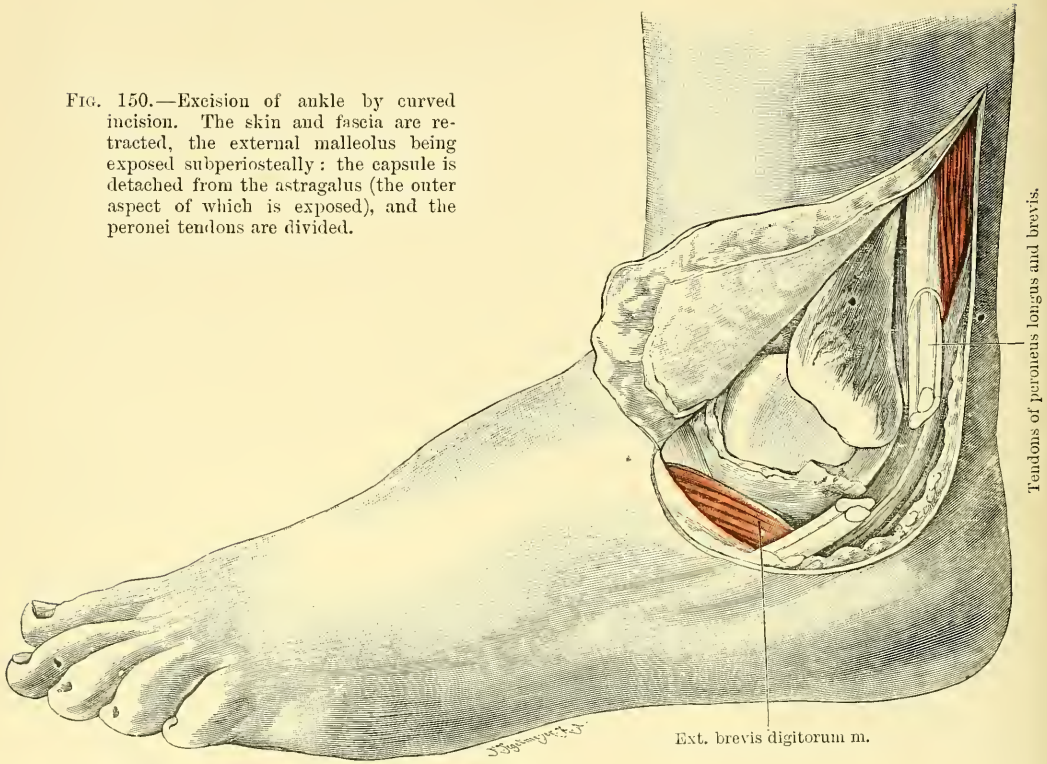

FIG. 150.—Excision of ankle by curved incision. The skin and fascia are retracted, the external malleolus being exposed subperiosteally: the capsule is detached from the astragalus (the outer aspect of which is exposed), and the peronei tendons are divided.

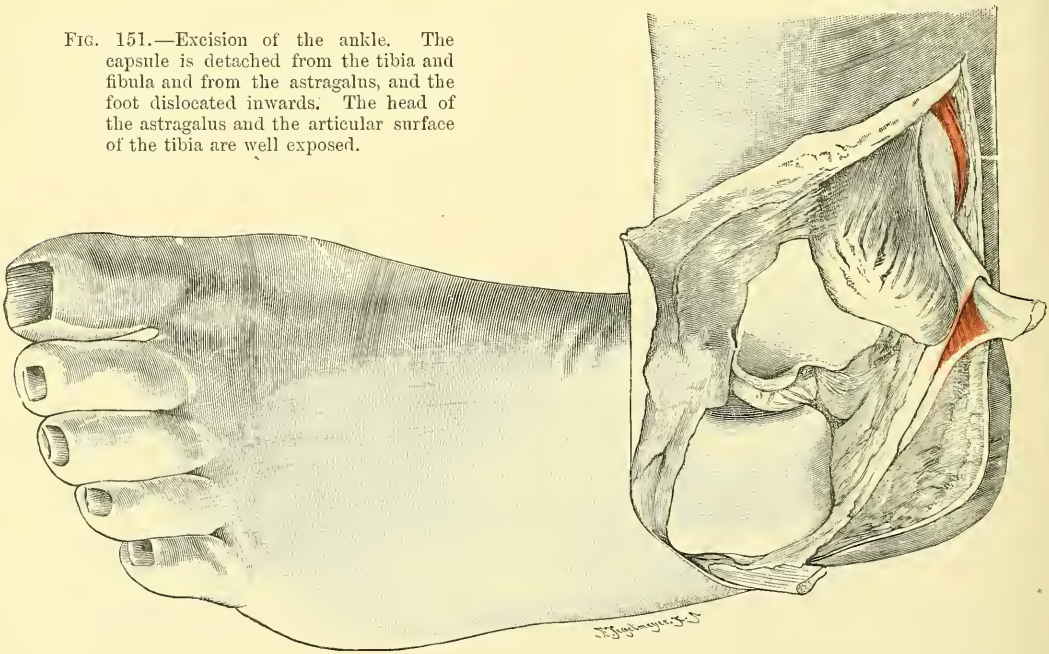

FIG. 151.—Excision of the ankle. The capsule is detached from the tibia and fibula and from the astragalus, and the foot dislocated inwards. The head of the astragalus and the articular surface of the tibia are well exposed.

shown in Fig. 151. If the bone is softened the internal malleolus is not infrequently broken in accomplishing this, but it is just in such cases that this accident entails no injury.

The ankle-joint is now well exposed, and can be thoroughly examined, as also can the tibio-fibular joint; and one can decide if the astragalus and the astragalo-calcanean joint are so involved that removal of the whole astragalus is necessary. In tubercular affections it is often desirable to try this method to ensure the riddance of all the disease, and there are no special difficulties in connection with the operation.

If there is no necessity for excising the astragalus, all that need be done is arthrectomy or excision of the ankle-joint.

The strong internal lateral ligament should be left attached to the tip of the internal malleolus, and should only be divided if the disease be extensive. It should be divided close to the bone, or better, a superficial layer of bone should be taken along with it, as the flexor tendons lie immediately behind the malleolus. The joint can now be easily scraped out and the astragalus removed. If the astragalus is to be retained, the astragalo-calcanean joint should not be opened unnecessarily, an accident which will be avoided by preserving the attachments of the capsule on the posterior and lateral aspects of the astragalus.

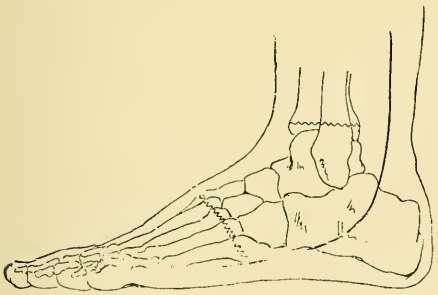

FIG. 152.—Resection of the entire tarsus (Wladimiroff, Mikulicz).

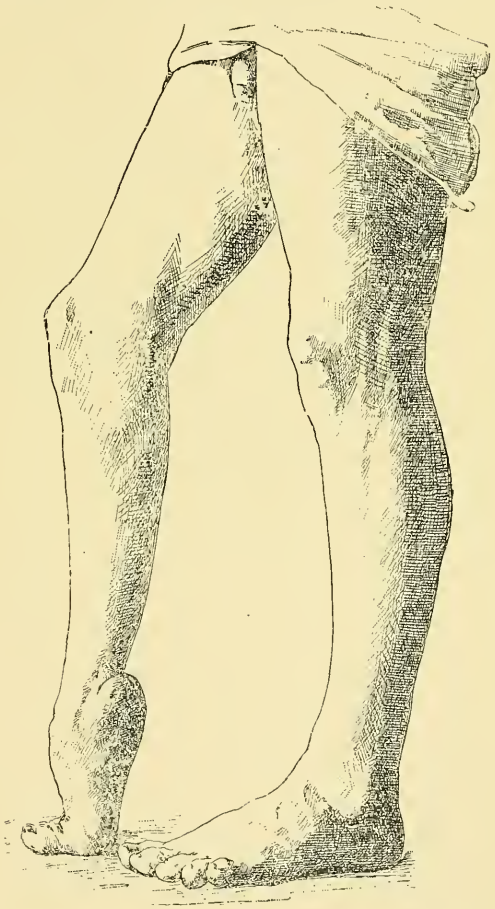

FIG. 153 shows the result after complete resection of the tarsus (from a photograph of a case operated on by the author).

The method above described keeps intact the ligamentous apparatus upon the inner aspect of the joint, as well as the support of the external malleolus upon the outer aspect, and thus provides as far as possible against lateral displacements of the foot.

The after-treatment is of great importance: the foot should be kept at right angles to the leg by means of a plaster of Paris bandage, applied at once, and retained until the wound is thoroughly healed. If the wound heals by first intention the patient can leave his bed in two or three weeks. At a later stage it is advisable to maintain the good position of the foot by means of a Scarpa's shoe.

11. Total Tarsectomy. Wladimiroff and Mikulicz have added to our measures for

preserving the foot by a method of operation which they have employed for disease of the posterior tarsus, a method which we regard as superfluous for disease of the posterior tarsus when the soft parts of the sole and heel can be retained, but one which we consider especially valuable in disease affecting all the bones and joints of the tarsus, as it affords the possibility of obtaining a useful foot. After the entire tarsus has been excised, the sawn bases of the metatarsal bones are applied to the sawn surfaces of the bones of the leg, the foot being brought into a vertical position continuous with the axis of the leg. The patient walks upon the anterior surfaces of the heads of the metatarsal bones, the toes being markedly dorsiflexed. If the scaphoid and cuboid, or the latter and the three cuneiforms, are sawn through, a broader and firmer surface is obtained.

The same principle is applied here as in Pirogoff's amputation, in which the posterior part of the foot is rotated 90° so as to elongate the leg.

As, however, Mikulicz's method presupposes a defect of the skin of the heel, which is an exceptional condition, and in the presence of which the management of the incisions is self-evident, we prefer to describe the method of operation in a typical case, namely, when the disease affects the entire tarsus and leaves an available skin covering.

The incision is just the same as that for excision of the posterior tarsus, namely, a postero-lateral curved incision (Fig. 152), beginning a hand's-breadth above the ankle-joint, and extending downwards behind the external malleolus and peronei tendons, and then forwards to the fifth metatarsal bone. As in the method already described, the bones and joints between the leg and the metatarsus are laid bare by separating the tendo Achillis and periosteum from the os calcis, and by freeing the peronei tendons from their sheaths and drawing them forwards. The insertions of all the long tendons of the foot (peroneus tertius, brevis, and longus) are detached from the upper, outer, and under surfaces of the tarsus respectively, as also are the insertions of the tibialis anticus and posticus from their upper, inner, and under surfaces. In doing this the blood-vessels and nerves are to be preserved.

Lauenstein, in cases where the ankle-joint is stiff, recommends that the boot be fitted with a suitable cylinder sole, the rounded surface being transverse to the axis of the foot.

(e) Operations on the Leg

12. Supramalleolar Osteotomy. This operation is performed for the correction of club-foot. The tibia and fibula are divided through an incision which runs from above obliquely downwards and inwards above the internal malleolus, and by this means the adduction of the foot is removed.

The foot, however, then assumes the abducted position that is met with in a Pott's fracture. As there is no real improvement in the ultimate position of the foot, the operation should be restricted to cases in which other methods have failed or in which the deformity has recurred.

13. Resection of the Lower Third of the Leg. In the case of extensive disease of the lower third of the bones of the leg, it may be admissible, by means of a very long postero-external incision, to expose and remove a slice of bone from the posterior surface of the os calcis, and to apply its raw surface to the sawn surface of the tibial diaphysis.

Brodnitz has adopted our suggestion with a slight alteration in the direction of the saw cuts. We reproduce in Fig. 154 illustrations of his modification of our methods.

14. Osteotomy of the Tibia. This operation, which is frequently undertaken, presents no difficulty, as the inner surface of the tibia is subcutaneous. It is performed after osteomyelitis to remove a sequestrum, a wide gutter-shaped opening being chiselled out on the inner aspect of the tibia through which the focus in the marrow is reached. To fill up the gap in the diaphysis of the tibia it is advisable to

turn the skin from both sides into the cavity so that it may become adherent to the edges of the bone, a process which may be facilitated either by pressure with iodoform gauze or by fixation nails.

Osteotomy of the tibia and fibula is also undertaken in rachitic curvatures. The bone is divided with the chisel without detachment of the periosteum through a small incision along the anterior edge of the tibia (the same operation being performed on the fibula on the outer side) generally below the middle of the bone.

In malunited fractures the operation varies in regard to the individual case. In genu valgum a wedge of bone may be removed on the inner side of the tibia below the epiphyseal cartilage.

The skin and periosteum are divided two fingers'-breadth below the level of the joint in the line of cleavage of the skin, *i.e.* transversely inwards from the tubercle

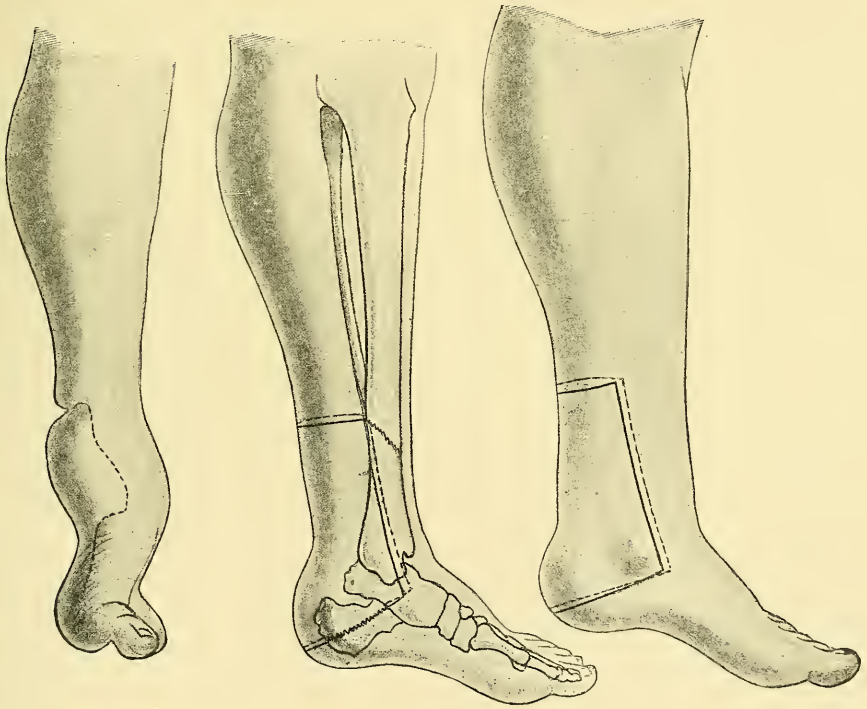

Fig. 154.

of the tibia to the edge of the calf muscles. After separation of the periosteum the chisel is applied in the direction of the skin incision. The attachment of the ligamentum patellæ must not be injured, because the bursa between it and the tibia may communicate with the joint. In an aggravated case of genu valgum it is better to remove a wedge from the tibia having its base directed inwards, otherwise, with the leg in the straight position, there is too great a strain on the head of the fibula, and paralysis of the external popliteal nerve which winds round it may be the result. Luksch (Nicoladoni) prefers to remove a prism of bone from the tibia.

15. Resection of the Tibia. Resection of the tibia may be necessary in acute osteomyelitis with extensive necrosis; or the entire diaphysis may have even to be removed. We have always found that, provided the periosteum is retained and the fibula is preserved as a support, complete regeneration of the tibia is to be expected. Although the upper end of the fibula projects upwards and the leg has a tendency to take the varus position owing to the traction of the new-formed and somewhat

consolidated bony tissue, a perfectly functional joint (capable of bearing weight) is obtained. In cases of total resection of the tibia where it has not been possible to preserve the periosteum, the fibula of the other limb may be transplanted. In an earlier edition we mentioned a case in which this had been successfully accomplished.

16. Resection of the Fibula. The diaphysis, and indeed the entire fibula, may be removed by an incision behind the whole length of the peronei muscles (*e.g.* in the case of a tumour or when it is to be used as a substitute for another bone), without interfering with the supporting power and activity of the limb, or with the movements of the foot in all directions. The external popliteal nerve is to be avoided as it winds round the neck of the fibula, and the peroneal artery is to be borne in mind as it runs down behind the lower half of the fibula.

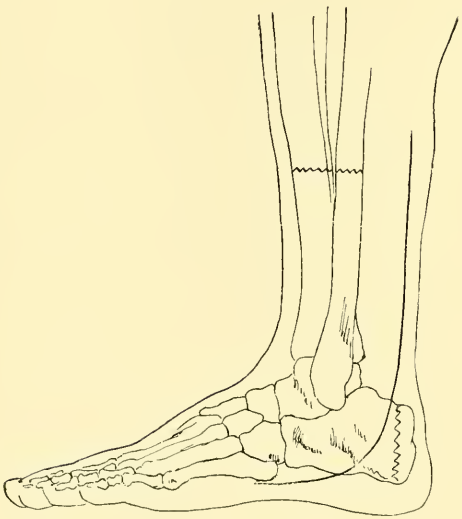

FIG. 155.—Resection of the lower third of the leg.

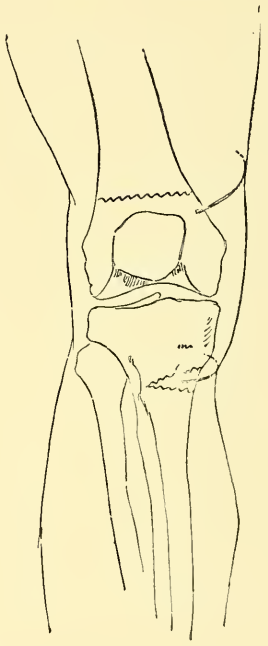

FIG. 156.—Osteotomy of the femur. Cuneiform osteotomy of the tibia.

(f) Operations on the Knee

17. Arthrotomy, Arthrectomy, and Resection at the Knee-Joint. (*a*) *Arthrotomy, and Resection of the Knee* (Figs. 157, 158). We have tested the many methods which have been proposed for freely opening the knee-joint. None of them, however, gives sufficiently free access in so simple a manner as the transverse curved incision with its convexity below. It must, however, be carried as far backwards as to include at least two-thirds of the circumference of the knee. It is not quite clear which surgeon has the merit of having introduced it, as Park appears to have first made the suggestion, and Textor is mentioned as the father of the method. Erichsen, however, has done much to popularise the operation.

Volkmann recommends a horizontal incision through the centre of the patella, while Diakonow (Starkow) divides the patella and the patellar ligament in a vertical direction, and detaches the tibial attachment of the latter together with a shell of bone. Like most mesial incisions it has the advantage of simplicity, and is attended with less injury to neighbouring structures.

We have completely replaced our former method of excision by means of a transverse curved incision by an external slightly J-shaped incision, as after having opened the joint (arthrotomy) it allows one to proceed to whatever extent of resection may be necessary. Apart from the skin incision, our method resembles the subcapsulo-periosteal method in always aiming at entire removal of the diseased tissue; in fact, after excision for diffuse tuberculosis of the knee, the skin is placed in direct contact with the bone. But we always endeavour to keep the quadriceps extensor apparatus intact, so that we may be free to continue the operation in

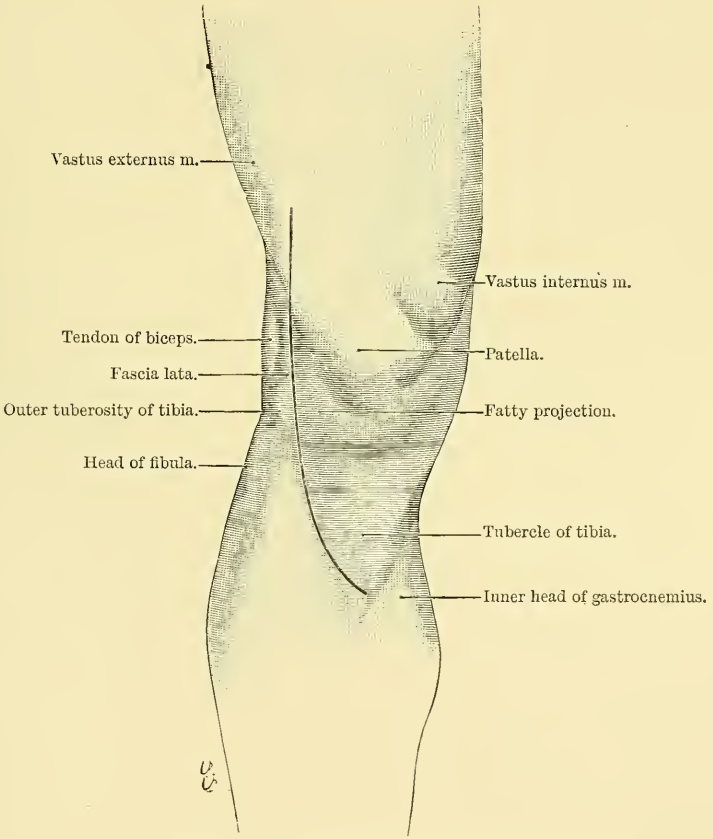

FIG. 157.—Incision for arthrotomy of knee.

whatever direction seems necessary, and our method of excision falls into line with the method of arthrotomy.

Langenbeck has employed a similar incision, but he makes it more curved and places it on the inner side of the joint. It is better, however, to place the incision on the outside, because should the knee give way subsequently it is almost always in the direction of genu valgum. It is important, therefore, that the resistance of the tissues on the inner side should not be diminished by dividing them, and for this reason we maintain that the external incision is preferable. We shall describe our procedure as we are in the habit of performing it on the living subject.

The incision (Figs. 157, 158), which begins over the vastus externus, a hand's-breadth above the upper border of the patella, extends at first vertically downwards a finger's-breadth external to it, and then curves slightly inwards to end at the

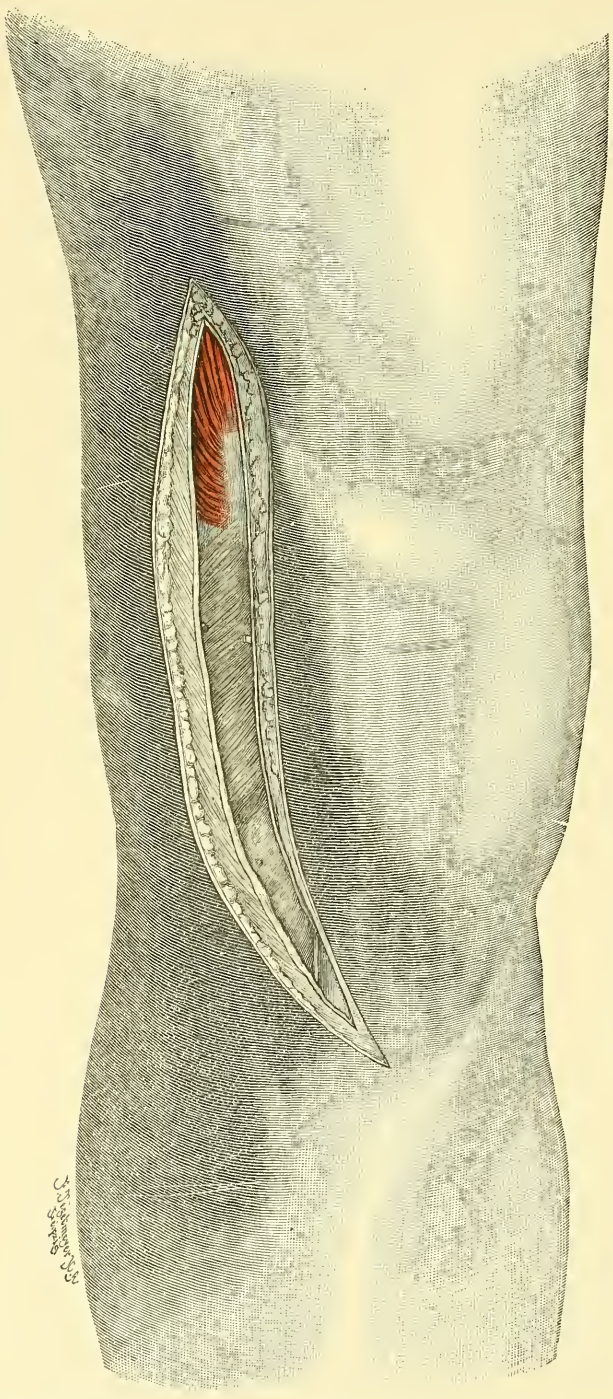

anterior border of the tibia just below its tuberosity. After dividing the skin, the dense fascia lata is exposed and divided, its fibres, which run obliquely downwards and forwards, being very thick below. At the upper end of the wound the outer edge of the vastus externus is exposed and divided: below this, are exposed, from above downwards, the outer surface of the capsule, some fatty tissue, and the outer edge of the ligamentum patellæ, which is freed down to the tubercle of the tibia, the latter, along with the ligament and the periosteum of the tibia, being then detached subcortically and retracted inwards.

In the upper part of the wound the capsule of the joint is divided over the outer aspect of the external condyle, and the upper end of the synovial pouch behind the quadriceps is exposed. Lower down, however, one keeps more to the middle line, so that without detaching the capsule from the external semilunar cartilage, the anterior extremity of the latter may be cut away from the tibia, and, along with the capsule, separated from the upper surface of the tibia. The ligamentum patellæ is then pulled to the inner side with a sharp hook, and after dividing the anterior extremity of the internal semilunar cartilage in front of the anterior crucial ligament, the meniscus, along with the capsule and periosteum of the tibia, is detached from the cartilaginous margin of the internal condyle.

FIG. 158.—Arthrotomy of the knee by means of the curved external incision; skin and fascia lata divided, with the vastus externus appearing above, and in the lower end of the wound the capsule, fat, and the outer edge of the ligamentum patellæ.

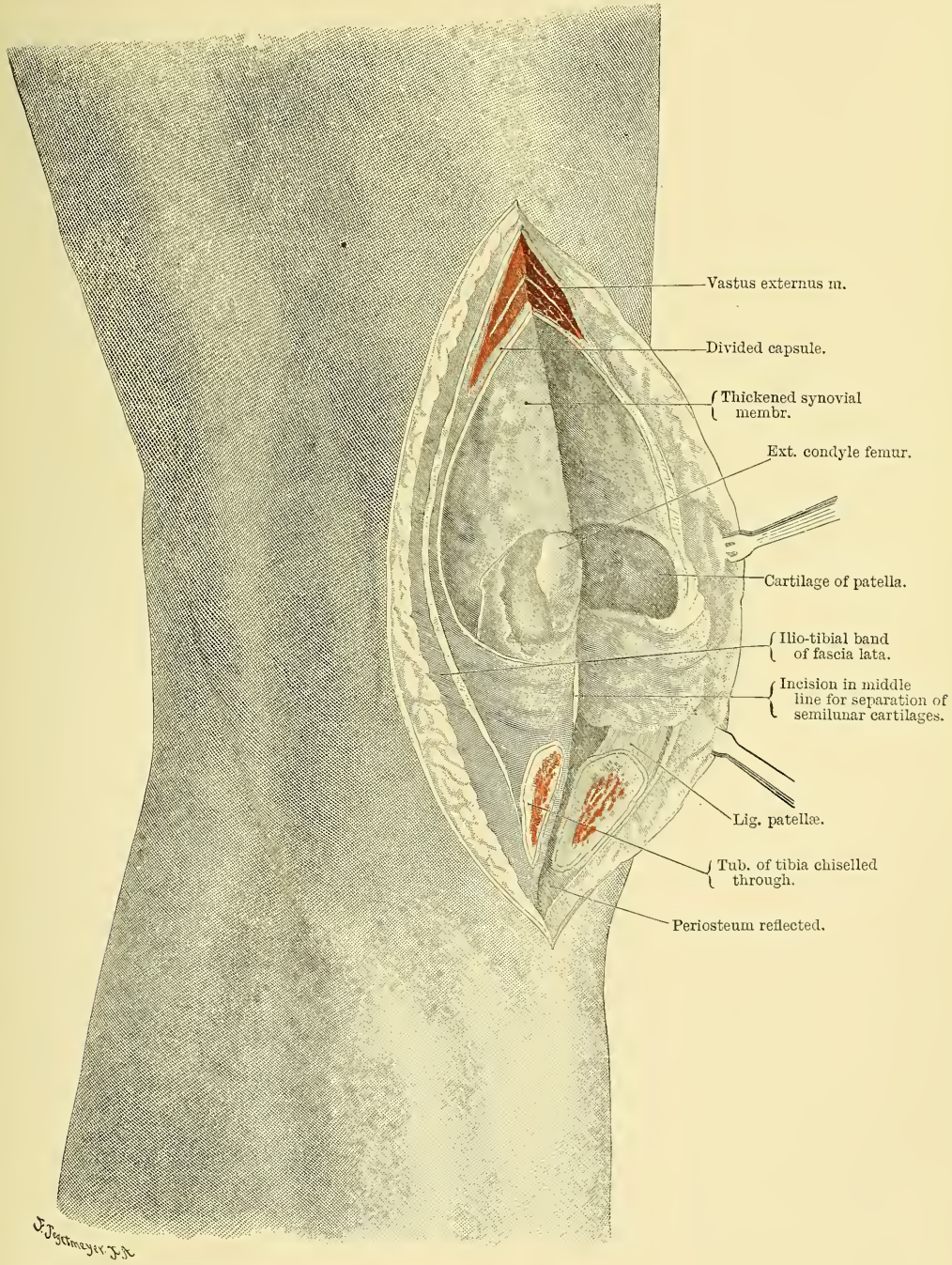

FIG. 159.—Arthrotomy of knee. The joint has been opened and the patella, with the quadriceps tendon and ligamentum patellæ pulled inwards; also the tuberosity of the tibia, which has been chiselled through, and is seen retaining its normal connection with the patellar ligament above and the periosteum below.

The patella should now be dislocated over to the inner side (Fig. 159), and by detaching the capsule from the tibia internally and externally, the leg can be more and more bent, until finally it is completely flexed. Next the attachments of the crucial ligaments are severed from the spine of the tibia (or a piece of bone is detached along with them) as far as the posterior attachments of the semilunar cartilages, which, along with the crucial ligaments, are separated as far as the posterior surface of the tibia (Fig. 160).

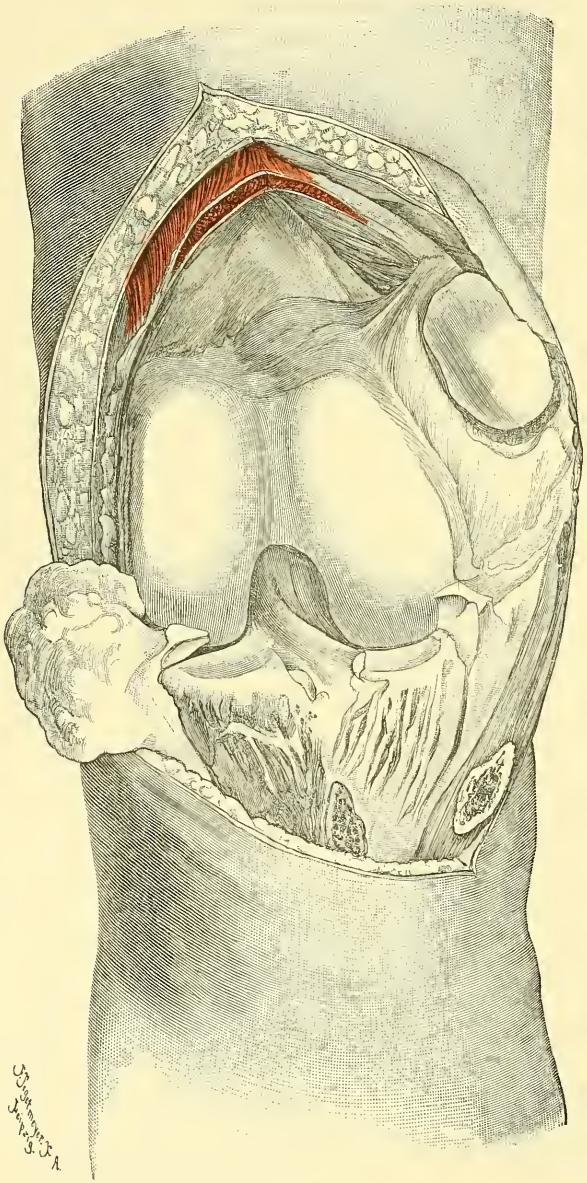

If it be necessary to remove the ends of the bones, the upper attachments of the crucial ligaments are separated from the intracondyloid fossa in such a way that they, along with the semilunar cartilages, retain their connection with the posterior wall of the capsule and the periosteum. Next the capsule is divided at the edge of the cartilage of the femur, and if it is not to be removed it is detached backwards subperiosteally as far as the upper attachments of the lateral ligaments. The femur is now sawn convexly below the level of the separated lateral ligaments, while the tibia, after the capsule and periosteum are separated from its posterior aspect, is sawn in a concave manner.

If the disease extends more deeply into the bones, the lateral ligaments, after chiselling through the epicondyles, are more extensively separated from the bones. In the case of the femur it is especially important, after separation of the periosteum and capsule

FIG. 160.—Arthrotomy of the knee by an external curved incision, giving a complete exposure of the joint. The capsule has been split upwards into the lower muscular fibres of the vastus externus, and downwards as far as the tubercle of the tibia, which has been chiselled off, still retaining its connection with the periosteum below, which is separated for a short distance. The whole of the lower part of the quadriceps apparatus can now be everted and thrown over to the inner side. The anterior attachments of the semilunar cartilages are detached and reflected, the one inwards and the other outwards, each retaining its connection with the capsule.

as far as the epicondyles, to detach these bony processes, together with the lateral

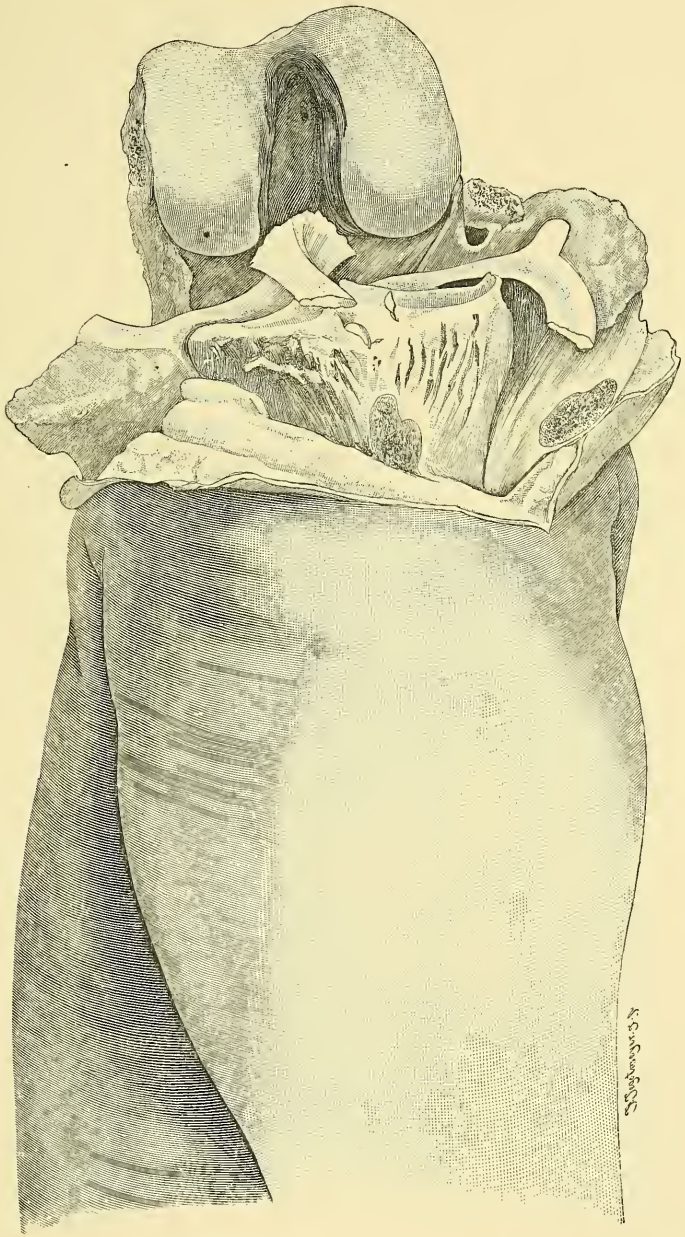

FIG. 161.—Excision of knee. Tubercle of tibia and semilunar cartilages detached as in Fig. 160; the attachments of the lateral ligaments are chiselled off through the epicondyles of the femur, and the crucial ligaments are separated from the intercondyloid notch of the femur and the upper surface of the tibia in continuity with the capsule.

ligaments and tendon-insertions, with hammer and chisel (according to the plan introduced by König for preserving the attachments of the ligaments), and to displace

them backwards, in continuity with the periosteum, as far as the level of the saw line (Fig. 161).

In order to further firm ankylosis by accurate apposition of the bones, the way in which the ends of the bones are sawn off is a most important matter. To avoid forward displacement of the femur upon the tibia, the saw has been directed at all kinds of angles, and a great variety of means of fixing the sawn surfaces has been employed. Nails and sutures have been used. As, however, these often tear out, and do not fulfil their object, Albert, in Vienna, and others, have bevelled the surfaces during the sawing. We have got by far the best results by sawing the femur so as to leave a convex surface, and the tibia so as to produce a corresponding concave surface. This method was recommended by Metzger, and by Fenwick, first in 1871, and later in another publication, where he reports twenty-eight cases in which the functional results were very good. If the operator thoroughly understands how to estimate the direction of the saw, the bony surfaces may be brought into such accurate contact and may be so firmly pressed together that all further artificial means of fixation are quite superfluous, provided, of course, that the limb is firmly fixed to a splint in the fully-extended position.[1] Sawing the femur in a curved direction has the further advantage of more certainly avoiding the epiphyseal line, a matter of great importance as regards the future growth of the femur. After adapting the two sawn surfaces to one another, all that we require is to introduce a suture which penetrates deeply through the skin and fascia, drainage tubes being inserted through special openings. By this plan, just as in simple wounds of the soft parts, we have of late years obtained complete union by first intention in numerous cases, so that after eight to fourteen days the patient can get up either in the plaster case applied after the operation, or the limb may be immobilised in a special water-glass bandage. The patient is able to stand on the leg six weeks after the operation. In those cases in which, on account of suppuration or other local infection, open-wound treatment must be employed, the ends of the bones cannot be fixed together by making curved sawn surfaces. In such cases it is well to retain the extensor apparatus.

(*b*) *Arthrectomy of the Knee-Joint.* Arthrectomy of the knee-joint by means of the external incision differs from the other methods in that the diseased capsule is laid bare as far as possible from the outer aspect: the incision, the subcortical separation of the crucial and lateral ligaments, the detachment of the epicondyles, the separation of the semilunar cartilages, together with the spine of the tibia, are the same.[2]

If the capsule is so diseased throughout that one is certain beforehand (*e.g.* in tuberculous synovitis and arthritis) that it must be removed *in toto*, whether a resection of the ends of the bones may require to be done in addition or not, one proceeds as follows :—

After the skin incision, a portion of the vastus externus and the fascia lata are divided (Fig. 158), the attachment of the patellar ligament is separated, the capsule of the joint is not cut into, but its outer surface is exposed over its entire upper and lower extent, and the visceral layer separated from the bones, which in the case of the femur may be easily done right up to the edge of the articular cartilage, as the pouch behind the quadriceps is separated from the bone by a distinct layer of fat.

[1] Küster (in the *Festschrift für Leuthold*, Bd. 2) thinks that too little attention has been paid to the exact coaptation of the joint surfaces. We have always emphasised the importance not only of primary exact coaptation, but also that the bones should be held in position, which is much more difficult with his method.

[2] It is reassuring to see from Blauel's article (*Beiträge zur klin. Chir.* Bd. 42) that Bruns has adopted the "extracapsular" method described by us six years ago in a former edition, and that he sets great value on it. He has, however, overlooked the fact that it had already been accurately described by us. Bruns uses the curved incision downwards (Textor) or upwards (Hahn) as was our former custom, but which we abandoned in favour of the lateral-shaped incision, as it is a disadvantage to injure the extensor apparatus in these cases (*e.g.* Volkmann's transverse patellar incision), if there is any doubt about a total resection being required. For the same reason also only a limited use is found for the extracapsular method of Wolkowitsch and Sabanejew, which begins on principle with sawing through the femur and tibia, and has been abandoned by Bruns. The same is true of Flint's operation (*Annals of Surgery*, 1906, 3).

The entire capsule is then divided along the edges of the articular cartilage of the femur, tibia, and patella,[1] the patella being detached along with the quadriceps and ligamentum patellæ. In children the separation of the attachments of the ligaments and the detachment of the epicondyles can be done with the knife.

In arthrectomy, in contrast to arthrotomy, the semilunar cartilages are removed, as they are also diseased, and it is not possible to preserve them in removing the capsule from above or below. The nature of the operation, especially in tuberculosis, is governed by the principle that all the diseased tissues, whether synovial membrane, cartilage, or bone, must be as thoroughly removed as if dealing with a malignant tumour.

After-treatment. When the capsule is preserved, it is to be carefully sutured, after which the flap is brought into position with a few deep sutures, and then, after providing for drainage, the continuous cutaneous suture is applied. To secure permanent healing in tubercular cases iodoform should be rubbed into all the recesses and folds. When sinuses and open wounds exist, the cavities are stuffed with iodoform gauze, the skin being retained in position by introducing temporary sutures, which are removed after one to ten days, and the definite suture is introduced (secondary suture) according to the plan recommended by us, and more recently somewhat modified by Bergmann, Sprengel, Helferich, and others. When there is any uncertainty the wound must be treated by the open method to the end. Küster's transverse elliptical incision with removal of the patella is a very suitable method when the wound has to be kept open, and packed with iodoform gauze or with Mosetig's iodoform filling, because it gives excellent access and the dressing is simplified.

The limb should always be fixed from the beginning in the extended position in plaster of Paris extending from the tuber ischii to the malleoli, the bandages being applied so that the wound can be dressed without the least movement of the limb, while the foot may be left free and moved from the first.

Atypical resections in connection with the knee-joint—for example, resection of one or other condyle or tuberosity—are only justifiable when one is certain of bringing about ankylosis of the other tuberosity or condyle with the opposing bone.

In resection of the knee, bone ankylosis is the object in view, while in arthrectomy fibrous ankylosis is, as a rule, undesirable. When ankylosis is fibrous or cartilaginous, as is often the case in children even after resection, it is very difficult to prevent subsequent flexion deformity when advanced atrophy of the quadriceps has occurred. The question may be raised whether tendon transplantation should not be undertaken to prevent this, by freeing the insertions of the biceps and either the semitendinosus or semimembranosus and uniting them with the fascia and periosteum to the edge of the patella.

18. Meniscotomy. Excision of a semilunar cartilage has frequently to be undertaken, as a result of injury, and is indicated much more often than is generally supposed. The so-called dislocation of the cartilage (generally the inner) is not a true dislocation, and it would be better if the term were no longer employed. It consists rather in a crushing of the cartilage with rupture and displacement of the torn ends which become locked and give rise to the well-known symptoms of a loose body in the joint.[2] The condition is cured by partial or total excision of the cartilage.

A curved incision from above downwards and outwards, similar to that employed in arthrotomy, is used on the inner side of the knee. After division of the skin and fascia, the capsule is opened over the cartilage by an incision from the internal lateral ligament to the ligamentum patellæ. The condition present can then be seen. By flexion and slight abduction of the knee, any tags projecting into the joint are observed and either the whole or merely the anterior part of the cartilage may be excised. The entire cartilage need only be removed when it is no longer connected with the

[1] In cases where extracapsular excision of the capsule is indicated, Küster is perfectly justified in emphasising the necessity of removing the patella on principle, which has for long been our practice.

[2] We intend shortly to publish our cases in conjunction with Dr. A. Kocher, who has studied the subject experimentally.

capsule or when it is thickened or sensitive. The wound is closely stitched without drainage.

The subsequent movements are thoroughly restored, but the knee has a tendency to a slight degree of genu varum.

19. Arthrotomy for Habitual dislocation of the Patella (congenital). The patella may be displaced outwards either from congenital reasons or as the result of a trauma. The displacement recurs very readily on account of the angle formed on the outer side of the knee by the tibia and femur, which gives the quadriceps a preponderating pull outwards.

Plication of the capsule on the inner side of the patella with a rampart suture ("mauernaht") has produced satisfactory results, while at the same time the aponeurosis of the vastus internus is split longitudinally and sutured as far as possible in a transverse direction.

Krogius has described a method, *i.e.* transplantation of muscle and tendons, which promises still better results. He raises a long bridge-like strip of the vastus internus along with its fascial extension and stitches it to the outer side of the patella through a separate incision. The synovial membrane need not be opened. Our external J-shaped incision may be used with advantage.

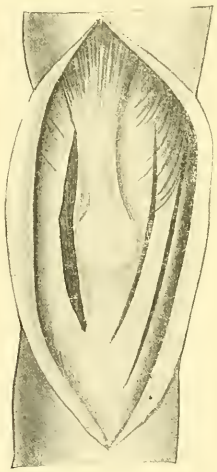

Fig. 162.

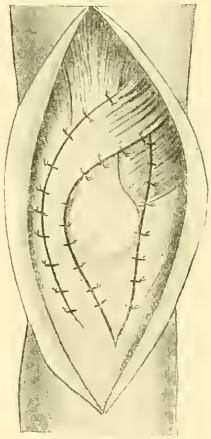

Fig. 163.

20. Excision of the Patella. This is an important operation for primary disease of the patella (which is not uncommon) in order to prevent diffuse disease of the joint. The individual steps of this very simple operation are—longitudinal incision, division of the fascia and of the smooth-walled bursa which is generally found underneath it, stripping off of the quadriceps fascia and of the periosteum, and, lastly, separation from the anterior wall of the capsule. After removing the patella the cut edges of the capsule can be united in the longitudinal direction without difficulty, the joint being closed and the extensor apparatus re-established. The results are very satisfactory, as a completely movable joint can be obtained (Dr. Kummer).

(g) Operations on the Thigh

21. Supracondylar Osteotomy of the Femur. The incision, whether on the outer or inner side, is along the line of cleavage of the skin, and passes obliquely from above downwards and forwards through the skin and the fascia lata, which is especially strong on the outer side. The vastus (internus or externus) is exposed at its posterior border and drawn upwards, while the periosteum is split vertically above

the epicondyle and separated forwards and backwards, and the bone divided with a chisel for two-thirds of its breadth, the remainder being broken across.

The superior internal (or external) articular artery is to be looked out for, and internally especially the deep branch of the anastomotic artery. Along with Macewen (to whom belongs the credit of devoloping this operation) we were the first to perform osteotomy of the femur for genu valgum.

An incision above the internal condyle, a finger's-breadth in front of the insertion of the tendon of the adductor magnus, must be regarded as the normal one, as it avoids the superior internal articular artery. Moreover, the bone is more easily reached from the inner side, and, after dividing the skin and the relatively thin deep fascia, it is necessary, in order to reach the periosteum, to free and hook aside the lower border of the vastus internus. By this plan the soft parts can be ensured against injury better than by the widely adopted procedure of Macewen, who introduces a chisel down to the bone through quite a small opening. We employ a chisel with a blunt projection at one side.

After dividing the greater part of the bone the remainder is fractured. The after-treatment is generally carried out by means of a carefully-applied plaster of Paris bandage. We have, however, given up this plan and now apply weight-extension in order to prevent stiffness of the knee-joint. The small wound is sutured and covered with a collodion dressing.

Supra-condyloid osteotomy has completely taken the place of Ogston's ingenious method of intra-articular division of the internal condyle of the femur for the femoral form of knock-knee. It is far preferable to every form of osteoclasia or forcible reduction without operation. It is not so frequently employed for contracture and ankylosis of the knee in bad position, because an excellent result is got by removing a wedge from the femur and tibia and dividing the capsule of the joint, by which means the cure is more permanent, as there is less chance of leaving behind some disease in the joint. In our own experience, in certain cases of contracture where there is a slight degree of movement at the joint, supra-condyloid osteotomy gives a better result than excision, the limb being brought into the extended position without injuring in any way the movements of the joint.

An incision is made external to the quadriceps (vastus externus), and the latter muscle is detached off the bone and retracted forwards along with the joint capsule. A wedge with the base forwards is cut with the chisel sufficiently high above the articular cartilage to avoid opening into the joint.

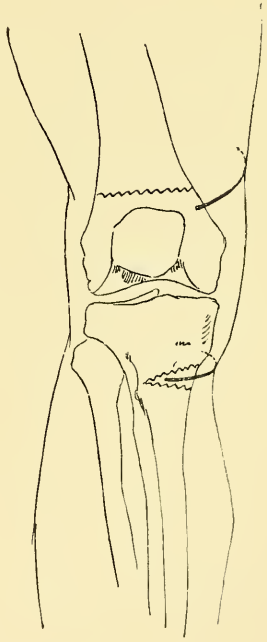

FIG. 164.—Osteotomy of the femur. Cuneiform osteotomy of the tibia.

22. Osteotomy and Resection of the Femur. Partial resections of the femoral diaphysis are undertaken in the treatment of acute and chronic osteomyelitis, especially in the latter, where local pain and fever may otherwise remain for a considerable length of time.

An incision may be made along the whole length of the outer side of the thigh without entailing any real damage on neighbouring structures. It should follow the posterior border of the vastus externus after dividing the skin and the strong fascia lata (ilio-tibial band) *i.e.* it may extend from the base of the great trochanter across which the terminal branch of the external circumflex artery runs, to the external condyle over which the superior external articular artery passes. The whole diaphysis of the femur is, however, only removed in the performance of extensive sequestrotomy after acute osteomyelitis.

23. Osteotomy and Sub-trochanteric Cuneiform Resection of the Femur.

Osteotomy below the trochanter is of historical interest as the operation which first brought osteotomy into notice. It was introduced by Rhea Barton. It was extensively employed by Volkmann, and Adams and Sayre have shown its advantages. It is an excellent operation for all malpositions of the hip which cannot be remedied otherwise: it is especially indicated, therefore, in old hip-joint disease with ankylosis, or stiffness in the position of extreme flexion and adduction. In bad cases one is glad when cure occurs with ankylosis, as in these circumstances excision of the hip with restoration of the movements at the joint would be unfavourable on account of the atrophied condition of the muscles. This difficulty is overcome by means of subtrochanteric osteotomy, which is equally efficient in correcting the deformity. The operation is easily performed, and if asepsis is secured it is not more serious than a simple fracture.

By subtrochanteric osteotomy a marked improvement can also be made in the mode of progression in old-standing, as well as in congenital dislocations of the hip. The operation in these cases is often far less serious than the severe open operation necessary for replacing the head of the femur into the acetabulum when reduction cannot be effected in any other way. If the dislocated head is well retained and movable in its false position, it is better to leave it there and to be content with straightening the limb by an osteotomy.

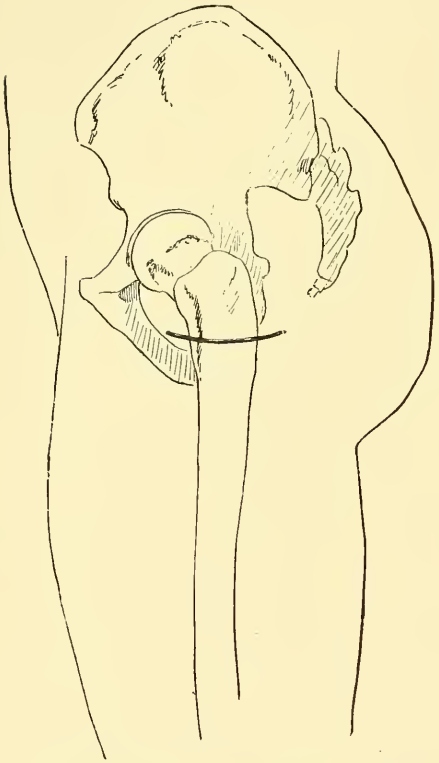

FIG. 165.—Subtrochanteric osteotomy.

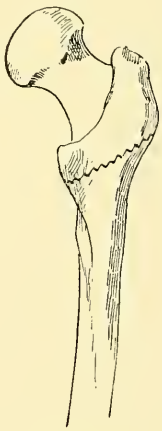

FIG. 166.

A transverse incision (or, still better, an oblique incision in the direction of the line of division of the bone) is made down to the bone on the outer side, through the skin and tendon of the gluteus maximus, behind the tendinous insertion of the vastus internus at the level of the base of the great trochanter and below the trochanter minor. The transverse terminal branch of the external circumflex artery runs parallel to the incision. The bone is chiselled through obliquely downwards, forwards, and inwards, so as to prevent the lower fragment from being displaced inwards or forwards when the limb is forcibly abducted.

For the after-treatment, in cases where the bad position is easily rectified, a plaster of Paris bandage is all that is required; but when there is any difficulty in at once bringing the limb into good position, weight-extension should be employed.

(h) Operations at the Hip and Pelvis

24. Arthrotomy and Resection of the Hip.—(*a*) *Excision of the Hip by the Anterior Method.* We have tried Hüter's anterior resection, which has been warmly recommended especially by Barker, Lücke, and Schede, but we regard it as indicated only in partial excision, *i.e.* for the removal of the anterior part of the capsule and head of the bone. Hüter's anterior longitudinal incision is especially adapted for exposing the acetabulum in congenital dislocation of the hip. For a description of the operation for congenital dislocation of the hip the reader should consult the works of Hoffa and Lorenz.

An incision, 10 to 15 cm. (4 to 6 inches) long, is carried downwards from the anterior superior spine of the ilium dividing the skin and fascia. The external cutaneous nerve lies to the inner side. The incision strikes the interval between the sartorius with the underlying rectus femoris (arising from the anterior inferior iliac spine) and the tensor fasciæ femoris. In the lower part of the wound the transverse branch of the external circumflex artery may be divided between two ligatures. The neck of the femur is then reached, and the capsule opened. If plenty of room is wanted, it is incised longitudinally from its upper limit downwards along the attachment of Bertini's ligament to the intertrochanteric line.

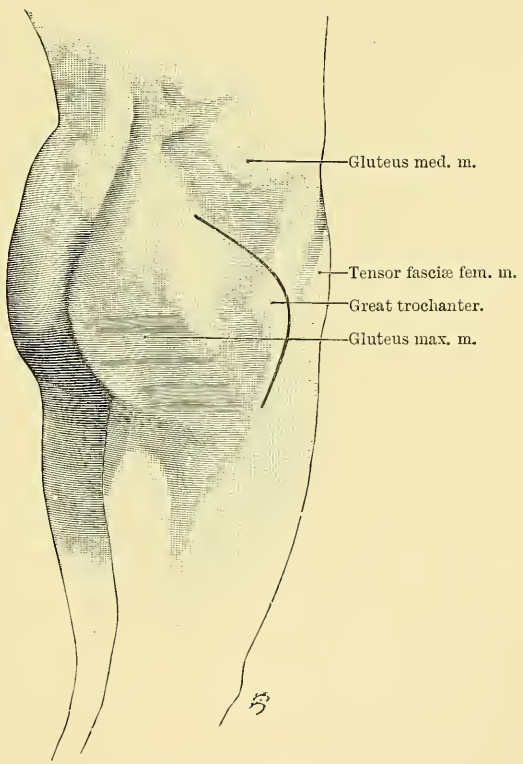

Fig. 167.—Incision for arthrotomy of hip.

This method allows of a simple or cuneiform osteotomy of the neck of the femur being performed, and we have employed it in the case of coxa vara. It can further be adopted in malunited fractures of the neck, for the removal of a focus of disease in the head and anterior aspect of the neck, and for making an acetabulum in a case of congenital dislocation of the hip. When, however, a thorough inspection of the joint has to be made, or when the capsule or part of the acetabulum has to be removed, it allows a very insufficient amount of space.

(*b*) *Posterior Method.* The posterior incision gives much more room, if the joint is to be freely exposed, especially if the following method is employed :—The incision is an angular (or curved) one, extending from the base of the outer surface of the great trochanter upwards to its anterior superior angle, and from thence obliquely upwards and backwards in the direction of the fibres of the gluteus maximus. The skin and fatty tissue are divided (Fig. 167). At the base of the trochanter branches of the external circumflex artery are divided and ligatured. The dense aponeurotic insertion of the gluteus maximus is now divided upon the outer aspect of the trochanter, exposing the periosteum and the insertion of the gluteus medius, which covers the

whole of its upper border, the detachment of the gluteus maximus being thus facilitated (Fig. 168).

The upper and back part of the incision divides the gluteus maximus in the direction of its fibres, and generally some vessels of considerable size, which must be ligatured. When possible, a still better plan is to expose the upper border of the gluteus maximus and to retract it downwards if it is weakly developed.

A fatty layer now appears, and after dividing it, the interval is reached between the lower border of the gluteus medius and minimus above, and the pyriformis below. The broad tendon of insertion of the gluteus medius (attached to the outer side of

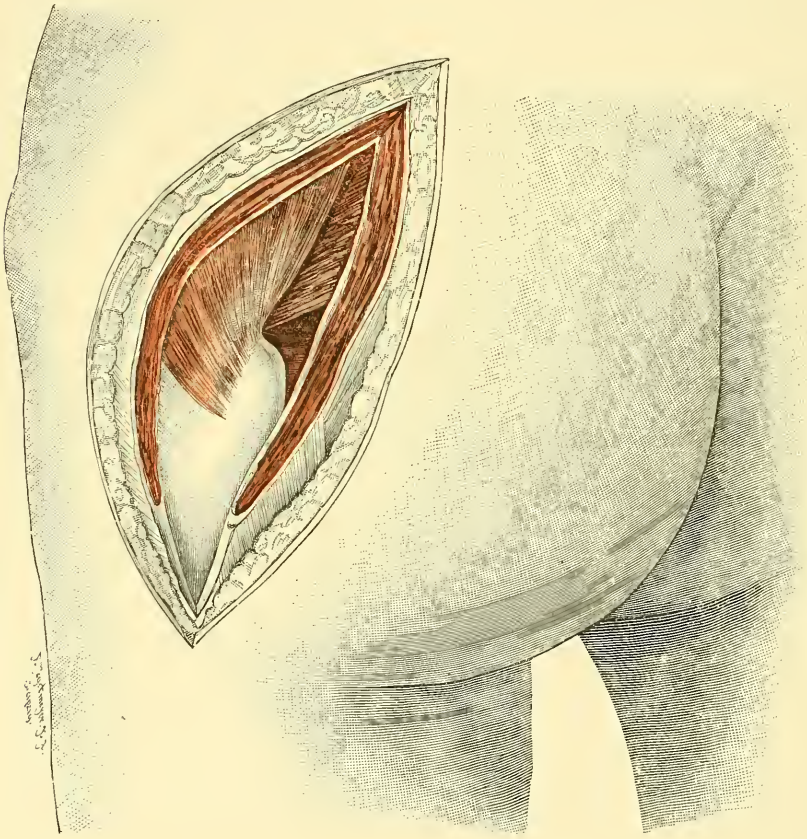

FIG. 168.—Arthrotomy of hip. The gluteus maximus and the dense fascia over the trochanter have been divided. The insertions of the gluteus medius and minimus are exposed.

the great trochanter), and under it the tendon of the gluteus minimus (attached to the anterior border of the great trochanter), together with the periosteum, are incised down to the anterior intertrochanteric line and detached forwards. The limb being flexed and rotated outwards, the ilio-femoral ligament is then separated from the anterior intertrochanteric line. The capsule is now divided along the upper border of the tendon of the pyriformis, and on flexing and rotating the thigh inwards the insertion of the pyriformis into the inner surface of the trochanter is detached along with the periosteum covering the bone. All the external rotators, along with the periosteum (or a superficial layer of bone), are then retracted backwards, beginning in front with the tendon of the obturator internus, the two gemelli, and the obturator

externus. In this way the periosteum covering the inner surface of the trochanter, together with the structures attached to its posterior surface, are reflected in their continuity (Fig. 169).

By this method the muscles supplied by the superior gluteal nerve, namely, the gluteus medius and minimus, are drawn forwards and upwards towards the tensor fasciæ femoris muscle, which has the same nerve-supply, and which, along with the glutei, is of special importance for the future abduction of the thigh; while the remaining muscles, the gluteus maximus, the pyriformis, and the obturators, which

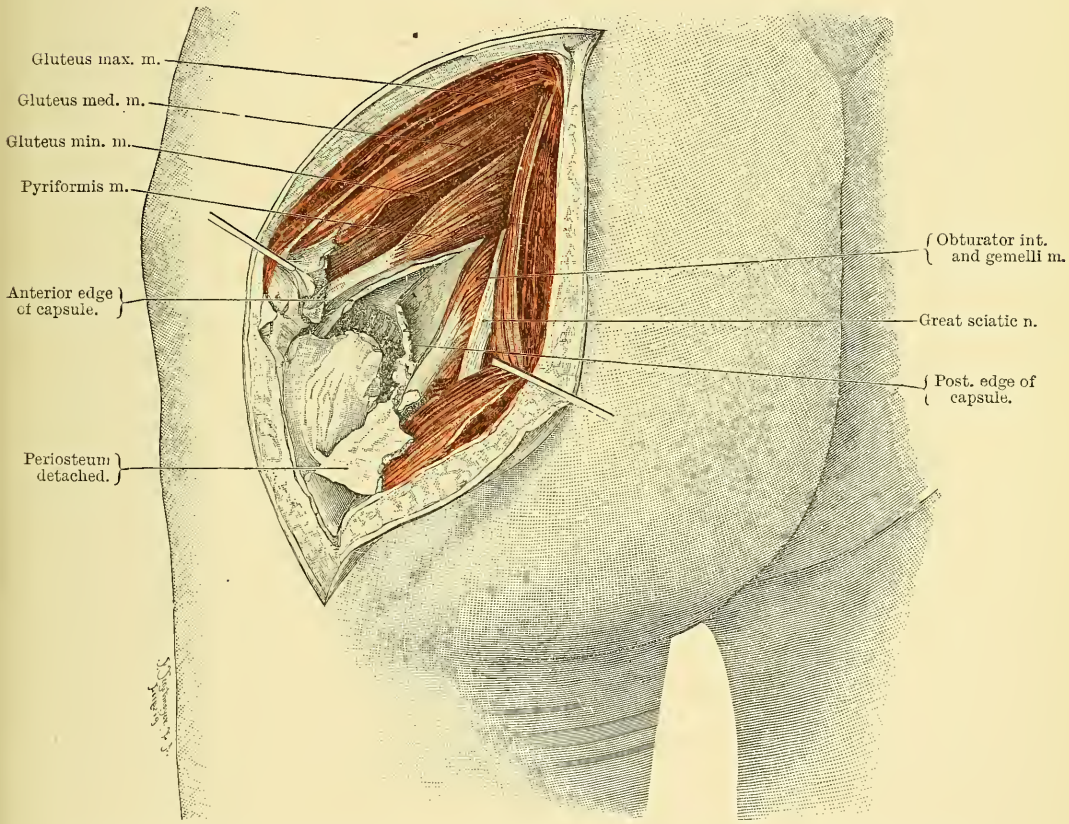

FIG. 169.—Arthrotomy of the hip. The capsule has been opened; the insertions of the gluteus medius and minimus, together with the pyriformis and periosteum, are detached in an upward and forward direction; the capsule, along with the periosteum and tendinous insertions of the obturator internus, gemelli, and obturator externus, is separated downwards and backwards.

are mainly supplied by the inferior gluteal nerve, are drawn downwards The pyriformis now and then receives a branch also from the superior gluteal nerve, which, however, is given off so high up that there is no fear of injuring it.

In this way also the entire posterior, external, and anterior surfaces of the head and neck of the femur, and as much as is necessary of the trochanter are exposed. One or two branches of the internal circumflex artery which run transversely over the capsule at the neck of the femur require to be ligatured; while the transverse branch of the external circumflex artery may also need similar treatment where it winds round the base of the trochanter under the vastus externus. As a rule it is sufficient to catch the small vessels with forceps and to twist them before closing the wound.

When the synovial membrane is tuberculous and has to be excised, it is easy, before opening the capsule, to dissect down accurately upon a large area of it from behind, and to separate it from its attachment to the acetabulum and neck of the femur, and thus to remove the posterior wall of the capsule *in toto*. The ligamentum teres is divided by cutting on to the head of the bone from behind and below, the limb being powerfully adducted, flexed, and rotated inwards. The head is then dislocated backwards, and the acetabulum rendered visible. The tuberculous tissue is now removed with scissors and forceps and scraped with a sharp spoon, while the wound surfaces are swabbed with a solution of carbolic and alcohol.



FIG. 170.

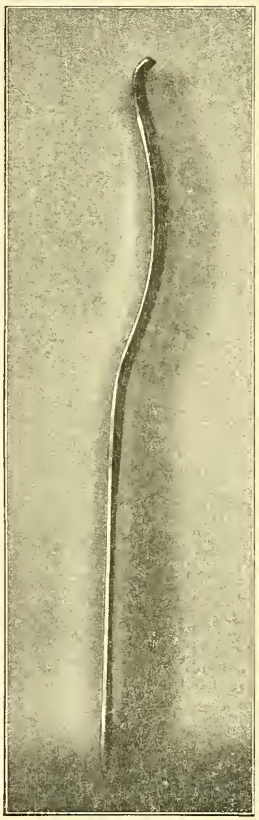

FIG. 171.

Scoop for the reposition of the head of the femur in the open operation for congenital dislocation of the hip.

Of the numerous methods employed for excising the hip we know of none which allows of such free inspection of the joint with so little injury to the muscles, nerves, and bone. It is a further development of Langenbeck's method by the oblique incision, which, however, does not admit of extirpation of the capsule alone with at the same time preservation of the bone. We shall therefore dispense with a comparison of this with other methods of operation.

If an arthrotomy is sufficient, or only bone is to be removed, the capsule is opened at once along the upper border of the pyriformis, from the acetabulum to the neck of the femur, and the capsule, periosteum, and muscular insertions are detached from the neck and the trochanter. The tendon insertions which have been detached subperiosteally (or along with a layer of bone), anteriorly, and posteriorly, are then replaced over the trochanter and sutured. Even when the disease implicates the anterior aspect of the neck of the femur, we have found this method better than an anterior incision.

Bardenheuer employs a still more drastic method by excising the joint completely together with the synovial membrane and capsule without opening the latter, *i.e.* by removing the head and neck of the femur and the acetabulum, and employing the Larghi-Sprengel transverse incision.

His method certainly ensures the most thorough removal of all the disease, but it necessarily entails sacrifice of the epiphysis and of bone which might have been preserved, since the synovial membrane envelops most of the neck of the bone.

As regards after-treatment, the ends of the bone must not be kept absolutely rigid, as is done in the knee with plaster of Paris, because here a movable joint is desired. The after-treatment is best carried out by weight extension, at the same time elevating the pelvis and maintaining both limbs in an abducted position. The initial dressing must consist of several layers of strongly-antiseptic gauze, which should not be changed

for eight to ten days. The drainage tubes should be wrapped in iodoform gauze wrung out of carbolic, and the wound covered with several layers of perchloride gauze, the skin being protected. The part is swathed in perchloride wool, which can be readily changed without interfering with the abducted position of the limbs.

25. Arthrotomy in Congenital Dislocation of the Hip. In the previous chapter we alluded to the anterior operation which is the one most popular with authorities on congenital dislocation, *e.g.* Hoffa and Lorenz. In our experience it has not afforded satisfactory results.

When an open operation is indicated, the posterior incision we have described provides the best access and consequently is most likely to prove successful. It has the further advantage that one may begin with a short incision. With the limb adducted and the head of the bone in consequence projecting posteriorly, an incision, 5 to 6 cm. (2 to 2½ inches) long, is made in the direction of the fibres of the gluteus maximus, the edges of which are held apart with two retractors and the joint is opened by cutting down on the thick capsule on the back of the dislocated head of the bone.

A lever, which we have found to be indispensable, is now forcibly pushed forwards towards the acetabulum between the head and the smooth surface of the dorsum ilii on which synovial membrane also extends, until it slips over the posterior margin of the acetabulum. At the same time by forcibly abducting the limb and rotating it outwards or very often inwards, the head of the bone which now rests in the hollow of the instrument is levered into the acetabulum by carrying the handle of the instrument forwards. The wound is simply closed with a continuous suture covered with collodion, and the limb is then put up in plaster.

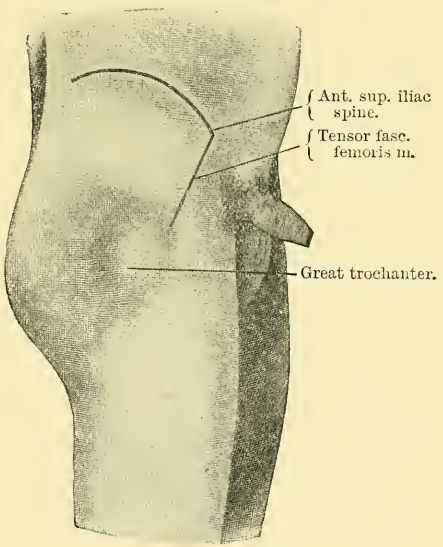

FIG. 172.—Sprengel's incision.

For long-standing non-congenital dislocations, Ollier and Mikulicz employ a transverse incision with its convexity downwards over the trochanter, the tip of which is chiselled off. Rydygier uses a similar flap and speaks with praise of the excellent access to the acetabulum obtained by cutting with the chisel right through the great trochanter above the trochanter minor.

26. Osteotomy of the Pelvis. To obtain free access to the outer surface of the ilium and to the upper and posterior aspects of the acetabulum, Sprengel has devised an incision which is deserving of notice, and which perhaps might be considered in connection with certain cases of congenital and old-standing dislocations. Sprengel has by this means cured obstinate cases of pelvic suppuration. It is, however, a more severe operation than our posterior method.

He carries an incision downwards from the anterior superior spine of the ilium between the anterior border of the tensor fasciæ femoris and the sartorius, dividing the dense fascia lata. A few small vessels are ligatured, and the wound is then extended backwards along the crest of the ilium, dividing the fascia and the origins of the gluteus medius and minimus, which are stripped off the pelvis with a sharp raspatory. By turning down a flap in this manner one obtains a very good view of the hip-joint and of the margin of the acetabulum. We once removed a traumatic exostosis from the acetabular margin by this method. The advantage of Sprengel's incision is that the entire soft parts together with the periosteum can be raised in a single piece.

27 Resection of Half the Pelvis. We first performed this operation in 1884 on a man, aged fifty-one, suffering from osteochondrosarcoma of the pelvis.

The tumour, which was first noticed six weeks after an injury, rapidly increased in size, and was attended with pain and interference with the joint movements. The right iliac fossa was almost entirely occupied by a large irregular, dense, hillocky tumour, covered here and there by a thin shell of bone and pushing the glutei before it, causing pain on pressure, and creaking on the hip-joint.

Fig. 173.—Excision of hip and innominate bone for a tumour of the pelvis.

At the operation (9th December 1884) the pubis and ischium were sawn through 2 cm. internal to the acetabulum, and the ilium was separated posteriorly at the sacro-iliac joint. The upper end of the femur had also to be resected.

On 19th January the patient was allowed to attempt walking, and on 16th March he was discharged, able to get about with the aid of crutches. His condition on 13th July 1888 (Fig. 173) was reported as follows:—Patient has been very well since the operation, and began to do light work one month after leaving hospital. He can now do light agricultural work, and can walk for an hour without fatigue.

He limps in the same way as a patient after excision of the hip, *i.e.* walks on the points of his toes and swings his leg forwards. The leg is in normal position and the knee can be fully extended. There is 4 ins. of shortening. Of passive movements there is a range of 270 degrees, and of active movements abnormal external rotation is possible. Normal active extension; passive hyperextension of 45 degrees. Passive abduction and adduction up to 70 degrees on both sides.

The upper end of the femur is only $1\frac{1}{4}$ in. from the middle line of the body, and is on the same level as the anterior superior spine of the ilium of the opposite side. The femoral artery is tortuous and pulsates strongly. The horizontal ramus of the pubis is $1\frac{1}{4}$ in. in length. The femur can be pushed upwards and downwards to the extent of an inch or so. There is a hernial protrusion of the abdomen the size of one's fist.

Soon after this case Roux performed a similar operation, and recently we have operated on another case in a boy, aged thirteen years, for sarcoma of the pelvis. The steps of the operation depend on the extent of the disease. In this case they were as follows:—An incision was made from the sacro-iliac joint along the crest of the ilium, and thence along Poupart's ligament.

After this incision the abdominal muscles are divided along their attachments to Poupart's ligament and the iliac crest, and the fascia transversalis and peritoneum are separated from the tumour as far as the large vessels (iliac artery and vein), which, with the anterior crural nerve, are retracted inwards. The smaller nerves (external cutaneous, etc.) have to be divided, the anterior and posterior circumflex iliac arteries being grasped with forceps.

The muscles which lie behind Poupart's ligament and external to the large vessels are then separated and divided. The rectus femoris, sartorius, tensor fasciæ femoris, and the iliac attachments of the gluteus medius and minimus are detached with a blunt instrument and divided as far back as the sacro-iliac joint.

The ilio-psoas and the capsule of the joint are then divided, while internally the pubis and ischium are exposed subperiosteally and cut through with forceps. A strong knife is then inserted into the upper part of the sacro-iliac joint, which is divided, and the innominate bone is dislocated downwards. The rest of the posterior surface of the pelvis is then exposed, and the attachments of the flexor muscles and the great sacro-sciatic ligament to the tuber ischii, and of the lesser sacro-sciatic ligament to the spine of the ischium, are divided. The bleeding, on account of the duration of the operation, is considerable, but none of the larger vessels are injured, and in our last case not a single vessel had to be ligatured. The wound, in the case of the boy, healed by first intention.

From our experience, in elderly and weakly subjects who do not survive operation, it appears to us to be an advantage, after detaching the abdominal muscles from the crest of the ilium and Poupart's ligament, and pushing back the fascia transversalis and peritoneum, to prevent excessive hæmorrhage by ligaturing, temporarily or permanently, the internal iliac vessels.

Partial excisions of the pelvis have been frequently performed (*vide* Gussenbaur, *on the Removal of Osseous Growths of the Pelvis*, 1891). Wilms has reported a case of Trendelenburg's where the entire anterior part of the pelvis was removed, after which the patient was able to walk about surprisingly well.

28. Resection of the Sacrum. We performed total resection of the sacrum for suppurative cario-necrosis in a woman aged thirty-seven, in December 1899, but she, unfortunately, died from cerebro-spinal meningitis. However, it is certain that the sacral canal and the sacral foramina can be opened and the cauda equina and nerves lifted out without any real harm. The woman had no muscular paralysis. The operation was performed with a knife and chisel.

(i) Operations on the Fingers and Hand

(*a*) *Preliminary Remarks on Operations on the Fingers.* The operations which the surgeon is called upon to perform on the fingers consist in the opening of abscesses, the removal of tumours, the resection of the small joints for acute necrosis of the articular extremities and for tuberculous arthritis, excision of an entire phalanx for tuberculous osteomyelitis (spina ventosa), and, lastly, amputations for injuries and gangrene of the fingers

While we are scarcely ever called upon to expose the small arteries and nerves, it is often necessary to make incisions so as to avoid them. As a rule, therefore, incisions, whether made merely through the soft parts, or in resecting the bones or joints, should be placed on the lateral aspects of the fingers: dorsal and palmar incisions are only made with the object of opening suppurating tendon sheaths, or for the purpose of suturing divided tendons. The chief mass of the subcutaneous soft parts of the fingers is made up of the tendons, which are absent upon the smaller lateral surfaces. The *flexor tendons* lie upon the periosteum. Opposite the middle phalanx the deep flexor tendons pass through those of the superficial flexors. The latter are crescentic on transverse section, with the convexity towards the bone, the former being cylindrical.

The two divisions of the flexor sublimis tendon, after embracing the tendon of the flexor profundus, are inserted into the lateral surfaces of the middle phalanx. The flexor profundus tendon, after passing through the slit in the flexor sublimis tendon, is inserted into the base of the terminal phalanx. As far as the bases of the terminal phalanges the tendons are enclosed in a fibrous tube continuous with the palmar fascia, and from the heads of the metacarpal bones downwards they are surrounded in addition by closed synovial sheaths, which, in the case of the thumb and little finger, approach and often communicate with the common flexor sheath in the palm. Vincula tendinum pass from the bones and the capsule of the joints to the under surface of the tendons.

The *extensor tendons* of the fingers are attached by some of their fibres to the

bases of the first phalanges, upon which they divide into three divisions. The tendons of the lumbrical muscles and interossei (flexors of the first and extensors of the second and third phalanges) pass under the lateral divisions to join the middle portion and to be inserted along with it into the base of the middle phalanx. The lateral portions, after extending laterally over the first interphalangeal joints, unite again upon the dorsum of the second phalanx and are inserted into the base of the terminal phalanx. All the extensor tendons are flat and fascia-like.

The extensor primi internodii pollicis is inserted into the base of the first phalanx of the thumb; the extensor secundi, placed somewhat dorso-ulnawards, is attached by all three divisions to the base of the terminal phalanx.

As the *terminal phalanges* have tendinous insertions only at their bases, incisions may be made anywhere according to the indications; that is to say, they may be placed either mesially or laterally.

The *digital arteries and nerves* give off branches which pass towards the dorsal aspect of the second and third phalanges. Lateral incisions over the middle phalanges are to be made nearer the dorsum, as the digital vessels and nerves come more into relation with the flexor tendons.

The palmar and dorsal digital vessels and nerves are of considerable size opposite the first phalanges, and here again the palmar vessels lie more towards the flexor tendons (the nerves being anterior to the vessels), so that incisions may be made laterally. Towards the base of the first phalanges, however, after the skin has been divided, the deeper incisions are to be curved towards the palmar aspect of the finger in order to avoid the broad tendinous insertions of the lumbrical and interosseous muscles. When a choice is possible, it is better to make an incision upon the ulnar rather than the radial aspect, because the lumbrical muscles (flexors of the first phalanges) wind towards the radial aspect of the finger.

(*b*) *Preliminary Remarks on Operations on the Hand.* Incisions are often required to be made in the hand in consequence of the frequency with which infective inflammations and abscesses are met with in this part of the body. The arteries, especially of the palm, are large enough to allow of the direct application of a ligature. Besides the incisions necessary to evacuate deep collections of matter, and for the ligature of the vessels, there are those required in operating on the tendons of the hand, be it for inflammatory affection of their sheaths or for suturing wounded tendons.

On the dorsum we have to deal only with tendons and nerves which for the most part can be felt through the skin, and hence serve as guides in making incisions. Large vessels are only met with behind and along the metacarpal bone of the thumb, and these, like the nerves, can be felt through the skin.

On the back of the hand a line drawn along the middle of the third digit up to the wrist separates the areas supplied respectively by the radial and ulnar nerves. The dorsal carpal arch and the metacarpal arteries are comparatively small vessels.

The extensor tendons at the wrist have for the most part separate synovial sheaths which extend downwards as far as the middle of the metacarpus. On the dorsum of the hand the radial nerve can be felt over the base of the second metacarpal bone, and the dorsal branch of the ulnar nerve over the base of the fifth metacarpal. In the interval between the first and second metacarpals, on the dorsum, the radial artery can also be traced upwards upon the base of the first metacarpal and then upon the trapezium.

The radial vein is visible as it ascends across the hollow between the tendons of the extensor secundi and extensor primi internodii pollicis.

Examination of the Structures which can be felt beneath the Skin. In the palm the vessels and nerves run in the intervals between the metacarpal bones, while the tendons are placed over them: all lie under the strong palmar fascia which gives off processes to join the tendon sheaths upon the fingers. Between the processes the fascia ends in concave arches which, by means of the septa passing from them to be attached to the deep transverse ligament, serve to separate the flexor tendons and lumbrical muscles from the digital vessels and nerves.

Under the palmar fascia is the bundle of flexor tendons with the lumbrical muscles,

surrounded by a synovial sheath which reaches from the ends of the bones of the forearm downwards to the middle of the metacarpus. The flexor longus pollicis possesses a sheath of its own. Under the tendons is a thin deep fascia which covers the interosseous muscles and the bones.

As landmarks for incisions in the region of the wrist, the following are to be mentioned: the *pisiform bone*, with the insertion of the flexor carpi ulnaris, and the ulnar vessels and nerve, which may be felt in contact with its radial aspect: upon the ulnar side of the wrist-joint below the pisiform bone the projecting body of the *unciform bone*, upon which the dorsal branch of the ulnar nerve can be felt: a thumb's-breadth below, and somewhat to the radial side of the pisiform bone, at the radial edge of the hypo-thenar eminence, is the *hook of the unciform*, below which the

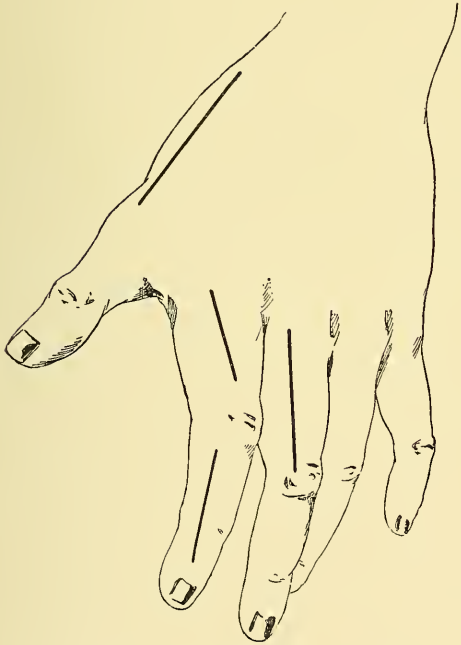

FIG. 174.—Excision of the phalanges and 1st metacarpal bone.

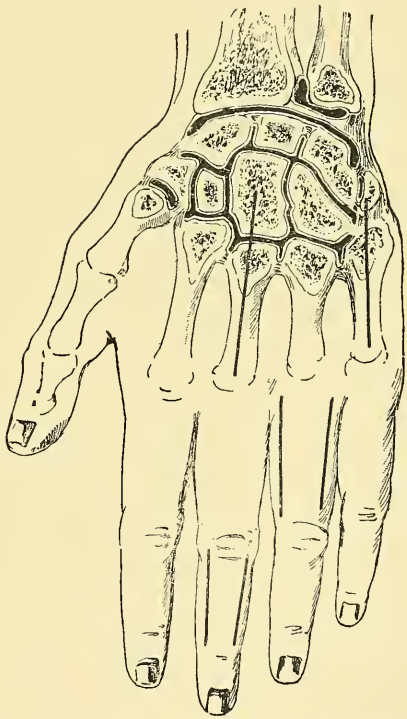

FIG. 175.—Excision of the phalanges and metacarpal bones. (Coronal section of the wrist, after Henle.)

deep branch of the ulnar artery and nerve curves round: the superficial sensory division of the ulnar nerve can be felt through the skin and rolled from side to side over the hook of the unciform: lastly, immediately above the ball of the thumb is the projection of the *os trapezium*, over which the superficial volar branch of the radial artery, which may be felt through the skin, descends to complete the superficial palmar arch. Two fascial envelopes surround the wrist, one a part of the general fascial envelope thickened by transverse fibres, the other situated deeply around the ligaments of the wrist-joint. Besides these, upon the palmar aspect is the strong anterior annular ligament which bridges over the tendons occupying the hollow of the carpal bones, and gives origin to some of the muscles of the thumb.

29. Excision of Phalanges and Metacarpal Bones, of Interphalangeal and Metacarpo-phalangeal Joints (Figs. 174 and 175). For the phalanges and their joints, lateral incisions are made, and for the metacarpal bones, dorsal incisions. The

incisions upon the fingers are placed near the dorsum, and this is to be the more particularly attended to the farther they extend towards the tips. In the case of the fingers it is desirable in removing a bone to make bilateral incisions, in order to prevent unilateral contraction of the scar and consequent lateral bending of the finger. The extensor tendons and nerves on the dorsum are to be avoided, the incisions being made over the bones where they can be felt beneath the skin.

When not contraindicated, the subperiosteo-capsular resection is to be performed. The head of the bone is first exposed because it can be more easily rendered movable.

In the case of the metacarpal bone of the thumb, the extensor brevis pollicis along with the periosteum is detached to one side, and the muscles of the ball of the thumb are detached to the other, the tendon of the extensor ossis metacarpi pollicis being separated from the base of the bone. In the case of the remaining metacarpal bones, the interosseous muscles are separated along with the periosteum. The carpo-metacarpal joint of the thumb is the only one with a separate synovial membrane, the others being continuous with the intercarpal joints.

(k) Operations on the Forearm

Incisions have to be made on the forearm to ligature wounded vessels, to suture nerves and tendons, and, not infrequently, to resect or suture fractures, and in the treatment of pseudarthrosis, as well as to open deep-seated abscesses under the muscles (associated with suppuration in the tendon sheaths), and under the periosteum in osteomyelitis.

Incisions on the *flexor surface* of the forearm should be made so as to avoid, on the one hand, the radial artery and radial nerve, and, on the other hand, the median nerve and the anterior interosseous nerve and artery.

The whole length of the radius and the interosseous membrane may be cut down upon without fear of injuring the nerves by an incision between the supinator longus and the flexors, as this is the frontier line between the structures supplied by the different nerves. The best plan is to pass down between the supinator longus and the flexors, and then to free the radial nerve on its outer side so that it may be retracted inwards along with the radial artery. In the lower third of the forearm the radial nerve must be left to the outer side of the incision, because here it leaves the radial artery to pass on to the dorsum of the wrist. In this way we recently exposed the whole length of the medullary canal of the radius in a case of diffuse osteomyelitis. At the upper end of the wound the fibres of the supinator brevis are detached and retracted outwards, while those of the pronator quadratus at the lower end are detached inwards. If it be necessary to expose the interosseous membrane from the radius, the muscles attached to the radius must be divided and separated, viz. the pronator radii teres in the middle third, the radial attachment of the flexor sublimis digitorum below it, and behind it the flexor longus pollicis. In the lower half of the arm the interosseous membrane can be reached from the inner side of these muscles without interfering with their attachments, because at this level there are no branches of the median nerve to injure. In the upper half of the forearm, after division of the pronator radii teres and flexor sublimis digitorum, it is a good plan to free the median nerve and then to pass to its outer side, as if in search of the anterior interosseous nerve. By dissection down to the radius and the interosseous membrane to the outer side of the last-mentioned nerves, the only branch likely to be injured is the one going to the flexor longus pollicis. Abscesses situated deep down on the interosseous membranes are not infrequently met with as the result of extensive suppuration beginning in the tendon sheaths of the hand.

Incisions on the *extensor* surface of the forearm, the muscles of which are supplied by the posterior interosseous nerve, may be made along the whole length of the ulna, as the dorsal branch of the ulnar nerve pass under the flexor carpi ulnaris quite at the lower end of the ulna. Further, this incision lies along the radial border of the extensor carpi ulnaris, which receives its nerve-supply at a higher level. Incisions

may be made on the radial side in a line from the head of the radius to its styloid process, but commencing $2\frac{1}{4}$ ins. below the head of the radius so as to avoid injuring the posterior interosseous nerve as it pierces the supinator brevis, the incision passing down between the radial extensors of the wrist and the extensor communis digitorum. After retracting the radial extensors outwards and the common extensor inwards, the extensors of the thumb are exposed with the posterior interosseous artery lying in the interval between the abductor longus pollicis (the muscle placed farthest to the radial side) and the extensor longus pollicis. In the lower half of the forearm, where the radial extensors appear from under the obliquely-placed extensors of the thumb, the radius must be cut down upon between the latter and the tendon of the supinator longus, the dorsal branch of the radial nerve being avoided. In the lower third, to the ulna side of the muscles of the thumb, incisions may be made between all the tendons on the posterior surface, because there are here no vessels or nerves to be avoided.

30. Osteotomy and Resection of the Ulna. The ulna lies subcutaneously along the whole length of the forearm, in the interval between the flexor and extensor carpi ulnaris muscles. It can therefore be excised either partially or completely without any difficulty and without injury to the surrounding structures. Staphylomycotic and tuberculous ostitis are not infrequent indications, while in fractures of the upper third of the bone, it may be necessary to wire the fragments in order to secure satisfactory coaptation.

31. Osteotomy and Resection of the Radius. The radius is much less easily accessible than the ulna. The head of the radius can always be felt under the skin at the outer part of the posterior surface of the elbow, and can therefore be resected by a part of the incision, the direction and position of which is fully described in our method of excision of the elbow.

The middle third of the diaphysis may be felt upon the posterior surface of the limb between the radial extensors of the wrist and the extensors of the fingers. It may be cut down upon here without fear of vessels, nor do the branches of the nerves come into question, as the adjacent muscles receive their nerve-supply higher up. The upper third of the radius is covered by the supinator brevis muscle, through which the posterior interosseous nerve passes backwards. The lower third, besides being covered by the supinator longus and the two radial extensors, which run all the way along it, is also covered by the pronator quadratus, and by the extensors of the thumb which pass obliquely over its postero-external aspect.

An incision extending down to the radius in its whole length is only possible along the line for ligature of the radial artery, by drawing the radial nerve to the outer, and the radial artery to the inner side. In the upper third the nerve lies well to the radial side of the artery; in the lower fourth it winds to the dorsal aspect of the wrist. In recent as well as old fractures of the radius, it may be necessary to perform osteotomy and wire the fragments, as otherwise fractures in the upper and middle thirds often unite very unsatisfactorily.

(l) Operations at the Elbow

Operations in the region of the elbow mainly comprise incisions into the joint for resection or for suturing the bone. It is only on its postero-lateral aspect that the joint is readily reached without danger of injuring neighbouring structures: hence this site is chosen for opening the elbow-joint, and we prefer our curved lateral incision. It is only in the region of the supracondyloid ridges that the humerus is so superficial that it can be cut directly down on without hesitation. The best guide to the level of the joint is furnished by the head of the radius, felt from the postero-external aspect. Other important landmarks are the two epicondyles and the olecranon process.

The tendon of the biceps can be easily felt at the front of the elbow with the pulsation of the brachial artery on its inner side. Lying behind the internal epicondyle

is the ulnar nerve. In most people the median basilic vein, which is selected for venesection, is generally visible at the bend of the elbow.

32. Arthrotomy, Resection, and Arthrectomy of the Elbow. In arthrotomy and excision of the elbow-joint, just as in all other joints in which a free exposure of the cavity is desired in order to remove accurately all diseased tissues, we adhere to the principle of making a somewhat more complicated skin incision, in order not only to preserve all the muscles along with their attachments, but especially also to spare the nerves which supply them. This was the main reason why we employed the posterior curved incision for arthrotomy of the shoulder, and why we subsequently also modified the methods which had been employed for excision of the elbow.

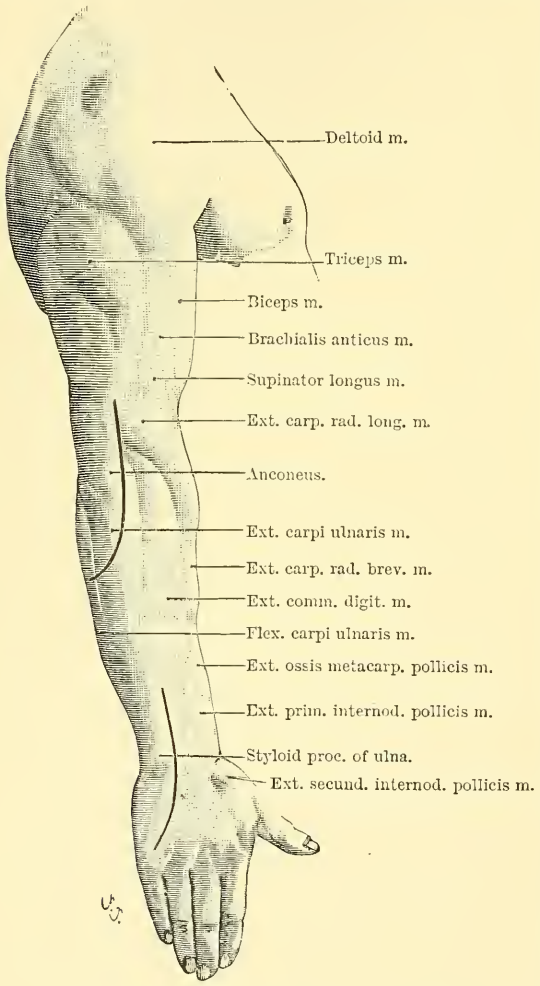

Fig. 176.—Arthrotomy of the elbow and wrist.

To begin with, we employed the simple method of Langenbeck with a posterior longitudinal incision, which was re-introduced by Treves, Park, and Maisonneuve; but we found, especially in tuberculous disease which was localised in or had extended to the region of the head of the radius, that the access was not so satisfactory. Ollier's bayonet-shaped incision is an excellent method for gaining this access, but it has the disadvantage of throwing the anconeus out of action. It is true that the oblique middle portion of Ollier's incision extends through the interval between the outer head of the triceps and the anconeus; but as the branch from the musculospiral nerve which supplies the latter muscle descends as an outrunner from the branch supplying the outer head of the triceps, it is necessarily divided, with the result that the anconeus atrophies. As it is our special duty in the case of the elbow to obtain an actively movable joint, the function of the anconeus ought to be preserved, as it serves to stretch and fix the capsule of the joint. We attain this by the following method of operation:—

With the elbow flexed to an angle of about 150°, an angular incision (Fig. 176) is, like Ollier's incision, begun at the external supracondyloid ridge 3 to 5 cm. (1½ to 2 in.) above the line of the joint, and is carried downwards practically parallel to the axis of the humerus, *i.e.* vertically downwards to the head of the radius, and from thence along the outer border of the anconeus to the posterior border of the ulna, 3 inches below the tip of the olecranon; finally, the incision terminates by curving inwards over the inner surface of the ulna. The first part of the incision extends down to the outer border and external condyle of the humerus, between the supinator

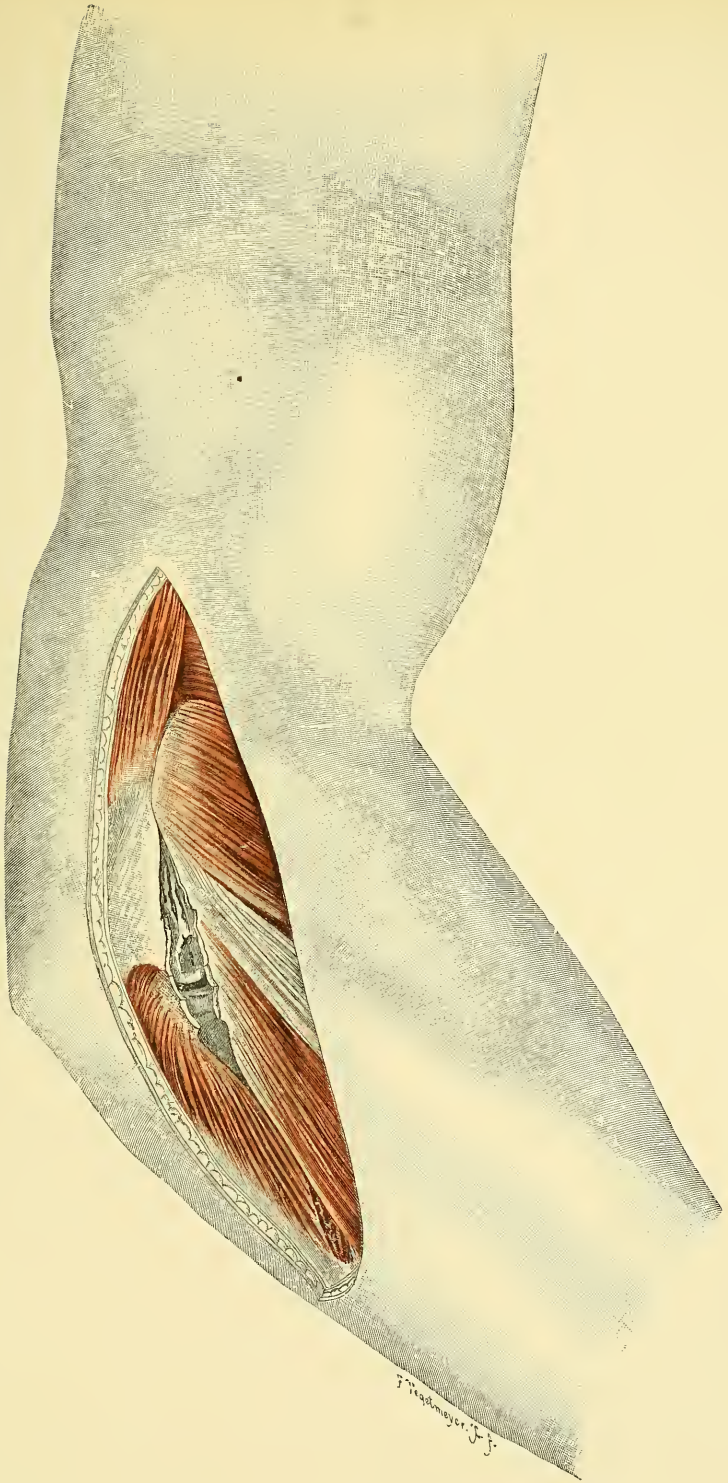

FIG. 177.—Arthrotomy of the elbow. The incision has been made through the skin and fascia down to the bone, in the interval between the triceps (posteriorly) and the supinator longus and extensor carpi radialis longior (anteriorly); lower down it has been carried through the capsule down to the head of the radius, while in the lowest part of the wound it has passed down to the ulna between the anconeus (posteriorly) and the extensor carpi ulnaris (anteriorly). The lowest fibres of the anconeus have been divided.

longus and radial extensors anteriorly, and the edge of the triceps posteriorly; below the external condyle it passes down to the bone between the extensor carpi ulnaris and the outer border of the anconeus, and divides the strong capsule over the head of the radius together with the annular ligament at its attachment to the ulna. The lower end of the incision divides the lower fibres of the anconeus transversely at their attachment to the posterior border of the ulna, because the muscle extends for a considerable distance down the forearm. The incision, therefore, falls accurately along the interval between the muscles supplied by branches of the musculo-spiral

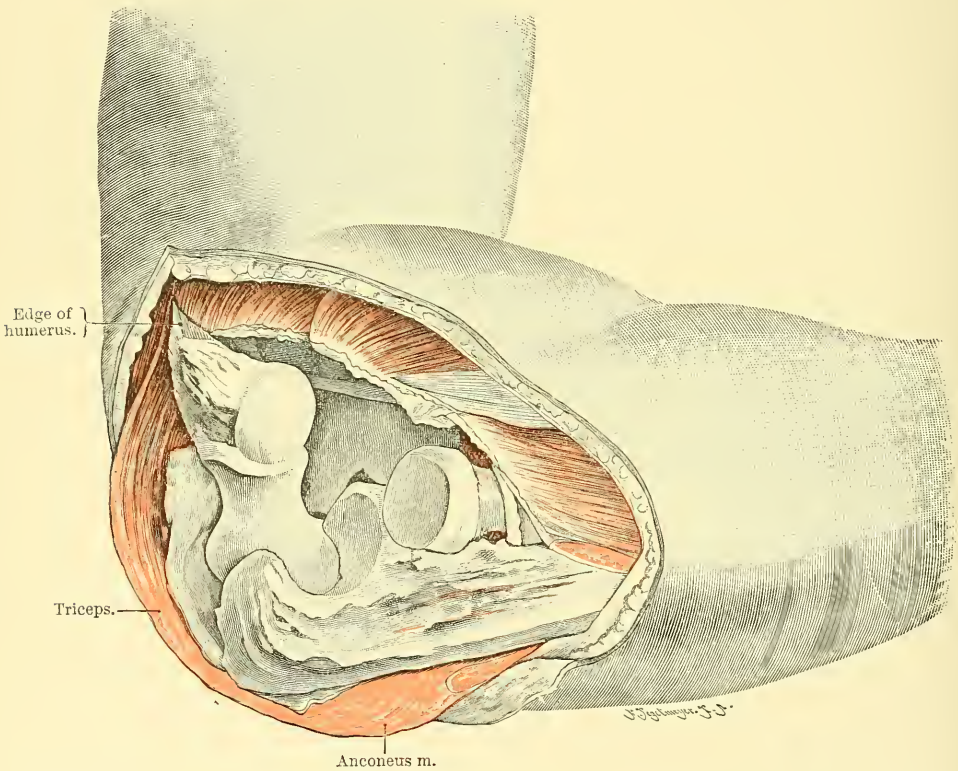

FIG. 178.—Arthrotomy of the elbow after the forearm has been dislocated inwards. The outer surface of the ulna is exposed with the anconeus detached from it. The cut surface of the anconeus is seen below. In the upper part of the wound the supinator longus is seen detached subperiosteally (or subcortically) from below upwards, as are also the extensor carpi radialis longior and brevior, extensor communis digitorum and extensor carpi ulnaris.

nerve and those supplied by the posterior interosseous, thus avoiding the possibility of subsequent muscular atrophy. The bone having been exposed and the capsule divided, the outer head of the triceps, together with the periosteum and the upper attachment of the capsule, is detached subperiosteally from the humerus, the anconeus from the posterior surface of the ulna, the insertion of the triceps from the tip of the olecranon, and the triceps-anconeus flap is (the joint being extended) displaced over the olecranon to its inner side. The external lateral ligament, with the attachments of the extensor tendons and the capsule attached to the external condyle, are separated subcortically with a sharp raspatory from below by means of a chisel and drawn forwards. The joint has now become so movable that the forearm can be

completely dislocated inwards (Fig. 178). The whole extensor apparatus, both as regards muscles and nerves, is preserved in its continuity, and the internal lateral ligament is still intact. If complete resection is to be performed, after dislocating the joint as above described, the internal lateral ligament is separated subperiosteally along with the muscles from the inner border of the ulna and the internal condyle of the humerus, and the ends of the bones are removed. In separating the lateral ligaments it is better to remove a shell of bone along with them, so as to preserve their attachment to the periosteum.

For many years we have been in the habit of making curved sawn surfaces in performing excisions; here not, as in the knee, merely to join the bones firmly together, but also in order to ensure an angular movement (flexion and extension) at the new joint. It is especially important to saw the olecranon in a curved direction, in order to preserve a lever into which the triceps is inserted. This goes a long way towards preventing partial dislocation forwards of the forearm.

We have already stated that as compared with the simple posterior longitudinal incisions, of which Langenbeck's is the most generally employed, the curved incisions, especially advocated by Ollier, have the great advantage of giving more room and better exposure of the joint, especially in the region of the head of the radius. It is not very likely that any one will care to employ transverse incisions (straight or curved), either alone or combined with one or two longitudinal incisions. The main directions of the incision must always be longitudinal if the muscles and their nerves are to be preserved. The only method which we need refer to is that of Auguste Nélaton, which is mentioned by Farabœuf. It has nearly the same direction as our incision, being carried longitudinally over the external condyle of the humerus and then bending at a right angle from the head of the radius towards the ulna. Nélaton's object in employing this incision is to thoroughly expose the head of the radius, but, like Ollier, he pays little attention to the preservation of the anconeus. Hueter, and, according to Farabœuf, Marangos have also recommended skin incisions which are allied to ours, but planned with a different object. Compared with our own method, the lateral transverse incision of Cavazzini is the reverse of an improvement, because it divides the anconeus transversely. He, however, dislocates the joint in the manner we have advised.

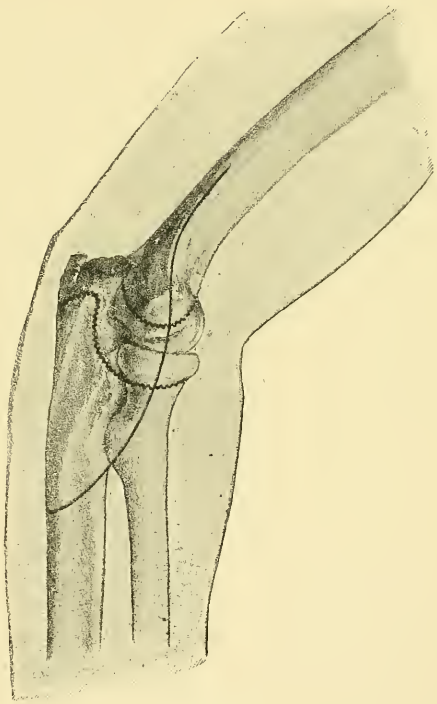

Fig. 179.

No other incision gives equally good access to all parts of the joint with so little injury and with such complete preservation of the important extensor apparatus. Moreover, after making the incision it allows us, better than other methods, either to completely expose (from the outside) and excise the capsule, or to resect the bones subperiosteally, because the incision only lies over the capsule for a short part of its extent.

For cases in which the disease is confined to the olecranon, the simple posterior longitudinal incision of Langenbeck has the advantage that it is carried directly down upon the seat of disease. When the disease is limited merely to the external condyle

or the head of the radius, Cavazzini's transverse external incision is occasionally of value. In all cases, on the other hand, where a thorough view into the joint is desired, our method above described has great advantages, while it is always more advisable to make it a rule to open into the joint.

After-treatment and Results of Resection of the Elbow. In the elbow more than in any other joint one can count with greater certainty on obtaining a freely-movable joint, provided the disease has been thoroughly removed and a mechanically sound new joint has been constructed. No plaster bandages are requisite, as active movements will be resumed in a few days. The forearm must, however, be placed in correct position, as the upper arm has a tendency to become rotated outwards and abducted. It should not be bandaged to the body in the position of adduction and pronation as is the usual practice, but should be placed so that the ends of the radius and ulna are in contact with the end of the humerus (which is rotated outwards). The forearm is simply placed vertically upright and is held in position by means of a curved splint.

In tubercular cases the surface of the wound should be swabbed with an alcoholic solution of carbolic and either thoroughly smeared with freshly-sterilised iodoform powder or paste after the bleeding has been carefully stopped, or the cavity of the wound may be filled with Mosetig's iodoform filling. A drain is inserted through a special opening on the anterior aspect of the joint. If the operation has been strictly aseptic, drainage may, however, be dispensed with, after the joint has been filled with the above-mentioned paste.

When resection has been undertaken for an old-standing dislocation, the sawn surface of the humerus should be smeared with iodoform paste and active movements begun as soon as possible. The same remark applies to the radius and ulna, but as a rule one tries to avoid sawing off the articular ends of the bones of both the upper and forearm. Apart from faulty division of the joint surfaces, neglect of starting active movements at an early stage must be regarded as a frequent cause of subsequent stiffness.

In tubercular cases complicated by mixed infection (sinuses) and also in those cases in which conservative treatment has been persisted in for too long a period, and where the proper time for operation has expired, it is best not to attempt to obtain a movable joint, but to treat the wound by the open method with iodoform plugging and procure solid bony union.

During the after-treatment the upper arm should be laid flat on a table, and while the patient holds it steady with his other hand, he at the same time carries out movements with the forearm which is in the upright position. The movements may be guided by means of an elastic apparatus. Passive movements are decidedly harmful.

Mention must lastly be made of the method which Quénu recommends for obtaining mobility in an ankylosed joint, *i.e.* by the interposition of a portion of the joint capsule and aponeurosis. The technique, however, must be decided in each individual case.

The best results are obtained by interposing the brachio-radialis muscle (supinator longus). It should be detached from the external supracondylar ridge and stitched to the inner side of the triceps tendon, a flap of periosteum being also placed over the joint surface. In tubercular cases it may be necessary to ensure mobility by interposing a layer of deep fascia.

(m) Operations on the Upper Arm

Very extensive operations have often to be performed on the upper arm for necrosis, for tumours of the humerus, and for pseudo-arthrosis. In 1898 we completely excised the humerus for diffuse sarcoma. The operation is done with least injury to the adjacent structures by making an incision upon the outer aspect of the humerus from the anterior border of the deltoid downwards along the external bicipital sulcus. In the upper part of the wound the cephalic vein is drawn inwards, and the anterior circumflex artery is ligatured below the head of the humerus. The lower part of the

incision is carried down to the bone between the outer head of the triceps and the brachialis anticus, the musculo-spiral nerve and inferior profunda artery being retracted posteriorly.

It is satisfactory to note that Rolando (*Clin. chir.*, Milano, 1904) has arrived at an incision which corresponds in every detail with that we have described.

On the inner aspect of the limb the bone is reached alongside the main vessels and nerves (median and ulnar), which are drawn inwards, but the dissection cannot be carried as far upwards and downwards as on the outer aspect. An incision is therefore only made along the internal bicipital furrow with the object of exposing the vessels and nerves or excising limited growths, *e.g.* a diseased lymphatic gland above the internal epicondyle.

In the case of a large osteochondroma of the humerus for which two other authorities had advised disarticulation of the arm, we succeeded in removing the tumour by the two incisions mentioned, and retaining a useful arm.

The best landmarks in examining the upper arm are the internal and external bicipital sulci: the biceps and the long head of the triceps can be gripped between the fingers and raised up from the bone.

The brachial artery can be felt in the entire length of the upper arm along the internal bicipital sulcus, from the head of the humerus, which can be palpated through the axilla, down to the middle of the bend of the elbow: the median nerve, which crosses the middle third of the artery from without inwards, can also be felt, while the artery can be compressed in its whole length against the biceps.

33. Osteotomy and Resection of the Diaphysis of the Humerus. For purposes of excision the relations of the humerus are not so simple as those of the femur. The removal of the upper and lower ends of the bone is considered with excision of the respective joints. The most important relation to be borne in mind is the musculo-spiral nerve, which winds round the posterior and outer aspects of the shaft.

It is mainly in osteomyelitis and fractures of the humerus, pseudoarthrosis (particularly common in this region) and malunited fractures, that the operation is indicated, *e.g.* for adhesions and paralysis of the musculo-spiral nerve.

The external bicipital sulcus is the only line along which the entire length of the diaphysis may be exposed. The circumflex vessels and nerve are to be avoided at the surgical neck. The fascia of the deltoid is divided in order that (the arm being abducted) its anterior border may be drawn outwards; next, the fascia covering the biceps is divided and the bone reached along the outer borders of the coraco-brachialis and brachialis anticus muscles. The musculo-spiral nerve and the accompanying superior profunda artery lie to the outer side, whilst, in the lower third, the musculo-cutaneous nerve, which descends between the biceps and brachialis anticus, is drawn inwards.

(n) Operations at the Shoulder

Operations in the region of the shoulder are most frequently performed in order to open the shoulder-joint, and to remove tumours, especially glandular swellings, from the axilla. The incisions are usually made along the anterior and posterior edges of the deltoid, which can be easily felt. If this does not give enough room, an additional incision may be made along the origin of the deltoid from the acromion process and clavicle, or along the spine of the scapula (see the anterior and posterior incisions for excision of the shoulder described on pages 320 and 322). The axilla may be opened up by an incision parallel to the furrow between the upper arm and thorax, *i.e.* crossing the folds of the axilla (sagittal incision), this latter incision giving good access to the axillary space without injuring the deeper structures. On bringing the arm to the side, the edges of the wound come together naturally, so that sutures are unnecessary. The sagittal axillary incision is especially useful for tumours of the glands, as well as for exposing the lower border of the glenoid cavity and the head of the humerus, when the latter has been dislocated forwards. In making the incision the arm should be well abducted.

34. Arthrotomy, Arthrectomy, and Resection of the Shoulder-Joint. (*a*) *From the front*—in disease of the head of the bone, or in old-standing anterior dislocations (Figs. 180 and 181).

The head of the humerus overlaps the glenoid cavity to a considerable extent anteriorly. The diameter of the latter in the horizontal direction is only half that of the cartilaginous portion of the head; so that to expose the head from the front is easy, while exposure of the glenoid is difficult. The simplest method is by the anterior longitudinal incision employed by Baudens, Malgaigne, Roeret, Dubreuil, and developed especially by Langenbeck and his pupils. The improvement by Hueter, Ollier, Chauvel, and Spence, which consists in making an oblique incision to preserve the deltoid (instead of the vertical incision downwards through it from the acromion), appears to be the most rational procedure, because this muscle plays the chief part in the subsequent movements of the arm.

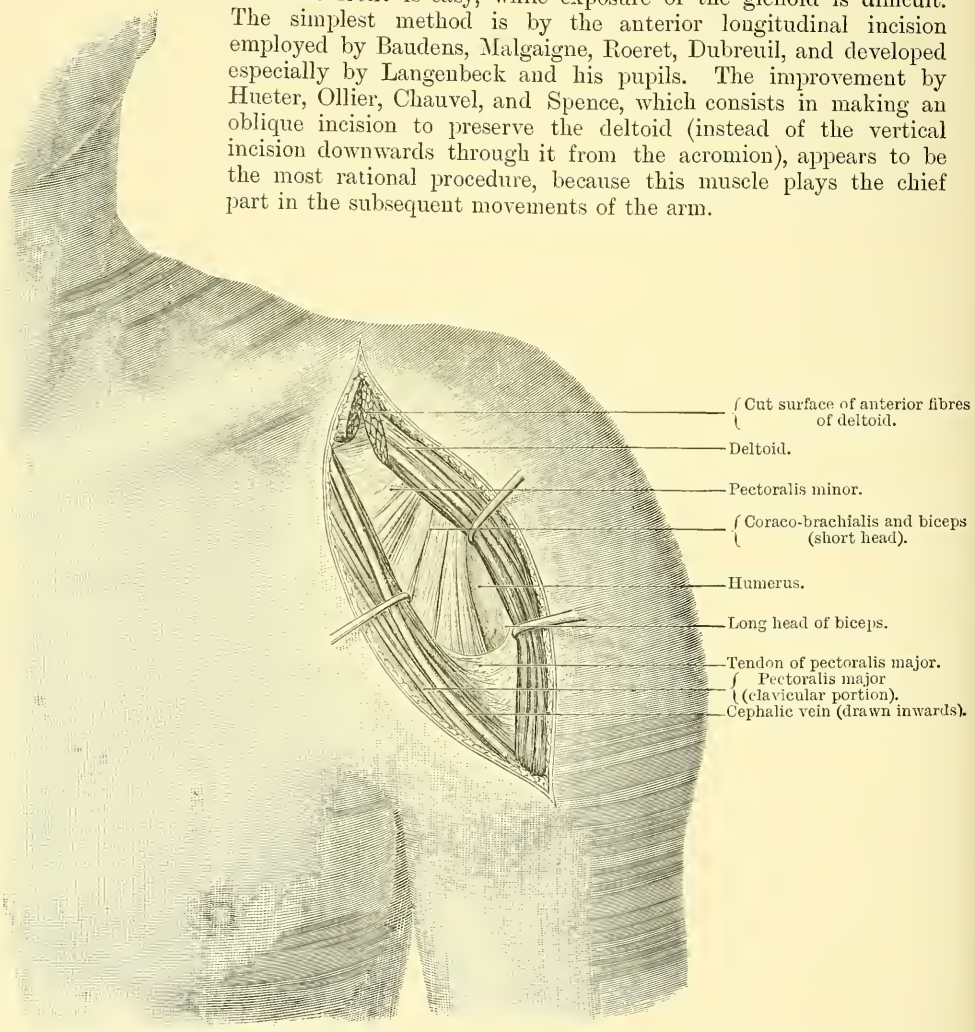

FIG. 180.—Excision of the head of the humerus by the anterior oblique incision (called by Esmarch, Ollier's method).

The incision begins upon the clavicle above the coracoid process, and passes downwards along the anterior border of the deltoid. The edge of this muscle, which lies close to the clavicular portion of the pectoralis major, is recognised by its relation to the cephalic vein, which is drawn inwards along with the pectoral muscle, the deltoid being drawn outwards. The upper and anterior fibres of the latter muscle are divided close to the clavicle, and a branch of the acromio-thoracic artery which lies under it is ligatured.

The muscles attached to the coracoid process, viz. the pectoralis minor, the short head of the biceps, and the coraco-brachialis, now appear, in front of which, at the lower part of the wound, the upper edge of the smooth tendon of the pectoralis major is seen passing to its insertion into the humerus. The arm being slightly rotated inwards, the sheath of the biceps tendon is opened by cutting down to the bone at the outer border of the above muscles, where the bicipital groove may be distinctly felt. The sheath is now slit up along with the capsule as far as the edge of the glenoid, and the tendon which is thus freed is drawn inwards. The biceps tendon is exposed, not only that it may be preserved, but in order that the upper end of the bone may be rendered accessible along the line of the

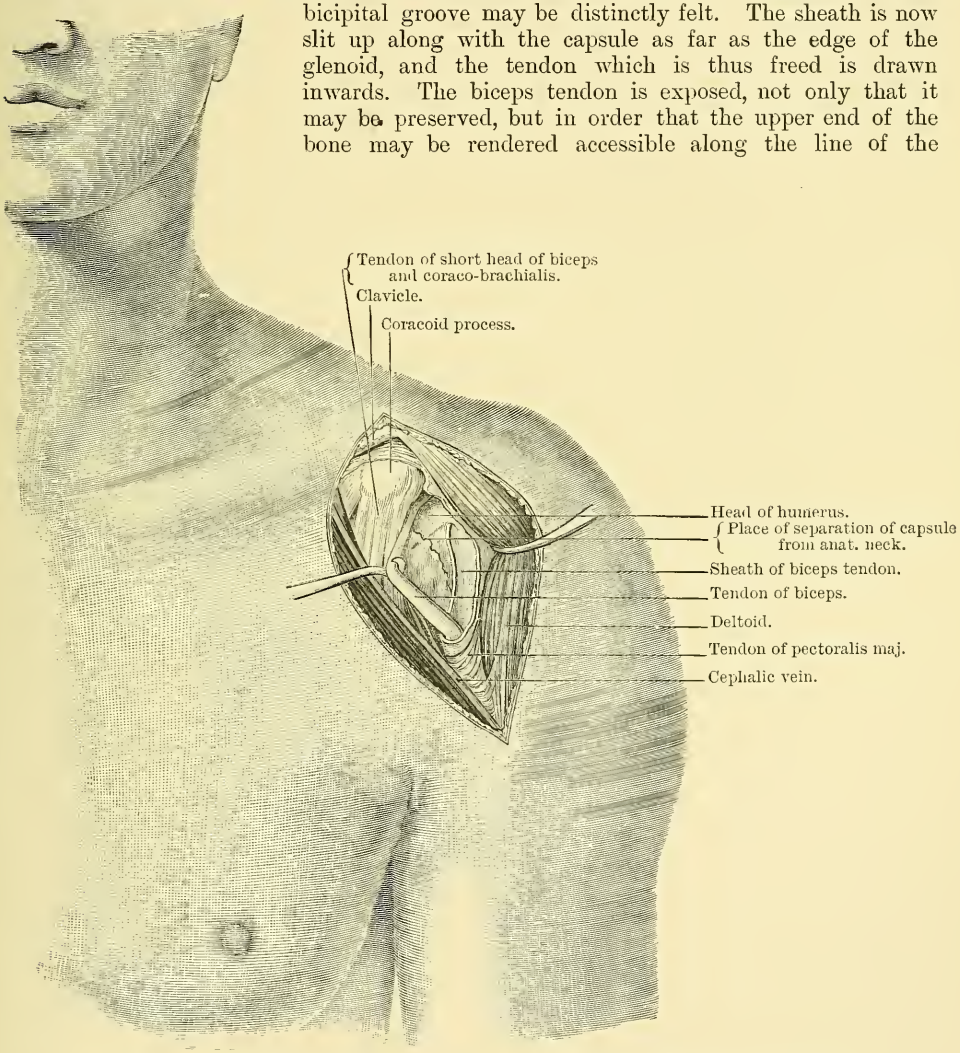

FIG. 181.—Excision of the head of the humerus by the anterior incision. Second stage: the biceps tendon is lifted out of its sheath, and the joint is opened.

bicipital groove which corresponds to the boundary between the attachments of the anterior and posterior muscles. The tendons which are inserted into the upper end of the humerus and the capsule, viz. the subscapularis into the lesser tuberosity, the supraspinatus, infraspinatus, and the teres minor into the greater tuberosity, are now separated close to the bone by means of vertical cuts made parallel to the bicipital groove. In doing this the humerus is rotated first outwards and then inwards. *No* transverse incision is to be made in the capsule. In cases in which the humerus must

be exposed farther downwards, the anterior and posterior circumflex arteries and the circumflex nerve which surround the surgical neck must be borne in mind, and the former if necessary ligatured. Catterina has obtained better access from the front by carrying the incision obliquely across the clavicle, dividing the latter in its outer third, and dislocating it backwards along with the deltoid, after first of all dividing the attachment of the trapezius above and the coraco-clavicular ligament below.

(*b*) *Resection from behind* (Figs. 182 to 186) is employed when the disease involves more especially the glenoid cavity, or in diffuse disease of the joint.

The skin incision, as shown in Fig. 182, is carried from the acromio-clavicular joint over the top of the shoulder and along the upper border of the acromion to the outer part of the spine of the scapula (root of the acromion), and from thence downwards in a curved direction towards the posterior fold of the axilla, ending two fingers'-breadth above it. The upper limb of the incision passes through the superior ligament right into the acromio-clavicular joint (the strong fibres of which are divided), and in the rest of its course divides the insertion of the trapezius along the upper border of the spine of the scapula. The descending limb of the incision divides the dense fascia at the posterior border of the deltoid, and exposes the fibres of the latter. The thumb is now introduced beneath the smooth under surface of the deltoid so as to separate it from the deeper muscles (with which it is connected merely by loose cellular tissue) up to its origin from the acromion, and its posterior fibres are divided. The finger is then carried along the upper border of the infraspinatus muscle so as to free it opposite the outer border of the spine and the root of the acromion.

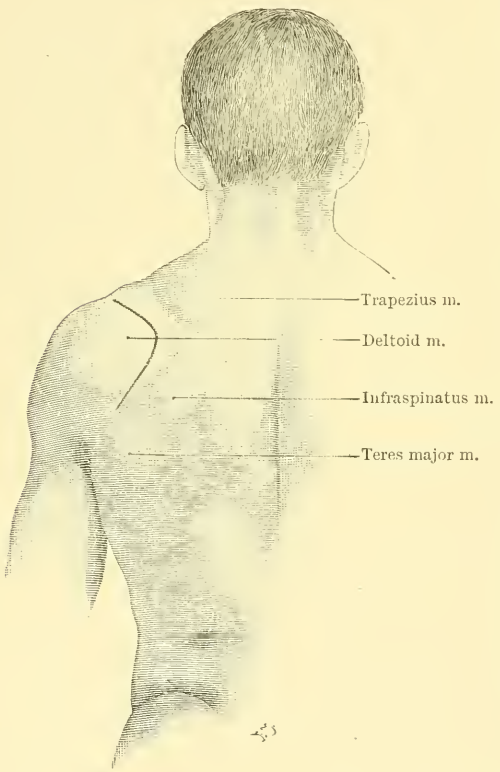

Fig. 182.—Arthrotomy of the shoulder by posterior curved incision.

In a similar manner the lower border of the supraspinatus is detached with a blunt dissector from the upper border of the spine of the scapula, in order that the finger may be passed from above underneath the root of the acromion. The root of the acromion, which is now freed, is chiselled through obliquely towards the neck of the scapula, and the acromial portion, along with the deltoid, is forcibly pushed forwards with the thumbs over the head of the humerus.

In chiselling through the bone, care must be taken not to injure the suprascapular nerve which passes under the muscles from the supraspinous into the infraspinous fossa by avoiding too deep division of the scapular spine; the nerve is also protected by the transverse ligament of the scapula. It is desirable before chiselling the bone to bore the holes required for the subsequent suture.

Instead of dividing the root of the acromion, the formation of the posterior flap may be simplified by merely detaching the scapular origin of the deltoid subcortically: this allows of a subsequent very firm union.

After reflecting the acromio-deltoid flap, the head of the bone is readily accessible

in its upper, outer, and posterior aspects, covered by the tendons of the external rotators, viz. the supraspinatus, infraspinatus, and teres minor muscles. The posterior surfaces of these muscles are also exposed. An incision is now made over the head of the bone, and in order to avoid unnecessary injury this must be done accurately. The assistant pushes the head of the humerus backwards and upwards, rotating it at the same time outwards, till the bicipital groove is felt. Posteriorly, where the muscles and their tendons are inserted into the greater tuberosity and the spine of the greater

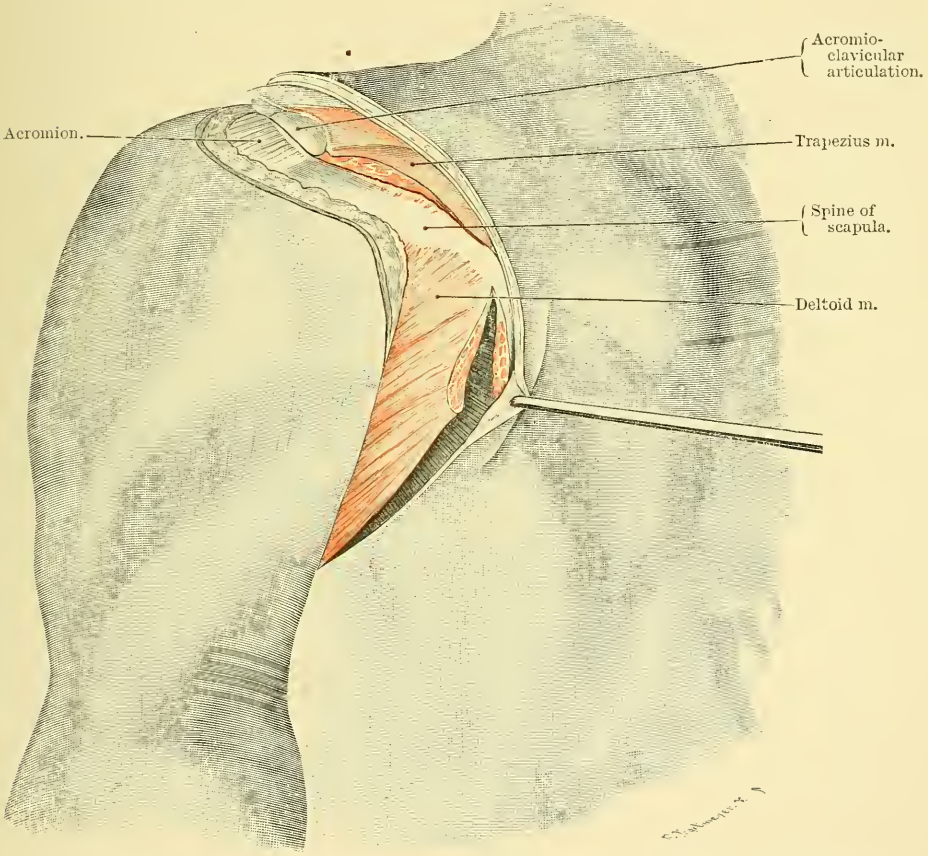

FIG. 183.—Arthrotomy of the shoulder by the posterior curved incision. The acromio-clavicular joint is opened and the trapezius is detached from the upper border of the spine of the scapula. The deltoid is exposed along its lower border, and its attachment to the spine is divided posteriorly, and at this point, after detaching the supra and infraspinatus muscles, the chisel is inserted to divide the spine of the scapula.

tuberosity, a longitudinal incision is carried down to the bone in the coronal plane. It extends upwards through the capsule along the anterior edge of the insertions of the external rotator muscles and over the highest part of the head of the humerus, so as to expose the tendon of the biceps as far as its attachment to the upper edge of the glenoid cavity. The insertions of the external rotators are now separated from the greater tuberosity and drawn backwards. The biceps tendon is freed from its groove and drawn forwards, so that its sheath may be inspected. The whole procedure is made easier by carrying the elbow forwards and at the same time rotating the arm outwards, and pushing it backwards.

In this way the entire head of the humerus and the glenoid fossa can be freely exposed, and if it is not necessary to perform a complete excision, the anterior wall of the capsule and the insertions of the anterior muscles can be preserved. In other cases the insertion of the subscapularis into the lesser tuberosity is detached upwards and inwards.

The circumflex vessels and nerve which emerge from under the teres minor can be preserved: indeed, if the operation be properly performed there need be no fear of injuring them.

When the head has been thoroughly cleared, and especially if it be excised, an

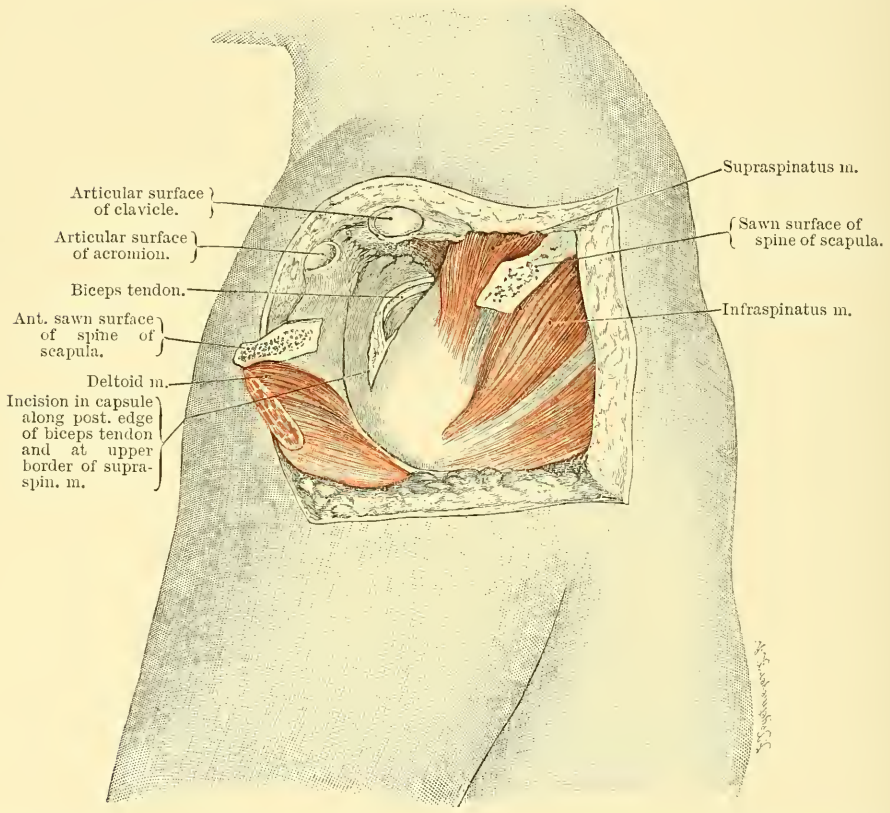

FIG. 184.—Arthrotomy of the shoulder. The flap, consisting of skin, deltoid, and acromion, has been thrown forwards. The capsule has been incised immediately behind the long tendon of the biceps, at the upper border of the supraspinatus.

excellent view of the glenoid is obtained, much better than is possible by the anterior incision; and as it is most important to remove all the infected tissues in tuberculous disease, this complete exposure of all parts of the joint is the great advantage of the method. Moreover, this free exposure is obtained without interfering with the function of the deltoid or other muscles of the shoulder. Yet another advantage over the anterior method is, that when the disease in the head is limited or absent, only the posterior muscles require to be separated, while the anterior part of the capsule, the coraco-humeral band, and the subscapularis muscle are preserved intact, and in this way there is no tendency or the head of the bone to be displaced upwards towards the coracoid, which so frequently occurs as the result of the anterior operation. The method is therefore especially valuable in partial arthrectomies.

Neudörfer has recommended an incision below the acromion, while MacCormac recommends a posterior longitudinal incision, but they have not found favour, as they do not give sufficient space.

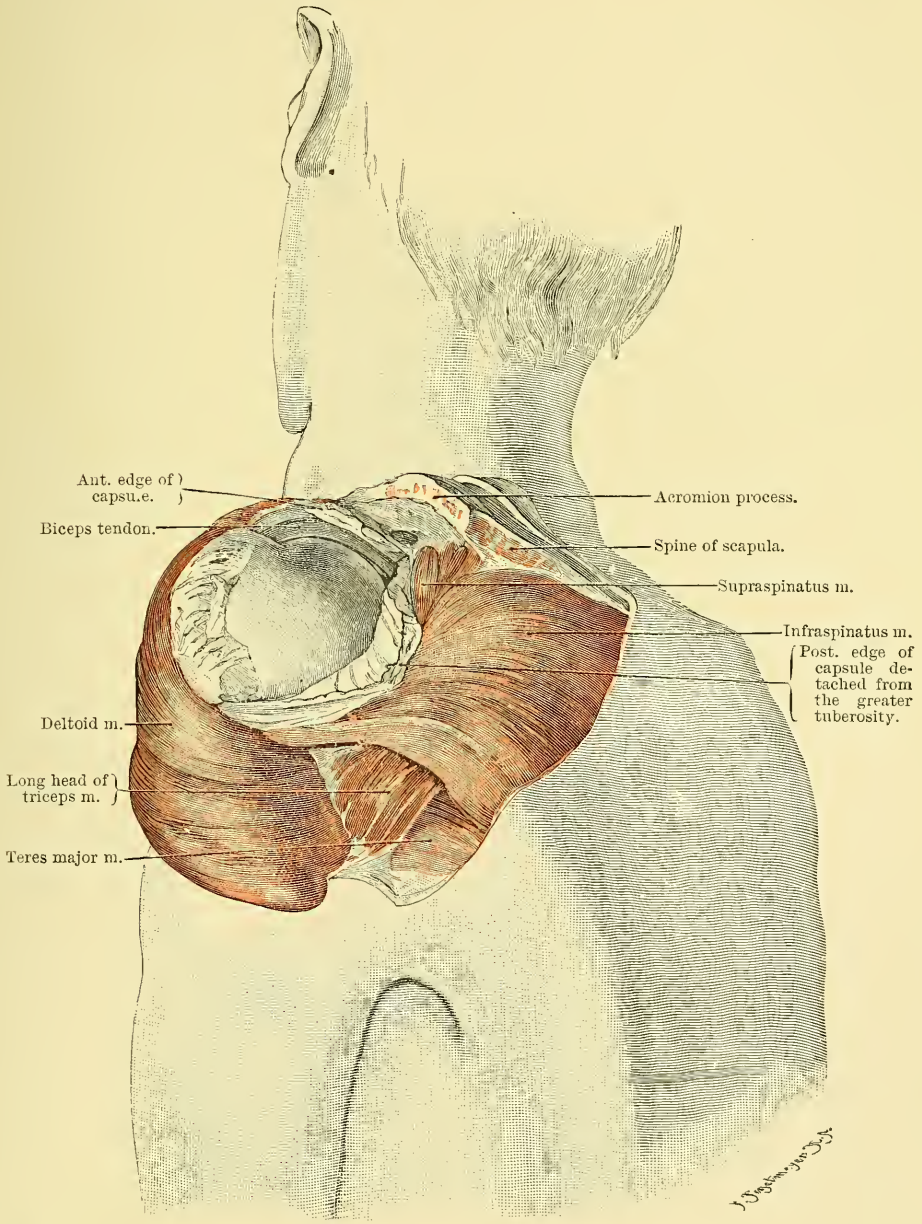

FIG. 185.—Excision of shoulder from behind. The deltoid is separated from the acromion and the spine of the scapula; the bone is not yet divided. The capsule has been incised at the upper border of the supraspinatus, and has been stripped backwards off the head of the humerus along the greater tuberosity.

The excellent results to be obtained by our method are shown in Fig. 186. It

represents a resection of the shoulder-joint performed by Dr. Lardy for fracture through the tuberosities of the humerus with rotation of the head of the humerus. The photograph was taken five months after operation.

In ankylosis of the shoulder Coville obtains a movable joint by the interposition of a flap of the deltoid. If the anterior operation is used, a strip of the deltoid is taken from the front of the clavicle; but with our posterior method it is even better to detach a flap from the fibres attached to the spine of the scapula, and stitch it to the intact anterior wall of the capsule.

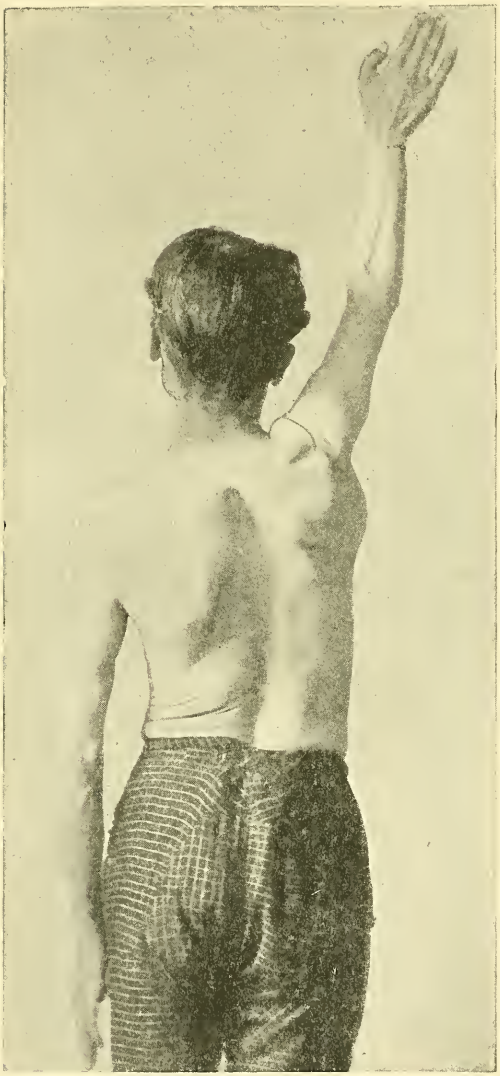

Fig. 186.—Excision of the shoulder for tubercular disease, with fracture and rotation of the head of the humerus.

Total Arthrectomy of the Shoulder-Joint. Bardenheuer performs a total extracapsular excision of the shoulder in a similar manner to that already described for the hip. The advantages of this operation have been dealt with in connection with the knee, of which the procedure was given in full detail. He detaches the insertions of the muscles along with a scale of bone behind, in front, and below, and then removes the head of the humerus below the attachment of the capsule without opening into the joint. The scapula is then divided above the capsule with a saw or chisel and the coracoid process is detached, by which means he is able to remove completely the whole joint together with the capsule and articular ends of the bones.

From the point of view of a radical removal of the tuberculous tissue such an operation is certainly the most thorough, but, as has been already pointed out in the case of the hip, healthy bone is sacrificed (since the limits of the disease cannot be determined beforehand), while the newly-formed joint surfaces cannot be closely fitted to each other. In addition, the subscapular bursa must be opened, and may prove a source of infection. The use of the method should be restricted to advanced cases of diffuse disease.

The excellent functional results that Bardenheuer obtains, in spite of the unnecessary sacrifice of bone, depend on the fact that a complete removal of all the disease is effected. In our opinion, however, equally good results can be obtained by less drastic measures, combined with suitable after-treatment.

After-treatment. We agree entirely with Bardenheuer that active movements should be commenced at an early stage, if satisfactory functional results are to be

obtained. We also agree that in the shoulder, as with the hip, the after-treatment should start with extension. Bardenheuer properly applies extension with the arm strongly abducted (it may even be elevated), because the patient recovers the power of adduction well enough, thanks to the weight of the arm; while the abducted position further allows satisfactory access to a posterior wound. Elevation forwards, which is naturally combined with it when the patient is recumbent, is only of advantage for later use. For the initial exercises, the arm is kept raised up by means of a weight and pulley, so that the patient has not to contend against the weight of the arm.

Thorough drainage must be provided, the tubes being introduced through special openings. The wound, which has been well smeared with iodoform, should then be dressed with a plentiful supply of iodoform gauze, over which several layers of antiseptic gauze are applied, so that the deep dressings need not be changed for the space of from eight to ten days. In suitable cases we do not employ drainage, and obtain primary union if the cavity is filled with iodoform paste (Mosetig).

When the muscles are much atrophied, plaster bandages should be applied and a stiff joint obtained, while if sinuses are present, the wound must be treated by the open method and packed.

35. Resection of the Clavicle, and of the Sterno-Clavicular, and Acromio-Clavicular Articulations. As the clavicle is subcutaneous throughout its whole length, its excision is a simple matter, provided it can be done subperiosteally. After dividing the skin, platysma, clavicular branches of the descending superficial cervical nerves, and fascia, the periosteum is divided and reflected. The clavicle should be sawn through in the middle, as it is then easier to clear each half separately. The clavicular attachments of the sterno-mastoid and trapezius muscles are detached from the upper surface, and the clavicular portions of the pectoralis major and deltoid from its anterior surface, whilst from its under surface the subclavius muscle and the costo-clavicular ligament are to be separated.

In tumours of the clavicle (sarcoma) the incision is made over the tumour, outwards and slightly upwards, along the clavicle. The skin and fascia are dissected off the tumour, the clavicular branches of the descending superficial cervical nerves being divided, along with small branches of the external jugular vein behind the sterno-mastoid. The posterior border of this muscle is raised, and its clavicular origin divided well wide of the tumour, the clavicular insertion of the trapezius being also cut across. The clavicular origins of the pectoralis major and the deltoid are next divided, free of the disease. The periosteum can now be incised over the healthy part of the bone in front of the limits of the tumour, and reflected from the lower surface. The knife or scissors are only necessary for division of the tendinous insertion of the subclavius into the junction of the middle and outer third of the clavicle and for the coraco-clavicular and costo-clavicular ligaments. Before dividing these tough structures the acromio-clavicular joint is opened, and the outer end of the clavicle forcibly pulled upwards with a hook. The subclavian vein, which lies behind the subclavius muscle, is thus easily avoided.

In excision of the *acromio-clavicular joint* the outer end of the clavicle is freed merely by cutting through the strong ligaments upon the surface of the joint.

There is no difficulty in excising the *sterno-clavicular joint* by an anterior incision, because the meniscus facilitates the separation of the articular ends. When, however, the excision cannot be made subcapsulo-periosteally, the transverse vein at the suprasternal notch must be kept in mind in dividing the interclavicular ligament, while in dividing the clavicular portion of the sterno-mastoid the anterior jugular vein, which runs outwards behind it to open into the external jugular, is to be looked out for. In extensive division of the subclavius muscle and the costo-clavicular ligament, the close proximity of the pleura and of the subclavian vein must not be forgotten.

Tuberculous arthritis not infrequently affects both joints. Resection may also be indicated in dislocations.

36. Resection and Total Excision of the Scapula (Fig. 187). *Complete* excision

of the scapula was first performed by Langenbeck (Gies) in 1855. Ceci, and more recently Picqué and Dartigues have shown what excellent functional results can be obtained after its complete removal. A useful arm is obtained even although part of the clavicle or the head of the humerus is removed. The difference, however, between a subperiosteal and parosteal removal is very considerable, so far as the subsequent functional result is concerned. The subperiosteal operation is employed mainly in cases of acute osteomyelitis with necrosis, where the periosteum has already been separated to a considerable extent; the operation is then comparatively easy. Unnecessary injury to neighbouring parts may be avoided by beginning the dissection over the spine of the scapula and keeping close to the bone; while it is of the utmost importance that the suprascapular nerve, which is in close contact with the back of the neck of the bone, should not be injured. In such cases, as has been proved by Bockenheimer's recent experiences, almost complete regeneration of the scapula results, while the normal mobility of the shoulder is also restored. On the other hand, when we have to deal with a tumour, all hope of movement at the shoulder must be abandoned, and one must be content to preserve the valuable movements of the elbow, hand, and fingers. Total excision is really only indicated in the various forms of sarcoma; and then, to avoid recurrence, one has to remove the muscles as well, *i.e.* the muscles which are inserted into the scapula or which pass from it to the arm.

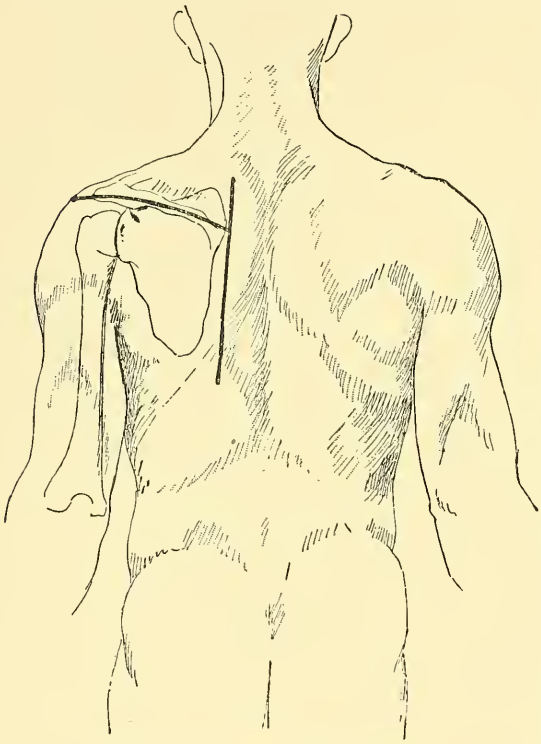

Fig. 187.—Excision of the scapula.

Excision of the Entire Scapula for Tumours. A curved incision is made along the acromion and spine of the scapula as far as its vertebral border. A second incision is carried along the vertebral border of the bone from its superior to its inferior angle. As far as the function of the arm is concerned, it is a great advantage if a considerable portion of the acromion can be retained, because the trapezius and deltoid muscles are attached, the former to its inner and the latter to its outer border. If the whole acromion is to be removed, the incision extends at once into the acromio-clavicular joint. If a portion of the acromion is to be preserved, the bone is divided with the chisel at the place selected.

The lower triangular flap is thrown back over the posterior fibres of the deltoid anteriorly, and the ascending portion of the trapezius posteriorly, as far as the upper edge of the latissimus dorsi. The finger is introduced under the exposed posterior border of the deltoid, and the muscle is divided (if the disease admits) close to the spine and acromion as far as the acromio-clavicular joint, or to the place where the acromion has been chiselled through.

In this way the posterior surface of the shoulder-joint, together with the tendons of the external rotators, is exposed in the same way as in our method of excising the shoulder-joint by the posterior incision. If the articular portion of the scapula can be retained, muscle after muscle is cut across upon an elevator, or upon the finger

introduced beneath them. If, however, the articular portion of the scapula must be removed, the tendons are detached from the head of the humerus just as in excision of the shoulder-joint, viz. the supraspinatus, infraspinatus, and teres minor from the greater tuberosity, the subscapularis from the lesser tuberosity, and farther down the united insertions of the latissimus dorsi and teres major muscles from the inner bicipital ridge.

The circumflex nerve and the posterior circumflex artery are to be avoided, or the latter may have to be ligatured at the lower border of the teres minor, whilst farther backwards the dorsalis scapulæ artery must be ligatured.

Next follows the division of the trapezius. The finger is introduced under its fibres from the place where the acromion is divided, and the muscle is detached along the acromion and spine. The acromial branches of the acromio-thoracic artery will require to be ligatured in separating the anterior part of the muscle.

By drawing downwards the scapula, which has now become more movable, the muscles attached to its upper border are separated from before backwards, viz. coraco-brachialis, short head of biceps and pectoralis minor from the coracoid process (or the process may be chiselled off) the omo-hyoid (with ligature of the suprascapular artery) and the levator anguli scapulæ at the upper angle, branches of the posterior scapular artery being ligatured.

There still remains the broad insertion of the serratus magnus at the vertebral border, in dividing which the scapula is to be rotated towards the spine. Lastly, the insertions of the thin rhomboid muscles are cut across, the posterior scapular artery, which descends along the vertebral border of the scapula upon the serratus posticus superior muscle, being ligatured if necessary.

Buchanan (1900) has collected seventy-two cases of Langenbeck's total excision of the scapula, with 15·3 per cent deaths. In ninety-two cases partial excision was performed with 18 per cent deaths.

Quénu and Renon have shown that the subsequent functional results are better if the acromial end can be retained and the remains of the capsule, as well as the stumps of the muscles, are sutured to it.

In a partial excision, especially of the scapular spine, shorter incisions along the same lines should be made. An anterior incision is only required for the removal of the coracoid process. Good functional results are obtained provided the articular and acromial portions of the scapula can be retained.

As regards the after-treatment of a total excision, the essential feature is to provide a fixed point for the head of the humerus. In the first place the head must be fixed by stitching the capsule and any available stumps of tendons to the clavicle, silk sutures being used, after which the stability and functional efficiency of the joint may possibly be increased by suture of the muscle.

The upper border of the deltoid, apart from the portion that may have been left attached to the acromion, is then stitched along with the trapezius, omo-hyoid and levator anguli scapulæ, while the muscles arising from the coracoid process are sutured to the clavicle.

It is well to follow Bardenheur's advice and lay the arm in a position of abduction and elevation, so that the function of the most important muscle may be retained.

The above precautions are still more necessary if the head of the humerus, with or without a portion of the diaphysis, has been removed along with the scapula. Even then, however, the useful movements of the elbow, wrist, and fingers are preserved.

B. AMPUTATIONS AND DISARTICULATIONS

(a) Introduction

Since our last edition, the advances made in the methods of performing amputations and disarticulations lie in the direction of paying even more attention than formerly

to obtain a useful stump, Bier having given a useful impetus to the efforts in this direction. Since asepsis has been ensured and perfect healing obtained in amputations as in other wounds, more care has been bestowed on the shape of the stump as well as on provision of the best possible function. Further, greater simplicity has been attained. To illustrate this we reprint from the third edition the chapter on the evolution of the different methods of amputation, and the manner of carrying them out; and we shall describe the normal procedure which is applicable in all cases.

Methods of Amputation.

Fig. 188.

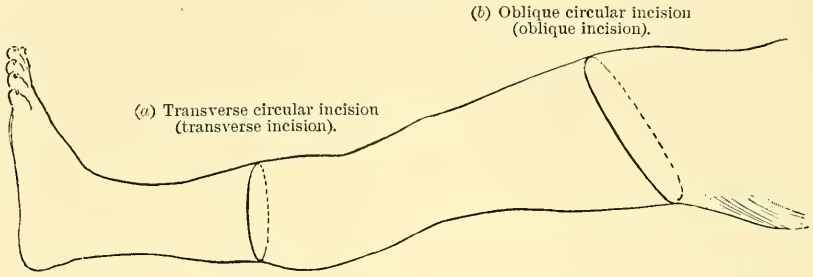

I. Fundamental type: circular incision.

Fig. 189.

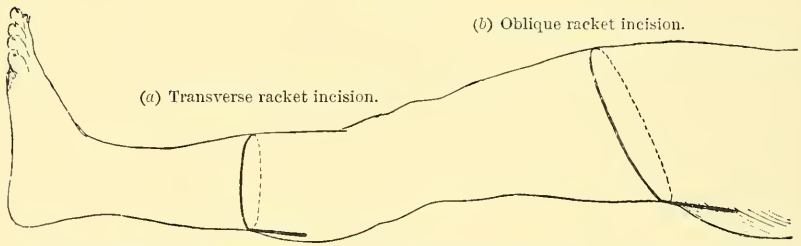

II. Addition of a longitudinal incision, to simplify the operation: racket incision.

Fig. 190.

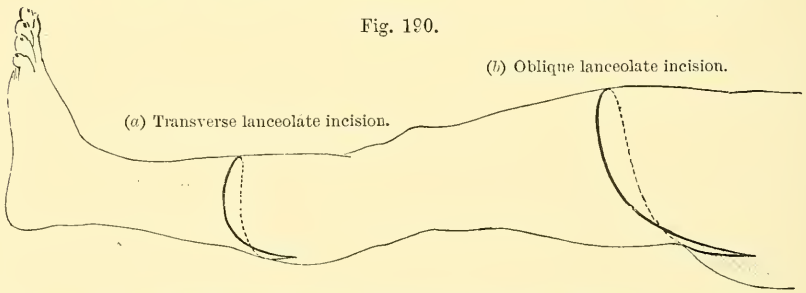

III. Angles of the racket incision rounded off so as to allow of the incision being made more rapidly by one sweep of the knife: lanceolate incision.[1]

(b) Evolution of the Methods of Amputation

The oldest method of performing amputation of the limbs, which as it were of itself was enforced upon the older surgeons, is extremely simple. A circular incision is carried down to the bone above the part of the limb to be amputated, and the soft parts are stripped off the bone, so that when the latter is sawn across they can be

[1] Formerly termed "oval incision"; a pointed figure, however, is not an oval. The term "oval incision" would apply only to our oblique incision (Fig. 188).

made to cover the stump without any tension. If the bone cannot thus be shelled out through a transverse incision alone, a single, or two longitudinal incisions should be added, also carried down to the bone (racket and rectangular flap). This simple process has in course of time undergone so many variations that the most modern surgery has, as it were, had to rediscover it. Neudörfer, Bruns, and others have shown that the best covering for the end of the bone is obtained by placing over it the periosteum and the soft parts entire, with as little injury as possible, the soft parts being divided down to the bone, and the periosteum cut through farther up, so as to get a covering for the sawn surface.

In order to show the connection between the different methods of amputation we give in Figs. 188 to 190 a general view of the evolution of the more complicated incisions from the simple circular methods.

The circular method (better called the transverse method) is the oldest, and consists in carrying a transverse incision right round the limb in a plane at right angles to its long axis. If the plane is oblique to the axis of the joint, an oval incision results

FIG. 191.

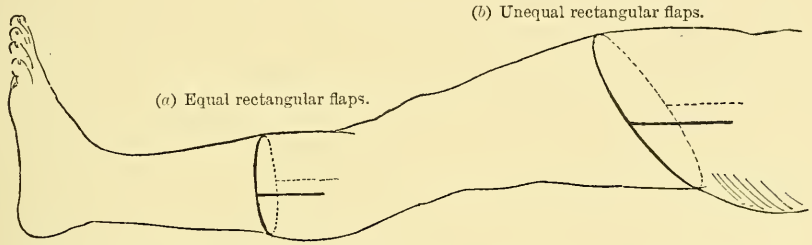

IV. Two longitudinal incisions added to the circular incision: rectangular flaps.

FIG. 192.

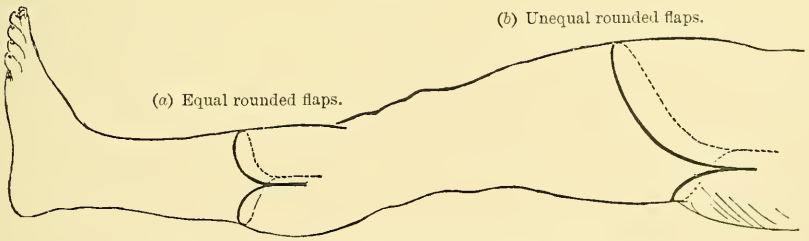

V. Angles of the rectangular flap rounded off: rounded flaps.

(Fig. 189) (better described as the oblique method, the oval often being of an irregular form). From the transverse circular and oblique circular incisions, all other methods are derived by the addition of longitudinal incisions with rounding off of the angles formed. If a longitudinal incision be added to a circular one, a *racket incision* results, and by rounding off the corners, the so-called *oval incision*, better termed the *lanceolate incision* (as an oval with a pointed extremity is not really oval). If two longitudinal incisions are added, *rectangular flaps* are produced, and by rounding off the corners the *typical horse-shoe flap* is the result.

The *transverse circular incision*, or shortly the *transverse incision* (Figs. 188 and 193), is the fundamental type of one method of amputation. It originated as a single incision from Celsus, as a double incision, with higher division of the muscles, from Cheselden and Petit (Schede). The process of sawing the bone higher up was introduced by Louis and Boyer. According to Freres's description, Celsus divided the soft parts on one side and separated them from the bone, in fact practising what, with

some modification, has been lately recommended by Bruns and Neudörfer. The present circular method was introduced by Bell and Hay (Treves).

While this operation is simple in execution, it has a number of disadvantages which prevent it being universally employed. (1) Since in an amputation one endeavours to preserve as much as possible, the oblique incision is preferable whenever there is more healthy skin on one side than on the other, or when the skin on one side is more adapted for a covering. (2) The separation of the skin to a sufficient extent is difficult where the limb to be amputated is conical. (3) In the transverse circular incision the cicatrix comes to lie upon the end of the stump, which is not the case with the oblique incision. Figs. 193 and 194 sufficiently illustrate the different positions of the lines of suture.

It is evident, therefore, that on the above grounds the *oblique circular incision* (Figs. 188 and 194) has a far wider range of employment, because it is applicable to most cases, is easily performed, and gives a movable skin-covering free from a cicatrix over the end of the stump. The oblique circular incision is, therefore, the method to be selected in the majority of amputations and disarticulations when no special indications are to be fulfilled.

The circular incision (transverse or oblique) in one plane does not always give sufficient space for dividing the deeper parts, especially the bones; and it is on account of the mechanical difficulties that more complicated incisions are employed, viz. the addition of *longitudinal incisions* to the circular one.

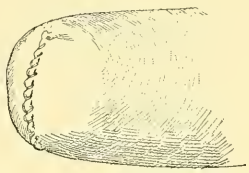

FIG. 193.—Position of the line of suture by the transverse circular incision.

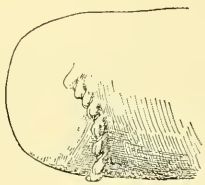

FIG. 194.—Position of the line of suture by the oblique incision.

The *racket* (Fig. 189) and its variety, the *lanceolate incisions* (Fig. 190) give better access to bones and joints, and are therefore to be preferred in difficult disarticulations, if the indication is to retain as many muscles as possible in the stump, as in disarticulation (and high amputation) at the hip, shoulder, and carpo-metacarpal joint of the thumb. A further advantage of this incision is that the larger vessels can be ligatured and the larger nerves cut across before the limb is severed. The lanceolate incision requires more practice than the racket.

Neudörfer (Wanach), and subsequently Chaput, have recommended, as the typical method for all amputations, that in which a longitudinal incision is first made down to the bone, which is then chiselled through at the upper end of the incision and removed with subperiosteal (subcortical) separation of the soft parts, the latter being then divided transversely at a lower level. This is practically a racket incision.

The flap methods (Figs. 191, 192), in the form of skin flaps (Lowdham), of skin and muscle (Ravaton), and the transfixion flaps (Vermale) are more satisfactory when the skin or subjacent muscle demand special attention upon one or other aspect of the limb, and when the oblique incision is too difficult. This is the case, for example, as regards the skin of the sole and heel, the muscles of the shoulder and hip. The disadvantage of the flap method, which applies also in a less degree to its fundamental type, the oblique circular incision, is the defective nutrition of the skin.

(c) Performance of the different Methods

The transverse circular method (Figs. 195, 196). The skin and superficial fascia are divided circularly at right angles to the axis of the limb, first upon the under and

then upon the upper segment of the circle. The assistant retracts the skin well upwards with both hands whilst the knife divides the fibres which are stretched between the superficial and deep fascia. The superficial muscles are then divided, and at the level up to which they have retracted the incision is continued through the deeper muscles down to the bone. The height at which the bone is sawn across above the skin incision is equal to fully half the diameter of the limb. The soft parts must

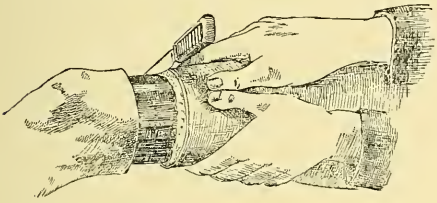

FIG. 195.—Transverse circular incision: method of retracting the skin, and position of the knife.

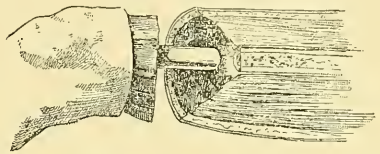

FIG. 196.—Transverse circular incision: Sagittal section, to show the hollow cone which is left after sawing through the bone.

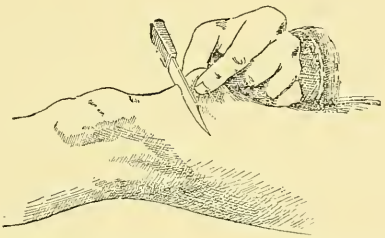

FIG. 197.—Oblique incision: the lower end made by cutting across a fold of skin raised up between the finger and thumb.

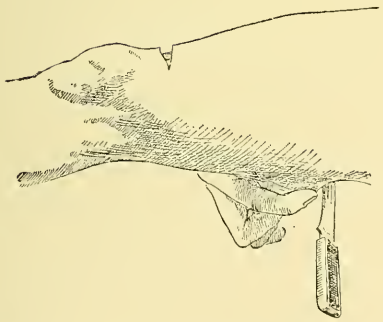

FIG. 198.—Oblique incision: the upper end made by cutting across a fold of skin raised up between the finger and thumb.

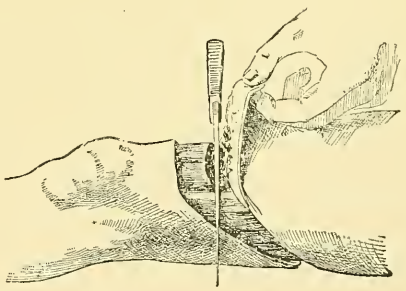

FIG. 199.—Oblique incision: position of the knife in order gradually to carry the incision deeper through the soft parts of the flap.

always be able to be approximated over the bone without the least tension. The periosteum should be divided as high up as possible, the soft parts being retracted with long gauze compresses to protect them while the bone is being sawn. The bone is sawn through 1 cm. below the level at which the periosteum is divided.

By making a series of circular incisions (the superficial parts being retracted to allow the deeper parts to be divided at a higher level), a funnel-shaped cut surface is obtained, at the bottom of which is the sawn surface of the bone. A broad apposition

of all the soft parts is ensured (Fig. 196). The muscles are stitched over the bony stump with buried sutures as far as the skin.

The oblique or oval incision (Figs. 197, 198, 199). The "elliptical" method is attributed by Treves to Sharp and Soupart, while the oblique incision which we describe has been used by Blasius. The upper and lower ends of the incision are indicated by making short incisions into a fold of skin raised up between the finger and thumb, the distal incision being made at right angles to the surface, and the proximal one parallel to the surface (Fig. 197, 198). The upper end lies at the level where the bone is to be sawn through; the lower end lies at a distance below it equal to the diameter of the limb. After dividing the skin and fascia, the operator seizes the lower ellipse of skin with the left hand (Fig. 199), draws it upwards, and divides the muscles down to the bone, *the edge of the knife being directed towards the bone* so that a flap of skin and muscle is formed which increases in thickness towards the line of division of the bone. Periosteum and bone are treated as in the transverse circular incision. The musculo-cutaneous flap is now folded over the wound.

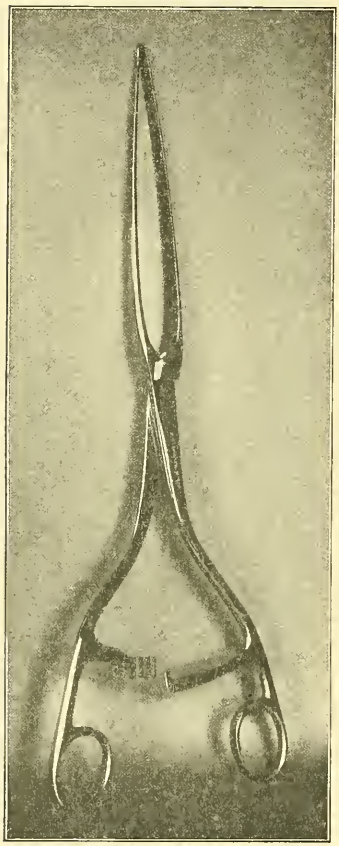

Fig. 200.—The Lynn-Thomas Forceps.

If for any reason the muscles and tendons cannot be retained, then, after the skin incision has been made, the lower end of the skin flap is seized and dissected up from the subjacent tissues to the level of the upper end of the incision, the edge of the knife being kept vertical to the muscles and never directed towards the flap. After the skin has been dissected up, the muscles and bone are dealt with in exactly the same way as in the transverse circular method.

The racket incision and its modification, the lanceolate incision (Figs. 189, 190). Malgaigne is the originator of the racket method, Scoutetten of the lanceolate incision. It consists in the addition of a longitudinal incision directed upwards from a transverse (or oblique) circular incision, the longitudinal incision extending upwards to the level at which the bone is to be divided. When possible the longitudinal incision is placed over an intermuscular septum which separates two areas of nerve-supply, extends down to the bone, avoiding the vessels and nerves, and divides the periosteum, which is then separated. Bleeding vessels are ligatured, and larger vessels are directly sought for in order to diminish the bleeding from the subsequent circular incision. In disarticulations the joint is opened by the longitudinal incision and the capsule separated from the bone.

Neudörfer first divides the bone with a chisel through the longitudinal incision and shells it out subperiosteally down to the level at which the circular incision is made. At this stage Lynn-Thomas's compression forceps (tourniquet) can be applied with advantage to control the bleeding (Fig. 200). The skin is then cut through transversely or obliquely and retracted, after which the muscles are divided and the bone is sawn across, if this has not already been done, as Neudörfer advises. The muscles are then carefully stitched in layers so that the coverings of the stump may be freely movable.

Just as the oblique incision is the most important and most universal method of amputation in simple cases, so is the *racket incision* the type of amputation for all

cases in which special value is placed upon retaining the muscles in the stump, and consequently the maximum of movement, especially in the neighbourhood of muscular joints such as shoulder, hip, thumb, and elbow. The racket method provides actively movable stumps when the bone has re-formed, or even if the bone has been entirely removed, and the effect is enhanced if the muscles of antagonistic action have been sutured over the end of the stump.

The lanceolate incision, in which the angles of the racket incision are rounded off, is the more convenient and elegant modification of the latter process, if there is no question of retaining the periosteum.

The circular methods with two lateral incisions, or *the double flap methods* (Figs. 189 and 190), are modifications of the simple types for the purpose of simplifying the execution of the operation. They are therefore everywhere applicable when the simple circular incision is difficult to perform on account of the density and tension of the skin, or on account of the breadth of the ends of the bones, especially in amputations at the ankle-joint.

The fundamental type consists of two longitudinal incisions placed opposite one another, and united at their lower ends by a circular incision. If this circular incision lies transversely, two rectangular flaps of equal length are the result. If it is placed obliquely, the flaps are of unequal length. Teale, for example, employed the flap method in the strict sense of the term: in making the flaps he dissects up all the soft parts as far as the level at which the bone is sawn across. As a rule, however, the flaps are rounded off as they are cut, so that only a portion of the longitudinal incisions is retained, and instead of a circular incision, we have two curved incisions which join the longitudinal ones at an acute angle. The mistake usually committed by beginners is that they make the two curved incisions join one another at too wide an angle. It is therefore desirable that less experienced operators should begin by making the two lateral incisions, and then connect them in front and behind by two curved incisions. The skin and fascia are divided, and just as in the simple oblique incision, the lower edge of the flap is raised up and the muscles are divided obliquely down to the bone. Two oblique raw surfaces are thus obtained, which in the case of flaps of equal length are applied to one another. With flaps of unequal length the larger one (generally the anterior) covers the main part of the wound surface. When two equal flaps are made, their length should correspond to half the diameter of the joint, while a single flap equals the diameter. When the oblique incision is used, the muscles are occasionally not required in the flap, the latter then consisting only of skin and fascia.

Mention must be made of that variety of the flap method in which the parts are *transfixed* by a double-edged knife. The limb is transfixed, and the flaps are formed by carrying the knife downwards along the bone, and dividing the muscles and skin in an arched direction towards the surface, first on one aspect and then on the other. This rapid method produces a very clean wound, but it has lost its importance since the introduction of anæsthetics and of Esmarch's prophylactic arrest of hæmorrhage.

After removal of the limb the vessels are caught with Kocher's artery forceps and ligatured with fine silk, while the nerve-trunks are sought for, drawn forwards, and cut across as high up as possible, so as to be removed from the scar and prevent any irritation from pressure or adhesions. Severe pain may result from involvement of the nerve-end in the scar. The muscles are then sutured in layers and the skin is closed with a continuous suture. When the wound surfaces cannot be brought into complete apposition and sutured in their whole extent, a glass drain (with large lateral openings) is introduced through a small special opening as directly as possible into the cavity which is left.

(d) Methods of obtaining functionally useful Stumps

In the upper limb a stump is functionally good when it can control its artificial limb without giving rise to pain, while in the case of the lower limb it must in

addition be capable of bearing weight, *i.e.* a good stump must be able to bear the direct pressure of the artificial limb when the body weight is imposed on it. There is thus some difference between the essentials of a good stump in the upper and in the lower extremities, as a stump which might prove eminently suitable for the arm is under similar conditions quite useless in the leg.



FIG. 201.—Skiagram of stump, one and a half years after osteoplastic amputation.

Much attention has recently been paid to the importance of this weight-bearing capacity and its introduction has led to great practical improvements. Bier, who was the pioneer in this movement, was the first to show how the diaphysis of a bone can be made capable of bearing weight, although his operation is now regarded as too complicated in certain cases.[1] That there was much room for improvement is shown by Crainer[2] who collected 96 cases of amputation through the thigh and leg, 70 of the stumps being bad and only two capable of bearing weight.

While the majority of surgeons prefer to use a periosteoplastic method of amputation through the shaft of a bone, a method introduced by Walther in 1813 and improved by Ollier (Schede), Bier was the first to introduce on principle the osteoplastic process, originally suggested by Pirogoff, and first applied by Gritti.

The theory on which Bier founded his method, namely, that the raw surface of a bone is and remains tender, and that therefore the medullary cavity must be covered by a flap of bone which is in normal connection with its periosteum, has been proved to be unsound. Thus, in his original method, he used to construct what was practically an artificial foot out of the periosteum turned round in the form of a flap, but later along with v. Eiselsberg he devised the simpler form of osteoplastic flap to replace the subperiosteal operation he had abandoned. Hirsch next came forward with his observations that useless stumps of various types could be made capable of bearing weight by treatment with gymnastics,[3] massage, and gradually increasing pressure. Honsell (of Bruns's clinic) has confirmed this fact for stumps formed by the sub-periosteal method.

[1] The first communication, *D. Zeitsch. f. Chir.* Bd. 34. [2] *Arch. f. Orthopädie*, Bd. 3.
[3] *D. med. Wochenschr.*, 1899, No. 47.

In opposition to Bier's views, Hirsch and Bunge[1] have correctly shown that the protection of the raw end of the bone from pressure is of far less importance than the removal of all sensitive structures at the operation, especially the periosteum and, according to Bunge, also the marrow. This view culminated in the introduction of the aperiosteal method of amputation.

In the latter method it has been conclusively proved by Bunge, v. Eiselsberg (Ranzi), Moskowicz, Amberger, Manninger, and Steiger[2] (of our clinic), that the



FIG. 202.—Skiagram of stump three and a half months after aperiosteal amputation. Very good result in regard to bearing pressure.

cicatricial sawn end of the bone is not in itself tender, even though the medullary cavity has been left open.

Tenderness is due much more to excessive growth of the periosteum (perhaps also in the marrow, Bunge) which leads ultimately to the production of exostoses, and can most easily be prevented by a complete removal of the periosteum covering the end of the stump, although the experience of Hirsch and ourselves also shows that exostoses can be prevented by accustoming the limb early to bearing weight on its surface.

[1] *Verhandlungen d. deutsch. Gesellsch. f. Chirurgie*, 1900, ff.

[2] Bern Dissertation, 1903.

We here reproduce some characteristic radiographs which have been published by Steiger in our clinic. Fig. 201 represents the appearance after an osteoplastic amputation of the leg (Bier and Eiselsberg method), in a man aged forty-six. As some necrosis occurred and a sinus formed, a second amputation was performed. The stump after the first, *i.e.* osteoplastic, operation was well rounded, the bones united, and there was no tenderness on pressure. At the second operation an aperiosteal amputation (Bunge) was performed. The result is excellent and the stump bears the weight of the body without any pain. As Fig. 202 shows, the stump is smooth, round, and devoid of any exostoses.

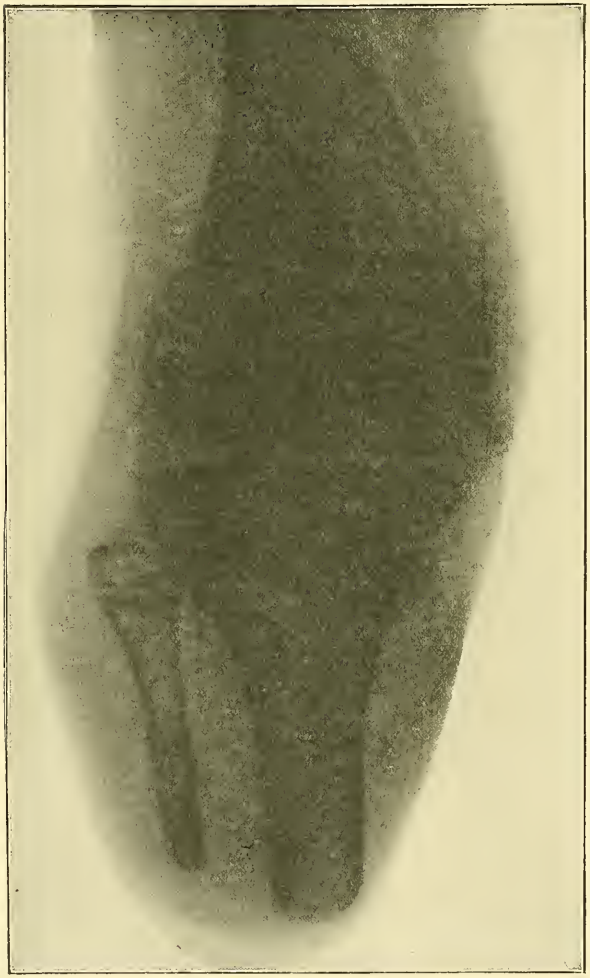

Fig. 203.—Secondary aperiosteal amputation of leg. Excellent weight-bearing stump (Fankhauser).

Figs. 203 and 204 give a further comparison between the aperiosteal and subperiosteal methods.

In the case of the child (Fankhauser) eleven years old, the leg was amputated elsewhere by the subperiosteal method without, unfortunately, a radiograph of the stump having been taken. A second amputation was found necessary owing to pain. The result of this typical aperiosteal stump (Fig. 203) was perfect.

The appearances of the subperiosteal stump from a man fifty-one years old are quite typical (Fig. 204). In spite of the fact that the stump is well rounded, an exostosis formed which was tender on pressure and prevented a bucket limb being worn.

That perfect stumps can be obtained by the subperiosteal method is shown by the radiograph in Fig. 206, which represents the case of a man who had an osteoplastic amputation on one side (Fig. 205) and a subperiosteal amputation on the other side (Fig. 206). Both stumps are well rounded off, are not tender, and bear weight admirably.

Steiger has investigated and compared 21 cases of amputation through the leg and 15 cases of amputation through the thigh from our clinic, in which various methods were used. His observations show that satisfactory results are obtainable by all three methods, viz. aperiosteal, subperiosteal, and osteoplastic, provided (1) that the operation is correctly performed, (2) that primary union occurs, and (3) that the stump is at an early stage accustomed to bear weight and can thus adapt itself rapidly to its new function.

The following questions must be considered :—

(1) Which method can be most relied upon to give a stump which can bear weight in the event of complications being present, especially in the healing of the wound? The answer is not difficult. With the osteoplastic method there is most chance of necrosis, the subperiosteal method leads to exostoses as the result of inflammation, while only the aperiosteal method can furnish a useful stump in the presence of such complications. Ranzi and Auffenberg,[1] from v. Eiselsberg's clinic,

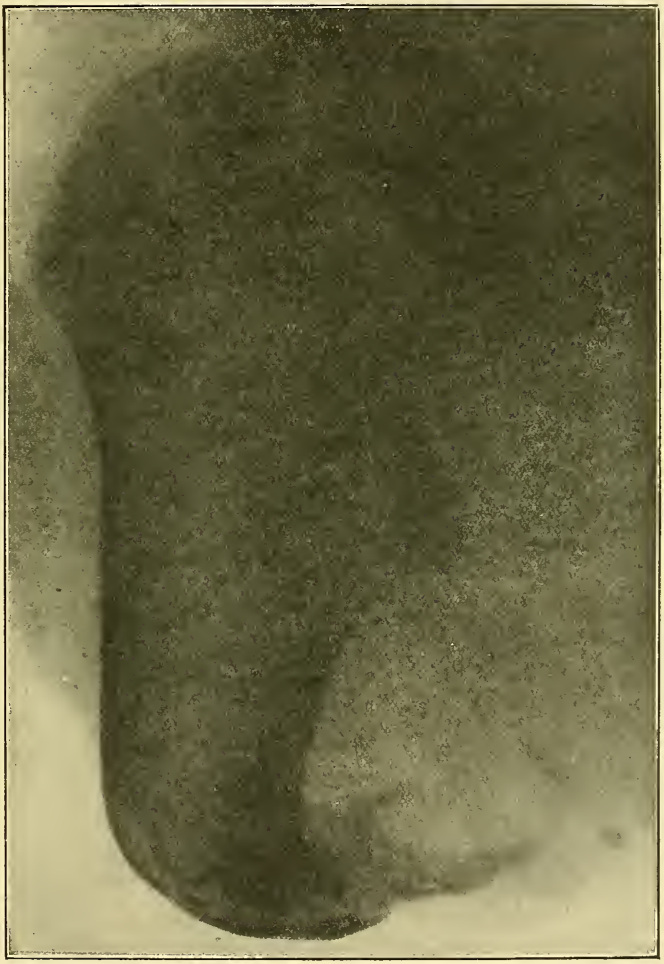

FIG. 204.—Skiagram, after subperiosteal amputation through the thigh.

expressly state that even when the wound suppurates, good functional results are still obtained by Bunge's aperiosteal method.

(2) Which method is the easiest and best adapted for inexperienced surgeons, *e.g.* in the field? Here also the answer is not difficult. The osteoplastic method (as can be seen in every operative course) is difficult, and requires practice and care. The aperiosteal method is the simplest and the most natural, inasmuch as the bone projects free from periosteum.

Bunge's aperiosteal method should therefore be regularly employed for all amputa-

[1] *Wiener klin. Wochenschr.*, 1905, No. 51.

tions through the shaft of a long bone. When primary union is obtained, and consequently the stump is at an early stage accustomed to bearing pressure, excellent results are obtained. Bunge maintains that the functional results are also good even

FIG. 205.—Osteoplastic amputation.

FIG. 206.—Subperiosteal amputation.

when no care is taken regarding the position of the scar and no special after-treatment is adopted.

If this were so, the measures for the subsequent utility of the stump that Hirsch adopts, viz. massage, etc., would be superfluous except in regard to its pressure-

bearing function. It is better, however, not to count on this, for there is no doubt that, as regards the question of bearing pressure on the stump, great care must be taken to ensure that the cicatrix will not be exposed on the end of the limb, *i.e.* an oblique or flap incision must be used. We can only depart from this rule in the case of a high amputation or disarticulation of the thigh, because then the artificial limb takes its purchase from the pelvis. In every amputation the nerves must be cut short, in order to prevent the possibility of their becoming adherent in the cicatrix.

There are two points which must be observed in all amputations and disarticulations: first, to avoid a painful stump, and second, to prevent atrophy. Asepsis is, of course, an essential, and fine non-sensitive scars both in the soft parts and in the bone, the periosteum of which is very sensitive to inflammation, are only obtained by a strict aseptic technique. A painful stump is really caused by the sensitiveness of the scar. The edges of the wound must be clean cut and stitched without tension or pressure, while absolute arrest of hæmorrhage is important in relation to asepsis in amputation as in all operations elsewhere.

If asepsis is secured, the scar must be protected from every form of mechanical injury, especially from pressure and tension, if the stump is to be painless. Nerve cicatrices—so-called amputation neuromata—give rise to the greatest pain. We have already stated how they can be avoided. Further, the cicatrix in the skin must be so placed that it is not exposed to pressure between the end of the bone and the artificial limb. It should not be adherent to the cicatrix in the deep tissues, and especially must not be continuous with that in the muscle and bone. To avoid these dangers the deep fascia should be carefully sutured by itself and if possible the superficial and deep cicatrices should not be made parallel.

Similarly the cicatrix in the muscle ought not to be placed between the bone and the surface of the artificial limb, and the same rule applies even more forcibly to the position of the cicatrix in the periosteum, which, according to Lennander, is the only sensitive part of bone. Whether the marrow is sensitive or insensitive has not been definitely determined. Care must be taken, therefore, that there shall be no periosteal scar exposed to pressure. Hence it is better to remove the periosteum entirely from the end of the stump. It is certainly not a matter of indifference whether the edges of the bone are left sharp or are rounded off, as the latter method prevents harmful pressure.

It is a recognised fact that when a long bone is sawn through its epiphysis, the stump is readily adapted to bearing pressure, for here, as in disarticulations, the end of the bone is very easily rounded off.

Muscular atrophy, on which the production of a conical stump depends, is prevented by providing a new insertion for the muscles. When the muscles cannot be sutured directly to the bone, they should be stitched over the end of the stump, *i.e.* those that have an antagonistic action. One advantage of disarticulation is that the normal insertions into the epiphysis are retained.

This is a point to which hitherto no special attention has been paid. The suggestion made by Wilms[1] of covering the end of the bone with a tendon and stitching the latter to the periosteum has been successfully carried out by Dichel, the tendo Achillis being employed in the case of the leg and the quadriceps in that of the thigh. Like Bunge and others, we cannot attribute the advantage of this procedure simply to the fact that it forms a cushion over the end of the bone. We are inclined to the belief that the interposition of the tendon prevents the formation of cicatricial adhesions between the raw end of the bone and the wound in the soft parts. In this sense, the operation which has been already put in practice by Duval and Laborie finds its justification.

Early exercise (Hirsch) is a further means by which atrophy may be prevented, but it depends entirely on primary union and the freedom from pain. It acts by stretching adhesions much in the same way as peristalsis acts after laparotomy.

[1] *Centralbl. f. Chir.*, 1901.

(e) Amputations of the Foot

37. Removal of the Toes and Individual Metatarsal Bones (Fig. 207). As a rule it is advisable not to perform partial amputation of a toe, but to disarticulate it at the metatarso-phalangeal joint, as otherwise the stump is only an inconvenience.

Amputations and disarticulations of the toes are analogous to those of the fingers. For the phalanges and interphalangeal joints the oblique circular incision is indicated, whilst for the metatarsi and metatarso-phalangeal joints the racket incision (the handle on the dorsum) is made.

In the case of the great and little toe the dorsal portion of the incision is not placed over the middle of the phalanx and metatarsus, but more towards the middle line of the foot, so that the cicatrix may be out of reach of lateral pressure. The

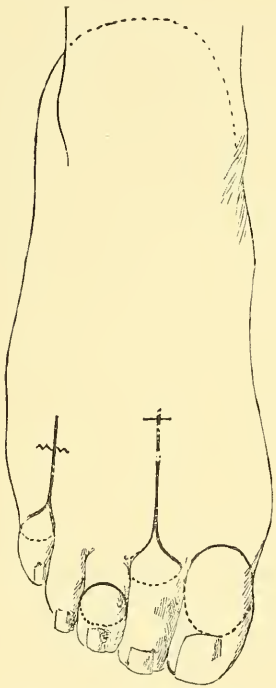

FIG. 207.—Disarticulation of the great toe at the metatarso-phalangeal joint, and of the 2nd toe along with its metacarpal bone: amputation through the 3rd toe, and through the 5th metatarsal bone.

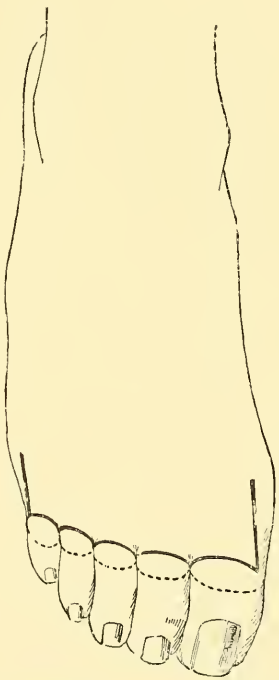

FIG. 208.—Disarticulation of all the toes at the metatarso-phalangeal joints.

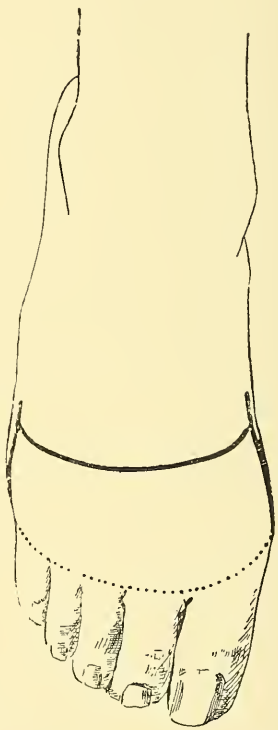

FIG. 209.—Disarticulation at the tarso-metatarsal joints, by means of a plantar flap with short convex dorsal incision.

resulting scar occupies as good a position as that in Farabœuf's amputation by internal and external plantar flaps.

38. Disarticulation of all the Toes (Metatarso-Phalangeal Disarticulation) (Fig. 208). Each toe is dealt with separately as follows:—It is dorsiflexed, and an incision is carried round it where it emerges from the general cutaneous envelope of the foot. When complete, all the incisions should unite at the webs. Upon the plantar aspect this incision runs exactly along the furrow between the digits and the

ball of the toes. A dorso-lateral incision is added over the metatarso-phalangeal joints of the great and little toes. In this way two rectangular flaps are formed.

The foot being held at right angles, the extensor tendons are divided as high up as possible, the lateral ligaments and the dorsal and plantar portions of the capsule are divided with a small knife, and, lastly, the plantar tendons. The dorsal and plantar tendons are then stitched together or to either side of the joint capsule.

39. Amputation through the Metatarsus (Fig. 209). This operation has the advantage over the tarso-metatarsal disarticulation that the insertions of the chief muscles of the foot are all retained, not merely the tibialis posticus and peroneus longus, but also the tibialis anticus and the peroneus brevis and tertius. Hence the foot retains its normal movements in all directions. It also provides a very serviceable

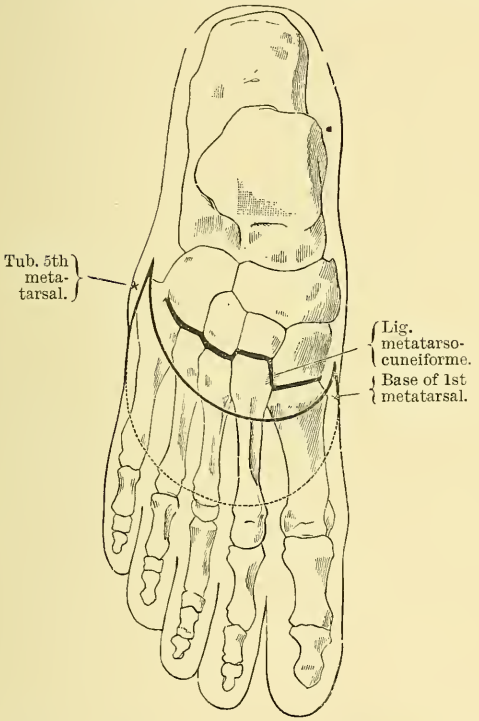

FIG. 210.—Lisfranc's amputation. Formation of dorsal and plantar flaps (dorsal view).

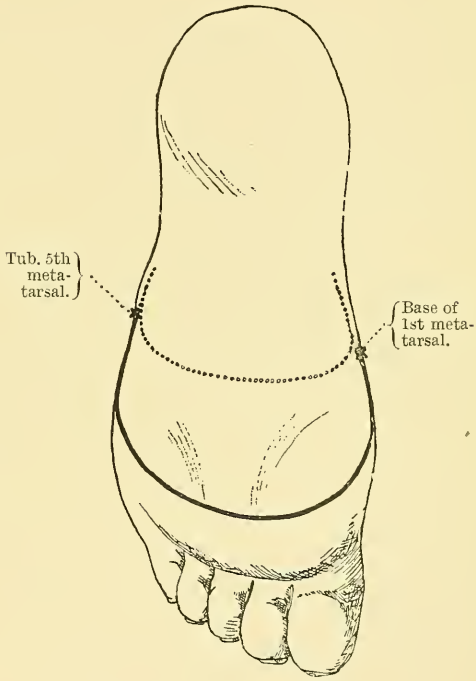

FIG. 211.—Lisfranc's amputation (plantar view).

support, as the important projection at the base of the fifth metatarsal is left, and the only one which is wanting is that of the head of the first metatarsal.

A flap is taken from the sole. The incision, which should begin and terminate slightly on the dorsum, is carried across the sole, in the furrow between the digits and the ball of the toes, as in disarticulation of the toes, while the upper extremities of the incision extend 1 cm. above the level at which the bone is to be divided. The flap is then dissected up off the bones, and a short dorsal flap, extending 1 cm. below the line of division, is cut, after which the metatarsal bones are one by one freed and cut across.

40. Disarticulation at the Tarso-Metatarsal Joints—between the metatarsus anteriorly and the three cuneiforms and cuboid posteriorly (Lisfranc's operation) (Figs. 210 and 211).

The line of the joint lies immediately behind the tuberosity of the fifth metatarsal on the outer side of the foot. The guide on the inner side is the slight prominence of

the base of the first metatarsal. With a finger of the left hand on each of these fixed points, an incision is carried along each side of the foot, and then across the sole at the level of the ball of the toes, thus forming a rounded flap on the sole. This flap, which is thicker posteriorly, is then dissected back as far as 1 cm. in front of the line of the joint. A convex incision is then made on the dorsum, 1 cm. in front of the line of the joint, and, after retraction of the skin, the periosteum is divided close to the important tendon insertions, and pushed back with a raspatory as far as the joint.

The line of the joint is convex forwards and outwards, having an upward indentation corresponding to the retreating middle cuneiform bone, which lies, as compared with the internal cuneiform, as much as 2 to 3 mm. behind the convex joint line, and 1 cm. behind it as compared with the external. The joint is opened opposite the first, third, fourth, and fifth, and lastly opposite the second, metatarsal. The

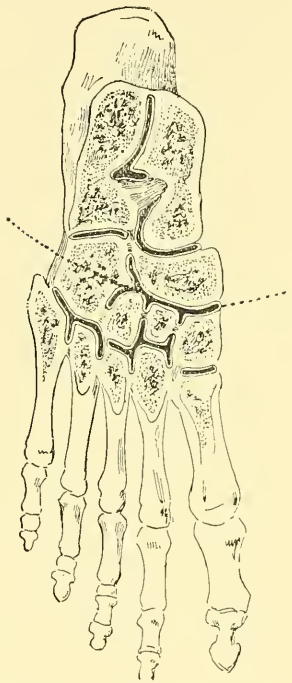

FIG. 212.—Anterior intertarsal amputation (Jäger). Horizontal section of foot (after Heitzmann).

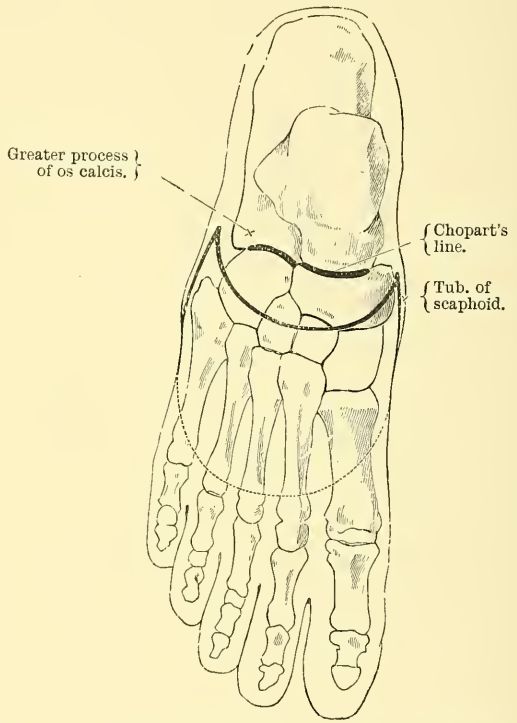

FIG. 213.—Posterior intertarsal disarticulation (Chopart). (Dorsal view.)

strongest ligament is that between the internal cuneiform and the base of the second metatarsal (Fig. 210), and it is only after this has been divided that the joint can be opened out. Division of the base of the second metatarsal in a line with the other joints is rather an advantage than otherwise.

As in all operations upon the foot, the vessels are retained in the plantar flap.

In cases where there is an insufficient skin covering, removal of the projecting internal cuneiform (Hey and Farabœuf) does not interfere with the functional activity of the foot any more than does the typical Lisfranc's operation, as the insertion of the tibialis anticus is still retained, or the tendons may be again stitched in accurate position.

41. **Anterior Intertarsal Disarticulation** (Jäger, Bona) (Fig. 212), between the three cuneiform bones anteriorly and the scaphoid posteriorly, the cuboid being sawn across. The operation is performed in a manner similar to Lisfranc's, but the plantar flap is $2\frac{1}{2}$ cm. shorter. The method has an advantage over Chopart's amputation

in retaining the strong ligaments which pass from the os calcis to the cuboid and scaphoid bones.

The Bona-Jäger operation is a type of one of the "irregular" amputations of the foot, because here amputation is combined with disarticulation. But even these irregular types are justifiable, as every case must be considered on its own merits, many of the tendinous insertions and supporting bony parts being preserved. We have already referred to the removal of the anterior half of the internal cuneiform bone. Similarly, disarticulation of the first metatarsal can be performed instead of Lisfranc's amputation, the other metatarsals being sawn across, and the valuable support of the tuberosity of the fifth metatarsal retained. Further, it is sometimes an advantage to remove only the first three metatarsals with the three cuneiform bones, and to retain the fourth and fifth with the cuboid; or, on the contrary, to remove the latter bones and leave the first metatarsal and the cuneiforms. These cases are exceptions to the rule of amputating the foot transversely.

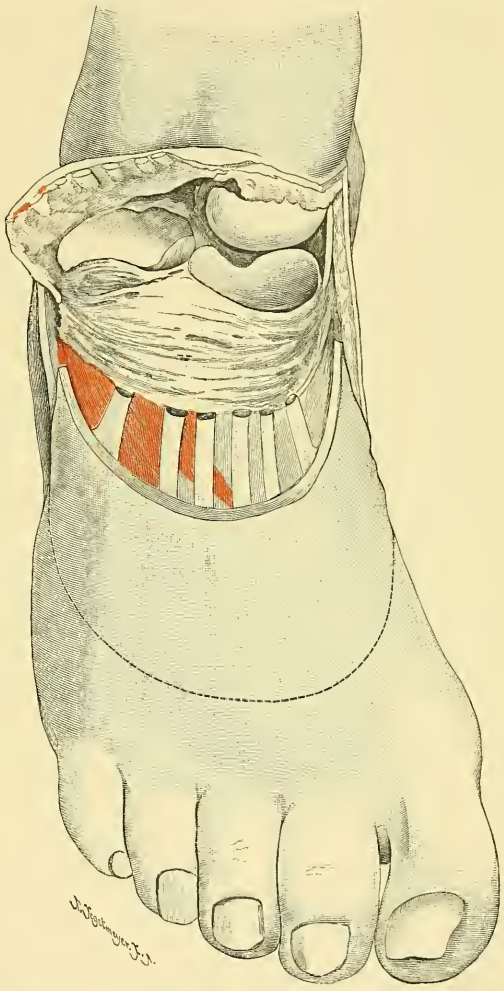

FIG. 214.—Posterior intertarsal disarticulation by a plantar flap and convex dorsal incision. The skin on the dorsum is retracted; the tendons are divided and the joint is opened, exposing posteriorly the articular surface of the head of the astragalus and the os calcis. Anteriorly are seen the articular surface of the scaphoid and part of the cuboid.

42. Posterior Intertarsal Disarticulation (Chopart's operation) (Figs. 213 and 214). The disarticulation takes place between the os calcis and astragalus posteriorly and the cuboid and scaphoid anteriorly. The operation often results in a bad stump from the foot assuming the equinus position, and pressure occurring at the anterior and lower part of the os calcis. This is easily understood since all the tendons on the dorsum of the foot have been divided, while the powerful tendo Achillis is left intact. It is necessary, therefore, to elongate the tendo Achillis, so that the stump may be retained at right angles to the leg until the extensors have gained a firm attachment to the deeper part of the cicatrix. Instead of waiting for this, the ends of the tendons may be sutured at once to the periosteum and ligaments on the dorsum with the foot at right angles.

Internally the joint line lies behind the projecting tubercle of the scaphoid, externally in front of the ridge on the greater process of the os calcis. The operation is performed by making two rounded flaps, the dorsal extending a thumb's-breadth in front of the line of the joint.

The dorsal tendons are cut with the foot at right angles. The dorsal incision is carried down to the bone across the scaphoid and cuboid, the joint capsule being then stripped back for a distance of 1 cm. The joint between the head of the astragalus and the scaphoid, which is convex downwards, is then opened from above. Towards the outer border of the foot the knife must be directed towards the toes, for the outer part of the calcaneo-cuboid joint is concave anteriorly, *i.e.* the line of the joint is ~ shaped. If the knife be carried too far back, it will open the astragalo-calcanean joint.

The chief structures which unite the bones are the inferior calcaneo-scaphoid and the calcaneo-cuboid ligaments.

When the foot has been disarticulated the extensor tendons (tibialis anticus, the extensor longus digitorum, and the peroneous tertius) should be sutured to the dorsal periosteo-capsular flap, the foot being held at right angles.

Hoffmann[1] has described a modification of Chopart's operation, suggested by Witzel, where the toes are retained. A rectangular area of skin containing the sinuses is first excised from the dorsum, the bones are then disarticulated at Chopart's joint, and at the metatarso-phalangeal joint (or the metatarsals sawn across), and the toes along with the skin of the sole are retained: the latter is redundant and folded at first, but soon shrinks.

43. Intertarsal Amputation. When the soft parts are insufficient for a Chopart's

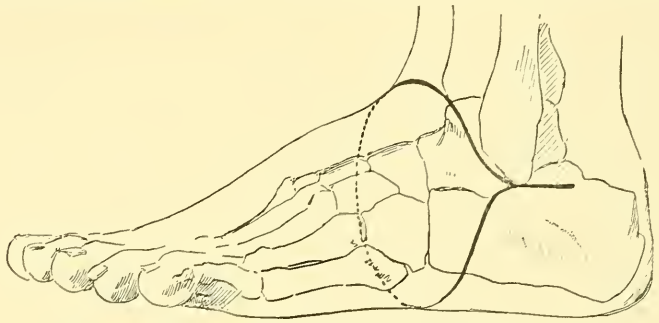

FIG. 215.—Subastragaloid disarticulation (Malgaigne, Textor).

amputation, the articular surfaces of the astragalus and os calcis are sawn off after disarticulating as in Chopart's operation. A movable stump may still be obtained, as the capsule of the ankle-joint (which does not extend farther forwards than 1 cm. behind the cartilage of the head of the astragalus) need not be opened.

44. Subastragaloid Disarticulation (Malgaigne, Textor) (Fig. 215). A racket-shaped incision is made, the handle being placed horizontally immediately behind and below the tip of the external malleolus, and the circular incision carried round the foot at the level of Chopart's joint. The incision is somewhat similar to that of Perrin and Chauvel, and is closely allied to Farabœuf's internal plantar flap.

The joint between the astragalus and scaphoid is opened from the dorsum without opening the calcaneo-cuboid joint. A narrow knife is then passed backwards and slightly upwards beneath the head of the astragalus so as to divide the strong interosseous ligament between it and the os calcis. The soft parts are then dissected from the os calcis, first from its upper surface, then from its outer and under surfaces, and lastly from its inner and posterior surfaces. The greatest difficulty is met with at the inner side in clearing the projecting sustentaculum tali.

If the soft parts are insufficient, the projecting head of the astragalus may be sawn off. The astragalus fits well into the heel cap. The stump bears weight excellently.

45. Subastragaloid Osteoplastic Amputation. This operation, introduced by Hancock, consists in sawing off the tuberosity of the os calcis, and applying it to the

[1] *Deutsche med. Wochenschr.*, January 1899.

lower surface of the astragalus, from which the articular cartilage has been sawn off. The circumstances in which this operation is called for are exceptional.

Ssabanejeff has also recently described an osteoplastic subastragaloid amputation.

46. Disarticulation at the Ankle-Joint (Syme's operation) (Figs. 216-220). This operation was performed by Syme by means of a flap taken from the heel. The

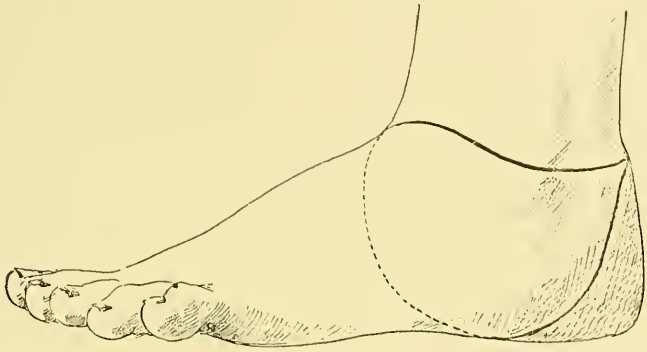

FIG. 216.—Disarticulation at the ankle-joint by means of an internal flap (Syme's amputation modified).

disadvantage of the method is that after the heel flap has been brought into position a cavity still exists between it and the bones.

The racket incision is preferable, the flap, which is taken from the inner side of the foot, commencing at the tip of the external malleolus (Fig. 216). This method resembles most the internal flap recommended by Farabœuf, and the methods of

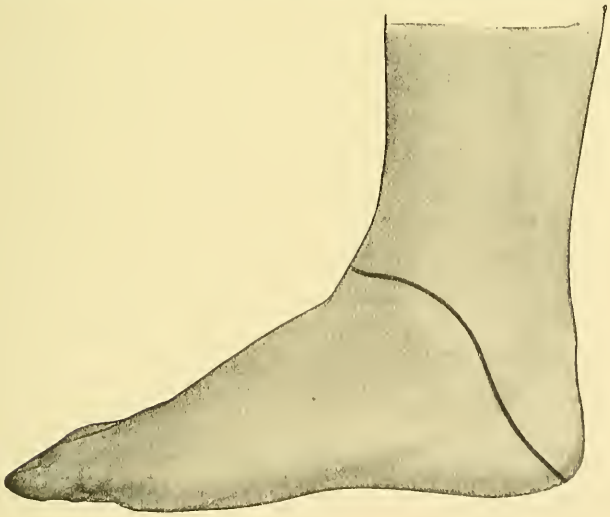

FIG. 217.—Guyon's wave-cut for disarticulation at the ankle.

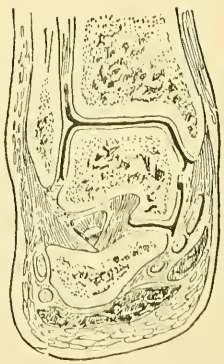

FIG. 218.—Coronal section through the ankle-joint (Henle).

Roux and Verneuil. According to Tauber, J. Bell used an internal heel flap in 1885. After dividing the skin, the strong bands of the external lateral ligament, the peroneal tendons, and the extensor tendons are cut across at the level of the retracted skin. The ankle-joint is opened, and the inner aspect of the os calcis is dissected from above downwards from the internal flap by keeping close to the bone. The malleoli are cleared and divided obliquely, but the cartilaginous covering of the tibia is left intact.

Poncet has shown that a very good stump can also be obtained by means of a dorsal flap. Guyon's wave-shaped incision is still better (Fig. 217), extending from the front of the ankle-joint backwards to the lower part of the tip of the os calcis. When enough skin cannot be secured to cover the epiphysis and the articular surface of the end of the tibia, Samter has turned down a strip of skin from the leg which he places over the wound like a stirrup, leaving the rest of the raw surface to granulate.

FIG. 219.—Disarticulation of the ankle-joint by an internal flap (inner side of foot). The joint has been opened above: the edges of the wound are gaping.

47. Osteoplastic Amputation of the Foot (Pirogoff) (Fig. 221). Pirogoff's operation derives its importance from the fact that it was the first osteoplastic operation introduced. It dates from 1854.

The tuberosity of the os calcis is sawn off and applied to the sawn surface of the tibia and fibula. The great advantage of retaining the tuberosity of the os calcis is that it fills the cavity or cup in the heel flap, and that the skin of the latter is well nourished. It is thus preferable to the original operation of Syme.

The simplest and best method of performing the operation is as follows:—Tenotomy of the tendo Achillis is first performed. The foot being held at a right angle, an incision is carried from the middle of one malleolus vertically downwards in the axis of the leg and across the heel to end at the middle of the opposite malleolus (stirrup incision). The whole of the incision extends down to the bone so as to divide all the tendons completely. Its extremities are united by a second incision passing

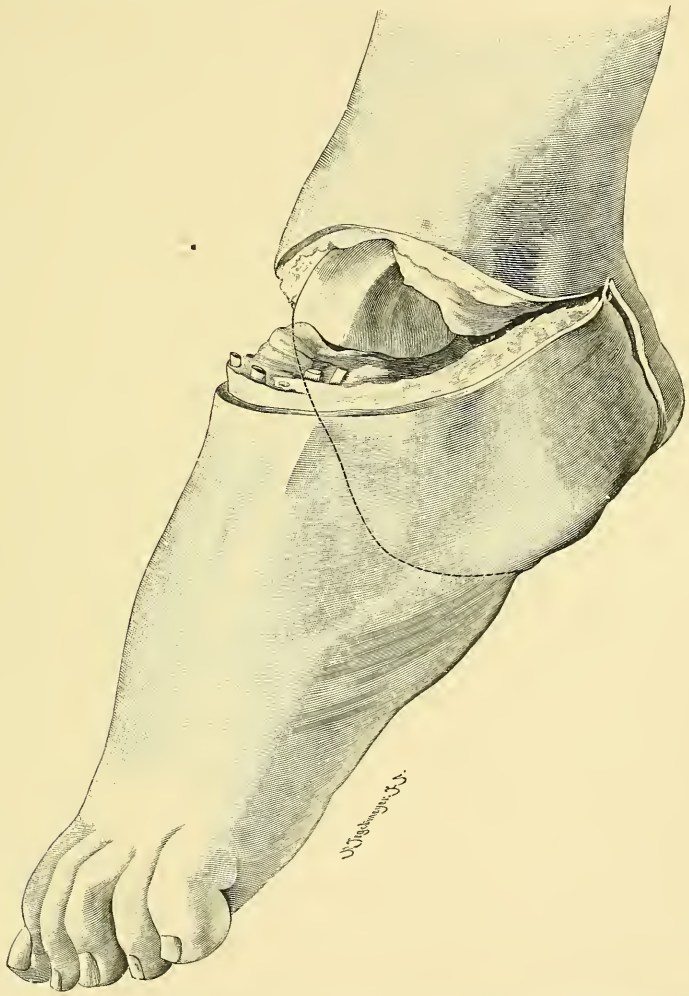

FIG. 220.—Disarticulation of the ankle by an internal flap (outer side). The joint is opened in front and externally; the head and outer surface of the astragalus and the tip of the external malleolus are exposed.

forwards across the dorsum of the foot exactly at right angles to the stirrup incision, and reaching a full thumb's-breadth in front of the line of the ankle-joint. It is carried through the skin and fascia only, the extensor tendons being divided at its retracted edge.

The ankle-joint is now opened from the front, the lateral ligaments are divided, and the astragalus is exposed as far back as its superior surface. The tuberosity of the os calcis is then sawn off vertically immediately behind the astragalus in the same

plane as the heel incision, and is turned upwards along with the skin of the heel. The malleoli are freed and sawn off 1 cm. above the line of the joint. It is unnecessary to preserve the periosteum as osseous union is obtained. The sawn surfaces are brought into accurate apposition by suturing the flap. The subsequent gait is excellent.

In order to avoid the tilting of the os calcis, which in our opinion is very considerable, many surgeons have sawn the os calcis obliquely (Günthner, Sedillot, Schede, Volkmann), or horizontally (Busk, Bruns, Pasquier, Lefort), or in a curved or angular direction (Bruns, Böckel). Küster considers Lefort's method of sawing the os calcis horizontally far better than the typical Pirogoff operation, because in the latter the thin skin of the heel is easily abraded. We regard this as unusual: our patients always find the stump extremely useful. It depends entirely on the manner in which the operation is performed. Küster proposed not to saw the os calcis at all, but to disarticulate the foot along with the astragalus, and to place the os calcis directly below the leg (intercruro-calcanean disarticulation). He employs a convex incision 1 cm. below the malleoli as far as the prominence of the fifth metatarsal, with a somewhat shorter dorsal convex incision across the astragalo-scaphoid joint. The astragalus is removed. The lower flap is brought up over the anterior surface of the os calcis.

If the os calcis is to be sawn horizontally, it is advisable to make an oval incision

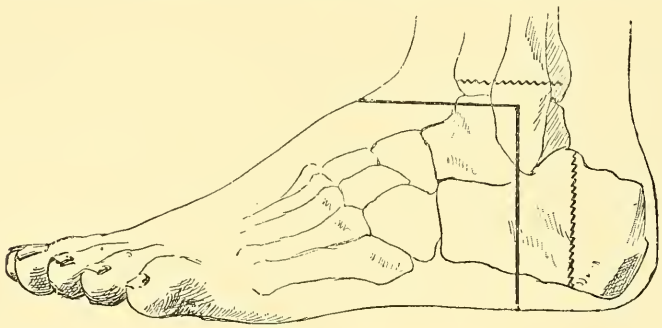

FIG. 221.—Osteoplastic disarticulation of the foot (Pirogoff).

beginning (Fig. 215) horizontally below the tip of the external malleolus. Through this horizontal incision access is obtained for sawing through the bone.

Tauber has further modified Pirogoff's operation by making an internal flap similar to that described in the previous section under Syme's operation. Instead of turning up the soft parts off the os calcis in the internal flap, he saws through the latter bone in the sagittal plane, and applies the inner half to the sawn ends of the bones of the leg.

All these modifications have a disadvantage over the method first described, viz. that part of the scar comes to lie nearer the under surface of the foot.

The original Pirogoff method is still the best, because the tuberosity of the os calcis is most frequently unaffected both in diffuse tuberculous disease of the joint and in injuries.

(f) Amputations of the Leg

48. Amputation of the Leg (Figs. 222-227). In the description of amputations in general we have already alluded to the incisions that may be used in amputating through the leg, and have also shown how stumps in this region can be obtained which are capable of bearing weight. An aperiosteal amputation should be performed at all levels.

The lines of incision at the various levels are shown in Figs. 222 and 223.

The longer flap is always taken from the front unless there are special reasons to

the contrary. At the ankle, it consists only of skin and fascia, while even farther up the flap largely consists of skin and fascia as there is no muscle on the inner surface of the tibia.

For this reason and to prevent pressure of the flap on the spine of the tibia, the longer flap should be taken in the middle third from the antero-external aspect of the leg. Farabœuf also speaks highly of an antero-external flap.

After dissecting up the flap as far as the upper end of the incision the muscles, which have not yet been divided, are cut transversely. One has to be careful in the interosseous space to cut exactly transversely so that the vessels may not be injured in their long axis.

The periosteum is then divided by a circular incision, and pushed downwards for a distance of 1 cm., at which level the bone is sawn through, thus leaving a projecting end of bare bone. Sharp edges, especially the anterior border of the tibia, should be rounded off, while the fibula should always be divided 1 to 2 cm. higher than the tibia so that it may not project into the soft parts.

In the region of the upper and lower epiphyses the bone should be sawn convexly as in Fig. 222, and the sharp margins rounded off with cutting forceps. Here, where there are no muscles, the deep fascia is brought directly over the sawn surface of the bone so that the skin may be freely movable. Wilms attains the latter object by interposing the tendo Achillis between the flap and the end of the bone. We merely mention that Ollier and Kummer use the skin of the heel as a covering for the stump to ensure that it will be able to bear weight, while Kummer waits until it has become contracted by the formation of granulation tissue.

It is convenient here to describe the typical osteoplastic

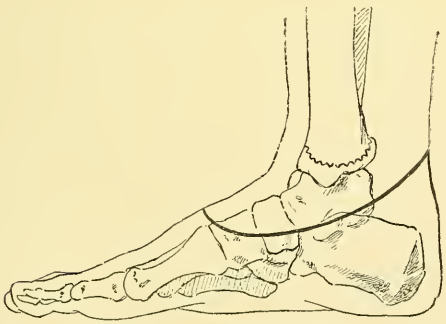

Fig. 222.—Amputation through the malleoli.

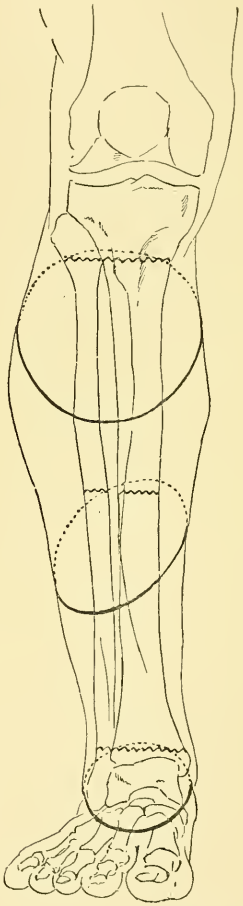

Fig. 223. — Amputations through the leg below the knee, in the middle third, and through the malleoli.

method, which, although it affords good results, is not so simple as the aperiosteal method.

We pointed out, in discussing amputations in general, that Bier first adopted a complicated method which was subsequently simplified by Lanz and Gleich. We agree to a large extent with Storp and Bunge's description of the method as performed by Eiselsberg, with, however, a few modifications.

Bunge describes the very simple operation as follows :—An antero-internal skin flap is dissected up, the centre of the flap corresponding to the inner surface of the

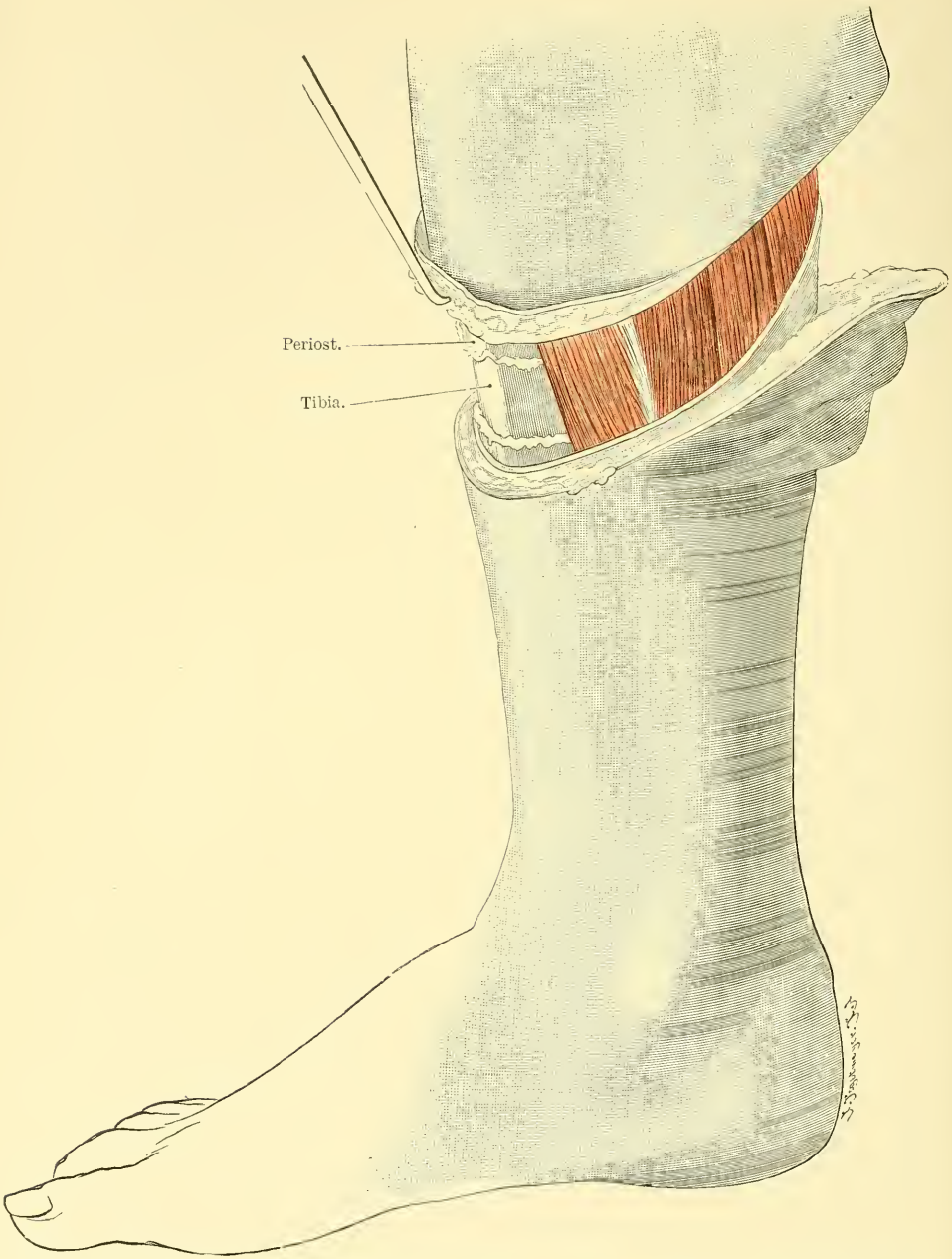

FIG. 224.—Osteoplastic amputation of the leg. An oblique incision is made through the skin and fascia, which are retracted ; the periosteum of the tibia is divided and stripped slightly upwards.

tibia. Then the periosteum is divided transversely at the level of the apex of the flap, and two lateral incisions are carried upwards through the periosteum 3 mm. behind the anterior and internal border of the tibia. The periosteum having been separated upwards for a short distance, a wedge is removed from the surface of bone

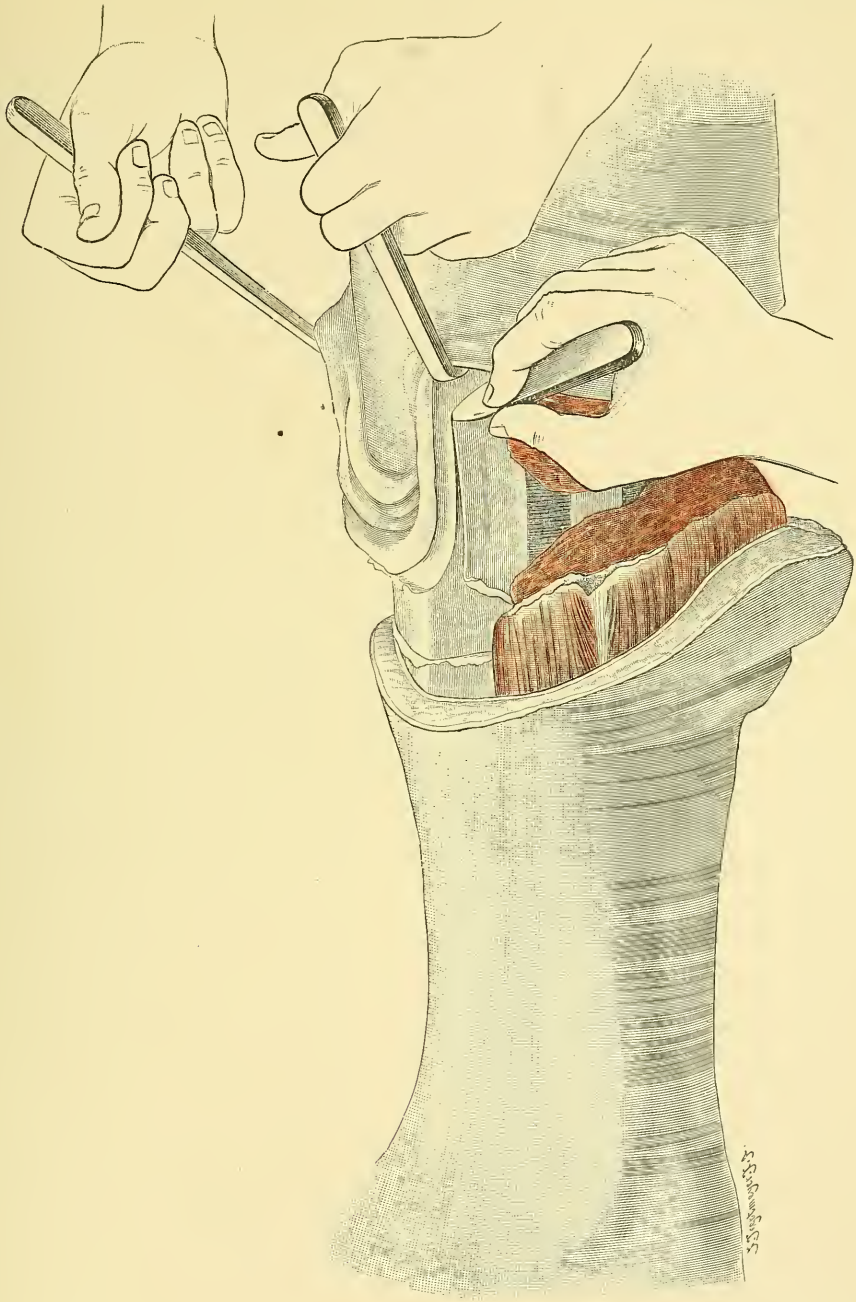

FIG. 225.—Osteoplastic amputation of the leg. The skin edges are retracted upwards; the periosteum is incised along the line at which the bone is to be sawn.

thus laid bare, so as to allow the blade of the saw to be applied parallel to the inner surface of the tibia, from which a layer of bone is removed subjacent to the rectangular flap of periosteum. This layer is next broken across with an elevator at its base, at

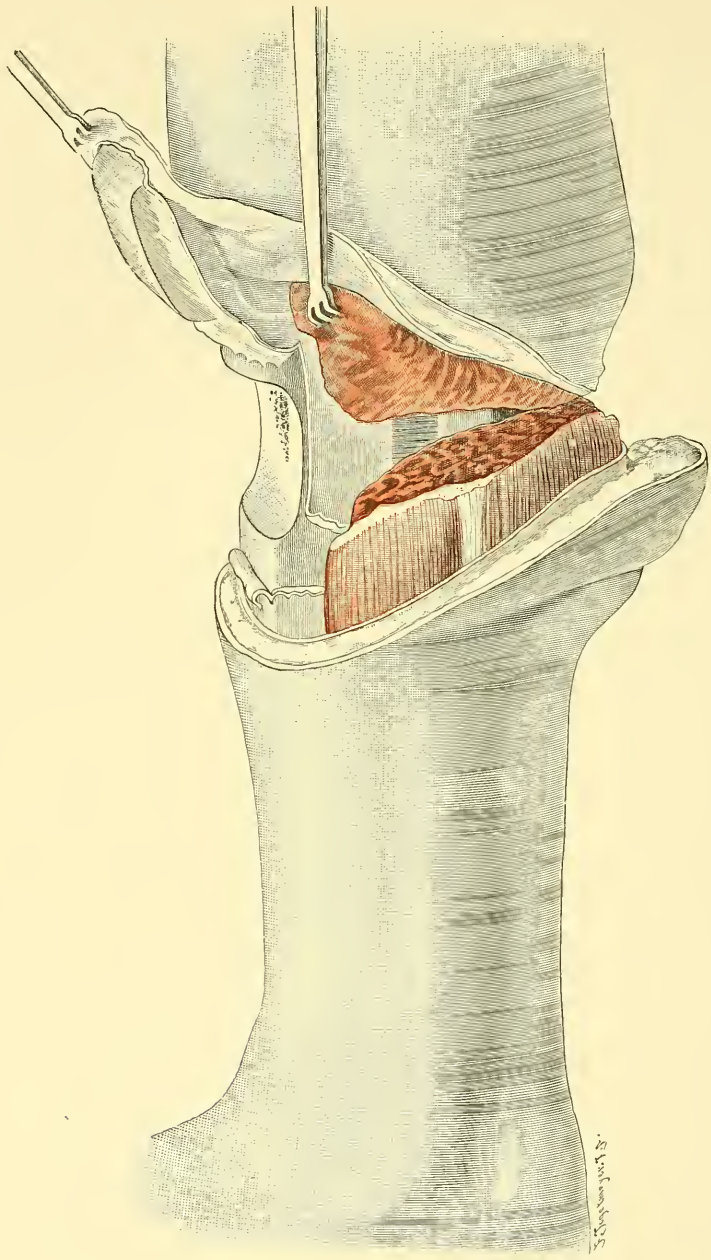

FIG. 226.—Osteoplastic amputation of the leg. A flap has been turned up consisting of skin, periosteum, and bone ; the periosteum has been stripped rather higher than the base of the flap of bone.

which level the periosteum is separated still farther upwards and the soft parts divided circularly. The bones are then sawn across and the osseous flap is sutured over the sawn surface of the tibia.

The principle formulated by Storp can be carried out in a simple way by retaining

the continuity of the osteoplastic flap with the skin. This may be done by chiselling the periosteo-osseous flap parallel to the inner surface of the tibia and reflecting it up along with the skin, the periosteum covering the lateral and posterior surfaces of the tibia as well as that of the fibula being also retracted.

It is desirable (and not difficult) to retain the continuity of the deeper parts with the skin, otherwise necrosis of the latter frequently occurs. Figs. 224, 226, show how this may be done, the saw being still used. The disadvantage of the chisel is that it often causes considerable splintering. We consider it unnecessary to provide an osteoplastic covering for the fibula. All that is required is to see that it does not project: if it does, it should be sawn higher up. We make an oblique incision through skin and fascia as in Fig. 224, but only reflect the skin sufficiently far up to enable us to divide the muscles transversely down to the bone. The skin over the tibia is then retracted with hooks, the periosteal flap is mapped out as in Fig. 225, and the strip of bone is removed with a saw, leaving a concave surface (Fig. 226). The fibula is now divided at a higher level, after which the tibia is sawn across convexly so that it will fit the flap.

In regard to the various methods of dealing with the thick muscles of the calf, we would simply mention that Treves, following Hey and Lee, utilises them in the flap posteriorly—a posterior musculo-cutaneous flap. In this way a smooth wound surface is obtained, if the large muscles of the calf alone are made use of. Teale and

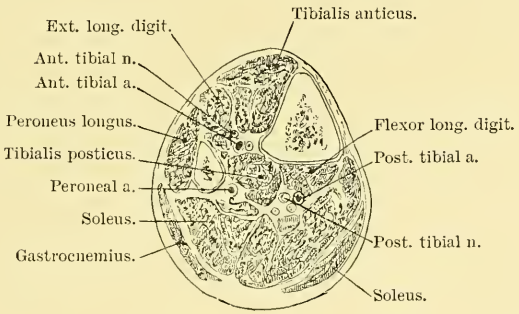

FIG. 227.—Transverse section through the leg above its middle (from a photograph).

Bruns endeavour to make the wound surfaces smaller by combining circular or semi-circular incisions with a longitudinal incision down to the bone.

Teale makes a large anterior and a small posterior rectangular flap. Bruns employs the original operation of Celsus, *i.e.* circular incision through skin, with circular division of the muscles at a higher level and subperiosteal shelling-out of the bone. In the description of amputations in general, we have already mentioned that the racket or double flap incisions are very suitable when thick masses of muscle have to be dealt with.

The anterior and posterior tibial vessels—the former lying upon the interosseous membrane, the latter upon the deep muscles of the calf—are met with along the whole length of the leg, and in addition, in the lower two-thirds, the peroneal artery, which lies between the flexor longus hallucis and the posterior surface of the fibula.

(h) Amputations at the Knee

In the knee, just as in other joint regions, amputation as high as possible through the bones on the distal side of the joint is preferable to disarticulation, provided the tendon insertions into the upper end of the tibia and fibula are preserved (*vide* the excellent stump as regards weight-bearing, illustrated in Fig. 205); if these are not retained, there is no object in the amputation. A second important point in deciding which of the numerous methods is to be employed is whether the joint is healthy or

not. Ssabanejeff has shown that even when the joint is diseased, a form of high amputation through the leg, which admits of the removal of the diseased synovial membrane, is still possible. After consideration of these two main points, all methods which guarantee a stump capable of bearing weight can be employed. On these principles we describe the different methods.

The question is still undecided whether or not it is advantageous, provided the knee-joint is healthy, to retain the capsule, while the same remark applies to the preservation (or non-preservation) of the patella. The latter is always of use when an artificial limb is fitted. In view of the comparatively small amount of muscular tissue in the region of the knee, the flap consists merely of skin and fascia, at least on the anterior surface. The oblique incision is to be preferred as the large size of the condyles of the femur requires that special care be taken to provide an ample covering of skin.

49. Disarticulation at the Knee (Figs. 228, 229). This is performed if the joint is in a healthy state, but amputation higher up is necessary if it is diseased. By retaining the capsule of the joint along with the synovial membrane (Socin) a freely movable covering for the stump is provided; but the same can be obtained if the flaps

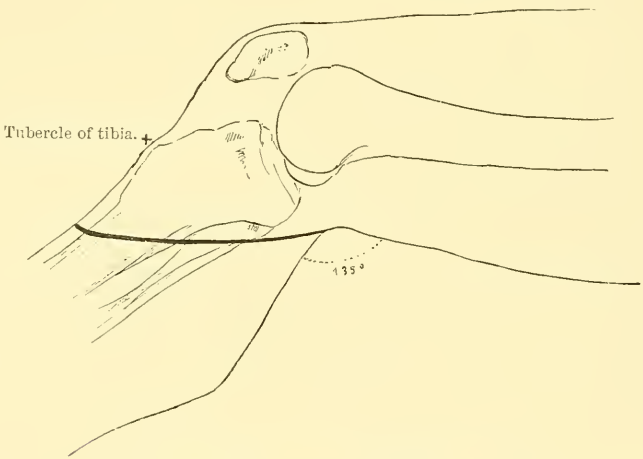

FIG. 228.—Disarticulation at the knee-joint.

are carefully stitched and asepsis is complete. Owing to the great breadth and thickness of the condyles there must be no lack of skin taken from the sides. For this reason the oblique incision is more suitable than any of the flap methods. An excellent stump is got if aseptic healing occurs.

(*a*) *Retaining Capsule and Patella.* An anterior flap is obtained by making an oblique oval incision, beginning posteriorly opposite the level of the joint, and ending anteriorly four fingers'-breadth below the tubercle of the tibia. If the leg be held with the knee half-bent (making an angle of 135° with the thigh), the incision falls in the continuation of the long axis of the thigh (Fig. 228). After dissecting up the skin and fascia, the capsule with the ligamentum patellæ, the semilunar cartilages, and lateral ligaments, are cut through anteriorly and laterally; the crucial ligaments are separated from the spine of the tibia; the posterior part of the capsule is cut through along the tibia, and the operation is completed by making a transverse incision through the soft parts posteriorly. The chief vessels requiring ligature are the popliteal artery and vein, but the articular arteries and branches to the gastrocnemius may also require tying. The popliteal nerves are pulled out and cut across high up.

When the cavity of the joint is retained it is necessary to introduce into it a drainage tube through a special opening on each side of the patella. The skin wound can then be completely closed.

(*b*) *With Removal of the Capsule and Patella.* Oblique incision as above. The fascial flap is dissected up to above the level of the patella, where the quadriceps tendon and insertions of the vasti to the patella are cut through. The synovial pouch underneath the quadriceps is dissected up on its outer side, separated from the front of the femur and divided at the margin of the cartilage. The crucial ligaments are severed close to the femur, the lateral ligaments are divided below the condyles, and the posterior part of the capsule is removed, after which the soft parts in the popliteal space are then divided from without.

The method of making an anterior flap is not so satisfactory as the oblique incision. Treves prefers two lateral flaps (Stephen Smith's operation), consisting of skin and fascia only, and this method is very popular with many surgeons.

The skin cicatrix, however, rests below on the end of the bone, while with our oblique incision it is entirely on the posterior aspect, even more so than it is after a circular incision.

Miller, with the knee fully extended, makes a circular incision round the limb $2\frac{1}{2}$ inches below the condyles. The soft parts retract so much on the flexor surface that it is only necessary to dissect up the flap on the extensor surface. A posterior scar results.

Bier declares that disarticulation at the knee gives an exceedingly good stump

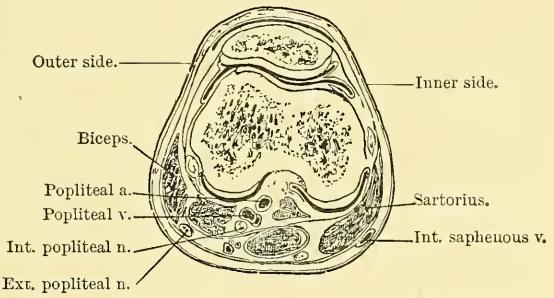

FIG. 229.—Section through the knee-joint at the level of the condyles of the femur.

because there is no bony scar formed. When there is plenty of skin it is to be preferred to all other methods.

All methods which result in a scar being left on the under surface of the stump are not so satisfactory. Naturally a posterior oblique incision may be employed if the skin in front is deficient.

(i) Amputations through the Thigh

These are among the most common amputations and are undertaken for injuries (complicated fractures and crushes) gangrene, and in suppurative and diseased conditions of the knee-joint. The choice of method largely depends on the level at which the amputation is to be performed. In the lower third where the muscles are scanty the coverings for the ends of the epiphysis and juxta-epiphyseal regions consist simply of skin and fascia. The stump, however, is functionally good, provided that the bone is rounded off, that the cicatrix lies posteriorly (oblique incision), and that the mobility of the skin is maintained by covering over the sawn surface of bone with a layer of deep fascia. In this respect the conditions are similar to those in disarticulation at the knee.

In the middle of the thigh one should still attempt to procure a stump adapted for bearing weight. All incisions therefore such as the circular and double flap incisions, in which the cicatrix generally lies over the end of the stump, are to be avoided as a rule. On the other hand, a long anterior flap is very suitable, as, owing

to the conical character of the limb in this situation, the oblique incision is more difficult. Simplification of the incision through the muscles (by making a circular incision through them in one plane as in the old Celsus operation) is recommended

Fig. 230.

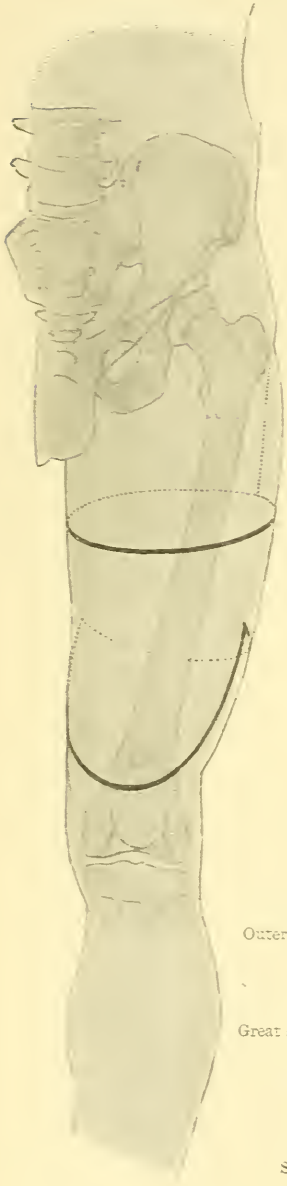

Fig. 231.

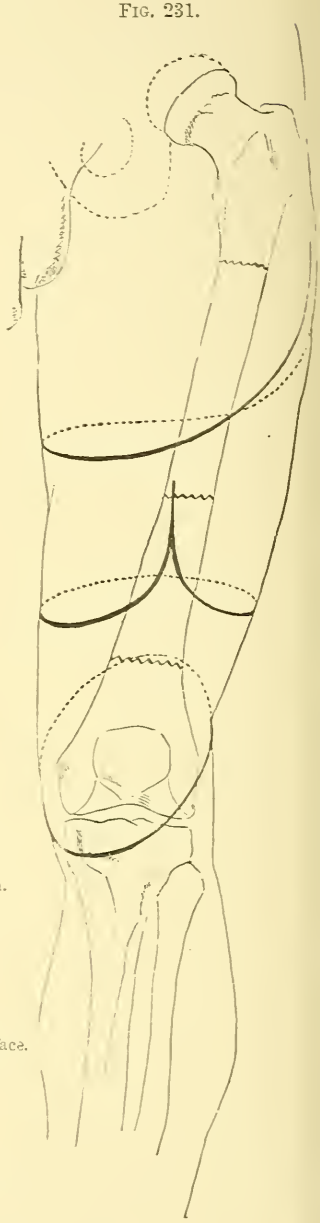

Fig. 230. — Flaps for amputation through the lower third of the thigh: and for amputation through the upper third (racket incision).

Fig. 231.—Amputation of the thigh below the trochanters: through the middle of the femur: above the condyles (supracondyloid).

Fig. 232.—Transverse section through the thigh (from a photograph).

Fig. 232.

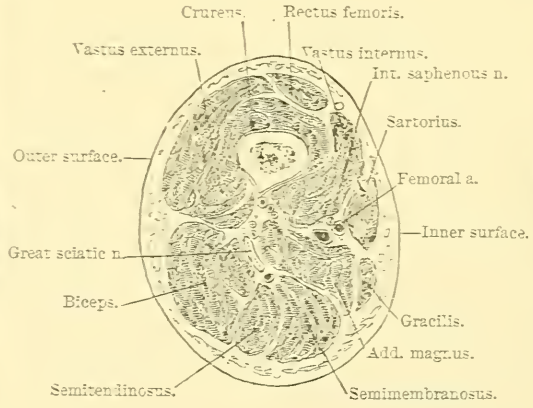

here as it was in the case of the muscular portion of the middle of the leg (Bruns), a flap of skin and fascia only being placed over the large cut surface of the muscles. If the muscles are atrophied, the anterior flap of skin and fascia should contain the whole thickness of the quadriceps.

When the artificial limb takes its purchase from the pelvis, a weight-bearing stump

is no longer necessary, and the steps of the original Celsus operation should be followed, *i.e.* the successive circular division of skin and fascia, then of muscles, and subperiosteal division of the bone. The popular methods of making lateral flaps, specially recommended by Esmarch, are equally good, as they result in a smooth wound, provide for good drainage, and are simple to perform, *e.g.* in war, where there is uncertainty as to the subsequent course of the wound.

In the upper portion of the thigh the conditions are different. Here there is no question of pressure of the artificial limb on the stump, and a stump capable of bearing weight is not required. All the more care, however, must be taken to provide a muscularly strong stump.

The position of the scar is here of secondary importance compared with the preservation of the muscles and soft parts. The racket and its modification, the lanceolate, incision is the best method to employ. The longitudinal portion of the incision is carried down to the bone along the posterior border of the vastus externus, the periosteum is dissected off the bone, and the latter divided according to Neudorffer's method, or with a Gigli saw. The bone is then shelled out downwards and, after retraction of the skin upwards, the muscles are cut through with a single circular sweep rather more than half the diameter of the limb below the level of division of the bone.

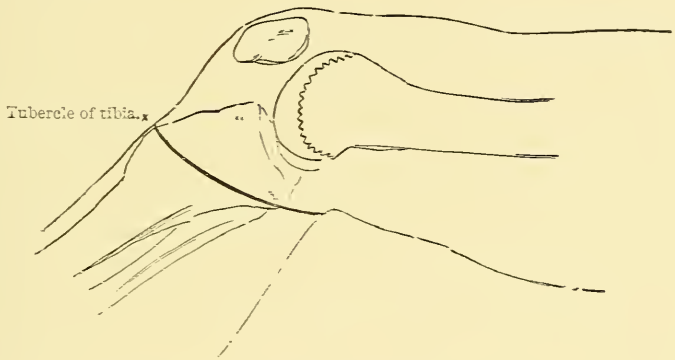

FIG. 233.—Amputation through the condyles (Carden).

50. Amputation of the Femur through the Condyles (Carden and Buchanan) (Fig. 233). Buchanan, in amputating at the lower end of the femur in children, simply separated the lower epiphysis of the femur.

Carden sawed off the condyles in a curved direction through their greatest breadth, obtaining in this way an excellent stump, and one well adapted for bearing weight Amputation through the condyles should take the place of disarticulation at the knee when the joint is diseased and removal of the synovial membrane is necessary. This indication calls for a different method of performing the operation. Here also the oblique incision is prolonged anteriorly so as to place the scar well away from the stump. The incision begins posteriorly at the level of the epicondyles and reaches down to just below the tubercle of the tibia. The flap, consisting of skin and fascia, is dissected upwards to above the patella: the quadriceps is here divided down to the synovial membrane of the joint, which is exposed and freed as far as its upper limit without opening the joint, and then stripped downwards off the bone to below the epicondyles of the femur. An incision is then carried round the femur down to the bone, from the upper border of its trochlear surface through the lateral ligaments just below the epicondyles, and transversely across its posterior surface immediately above the synovial pouches posteriorly behind the condyles. The lower epiphysis of the femur is sawn through convexly along this line, and the soft parts on the posterior aspect of the limb are divided.

The stumps which we have seen from this operation (and our teacher Lücke was very fond of the method) were all painless,[1] and bore pressure exceedingly well, in spite of the fact that the bone cicatrix was directed downwards. Moreover, the skin was always freely movable upon the stump, because the fascia was placed over the sawn surface of the bone, and the scar lay entirely on the posterior aspect of the stump.

51. Osteoplastic Amputation of the Femur through the Condyles (Ssabanejeff). Ssabanejeff has devised a form of *osteoplastic amputation* through the condyles in which the anterior flap contains a piece of bone sawn from the anterior surface of the

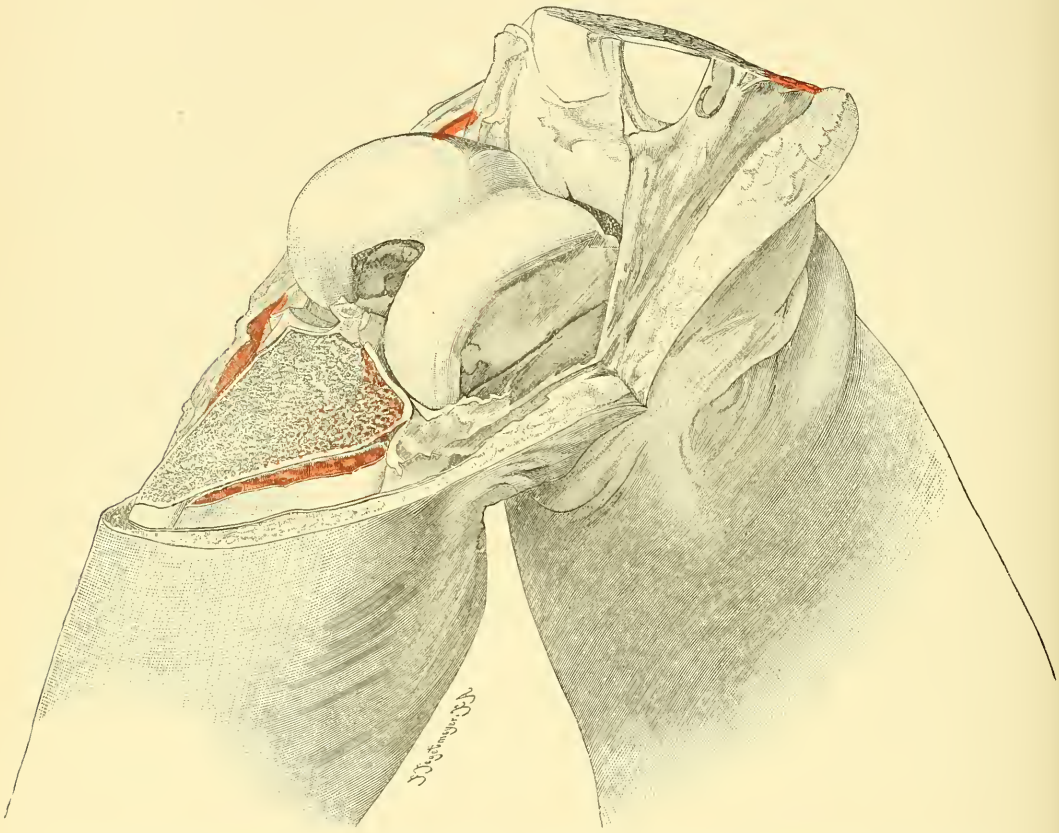

FIG. 234.—Osteoplastic amputation through the condyles of the femur (Ssabanejeff). An oblique incision has been made through skin and fascia as in Carden's amputation (Fig. 233). The tibia is sawn through obliquely upwards and backwards as high as the head of the fibula, and the flap containing the upper section of the bone is thrown backwards. The line of section through the condyles of the femur is shown.

tibia. After retraction of the anterior flap the saw is applied close to its anterior edge and carried in an oblique, or, better, slightly concave direction backwards to the posterior surface of the tibia, so as to remove from it a cap of bone (Fig. 234). The flap containing the piece of bone is reflected upwards as in the operation just described, after dividing the capsule and the lateral ligaments. The condyles of the femur are then divided obliquely as Fig. 234 shows, *i.e.* from above downwards and

[1] We must point this out in opposition to Bier, who disapproves of Carden's operation. We have seen a large number of excellent stumps capable of bearing pressure. Unfavourable criticism must be due to variations in execution and after-treatment.

backwards, after which the soft parts posteriorly are cut through transversely at the level of the joint.

In this way the skin and bone (anterior surface of tibia) most accustomed to bear pressure are both brought below the face of the stump, which is therefore an excellent one. The capsule, as well as the insertions of the sartorius, gracilis, and, if necessary, the biceps, are retained. We are indebted to Djelitizin for the idea of sawing the tibia obliquely instead of vertically as originally proposed by Ssabanejeff. Abrashanow has introduced a reverse operation, viz. the formation of a posterior flap containing the posterior half of the tuberosities of the tibia, which are applied to the horizontal and frontal sawn surfaces of the femur and patella.

These methods may be applicable when a portion of one of the bones containing a focus of disease must be removed. According to Hilgenreiner, Wölfler has tried them on the living subject and has obtained good and permanent functional results.

52. Supracondyloid Amputation. When sufficient skin cannot be got to cover the condyles a supracondyloid amputation must be performed. The amputation can be performed either by an oblique incision or by the flap method. In the latter case

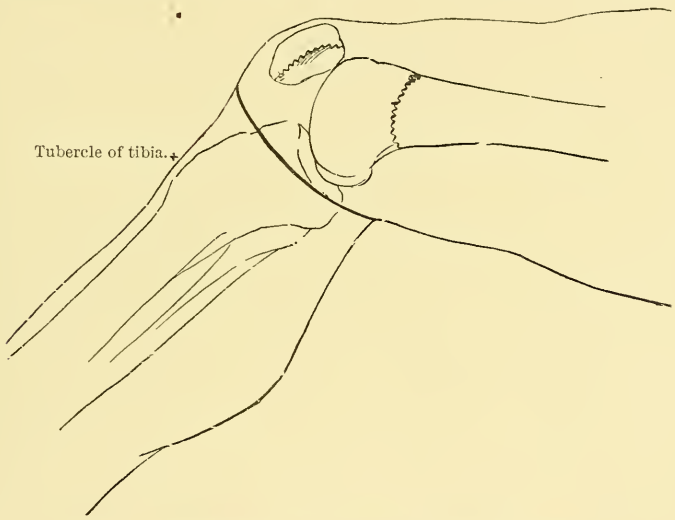

FIG. 235.—Osteoplastic supracondyloid amputation (Gritti).

the flap should be taken from the antero-internal aspect (Fig. 231), because if a purely anterior flap be made, the adductors pull the femur inwards and forwards and cause it to press against the inner corner of the wound. A favourite amputation with many surgeons is Spence's method, modified by Farabœuf, in which a large anterior and a small posterior flap are made, the latter being replaced by a mere convex incision. In this method also we prefer to make the anterior flap slightly on the inner side.

A good stump capable of bearing pressure is obtained after amputation above the condyles, by sawing the bone convexly and rounding off the corners. If the skin (*i.e.* a flap of skin and fascia) is not to be trusted on account of adhesions, infiltration or defective nutrition, it is well, according to Wilms, only to dissect up the skin to the upper border of the patella, to divide the quadriceps tendon at this point, and then to continue the formation of the flap obliquely upwards through the vasti. The quadriceps tendon is stitched to the periosteum behind, so that the end of the bone is covered.

53. Osteoplastic Supracondyloid Amputation of the Thigh (Gritti) (Figs. 235 and 236). An oval incision is made with its upper end situated posteriorly above the prominence of the condyles, its lower end anteriorly three fingers'-breadth below the

patella. The ligamentum patellæ is divided obliquely and a portion retained for subsequent suture. The knee-joint is now opened, and the capsule detached upwards along with the skin flap above the condyles, where the periosteum is divided all round and stripped off the bone two centimetres higher, *i.e.* the level of division of the bone. The femur is sawn through transversely immediately above the condyles, preferably leaving a convex surface. The cartilage is removed from the patella in such a way as to leave a concave osseous surface, which is applied to the convex sawn surface of the femur and held in position by a few sutures which unite the margin of the patella and the patellar ligament to the periosteum of the femur.

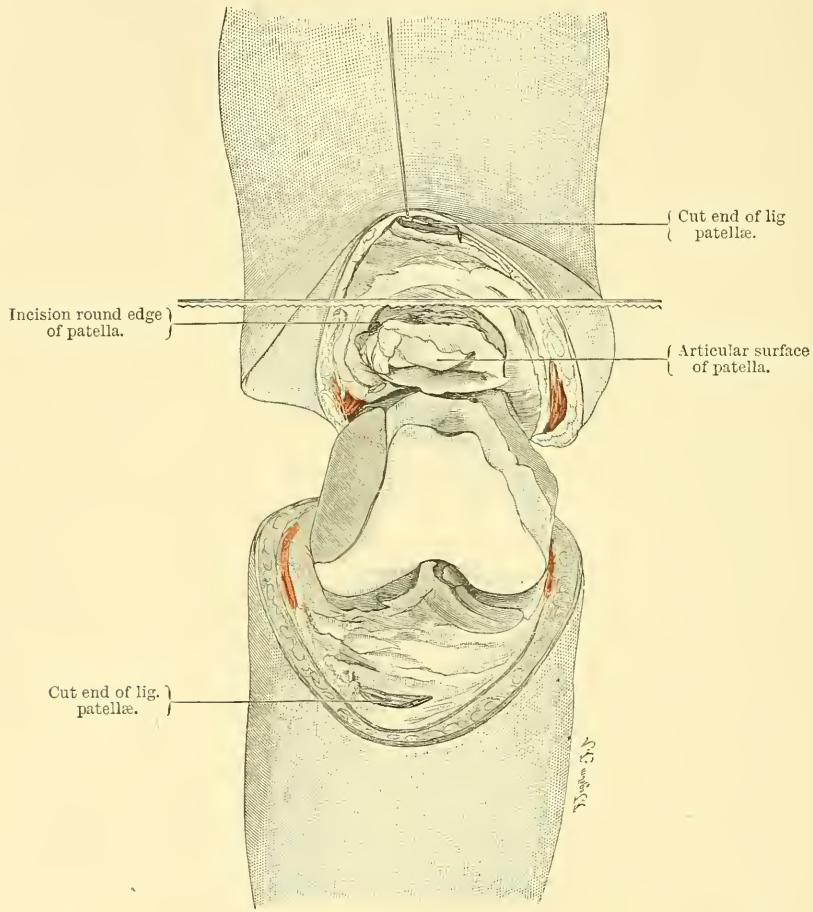

FIG. 236.—Supracondyloid osteoplastic amputation (Gritti) by an oval incision.

Balacescu[1] speaks in high terms of Gritti's operation, especially in regard to the shape of the stump obtained. In 111 reported cases he found the mortality from the operation was only 7·2 per cent.

Silbermark's modification[2] of Mosetig's operation, in which the stump of the ligamentum patellæ is merely stitched to the ends of the flexor tendons will be found described in former editions of this work.

54. Amputation through the Middle of the Thigh. The mass of muscle here affects the choice of method (*vide* Figs. 230 and 231). In the typical method a

[1] *Revista de chirurgie*, Bukarest, 1903, Nos. 11 and 12.

[2] *Centralbl. f. Chir.* 1904.

long anterior (slightly internal) and a convex posterior flap are made (*vide* Fig. 230). If there is much muscle the skin and fascia only are dissected back, and the muscles are cut transversely. If the muscles are atrophied a flap consisting of skin, fascia, and muscle is taken from the quadriceps. The operation is performed according to the rules for aperiosteal amputation (*vide* General Introduction), *i.e.* the periosteum is divided 1 to 2 cm. above the level at which the bone is to be sawn across leaving the stump bare. The sharp edges of the sawn bone are rounded off with bone forceps.

Methods which result in the scar lying on the stump are only permissible when the question of weight-bearing has not to be considered, and then only if the condition of the wound is simplified or improved by it, *i.e.* if the operation can be performed more expeditiously and with smaller wound surfaces. In muscular limbs two short flaps are made, and after retracting them, a clean cut is carried transversely through the muscles (Lisfranc and Esmarch). A very clean wound can also be made by dividing the muscles by transfixion after the skin has been divided. This operation is equivalent to the lanceolate incision as illustrated in Fig. 231. In very muscular limbs the periosteum is separated upwards for several centimetres so that a sufficient covering of skin and soft parts may be obtained.

55. High Amputation of the Thigh. When a high amputation of the thigh is performed, the artificial limb must take its support from the pelvis (tuber ischii) and there is no necessity for trying to obtain a stump capable of bearing weight. The stump must, however, be freely movable, so that the artificial limb can be fully controlled.

The technique of high amputation and disarticulation is therefore very similar. The racket incision, which we mentioned in the introductory chapter as being specially suited for this purpose, should be adopted (*vide* Fig. 230).

With a racket incision the hæmorrhage is easily controlled, a consideration which is here of more importance than lower down in the thigh, where an Esmarch's elastic tourniquet can be readily applied. By placing the longitudinal incision on the outer side of the thigh along the posterior border of the vastus externus, one can cut boldly down to the bone. The periosteum is then raised and the bone divided at the proper level [two-fifths of the diameter of the limb above the level at which the soft parts are divided (Neudörffer)], the lower end of the femur being brought out at the wound.

An elastic tourniquet is now applied, and having previously indicated by a scratch on the skin the level at which the limb is to be amputated, we rapidly make a circular incision with two successive sweeps of the knife. It is often more advisable to incline the incision a little obliquely downwards and forwards. An assistant grasps the soft parts and controls the vessels with his fingers, or Lynn-Thomas's excellent forceps-tourniquet (Fig. 200) may be applied and the soft parts in front and behind securely clamped.

56. Disarticulation at the Hip (Figs. 237, 238, and 239). Considering the mass of muscle which surrounds the hip-joint and the great importance, after removing the entire bony apparatus of the limb, of obtaining a movable muscular stump, high amputation through the thigh with subperiosteal removal of the upper end of the femur should, in the absence of special indications to the contrary, be regarded as the normal procedure. We may refer the reader to what has been said in speaking of amputations in general. Experience has taught us that here, just as in the shoulder, a movable muscular stump is of the greatest service in enabling an artificial limb to be worn.

A very different procedure must be adopted when it is necessary to remove as much as possible of the deeper soft parts, as, for example, in malignant disease. According to the indications, therefore, different methods of amputation must be employed, and these may be classified into two main groups.

The method practised by Beck and Verneuil, and improved upon by Rose (extirpation method), is to be regarded as the type of methods in which the deep soft parts must also be removed. For all cases, on the other hand, where the

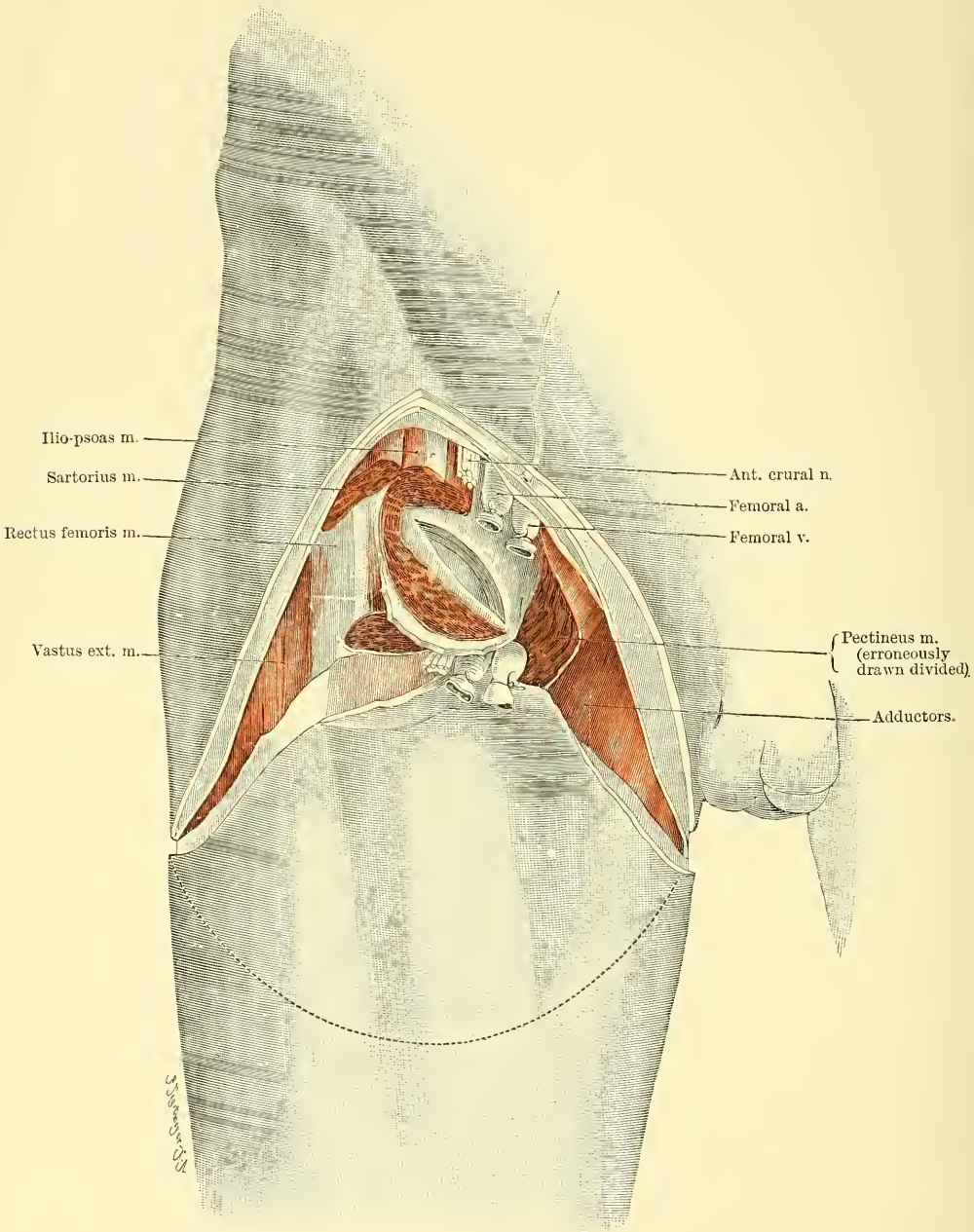

FIG. 237.—Disarticulation at the hip for disease affecting the soft parts in front. Extirpation method by the oval (or lanceolate) incision. The main vessels are first tied; the sartorius and ilio-psoas muscles are divided and the joint is opened anteriorly. The pectineus is erroneously represented as divided, whereas the anterior surface of the muscle should have been represented.

muscles can be retained, Roux's or Kocher's modification of the method of Ravaton (1743, Treves) and Kerr is indicated. An external racket or an external lanceolate incision is made, and a combined excision and amputation performed, as specially practised by us. The principle of this operation was carried out by Furneaux Jordan, who, by means of an external longitudinal incision, divided the insertions of the muscles into the trochanter and upper part of the femur, and amputated the limb as low down as possible by the circular method.

The excision-amputation method (a modification of Jordan's method) practised by us, diminishes the loss of blood, as it permits of the part of the operation which must be done without complete prophylactic control of hæmorrhage being performed with the minimum of injury. Lister has availed himself by this method of the advantage of first of all disarticulating the head of the femur, *which Esmarch leaves to the last.*

The remarkable danger and mortality which formerly attended the operation have been greatly reduced since Esmarch taught us how to effectually control the hæmorrhage. Rose's method is *meant* to be performed without Esmarch's prophylactic measure. Thanks, therefore, to the improvement in the technique, amputation at the hip can now be undertaken without hesitation even in comparatively feeble persons. We have had no experience of Wyeth's method, in which two large steel pins are pushed through the joint to keep the rubber tube from slipping. Wyeth has also employed this method for the shoulder since 1890, and has produced evidence to show that in nearly seventy cases the bleeding was controlled with absolute certainty. It may therefore be used with advantage in certain circumstances.

(*a*) *Extirpation Method* (Fig. 237) (Beck-Rose's operation). Rose, following the example of Beck (Lüning), removed the thigh like a tumour by dividing the larger vessels between two ligatures, and ligaturing the others immediately after dividing them. This *extirpation method* is the more suitable when the tumour extends high up in the region of the hip-joint. In such cases the soft parts can only be partially retained. For this reason no special description can be given of the operation to be performed, as this must necessarily vary in different cases. It is always desirable, however, to place the incision so that the main vessels (as in removing the upper extremity along with the shoulder girdle) can be ligatured at the outset, *i.e.* the angle of the incision is to be placed over the femoral vessels (Fig. 237). In this way all bleeding is prevented, with the exception of that from the obturator, gluteal, sciatic, and possibly the internal pudic arteries. If, however, forceps be at once applied to the bleeding vessels after dividing them, further hæmorrhage is reduced to a minimum.

The figure shows that the method described by us, from our experience of cases of sarcoma extending high up, depends on these principles, and can be considered as the *anterior* racket, in distinction to the *external* racket. According to Farabœuf and Treves, Larrey introduced this incision, which was practised in a modified form by Cooper, Verneuil, and Roser. Guthrie's and Lisfranc's methods are also very similar as regards the position of the incision, which was, however, partly made by transfixion. Of the earlier transfixion methods, which were regularly practised and taught, and were based on rapidity of execution with disregard of proper means of checking hæmorrhage, no more notice need be taken as they involve too severe bleeding.

(*b*) *Excision-Amputation Method* (Fig. 239). In all cases where the soft parts in the region of the hip can be retained, the bone should be shelled out from the soft parts quite bare, as the muscles of the stump are of great functional use for the attachment of an artificial limb. Especially if the operation be done subperiosteally, an actively movable stump is obtained just as in a high amputation through the femur. Like Shuter and others, we have seen such a solid and perfectly movable stump formed from the periosteum that it was scarcely possible to believe that disarticulation at the hip had really been performed. The method usually employed is that by the external racket incision.

Hæmorrhage is arrested by an elastic tourniquet, which, to prevent it slipping downwards, must always be applied in the form of a figure-of-eight round the thigh and pelvis. The complicated precautions of Trendelenburg, Senn, and Wyeth may

have advantages in individual cases, but as a rule they are unnecessary. Trendelenburg transfixes the limb with steel rods passed towards the inner side from the excision wound, and then winds a rubber tube round them in the form of figures-of-eight. Senn passes a double rubber tube through the limb from the wound for resecting the hip-joint, and ties the soft parts in two halves. Wyeth prevents the rubber tourniquet from slipping by transfixing the limb through its root with two large steel pins. Braun ligatures the external iliac vessels, and from this wound an assistant compresses the internal iliac, a plan which, he asserts, is attended with least hæmorrhage.

A circular incision is made through the skin at the level estimated in the usual way, the muscles are divided down to the bone at the level of the edge of the retracted skin, and, after dividing the periosteum, the bone is sawn across. The vessels are now carefully ligatured and the tourniquet removed.

Instead of the simple circular incision it is better to make an oval incision extending upwards on the outer side of the bone (Fig. 236): if necessary we may adopt Liston's plan of making short anterior

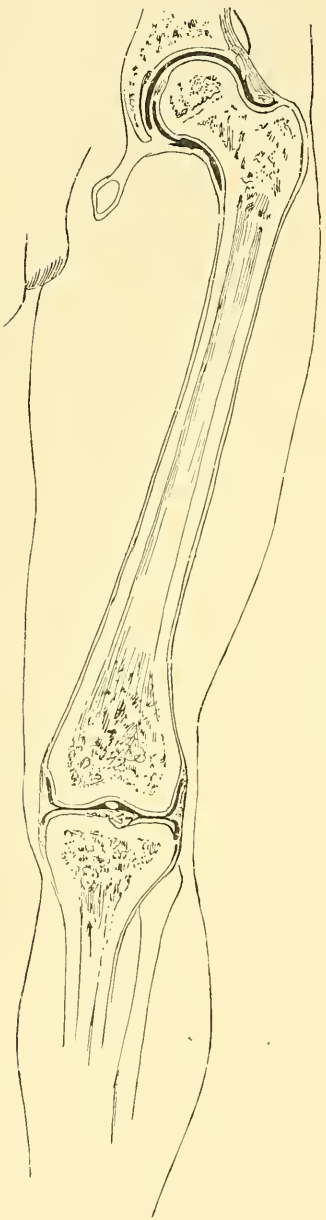

Fig. 238.—Coronal section of the hip- and knee-joints (after Henle).

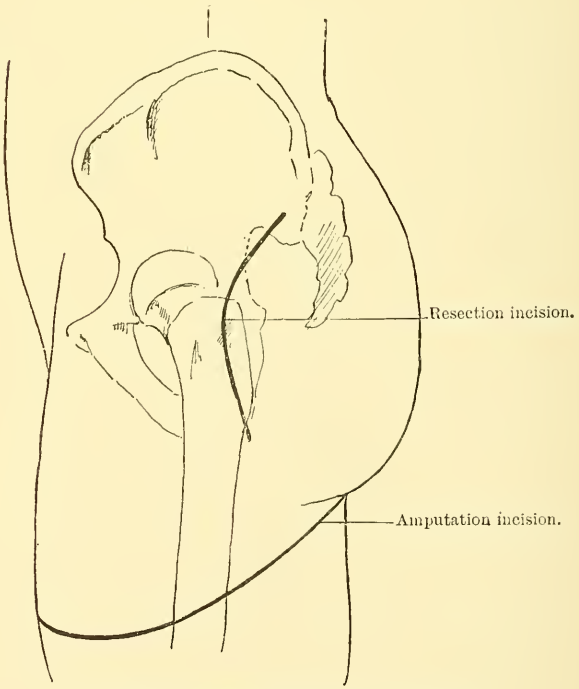

Fig. 239.—Disarticulation at the hip-joint.

and posterior skin flaps and dividing the muscles circularly.

Beck and Esmarch, after the circular amputation, divide the soft parts at the outer surface of the femur, and dissect out the bone subperiosteally by detaching

with a knife the attachment of the periosteum at the linea aspera, the insertions of the muscles (glutei, pyriformis, obturator externus, obturator internus and gemelli, and the quadratus femoris) into and below the great trochanter, the ilio-psoas into the lesser trochanter, and the attachments of the capsule in the region of the anterior and posterior intertrochanteric lines. The ligamentum teres is torn across by twisting round the femur.

Since 1876 we have had faultless results—nine cases, with no deaths (reported by Roux). Our method of operating (Fig. 239) is as follows:—The incision is the same as that described for excision of the hip, namely, in a curved direction over the great trochanter and through the fibres of the gluteus maximus, but is shorter than the ordinary one for excision. The fibres of the gluteus maximus are separated in the line of the incision and drawn apart. Branches of the gluteal and circumflex arteries are ligatured, the capsule of the joint is divided, and the insertions of the muscles (the glutei anteriorly, and the pyriformis, obturators, and quadratus posteriorly) are separated from their attachments close to the trochanter. The head of the femur is now dislocated, the ligamentum teres being divided or torn through. The soft parts are separated forwards and backwards from the great trochanter as far down as the lesser trochanter, where the strong insertion of the ilio-psoas is divided with a knife.

After completely arresting the bleeding, the limb is held up vertically, and an Esmarch's tourniquet applied in the form of a figure-of-eight around the highest part of the thigh and pelvis. The crossing of the figure-of-eight must be upon the posterior and outer aspect—that is to say, behind and above the great trochanter, so that sufficient pressure is exerted anteriorly.

The limb is now amputated below the trochanters. The skin incision is circular. The skin is then retracted, and the muscles are cut with a clean sweep down to the bone. The soft coverings must always be abundantly calculated for. The bone is then sawn across, and all visible vessels—first the femoral, then the profunda vessels, the internal saphenous vein, and the numerous small arteries—must be carefully ligatured, and the tourniquet removed.

The stump of the upper part of the femur is now surrounded with aseptic gauze and grasped while the remaining connections are freed from it subperiosteally, using the chisel for the linea aspera and insertions of the tendons, after which it is drawn out of the wound. Drains are introduced through special openings close to the resection and amputation wounds, both of which are closed by layers of sutures. In this way primary healing can be obtained in six to ten days.

Roux, in the paper already referred to, has drawn some comparisons between our operation and the methods employed by Volkmann, Guyon, and Reverdin.

57. Amputation of the Pelvis and Interilio-Abdominal Disarticulation. Our two cases of resection of the innominate bone, and those of Roux, show that this extensive operation can be performed with the best results. It is surprising, therefore, that the first cases of amputation of the hip along with the innominate, recorded by Gayet, should all have died.

Billroth first undertook the operation in 1889. Jaboulay performed it in 1894, and again in 1895, while the operation has also been done by Cacciopoli. These were cases of osteosarcoma of the pelvis, and in all death rapidly followed from shock, or sepsis. Girard of Bern was more fortunate, having performed the operation successfully in 1895, and again in 1897, in which cases, however, the osteosarcoma grew from the upper end of the femur, so that the operation was much easier than in cases where the tumour springs from the pelvis. Lastly, two cases were operated on for hip-joint disease with extensive involvement of the pelvis, one by Gerard in 1897 (which died from shock), and one by Bardenheuer which recovered. The ninth case was operated on successfully (Jaboulay's method) by Salistscheff in 1898 : the case was a difficult one and necessitated ligature of the common iliac artery and separation of the symphysis. Finally, we performed the operation with a fatal result on a boy with an extensive pulsating sarcoma of the pelvis. The case will be published. Kadjan also operated unsuccessfully.

The latest collection of cases has been made by Keen and Da Costa,[1] who reported an unsuccessful case in 1903. According to their figures only 5 out of 19 cases have recovered. But this apparently large mortality, 73·7 per cent, is increased if the indications for operation in the successful cases are examined. Bardenheuer's case was one of tuberculosis, and it may fairly be asked whether such a formidable operation is really indicated in tuberculosis of the pelvis. Girard's unsuccessful case was also one of tuberculosis of the hip-joint. Even if the hip-joint is involved one can combine a resection of the pelvis with excision of the hip as Roux and the author have proved (*vide* Resection of half the Pelvis). The reader is also referred to Sprengel's method of resection for extensive disease of the pelvis.

Freeman's case is not an interilio-abdominal disarticulation, but an amputation of the pelvis. The fact that the operation was considered possible shows that the conditions were more favourable than in those cases in which disarticulation is indicated.

In both of Girard's two successful cases, the sarcoma was situated in the thigh and not in the pelvis, cases in which one may keep close to the bone—(partly subperiosteal) in dissecting the pelvis, thus making the operation incomparably more simple and bloodless. One of his cases died of mestastasis after six months, while the disease recurred in the second case after about the same period. The operation amounted rather to a resection of half the pelvis, as disarticulation at the hip had been performed on a previous occasion.

Salitscheff's case was one of sarcoma of the pelvis, which from the description had extended chiefly downwards round the femur. The further career of this patient is not reported. The tumour was partly cystic, and was limited by a thick capsule.

Since the previous edition was published we have operated on yet another case of sarcoma of the pelvis, the patient succumbing from collapse. The prospects offered by the operation are very gloomy, as Morestin observed in the description of his case, even when the operation is clearly indicated, and where nothing but interilio-abdominal disarticulation remains to be performed. We regard it, therefore, as the duty of the surgeon in every case to determine whether resection of one half of the pelvis, or, what is more advisable, partial resection of the pelvis with or without excision of the hip, will not answer the purpose, and also whether or not amputation of the pelvis (Freeman) with retention of the posterior part of the ilium is possible, for in the latter case the operation is less severe; finally, in the case of a rapidly-growing, soft, vascular sarcoma of the pelvis, whether it would be better to try the effect of treatment by the Röntgen ray's and Coley's fluid, as, if the size of the tumour undergoes any reduction, there is more prospect of the operation proving successful.

Keen has reviewed the various incisions that have been adopted, and there appears to be no doubt that the same incision cannot invariably be employed. But the direction of the incision is not after all a matter of prime importance. The control of the hæmorrhage is of greater moment, for hitherto in all the unsuccessful cases death has been due to hæmorrhage generally in the first few hours. Nanu's and Keen's cases died on the second and twentieth days respectively from gangrene.

Secondly, in determining the incision one must always have in mind whether a resection or at least amputation of the pelvis may be sufficient. Freeman's and Keen's cases are typical instances of this point, and we here reproduce the two figures from Keen's article showing the line of division of the bone.

By preserving the posterior part of the ilium as shown in Figs. 240 and 241, the difficulty connected with separation of the sacro-iliac joint (a process which generally occupies time) is surmounted. Retention of the descending ramus of the pubis and part of the ascending ramus of the ischium dispenses with the separation of the root of the penis, an operation accompanied by much bleeding (Keen).

A still greater advantage of leaving these portions of bone, is that there is no necessity for the attachment of the muscles to the pelvis being divided, for no matter how rapidly this is effected, division of the muscles is always accompanied by excessive bleeding. As in Rose's method of disarticulation at the hip, large portions of muscle should be seized with crushing forceps, applied at some distance from their

[1] *Clinique internationale*, vol. iv.

attachments and divided between clamps. Lynn Thomas's forceps are excellently adapted for this purpose, as the tissues can be transfixed by the small blade.

On the basis of experiments and of our unfortunate experiences with two patients, we should proceed as follows in a case of sarcoma of the pelvis, in which condition alone an interilio-abdominal disarticulation is indicated. The median basilic vein is exposed and everything is prepared for intravenous injection. The patient is placed on a well-warmed operation table, and an enema of tea and brandy is administered.

An incision is made parallel to Poupart's ligament exactly similar to that used in ligature of the common iliac artery (1 in Fig. 242). (This might be effected under local anæsthesia.) The fascia is divided in the form of an angular flap, the muscles are separated in the direction of their fibres, the fascia is transversalis raised along with the peritoneum, and the internal iliac fossa and the common iliac artery

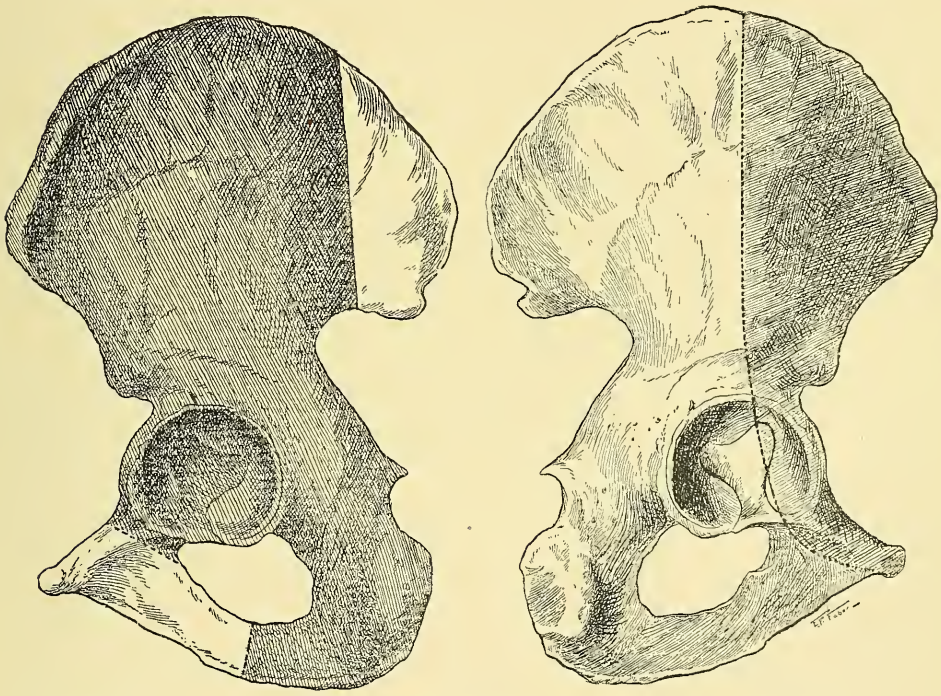

FIGS. 240 and 241.—Lines of section of pelvis in Keen and Freeman's cases of amputation of pelvis.

are exposed. The artery is temporarily controlled with a suitable compressor or clamp (Halsted), and after the vein has been emptied by elevating the limb, it is also clamped. We regard temporary closure of the vessels as a necessary precaution against collapse from acute anæmia. The inner surface of the pelvis is now carefully investigated, the limits of the tumour are defined, and the proposed lines of section of the pelvis determined.

The dorsal aspect of the innominate bone is then similarly examined. This is most satisfactorily effected through an incision in the same direction as that for ligature of the gluteal artery (2 in Fig. 242), only considerably longer and more like that we recommend for posterior excision of the hip at the upper border of the gluteus maximus. The great sacro-sciatic notch is thus exposed, and the line at which the bone is to be divided is defined.

After its fibres have been split the gluteus maximus can be drawn downwards with a hook without any appreciable bleeding and the bone is exposed at the upper

border of the great sacro-sciatic notch, where it is to be divided or, alternatively, the lower end of the sacro-iliac synchondrosis is exposed.

The tendon of the pyriformis is next cut across and the trunks of the great and small sciatic nerves are exposed and divided in the lower part of the great sacro-sciatic notch. The shock incurred by division of the great sciatic nerve may be avoided by an injection of novocain. With a hammer and chisel the base of the ischial spine is then cut through to the outer side of the internal pudic artery and nerve, and the inner aspect of the gemelli and the obturator internus followed down-

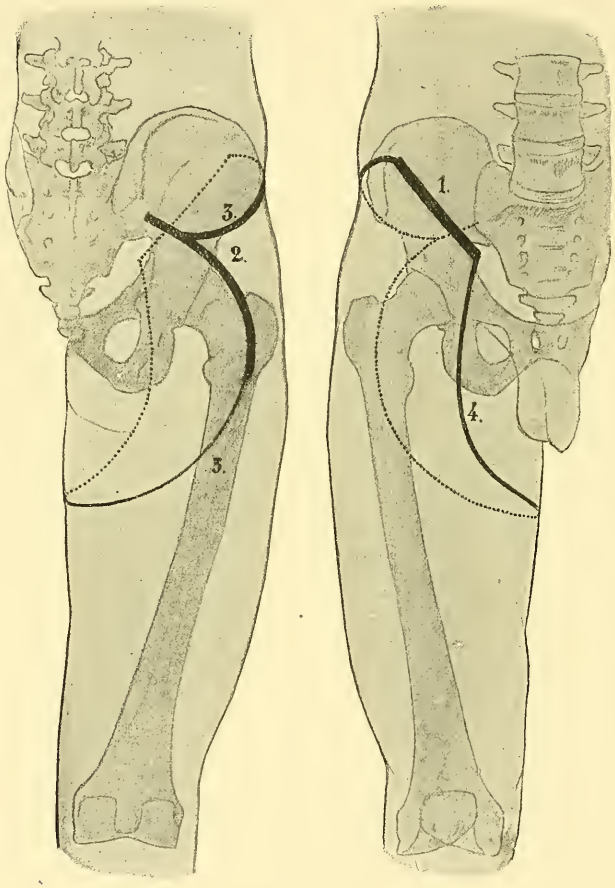

b. From behind. *a*. From in front.

FIG. 242.—Interilio-abdominal disarticulation. The graduated thickness of the black lines and the numbers indicate the course of the incisions.

wards to the sacro-sciatic ligament, the descending ramus of the ischium being then chiselled through into the foramen ovale above the attachment of the ligament to the ischium and tuberosity; in this way the tuber ischii is only held by the ligament and the muscles of the perineum.

The anterior and posterior incisions are now joined, as shown in Fig. 242 (No. 3), crushing forceps are pushed underneath the gluteus medius and minimus in the proposed line of section of the ilium, and the muscles are then divided between two

clamps, the application of the clamp being preferable to division of the muscles at their attachment to the bone.

A finger is now inserted into the anterior incision (Fig. 242, No. 1), two pairs of clamp forceps being introduced along it and the abdominal muscles are clamped just above the crest of the ilium. They are then divided between the forceps as far as the line of section of the crest posteriorly.

The ilio-psoas is next dealt with. The external iliac vessels, together with the ilio-inguinal and genito-crural nerves, are raised and retracted; but the nerves which descend at the side of the psoas and iliacus, namely, the anterior crural and the external cutaneous, are divided. The ilio-psoas is cut across between two forceps, and the bone is divided with a chisel, bone-forceps, or Gigli's saw, from the sacro-sciatic notch upwards along the selected line.

The anterior portion of the flap incision (No. 4, Fig. 242) is now carried vertically downwards on the anterior surface of the adductors, thus exposing the horizontal and descending ramus of the pubis, with the femoral vessels lying externally. The latter are ligatured above the origin of the profunda so that the internal circumflex vessels may be retained in the flap. The pubis is next divided with a chisel or bone-forceps as shown in Fig. 240 or Fig. 241 (Keen), separating the attachment of the internal and external obturator muscles from the foramen ovale. The obturator externus is then cut across. The innominate bone can now be drawn downwards and outwards, being only held by the levator ani. The pelvic fascia and periosteum are divided at the entrance to the true pelvis as far as the horizontal ramus of the pubis, preserving the obturator vessels and nerve, and the strip of fascia by which the levator ani and coccygeus are attached.

Finally, the skin incisions 4 and 5, Fig. 242, are completed, the adductors and the hamstrings are divided at their origin from the tuber ischii, and the vessels are tied seriatim.

The forceps, which still grasp the muscles, are now removed one at a time and the vessels are tied. After transfusion, the temporary clamp on the common iliac artery is removed and any branches of the obturator, circumflex, gluteal, and sciatic arteries which may still be bleeding are immediately secured. Our incision corresponds in the main with that of Savariand and Keen.

(k) Amputations of the Hand and Fingers

58. Amputation and Disarticulation of the Fingers (Figs. 243 and 244). The chief rule in the case of the fingers is to endeavour to retain a stump, no matter how short, provided the tendons remain connected with it, and that it can be covered with sound skin. A flap from the palmar aspect is preferable, as it avoids a palmar cicatrix, which is exposed to pressure. The oblique circular incision is most to be recommended, and is better than Farabœuf's lateral-palmar incision for the index and little finger. For a disarticulation the line of the joints is easily made out, because with the finger flexed they are always placed on the distal side of the dorsal bony prominences (Fig. 243). In disarticulations at the interphalangeal joints the knife is applied over the joint line, and directed obliquely downwards towards the palmar aspect. The attachment of the extensors at the base of the phalanx, then the dorsal part of the capsule, the lateral ligaments, the anterior part of the capsule, and lastly the flexor tendons, are divided, the latter being divided at the base of the phalanx, while the finger is held in the semi-flexed position. The ends of the extensor and flexor tendons are then carefully sutured to the remains of the capsule.

In amputations the palmar flap must be turned back in order that the rest of the incision may be carried round the bone. In dividing the tissues down to the bone the finger must be held midway between flexion and extension, so that both tendons are put slightly on the stretch and retain their function. The ends of the tendons are stitched to the corresponding tendon sheaths or to each other.

In disarticulating a finger at the metacarpo-phalangeal or at the carpo-metacarpal

joint the racket or *lanceolate incision* is used, the longitudinal portion of which is carried upwards over the back of the joint (Fig. 244). The tendons are divided in the middle position of the hand (so that the movements of the latter may not be interfered with) and are sutured to the remains of the capsule. The periosteum is divided and separated along with the capsule.

In metacarpo-phalangeal disarticulation of the thumb, the index finger, and the little finger, the dorsal part of the incision is placed towards the middle line of the hand instead of over the middle of the bone or joint.

In disarticulating a finger, with or without its metacarpal bone, the transverse incision follows exactly the line of the web of the fingers (Fig. 246): incisions must not be made higher up in the palm.

In disarticulation of the thumb at the metacarpo-phalangeal joint, it is important that the long tendons should be properly stitched, because the metacarpal of the thumb is movable, and the long extensors (with the abductor pollicis) are the only muscles which oppose the action of the short flexors in the thenar eminence.

Disarticulation of the Thumb (or Little Finger) along with its Metacarpal. In disarticulation of the first and fifth digits at the carpo-metacarpal joint, the strong muscles which form the thenar (and hypothenar) eminence must be preserved intact. As was pointed out

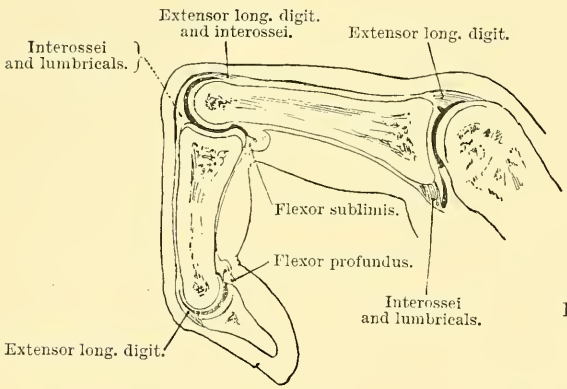

FIG. 243.—To show the line of the joints in the flexed position of the finger.

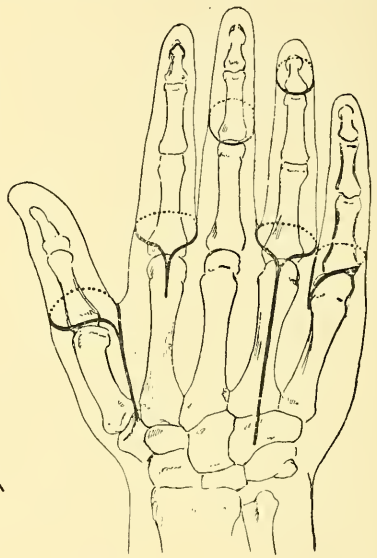

FIG. 244.
Disarticulation of little finger.
,, index finger.
,, ring finger along with its metacarpal bone.
,, thumb along with its metacarpal bone.
(Dorsal aspect of hand.)

in the general consideration of amputations, a racket or lanceolate incision with a long handle (*vide* Fig. 244) is to be preferred. Further, the handle of the racket should not be made quite on the dorsum, but should be placed more internal, towards the margin of the interosseus space. It is carried right down to the periosteum and bone and the latter is shelled out subperiosteally, and disarticulated at the proximal end by means of a transverse or oblique incision round the finger.

The long tendons should not be divided in the longitudinal portion of the incision, but should be cut across in the transverse part, the metacarpal bone occupying a position midway between extension and flexion. They should be stitched to the remains of the capsule which has been left attached to the periosteum. The long extensor tendons in particular (viz. extensor longus, extensor brevis, and abductor pollicis) must be carefully stitched, as in action they are antagonistic to the short powerful flexors as well as to the abductor. In conclusion, it must not be forgotten that the metacarpal may reform after a subperiosteal removal.

59. Disarticulation at the Wrist-Joint (Fig. 245). Very different methods are admissible for this operation, as for amputation through the forearm, the object being to obtain as long a stump as possible. In contrast to the main rule for the foot, an amputation must not be performed transversely through the wrist as long as a movable finger or portion of the hand can be retained.

An oblique circular incision is made, the upper end of which is placed at the level of the wrist-joint behind, while its lower end extends down on to the palm, the width of the flap corresponding to the diameter of the wrist. With the hand fully flexed towards the palm the extensor tendons and the posterior ligament are divided, whilst, below the projecting styloid processes, the lateral ligaments and tendons (extensor carpi ulnaris and the three extensors of the thumb) are cut across and the joint is opened. The bundle of flexor tendons is separated from the carpus and divided along with the skin at the extremity of the palmar flap. The palmar flap has the advantage of being very well nourished, of possessing fine tactile sensibility, and, in certain circumstances, of forming a movable muscular stump, while it further avoids leaving a scar on the palm, which would be exposed to undue pressure. The latter advantage is shared by Dubreuil's method, recommended by Treves, in which a flap is taken

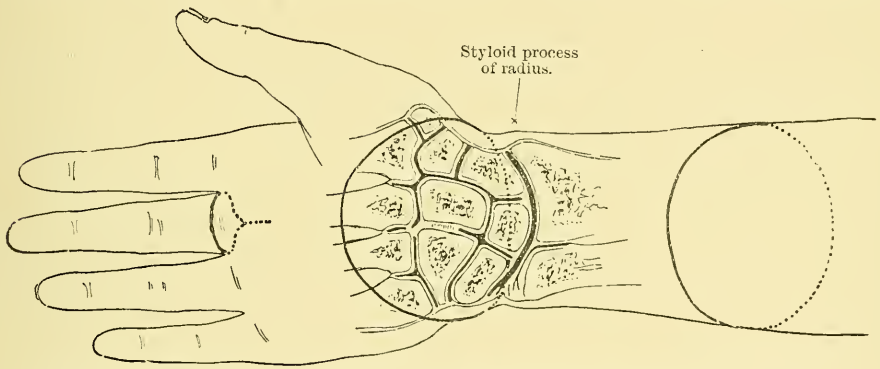

FIG. 245.—Disarticulation of middle finger. Disarticulation of the hand at the wrist-joint. Amputation through the forearm.

from the radial side and the muscles of the thumb are preserved. But care must be taken not to have the cicatrix over the end of the radius, where it is exposed to the greatest pressure. As the stump is not directly exposed to any pressure, an oblique incision (dorsal flap) or a circular incision extending half the diameter of the limb below the joint, may also be adopted. The flexor and extensor tendons should be sutured over the end of the stump to ensure that their function will not be impaired.

(l) Amputation of the Arm

60. Amputation of the Forearm (Figs. 245 and 246). As there is no necessity to provide a stump capable of bearing pressure, either a circular or oblique incision may be made, the flap in the latter case being taken from either aspect of the arm. Treves rightly states that in the muscular part of the forearm flap operations are preferable to either of the above methods on account of the difficulty of reflecting the skin and fascia.

Further, in the upper half of the forearm, where there is a considerable thickness of muscle, the racket incision should be adopted, the bones being shelled out subperiosteally, and the divided muscles carefully sutured over the end of the stump.

61. Disarticulation at the Elbow (Figs. 247, 248, 249). As in amputation in the region of the knee-joint, so also at the elbow, disarticulation at the joint itself is

to be preferred to amputation through the forearm high up, provided the joint itself is healthy and the muscle insertions at the ends of the bones of the forearm can be retained.

If, while the joint is healthy, the bones of the forearm must be removed, it is here also a great advantage if a muscular stump can be obtained with its nerve-supply uninjured. The simple racket incision described under the general principles of amputations, in which the soft parts of the forearm are divided circularly down to the bones, and the latter shelled out subperiosteally as far as the joints, is the most simple procedure and gives the best functional results (Fig. 247).

The most satisfactory incision for shelling out the bones of the forearm is the external J-incision we employ for resection of the elbow, as it entails least harm, the operation being subcapsulo-subperiosteal.

If the muscles cannot be preserved the oblique incision will be found to give a good stump. Further, the circular incision assumes the form of the oblique incision if the amputation is performed with the forearm held in the fully-extended position (Miller).

In the operative course the error is repeatedly made of regarding the tip of the olecranon as the guide to the line of the elbow-joint. The head of the radius is the proper guide. It can always be felt at the posterior aspect of the elbow.

An oblique incision is made on the dorsal aspect, beginning at the line of the joint, and extending a hand's-breadth below the tip of the olecranon. With

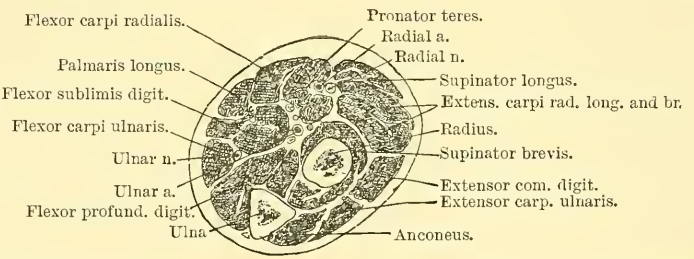

FIG. 246.—Transverse section through the upper third of the forearm (from a photograph).

the elbow bent to an angle of 135° the incision is parallel to the prolonged axis of the upper arm. The posterior flap, together with the periosteum, the anconeus, and the insertion of the triceps, is dissected up beyond the tip of the olecranon as far as the posterior surface of the humerus. In front, the soft parts and capsule of the joint are divided transversely. The flap being held aside, the radio-humeral joint is opened from without inwards.

Farabœuf, on the contrary, makes the oblique incision in the reverse way, commencing at the tip of the olecranon and extending downwards across the front of the forearm as far as a hand's-breadth below the elbow-joint.

62. Amputation through the Upper Arm (Fig. 250). In order that a broad covering may be obtained for the stump, it must be borne in mind that the upper arm is markedly flattened from side to side. Flaps are to be taken from the broad aspect. Accordingly, when oblique incisions are made, the upper end should fall over the internal bicipital sulcus. The biceps retracts to a great extent. A simple circular incision answers admirably if the soft parts are sufficiently pushed back subperiosteally.

The surgical neck of the humerus limits the height up to which a useful stump can be got in amputating through the upper arm, because the capsule extends down to this level internally. The other factors determining the future usefulness of the stump are the insertions of the deltoid, pectoralis major, and latissimus dorsi muscles, these being the chief adductors and abductors of the stump.

In amputating near the shoulder it is very essential that the function of the muscles should be retained, the best incisions to use here being either the racket or lanceolate

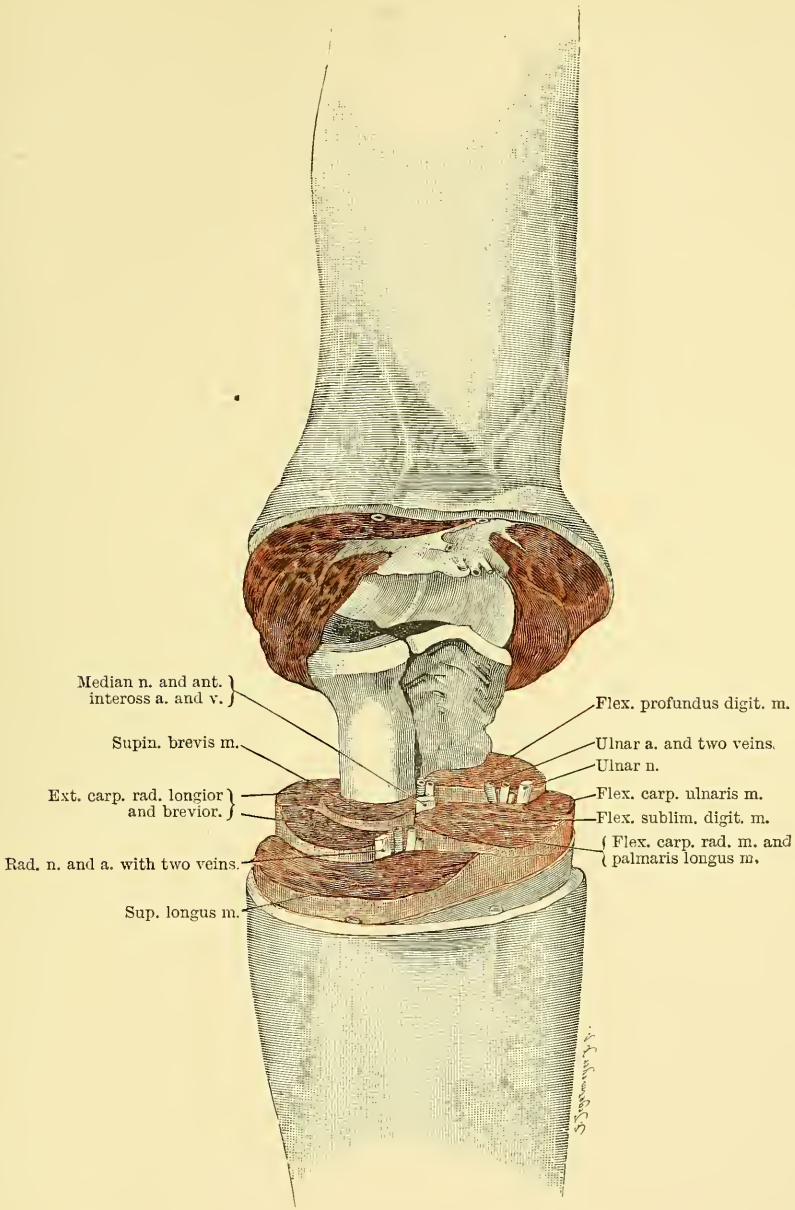

FIG. 247.—Disarticulation at the elbow-joint by a circular incision. The incision has been made down to the bone, and a "muscle-stump" provided by subperiosteal removal of the bones of the forearm. The soft parts are retracted upwards, and the joint is opened from in front.

variety. The longitudinal portion of the incision is made in the interval between the muscular groups supplied by different nerves, *i.e.* it should be made down to the bone at the anterior border of the deltoid between the internal and external rotators of the

humerus. The transverse portion encircles the limb about three-fifths of its diameter below the level at which the bone is divided, after the periosteum has been detached and the bone sawn across.

63. Disarticulation at the Shoulder (Figs. 251, 252). What has been said regarding disarticulation at the hip-joint applies to amputation at the shoulder with even greater force. If the soft parts, especially the muscles, can be preserved, a musculo-periosteal stump should always be ensured by shelling out the bone. This can be done either by combining excision with high amputation, or by the racket or lanceolate incisions. Just as in the thigh, the important point is, that the longitudinal portion of the incision should be placed in the interval between two muscular groups, supplied by different nerves. For this reason we give preference to the adoption of the anterior racket and the anterior lanceolate incisions.

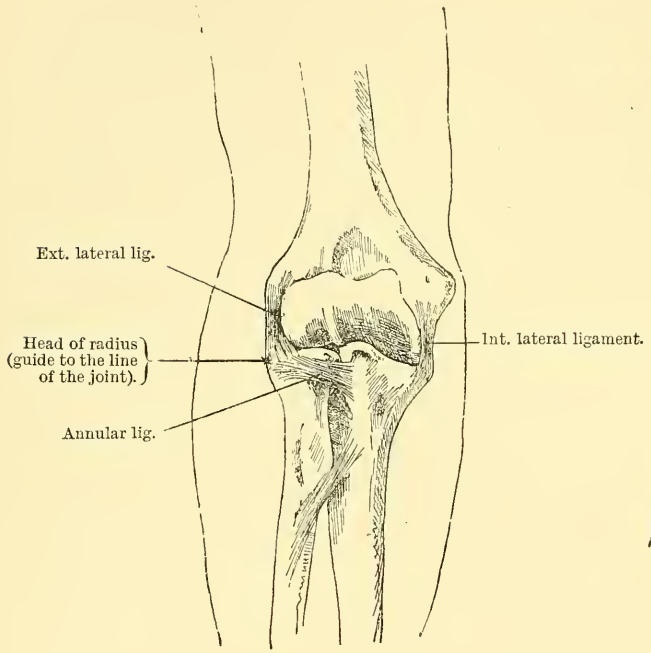

FIG. 248.—Ligaments of the elbow-joint.

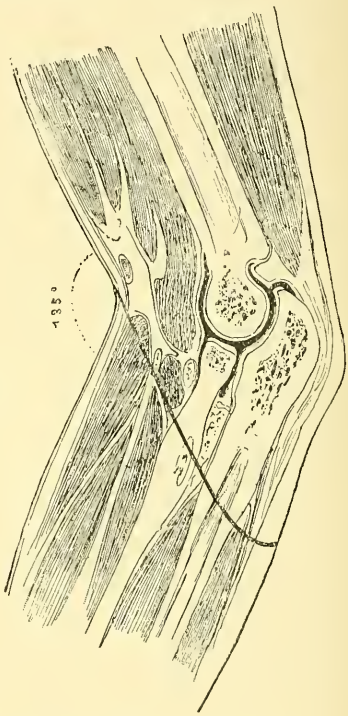

FIG. 249.—Disarticulation at the elbow-joint. (Longitudinal section through the elbow-joint, after Braune.)

When there is considerable laceration of the soft parts, *e.g.* after an injury, or if they are invaded by a new growth, the incision must of course be varied to suit the individual case. If the muscles have to be removed, a lanceolate incision (Fig. 252) is to be preferred as it affords the best covering for the stump. It is a matter of no difficulty to ligature the main vessels through the longitudinal part of the incision. The principle of the method is, therefore, the same as that employed by Rose for the hip, the main vessels being ligatured through the first incision, the remaining bleeding points being at once secured as the tissues are divided.

Just as at the hip, the typical disarticulation at the shoulder (racket incision) is carried out by performing a circular amputation at the level of the fold of the axilla, and then shelling out the humerus by an anterior longitudinal incision similar to that employed for excision of the joint.

Especially in the ordinary cases requiring disarticulation, viz. crushes of the arm,

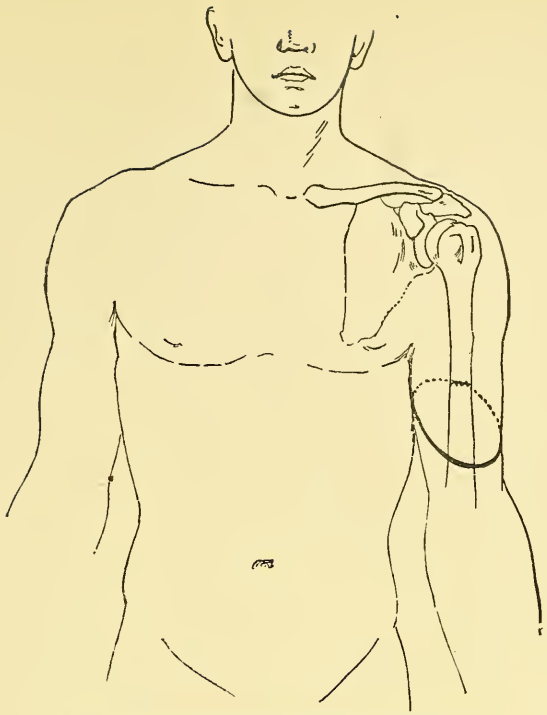

FIG. 250.—Amputation through the upper arm.

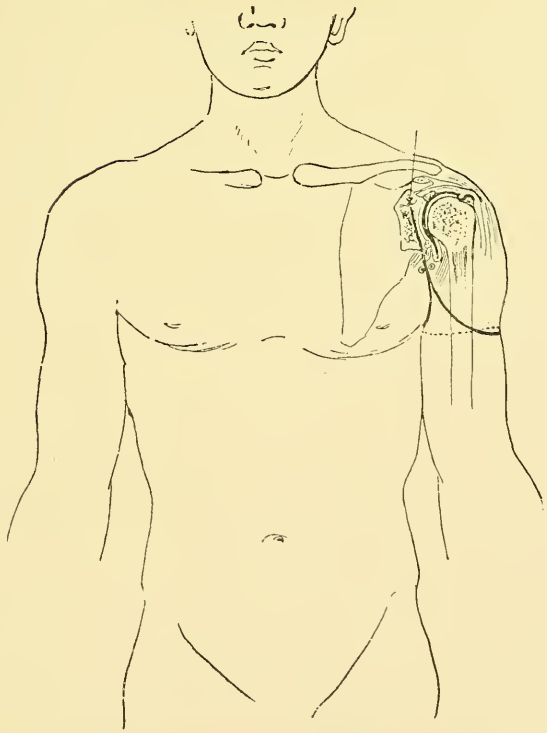

FIG. 251.—Disarticulation at the shoulder-joint.

the method we will now describe would naturally suggest itself. As severe shock and anæmia are often present, serious hæmorrhage must be avoided.

An incision beginning over the clavicle is carried vertically downwards external to the coracoid process. The upper part of the anterior fibres of the deltoid are divided, and forceps are at once applied to the bleeding points. The cephalic vein, which ascends in the interval between the deltoid and pectoralis major, is ligatured, as also are the acromial branches of the acromio-thoracic axis artery. The bone is reached

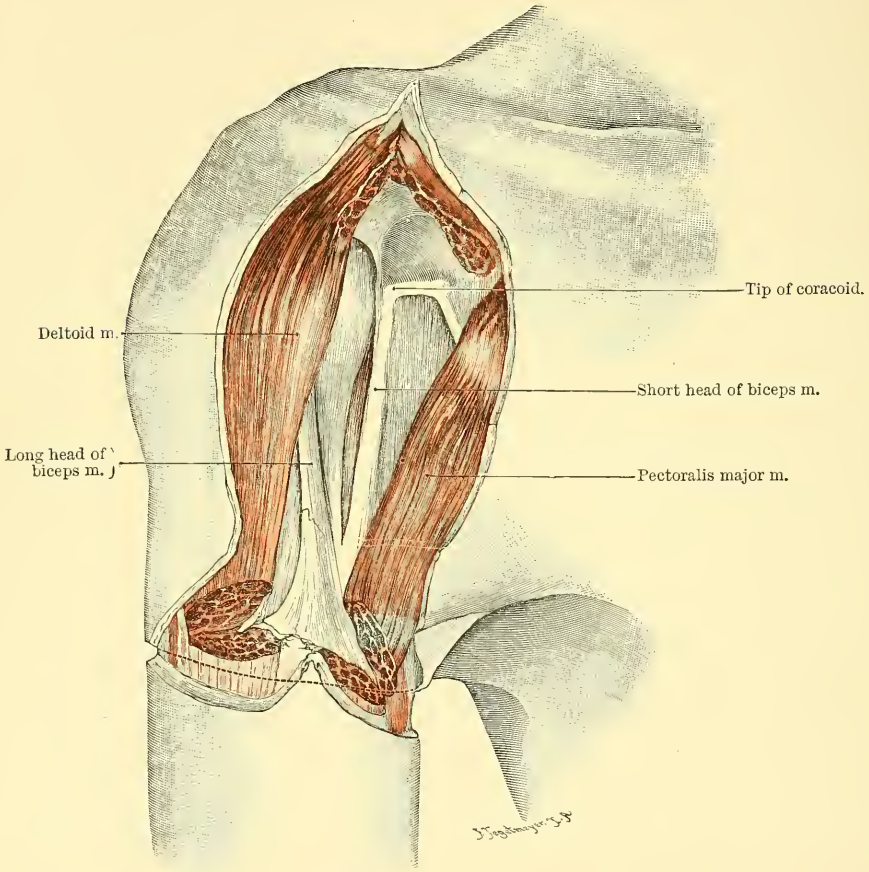

FIG. 252.—Disarticulation at the shoulder by the racket incision. The incision is made along the anterior edge of the deltoid, commencing above the coracoid process, which is exposed along with the origins of the short head of the biceps and the coraco-brachialis. The anterior border of the deltoid has been divided where it covers the coracoid, and the pectoralis major and deltoid are separated and divided lower down. The long head of the biceps is exposed, along which the incision is carried down to the bone.

by passing between the anterior border of the deltoid and the pectoralis major, and the capsule is slit upwards along the bicipital groove. The insertion of the subscapularis is detached from the lesser tuberosity, and lower down the insertions of the pectoralis major, latissimus dorsi, and teres major are separated subperiosteally from the region of the bicipital groove, the anterior circumflex artery being ligatured. The insertions of the supraspinatus, infraspinatus, and teres minor are then separated from the greater tuberosity, so that the head of the humerus may be protruded upwards and forwards out of the wound.

The racket incision is now completed by dividing the skin circularly at the level of the axillary folds. The vessels and nerves are then easily isolated, the former being ligatured and the latter divided. The subscapular artery and nerves can be grasped and dealt with. The circumflex nerve, which courses over the teres major and behind the bone to supply the deltoid, is to be carefully avoided, as the deltoid is the chief muscle of the future stump.

The method above described resembles very closely the racket method of Spence.[1] Larrey's racket method, recommended by Farabœuf, in which the longitudinal incision is placed externally, is not to be preferred, as it does not avoid the circumflex nerve, and therefore causes paralysis of the deltoid.

64. Interscapulo-Thoracic Amputation (Figs. 253, 254). In this operation,

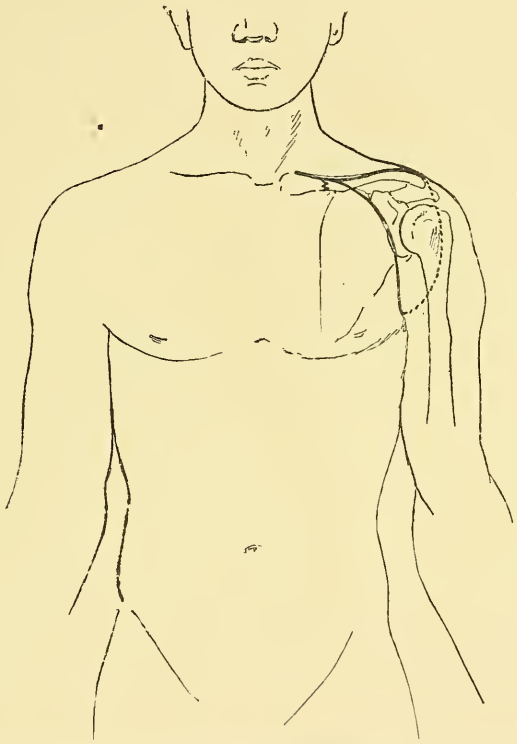

FIG. 253.—Removal of the upper extremity together with the shoulder girdle.

which is not a disarticulation, as no joint has to be opened in removing the shoulder girdle, the clavicle is sawn through, and only the muscular attachments to the scapula are divided. Hence the name we have selected.

Berger's operation is most commonly performed for injuries and tumours of the head of the humerus and the scapula (but exceptionally also for gangrene and spreading cellulitis), which have implicated the shoulder-joint and the scapula, frequently together with the axillary glands, the vessels, and muscles. Cases are also met with in which it is necessary to remove along with the arm merely a portion of the scapula (acromion and glenoid). If carried out in an exact manner, the operation is no more dangerous than disarticulation at the shoulder, and gives far better permanent results, in contrast to the conditions associated with interilio-abdominal disarticulation. The operation is

[1] Spence's *Lectures on Surgery*, vol. ii.

dependent for success on the mobility of the shoulder girdle, more especially of the scapula.

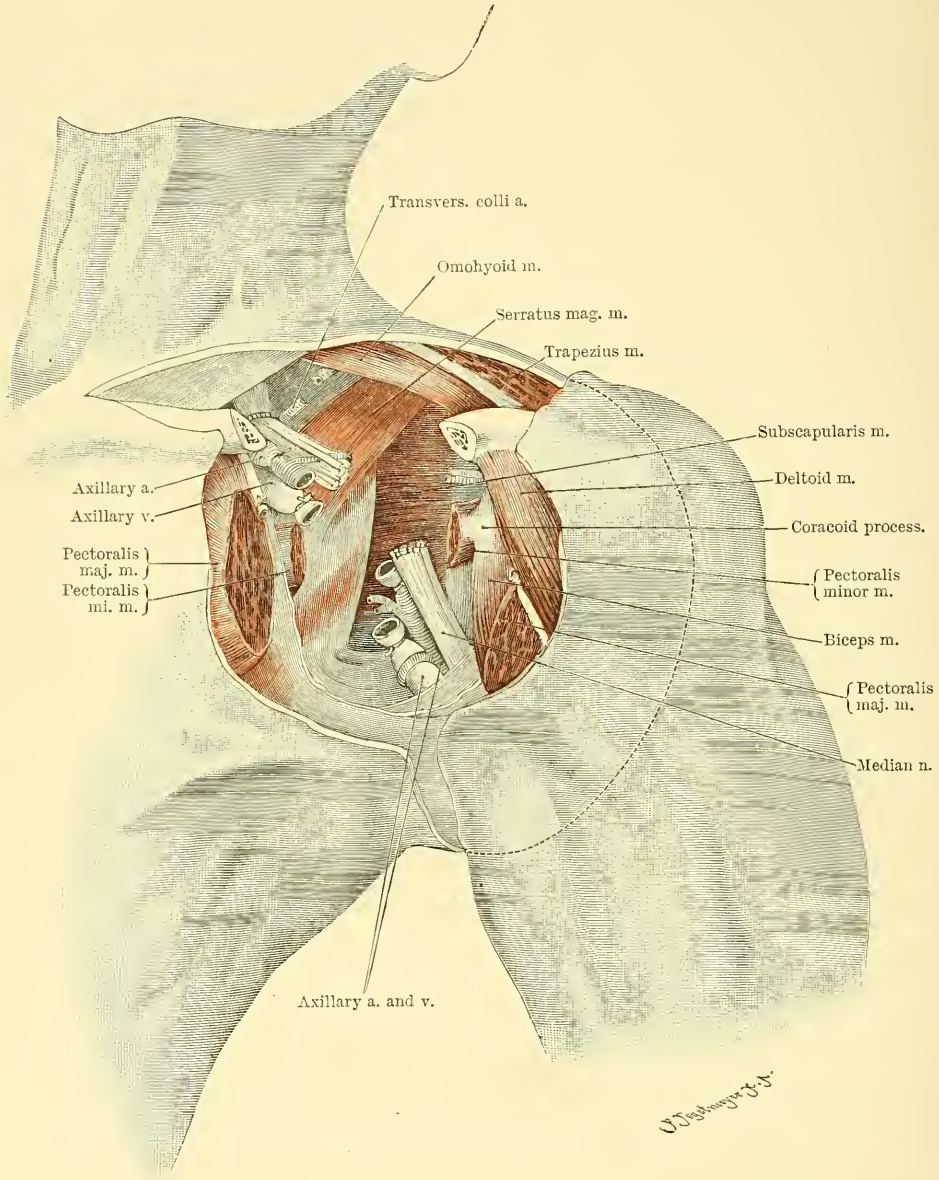

FIG. 254.—Disarticulation of arm and shoulder girdle, anterior incision, followed by division of clavicle pectorals, main vessels, and brachial plexus. The chest wall is seen on the left; the anterior aspect of the scapula covered by the subscapularis occupies the floor of the wound.

In 1898 Berger found that out of 46 cases there were only two deaths directly due to the operation, while ten were alive and well one year after the operation.

Buchanan has compiled an exhaustive list of the cases up till 1900 which were

operated on by Berger's method. In 1737 a patient, whose arm and scapula were completely torn off as a result of a machine accident, was successfully treated in St. Thomas's Hospital, and in 1808 Cunning performed the first successful operation for a gunshot wound, and in 1886 Crosty one for tumour. In 1887 Berger wrote an exhaustive monograph containing a clear description of the details of the operation. Buchanan gives a list of 181 cases (131 for tumour) with 16 per cent of deaths. To these may be added 31 cases in which, after disarticulation at the shoulder, the scapula was subsequently excised with 6·6 per cent of deaths. Since the introduction of antiseptics the mortality has been reduced to 8 per cent.

Jeaubran and Riche have collected 188 cases with a mortality of 11·1 per cent. They draw special attention to the fact that before 1887 the mortality was 29 per cent, but that now it is only 7·8 per cent. To Lister, therefore, as well as Berger, much credit must be given. They mention 8 cases of sarcoma in which a radical cure was obtained, although in Küster's case there was a recurrence after ten years' interval.

We would here allude to the necessity of making a thorough examination of the humerus in all new growths affecting it, in case excision or disarticulation at the shoulder-joint might not still be possible, and especially in cases of tumour of the scapula whether resection might not be sufficient, possibly combined with excision of the shoulder-joint.

The operation is performed through a racket or lanceolate incision, such as we always employ for amputations near the trunk, and is carried out as follows:—

Prophylactic control of hæmorrhage is obtained by ligaturing the large vessels, while the extent of the incision has often to be greatly modified as it depends on the amount of skin involved in the disease.

Operation. An incision down to the bone is made along the clavicle, and after separation of the periosteum with a raspatory, the clavicle is sawn through in its inner third, and pulled outwards with a sharp hook. The posterior layer of the periosteum and the underlying subclavius muscle are then carefully divided, the trunks of the brachial plexus exposed, and the individual cords isolated and divided after injection with novocain.

The axillary vein occupies an anterior position immediately behind the subclavius muscle, while the artery lies close below the nerves of the plexus. Both artery and vein are ligatured and divided.

If it be desired to restrict the hæmorrhage to a minimum, it is necessary to secure the branches of the subclavian which pass outwards in front of the scaleni. These are the ascending cervical passing vertically upwards, the superficial cervical passing upwards and outwards, the suprascapular passing horizontally beneath the clavicle, and, lastly, and most important, the transversalis colli artery, which passes outwards and backwards over or through the brachial plexus to supply the levator anguli scapulæ and supraspinatus muscles, and is continued downwards as the posterior scapular artery along the vertical border of the scapula, between the rhomboids and the serratus posticus superior. No important hæmorrhage need then be anticipated.

The operation is now proceeded with according to the method originally proposed by Rose for disarticulation at the hip—that is to say, as if the arm and scapula constituted a tumour which one had to excise. An incision is carried round the arm as is indicated in Fig. 254, and the skin, fascia, and the two pectoral muscles are divided. When the axilla contains infected glands the muscles are divided close to the thorax. In the absence of infected glands the muscles are divided close to their insertions into the humerus and coracoid process respectively. The cephalic vein, which runs in the groove in front of the deltoid, is avoided.

The dissection is continued along the outer wall of the thorax, *i.e.* the serratus magnus through the loose cellular tissue towards the ventral surface of the scapula, infected glands, should they exist, being at the same time raised from the thorax. When the posterior fold of the axilla is reached, the latissimus dorsi is divided close to its insertion, or nearer the thorax if the glands are involved.

The trapezius is now detached from the upper border of the clavicle and the

acromion process (if necessary the Lynn Thomas forceps being used to control the bleeding), after which the arm and shoulder are rotated outwards so as to completely expose the ventral aspect of the scapula and its muscles. At the upper angle the thick insertion of the levator anguli scapulæ is divided, and branches of the posterior scapular artery secured. The thick serratus magnus and the thinner rhomboids are then divided in succession along the vertebral border of the scapula. The arm and the scapula being now drawn away from the trunk, the trapezius is separated from the spine, and the omo-hyoid from the upper border of the scapula, and the arm and shoulder girdle are removed without appreciable loss of blood.

We performed this operation in 1902 on a boy for a diffuse sarcoma of the scapula, which involved the shoulder-joint and the upper portion of the humerus. Only two teaspoonfuls of blood were lost, and in five days the wound was simply covered with a strip of collodion, a single glass drainage tube having been inserted through a special opening in the posterior fold of the axilla.

Our description thus corresponds essentially to the interscapulo-thoracic disarticulation of Berger, who, along with Farabœuf, Adelmann and Chavasse, has gained distinction for the development of the best procedure. Bergmann also, according to Nasse, performs the operation in the same way as above described. Esmarch has added to the method the sawing of the clavicle and preliminary ligature of the subclavian vessels. If the tumour has invaded the skin extensively, Keen's plan of utilising the skin from the whole length of the upper arm may be employed.

END OF VOL. I

Printed by R. & R. Clark, Limited, *Edinburgh.*